

# Getting Started in Clinical Radiology

From Image to Diagnosis

George W. Eastman  
Christoph Wald  
Jane Crossin

Foreword by  
Reginald Greene







This book is dedicated to Gustav Bucky—  
radiologist, inventor, teacher.  
And with love to Mary and Jerry Crockett.

# Getting Started in Clinical Radiology

From Image to Diagnosis

**George W. Eastman, M.D.**

Professor of Radiology  
Virchow Campus of the Charité  
Humboldt University and Free University of Berlin  
Berlin, Germany

**Christoph Wald, M.D., Ph.D.**

Assistant Professor of Radiology  
Tufts University School of Medicine  
Boston, USA  
Department of Radiology  
Lahey Clinic  
Burlington, MA, USA

**Jane Crossin, M.D.**

Senior Lecturer Medical Imaging  
Department of Medical Imaging  
Royal Brisbane Hospital  
Brisbane, Australia

1035 illustrations

Thieme  
Stuttgart · New York

*Library of Congress Cataloging-in-Publication Data*

Eastman, George W.

Getting started in clinical radiology : from image to diagnosis / George W. Eastman, Christoph Wald, Jane Crossin.

p. ; cm.

Includes index.

ISBN 3-13-140361-6 (GTV : alk. paper) –

ISBN 1-58890-356-7 (TNY : alk. paper)

1. Radiology, Medical–Outlines, syllabi, etc.

2. Diagnostic imaging–Outlines, syllabi, etc.

[DNLM: 1. Diagnostic Imaging–Problems and Exercises.

2. Radiology–methods–Problems and Exercises.

WN 18.2 E13g 2005] I. Wald, Christoph. II. Crossin, Jane.

III. Title.

RC78.17.E37 2005

616.07'57–dc22

2005016549

**Important note:** Medicine is an ever-changing science undergoing continual development. Research and clinical experience are continually expanding our knowledge, in particular our knowledge of proper treatment and drug therapy. Insofar as this book mentions any dosage or application, readers may rest assured that the authors, editors, and publishers have made every effort to ensure that such references are in accordance with **the state of knowledge at the time of production of the book.**

Nevertheless, this does not involve, imply, or express any guarantee or responsibility on the part of the publishers in respect to any dosage instructions and forms of applications stated in the book. **Every user is requested to examine carefully** the manufacturers' leaflets accompanying each drug and to check, if necessary in consultation with a physician or specialist, whether the dosage schedules mentioned therein or the contraindications stated by the manufacturers differ from the statements made in the present book. Such examination is particularly important with drugs that are either rarely used or have been newly released on the market. Every dosage schedule or every form of application used is entirely at the user's own risk and responsibility. The authors and publishers request every user to report to the publishers any discrepancies or inaccuracies noticed. If errors in this work are found after publication, errata will be posted at [www.thieme.com](http://www.thieme.com) on the product description page.

Illustrator: Andrea Schnitzler, Innsbruck, Austria

© 2006 Georg Thieme Verlag,

Rüdigerstrasse 14, 70469 Stuttgart, Germany

<http://www.thieme.de>

Thieme New York, 333 Seventh Avenue,

New York, NY 10001 USA

<http://www.thieme.com>

Typesetting by Mitterweger &amp; Partner, Plankstadt

Printed in Germany by Grammlich, Pliezhausen

ISBN 3-13-140361-6 (GTV)

ISBN 1-58890-356-7 (TNY)

Some of the product names, patents, and registered designs referred to in this book are in fact registered trademarks or proprietary names even though specific reference to this fact is not always made in the text. Therefore, the appearance of a name without designation as proprietary is not to be construed as a representation by the publisher that it is in the public domain.

This book, including all parts thereof, is legally protected by copyright. Any use, exploitation, or commercialization outside the narrow limits set by copyright legislation, without the publisher's consent, is illegal and liable to prosecution. This applies in particular to photostat reproduction, copying, mimeographing, preparation of microfilms, and electronic data processing and storage.

## Foreword

The opening sentence says it all: "Radiology can be a lot of fun!" It summarizes what is unique about this book.

Radiology books designed for medical students have as their main purpose an introduction to the science and art of medical imaging. Behind this obvious purpose is an implicit intent also to fascinate students, and thereby to inspire some of the most susceptible and capable to choose a career in radiology. An early attempt to inspire students grew out of a classroom medical student teaching program, in which the radiologist Lucy Frank Squires was assisted by students and radiology trainees like myself. That course was wildly successful and attracted many students to a lifetime interest in radiology. What made this program unique was its light-hearted approach and the use of everyday household objects to explain radiological principles to the students, and to make them feel comfortable in the process.

This text by George W. Eastman, Chris Wald, and Jane Crossin is, in many ways, an extension of that successful humanistic formula for medical student teaching. The authors have captured our attention by introducing the subject through the eyes of fictional medical students to whom they have given form, substance, and personalities with emotions and fears. Although fictional, the characters are realistic in their foibles. What is new and different in this book is its clever use of these students to make us inquisitive about them as well as the real subject matter. This process relieves some of the inherent dryness of the topic by involving our hearts in the sharing of the uncertainties and concerns of the characters, and it captures our attention.

The thread of human connection to our fictional students weaves its way through the book. In the introduction we learn of the diverse backgrounds of the students, something of their private lives, and gain an inkling of their interactions with each other. In the chapter on chest radiology, we sympathetically experience the challenge of the subject material through their eyes.

The complexity of modern radiology is reflected in the organization and content of the book. The students' introduction to radiology starts with technical aspects of basic image acquisition and extends to the fundamentals of psychophysics in image perception, an important topic often overlooked in radiology texts. What follows includes principles of disease detection, disease diagnosis, and appropriate examination selection. As one who was a radiology trainee in the 1960s, I never cease to be amazed at how simple life was at that time. One chose between either film radiography or fluoroscopy; there was nothing else but nuclear medicine, which was then still in its infancy. Now, the wide range of imaging modalities makes it essential to learn how to choose between them to make the best use of imaging.

For this voyage of the medical student into the world of radiology, the authors have set sail toward a unique polar star that encompasses humanism as well as comprehensive imaging science. The text promises to introduce and guide a new generation of students into the fascinating world of radiological imaging.

Reginald Greene



## A Word of Thanks

We would like to thank all who have so generously contributed to the development of the overall concept and final realization of this book. First of all there are the many students and residents we persuaded to act as “didactic guinea pigs” for us. Their remarks were helpful and encouraging, sometimes keenly observed: “Awkward style!” Their contributions were substantial. The same holds true for a number of residents and fellows as well as staff radiologists in our respective departments poring over parts of the book and sharing their views on particular features. To ensure that the cases provided were not only radiologically correct but also reflected the referring physicians’ point of view, we asked quite a number of colleagues from other specialties to review the respective chapters. In particular we would like to thank Professor Hartmann (Ophthalmology), Dr. Schlunz (Facial and Plastic Surgery), Dr. Matthias (Ear Nose and Throat Surgery), Dr. Kandziora (Trauma Surgery), all from the Charité Hospital in Berlin; Professor Wagner (Radiology) from Marburg University; and Professor von Kummer (Neuroradiology) from Dresden University. All analogies used in Chapter 3, “Tools in Radiology”, were double-checked for correctness from an engineering point of view by Dr. Anton of Siemens Medical Systems. We would also like to acknowledge the support of Thavaganeshan Vasuthevan of GE Medical Systems.

We owe special thanks to Professor Wermke of the Charité for the permission to use his ultrasound images for Chapter 9, “Gastrointestinal Radiology.”

We are grateful to a long list of colleagues (see opposite) who have supported this book by supplying us with some of their best case material or in other ways.

None of this would have happened had it not been for the support of the publishers, Thieme. Special thanks go to Cliff Bergman, Juergen Luethje, and Antje Voss. They readily adopted the concept and enhanced or smoothed over

parts of it where this was felt to be necessary. They accompanied the book—with patience and motivation—through the production phase.

Each one of us has—at different times in our professional lives—benefited from working with inspired radiologists who had the ability to plant the enthusiasm for practicing and teaching radiology in our heads and hearts. On G.W.E.’s side these were Drs. Jürgen Freyschmidt, Hans-Stefan Stender, Klaus Langenbruch, Reginald Greene, Dan Kopans, Ad van Voorthuizen, and Jan Vielvoye. Among others, Drs. Robert E. Wise, Frank Scholz, Alain Pollak, and Roger Jenkins from the Lahey Clinic in Boston have been an invaluable inspiration for C.W. to remain in an academic career and look beyond the obvious. J.C. thanks Drs. Gord Weisbrod, Steve Herman, and Naeem Merchant in Toronto for sharing both their enthusiasm for radiology and their encyclopedic radiological knowledge. All of us loved to learn with books by Benjamin Felson, Clyde Helms, and Lucy Frank Squire.

Our families have, of course, felt the ups and downs of this project the most. The ease and the many different ways in which our children learn about this world we live in were a great source of ideas. The critical minds of our spouses put an end to many initial little afterthoughts, that, on reflection, it would have been unwise to include in this book. Many thanks for their patience.

Finally, this book—like all of radiology—is a dynamic affair. Any comments, criticisms, and suggestions for improvement are most welcome and will be considered in its further development. All those involved in teaching who would like to contribute first-rate didactic material are also invited to do so. All contacts can be made via [george.w.eastman@thieme.com](mailto:george.w.eastman@thieme.com).

George W. Eastman  
Chris Wald  
Jane Crossin

# Colleagues and Co-workers Who Have Contributed Images to this Book

## Chapter 6

Paul Bode of Leiden	Fig. 6.7
Ulrike Engert of Berlin	Fig. 6.25
Hans-Holger Jend of Bremen	Fig. 6.31
Matthias Jürgens and Michaela Fahrenkrug of Berlin	Fig. 6.33
Udo Kaisers of Berlin	Fig. 6.43c
Ajay Chavan of Oldenburg	Fig. 6.56

## Chapter 7

Hans-Frank Böttcher of Berlin	Fig. 7.2 b, c
Jörg Hendrik Seemann of Berlin	Figs 7.2d–f; 7.16c, d; 7.18a–d
Matthias Gutberlet of Berlin	Fig. 7.2g, h, j
Peter Ewert of Berlin	Fig. 7.2i
Jens Ricke of Berlin	Fig. 7.3a–c
Ulf Karl-Martin Teichgräber of Berlin	Fig. 7.14
Hans-Joachim Wagner of Marburg	Fig. 7.12a, b
Petr Podrabsky of Berlin	Fig. 7.13a, b

## Chapter 8

Walter T. Kating of Berlin	Fig. 8.11
Thomas Schnalke and Christa Scholz	Figs. 8.19b; 8.21b
Johannes Hierholzer of Potsdam	Fig. 8.24c
Helga Bertram of Berlin	Fig. 8.26
Gerwin Lingg and Corinna Schorn of Bad Kreuznach	Figs. 8.48–8.51; 8.72–8.75
Special thanks to the Rugby Club of Berlin	Fig. 8.29c

## Chapter 9

Rainer Roettgen of Berlin	Figs. 9.1a, b; 9.25b
Ulrike Engert of Berlin	Fig. 9.2c
Dieter Gläser of Berlin	Figs. 9.7b; 9.70l
Joachim Werner Kaufmann of Berlin	Figs. 9.20a; 9.25a
Johannes Hierholzer of Potsdam	Fig. 9.22a, b
Thomas Riebel of Berlin	Fig. 9.26a–d
Petr Podrabsky of Berlin	Fig. 9.37a–c
Helga Bertram of Berlin	Fig. 9.37d, e
Wolfram Wermke of Berlin	Figs. 9.41a; 9.42a; 9.43a (left), b; 9.45a; 9.47a; 9.48a; 9.49a; 9.50a; 9.56a, 9.59
Michael Westphal of Berlin	Fig. 9.70k
Matthias Grothoff of Berlin	Fig. 9.70n

## Chapter 10

Ricarda Rühl of Berlin	Fig. 10.1a, b
------------------------	---------------

## Chapter 11

Thomas Liebig of Hanover	Figs. 11.4; 11.30
Stefan Niehus and Michael Werk of Berlin	Fig. 11.7f–i
Karl-Titus Hoffmann of Berlin	Figs. 11.15; 11.28
Harald Bruhn of Berlin	Fig. 11.32

### *Chapter 11*

Uta Zaspel of Berlin

Fig. 12.5

Regina Bartezko of Berlin

Fig. 12.17a

Hanno Stobbe of Berlin

Fig. 12.17a, b

Magdalena Bostanioglo of Berlin

Figs. 12.11–12.14

### *Chapter 13*

Arne Lemke of Berlin

Fig. 13.18

Rüdiger von Kummer of Dresden

Fig. 13.19b–d

### *Chapter 14*

Walter T. Kating of Berlin

Fig. 14.9a, b

# Contents

<b>1 Why Another Textbook of Radiology?</b> . . . . .	<b>1</b>	<b>2 Radiology's Role in Medicine</b> . . . . .	<b>4</b>
Can You Imagine Radiology to be Fun? . . . . .	1	What Is So Different in Radiology as	
What Is So Special about Learning		Opposed to Other Clinical Disciplines? . . . . .	4
(and Teaching) Radiology? . . . . .	1	Which Other Special Aspects Are There	
What Makes This Textbook Different		to Consider? . . . . .	4
to Others? . . . . .	1	What Else Could Improve Your Compassion	
How Is This Book Structured? . . . . .	1	for the Radiologists? . . . . .	4
Who Will Accompany You through This Book? . . . . .	2		
What Is There to Say about the Style			
of the Book? . . . . .	3		

## A Short Run through Radiological Basics

<b>3 Tools in Radiology</b> . . . . .	<b>6</b>	Tissue Characteristics on Radiographic	
<b>3.1 Projection Radiography</b> . . . . .	<b>6</b>	Images . . . . .	18
Generation of X-Rays . . . . .	6	What Is a Normal, What Is a Pathological	
Attenuation of X-Rays . . . . .	6	Finding? . . . . .	21
Detection of X-Rays . . . . .	6	Where is the Pathology? . . . . .	21
Techniques of Exposure . . . . .	8	What Can Go Wrong in Perception? . . . . .	25
Contrast Media Examinations . . . . .	8	<b>4.2 Can We Reach a Diagnosis that Approaches</b>	
Image Processing . . . . .	8	<b>Histological Certainty?</b> . . . . .	26
<b>3.2 Computed Tomography</b> . . . . .	<b>9</b>	Are There Any Volume Changes? . . . . .	26
Working Principle . . . . .	9	What Happens to the Surrounding Anatomy? . . . . .	26
Contrast Media . . . . .	10	What Is the Internal Structure Like? . . . . .	26
<b>3.3 Ultrasonography</b> . . . . .	<b>10</b>	What Pathology Commonly Occurs in a	
Working Principle . . . . .	10	Particular Anatomical Region? . . . . .	26
<b>3.4 Magnetic Resonance Tomography</b> . . . . .	<b>10</b>	<b>5 Risks, Risk Minimization, and</b>	
Generation of the MR Signal . . . . .	11	<b>Prophylactic Measures</b> . . . . .	27
What Is So Special about the "External" and		<b>5.1 The Nonindicated Study</b> . . . . .	27
"Internal" Magnetic Fields? . . . . .	13	<b>5.2 The Ill-Prepared Study</b> . . . . .	28
How Do We Generate an MR Signal		<b>5.3 Studies with Contrast Media</b> . . . . .	29
in a Salami? . . . . .	13	Contrast Media in Radiography and CT . . . . .	29
Spatial Allocation of the MR signal . . . . .	14	Contrast Media in Magnetic Resonance	
Analysis of the MR Signal . . . . .	14	Tomography . . . . .	31
<b>3.5 Our Perception</b> . . . . .	<b>15</b>	Contrast Media in Ultrasonography . . . . .	31
<b>4 Phenomena in Imaging and</b>		<b>5.4 The False Finding</b> . . . . .	31
<b>Perception</b> . . . . .	<b>18</b>	<b>5.5 Risks of Radiological Procedures</b> . . . . .	32
<b>4.1 What Do I Need to Know for Image</b>		Risks of Projection Radiography and	
<b>Analysis?</b> . . . . .	18	Computed Tomography . . . . .	32
Is the Quality of the Study Technically		Risks of Ultrasound . . . . .	35
Adequate? . . . . .	18	Risks of Magnetic Resonance Tomography . . . . .	35
How Do I Analyze an Image? . . . . .	18	<b>5.6 Risks of Intervention</b> . . . . .	36



## From Detection to Diagnosis and Beyond

<b>6 Chest</b> .....	40	<b>8 Bone and Soft Tissues</b> .....	115
<b>6.1 How Do I Analyze a Radiograph of the Chest?</b> .....	40	<b>8.1 How Do You Analyze a Bone Image?</b> .....	120
First Determine the Image Quality .....	40	Bone .....	120
Now Go Ahead and Analyze the Thorax .....	40	Joints .....	120
Now Get Additional Information from the Lateral Chest Radiograph .....	46	Soft Tissues .....	120
I See an Abnormality—What Do I Do Now? .....	46	I See an Abnormality—What Do I Do Now? .....	121
<b>6.2 Opacities in the Lung</b> .....	47	<b>8.2 Diseases of the Bone</b> .....	121
Solitary, Circumscribed Opacity of the Lung .....	47	Focal Bone Lesions .....	121
Multiple Lesions in the Lung .....	56	Generalized Bone Diseases .....	132
Diffuse, Homogeneous Opacity of the Lung .....	60	<b>8.3 Diseases of the Spine</b> .....	139
<b>6.3 Acute Pulmonary Changes</b> .....	63	<b>8.4 Diseases of the Joints</b> .....	146
Acute Diffuse Linear, Reticular, Reticulonodular (Interstitial) Pattern .....	63	Joints of the Upper Extremity .....	147
Acute Diffuse Acinar, Confluent (Alveolar) Pattern .....	69	Joints of the Lower Extremity .....	151
<b>6.4 Chronic Lung Disease</b> .....	72	<b>8.5 Fracture and Dislocation</b> .....	161
Chronic Linear, Reticular, Micronodular (Interstitial) Pattern .....	72	<b>8.6 Soft Tissue Tumors</b> .....	162
<b>6.5 Pulmonary Symptoms without Correlating Findings in the Chest Radiograph</b> .....	78	<b>8.7 Gregory's Test</b> .....	164
<b>6.6 Lesions in the Mediastinum</b> .....	83	<b>9 Gastrointestinal Radiology</b> .....	168
Widening of the Upper Mediastinum .....	83	<b>9.1 How Do We Analyze an Abdominal Radiograph?</b> .....	174
Abnormal Findings of the Lower Mediastinum .....	86	What Can You Evaluate on an Abdominal Radiograph? .....	174
<b>6.7 Enlargement of the Hila</b> .....	91	Why Are You Interested in the Standard Chest Radiograph in a Patient with Abdominal Pain? .....	176
<b>6.8 The Ultimate Exam</b> .....	93	I See an Abnormality—What Do I Do Now? .....	176
<b>7 Cardiovascular and Interventional Radiology</b> .....	97	<b>9.2 Patient with Acute Abdominal Pain</b> .....	177
<b>7.1 Interventions in Vascular Occlusive Disease</b> .....	99	<b>9.3 Diseases of the Esophagus</b> .....	182
Arterial Occlusion .....	99	<b>9.4 Diseases of the Small Bowel</b> .....	188
Venous Obstruction .....	102	<b>9.5 Diseases of the Large Bowel</b> .....	192
<b>7.2 Tissue Biopsies</b> .....	104	<b>9.6 Problems with Defecation</b> .....	198
<b>7.3 Insertion of a Drain</b> .....	107	<b>9.7 Diseases of the Liver and the Intrahepatic Biliary System</b> .....	200
<b>7.4 Implantation of a Transjugular Intrahepatic Portosystemic Stent-Shunt (TIPSS)</b> .....	108	Focal Liver Lesion .....	200
<b>7.5 Implantation of a Vena Cava Filter</b> .....	109	Diffuse Liver Disease .....	208
<b>7.6 Implantation of a Port</b> .....	110	<b>9.8 Diseases of the Extrahepatic Biliary System</b> .....	210
<b>7.7 Embolization</b> .....	111	<b>9.9 Diseases of the Pancreas</b> .....	211
<b>7.8 Neural Blockades</b> .....	113	<b>9.10 Diseases of the Peritoneum and Retroperitoneum</b> .....	214
<b>7.9 Gregory's Test</b> .....	114	<b>9.11 Gregory's Test</b> .....	216

<b>10 Genitourinary Tract</b> .....	219	<b>12 Breast</b> .....	268
<b>10.1 How Do You Assess a Renal   Ultrasound?</b> .....	220	<b>12.1 How Do You Analyze   a Mammogram?</b> .....	270
I See an Abnormality—What Do I Do Now? ...	220	How Do You Evaluate the Image Quality? ...	270
<b>10.2 Renal Masses</b> .....	221	What Do You Have to Pay Attention to in Image Analysis?.....	270
<b>10.3 Renal Volume Loss/Renal Atrophy</b> .....	225	Ready for Your First Case? Let's Go! .....	272
<b>10.4 Increase in Renal Volume</b> .....	226	<b>12.2 Tumorlike Lesions and   Tumors of the Breast</b> .....	272
<b>10.5 Renal Calculi</b> .....	227	<b>12.3 Breast Implant</b> .....	280
<b>10.6 Adrenal Tumors</b> .....	228	<b>12.4 Tumors of the Male Breast</b> .....	282
<b>10.7 Where Is Greg?</b> .....	229	<b>12.5 Dr. Skywang's Test</b> .....	283
<b>11 Central Nervous System</b> .....	231	<b>13 Face and Neck Imaging</b> .....	285
<b>11.1 How Do You Analyze   a Sectional Study of the Head?</b> .....	233	<b>13.1 Diseases of the Nose   and Sinuses</b> .....	286
Key Points of Thorough Image Analysis .....	233	<b>13.2 Disease of the Ears</b> .....	292
I See an Abnormality—What Do I Do Now? ...	234	<b>13.3 Diseases of the   Temporomandibular Joint</b> .....	293
Are You Ready for Your First Case?.....	234	<b>13.4 Injuries and Diseases   of the Orbit</b> .....	294
<b>11.2 Perfusion Disturbances   of the Brain</b> .....	235	<b>13.5 Diseases of the Neck</b> .....	299
Brain Hemorrhage .....	235	<b>13.6 The Teeth You Need</b> .....	302
Cerebral Infarction .....	237	<b>14 Trauma</b> .....	304
<b>11.3 Brain Tumors</b> .....	240	<b>14.1 Polytrauma</b> .....	304
Perisellar Brain Tumors .....	250	<b>14.2 Luxations and Fractures</b> .....	331
Tumors of the Cerebellopontine Angle .....	253	<b>14.3 Hannah's Test</b> .....	339
<b>11.4 Neurodegenerative Diseases</b> .....	255		
<b>11.5 Congenital Disorders of the Brain</b> .....	258		
<b>11.6 Spinal Cord Tumors</b> .....	261		
<b>11.7 Gregory's Vernissage</b> .....	266		
<b>Solutions to the Test Cases</b> .....	342		
<b>Post Scriptum</b> .....	344		
<b>Index</b> .....	345		



---

# 1 Why Another Textbook of Radiology?

## Can You Imagine Radiology to be Fun?

Radiology can be a lot of fun! It is this very personal experience of the authors that will accompany you throughout this book and hopefully throughout the rest of your medical life. It is also the main reason why we considered this book to be necessary. Can diagnostic imaging and the therapy of patients in need be a pleasant task? The answer is a resounding “yes.” Successful management in medicine relies on keeping a certain distance from the events. Empathy and respect are essential for a trustful relationship with the patient. The optimal path to the right diagnosis and subsequent adequate therapy, however, requires primarily clear thinking. Clear thinking, in turn, greatly profits from motivation, optimism, and enjoyment of what one is doing. The enthusiasm for a “great case,” which temporarily seems to ignore the often tragic personal fate of the patient, must not be taken away from the radiologist. The same is true for learning about radiology—as a student, as a young doctor: One has to enthuse the neophytes for the fascinating field of radiology!

## What Is So Special about Learning (and Teaching) Radiology?

Radiology is a gigantic, continually growing specialty that gets ever more complex by the month. It is, for several reasons, not to be learned by heart. The tools of image acquisition and image analysis have to be mastered, i.e., their principles have to be understood. Understanding the principles of imaging—just like the understanding of any individual image—is primarily an intellectual challenge. It is on this foundation that specific knowledge can be accumulated, of course through reading the literature but most of all through very personal transfer of experience: “There is no substitute for a seasoned radiology teacher.” In few medical fields can the exchange of knowledge between the teacher and the trainee be as intense, interactive, and multifaceted as in radiology. Radiology for that reason is a didactic specialty “par excellence.” Using exemplary image material, most relevant diagnostic techniques can be taught and learned. That is the great opportunity of academic radiology—we just have to seize it.

## What Makes This Textbook Different to Others?

Well . . . a lot of things. But one of the main ideas we try to convey in this book is the overriding importance of a

sound indication for every radiological examination or therapy. The number of nonindicated examinations is unfortunately high; the driving forces are manifold: litigation, examinations that are “en vogue,” overworked referring doctors who would rather get the scan and then examine the patient, and the practice of self-referral by non-radiologists who have a financial interest in imaging the patient in their own private practice or institution. All lead to many unnecessary diagnostic examinations with unintended consequences for our patients. Overutilization also poses a threat for the future—i.e., your professional life and our healthcare systems—as it is not economically sustainable in any of today’s societies. We would like to infuse you with the right attitude and give a proper orientation of what is indicated when. The indication guidelines of the British Royal College of Radiologists under the title “Making the best use of a Department of Clinical Radiology” have thus been inserted into and adapted to this book.

## How Is This Book Structured?

The first part of this book, entitled “**A Short Run Through Radiological Basics**,” will describe and hopefully allow you to understand the essentials of imaging. For starters, you are going to be fed the technical principles of image acquisition. To keep this part digestible, “normal life” analogies have been recruited wherever complex technologies made this necessary and where it was felt to be didactically appropriate. Subsequently we’ll take you through the phenomena and procedures that help you tackle image analysis in diagnostic imaging. We take special care to alert you to the importance of psychophysical perception: in a world filled with fantastically expensive imaging equipment it is still your visual and central nervous system that detects and categorizes disease. This fundamental truth is frequently underrepresented in other texts. Last but not least, you are going to learn about the obvious and not so obvious risks of imaging and image-guided therapy.

The second, the clinical, part of this book is entitled “**From Detection to Diagnosis and Beyond**.” You will get to know not only the specific examination modalities for each organ system but also the most efficient diagnostic work-up in emergency radiology—under circumstances you will encounter in your not too distant future professional medical life when you are most likely to make crucial decisions yourself. You will be confronted with cases to solve just as if you were already engulfed in clinical routine. Every individual problem is approached by a combination of image analyses, taking into account relevant available history,

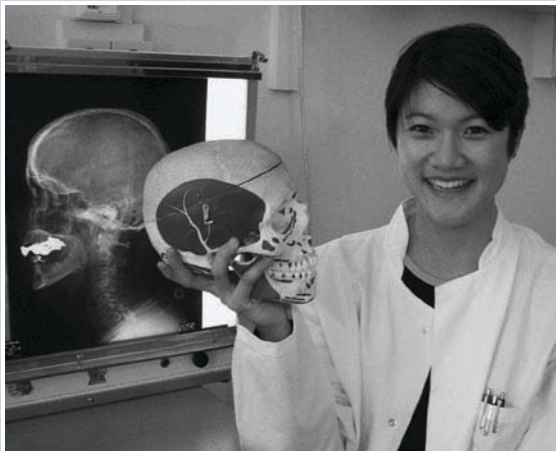


and whatever clinical symptoms you might be able to verify yourself. The path to the right diagnosis is then laid out—you just have to stay on it. The differential diagnoses are described in the approximate order of likelihood, if that does not interfere with the didactic point to be made. The traditional pathologically oriented approach thus takes a step back to leave center stage to radiological morphology: it is just you and the image you have to evaluate.

### Who Will Accompany You through This Book?

Five medical students will see you through this book: Giufeng, Hannah, Joey, Paul, and Ajay. All of them are bright, highly motivated kids, well prepared by their teachers and eager to solve cases on their own. It goes without saying that they eventually present their findings to “their” radiologist in charge—to get the final blessing and to learn

even more. Their first few weeks in radiology have made them inspired diagnosticians, running down interesting cases and not giving up before they find a convincing diagnosis. They are also a truly international bunch, having been attracted to this academic hospital in “down under” Sydney for a variety of reasons. (Hannah, Giufeng, Joey, Paul, and Ajay are, of course, fictitious persons. All stories relating to them are also pure fiction. We would like to thank our young colleagues and collaborators Juliane Stoll, Il-Kang Na, Ralph Patrick Chukwuedo, Ansgar Leidinger and Tino Bejach for the permission to use their pictures. Working together with them was a lot of fun. A great thanks goes to our pleasant young colleague Gero Wieners who posed as Gregory. The patients’ names are also fictitious. Similarities to real persons are not intended and are pure coincidence. The cases are didactically optimized and compressed to fit the objective of this book.)



**Giufeng** (Chinese for “the gentle one”) (Fig. 1.1) is a native of Sydney, to where her parents moved in the eighties straight from Singapore. As you can undoubtedly tell from the picture, she has developed a special interest in neuroradiology. She knows everything about the cranial nerves, their tracts and nuclei. The sensory organs are another one of her specialties. For that and other reasons, Gregory, the senior resident assigned to neuroradiology, frequently visits with her.



**Hannah** (Fig. 1.2) has come from Berlin for her final year in medical school. Her love of the sun, the beach, and classical music got her to the “emerald city.” If she had to pick a favorite field in radiology, she would probably choose musculoskeletal radiology. She has already made up her mind to try her luck in radiology, but if that doesn’t work out she will try to become an orthoped. She never loses control, however mixed-up things may be. Wiseguys get finished off by her with just a few carefully chosen words. Her private passion is—you guessed it already—surfing on Sydney’s Bondi beach.



**Paul** (Fig. 1.3) says he sucked radiology in with his mother’s milk. His father is a medical physicist, his mother a successful painter of abstract art, his brother a Melbourne investment broker almost unscathed by any bear attacks. Paul loves to dive into complex cases much like others get submerged in the latest thriller by Michael Crichton. In any case: He finds radiology a very attractive field—almost as attractive as . . . well, as far as Paul is concerned, he is getting sick and tired of this neuro guy and his interventions.

## What Is There to Say about the Style of the Book?

Radiology is a thriving field with fashions, moods, fascinating personalities, and a lot of history to go around. Radiologists love to assign names to phenomena, signs, and techniques. Most of these are globally understood—radiology was a truly global thing from the very beginning. So there are a lot of Latin, German, and French terms—add a Greek cracker now and then. If they help us understand, we should use them. Some remind us of great physicians who were inventors, researchers, teachers. It does not hurt to acknowledge their accomplishments, and we support that by giving a little worthwhile or possibly useless information about them now and then in this book.



**Ajay** (Fig. 1.4) is originally from Johannesburg, South Africa, where his grandfather used to work with a certain Mahatma Gandhi. The family is rumored to be obscenely rich—car manufacturing, real estate, you name it. He is already married at the age of 25, much to the sorrow of the women around him. His wife is dashingly beautiful and three handsome kids are coming right after their father. Ajay has an untamable urge to tell delicate jokes to everyone, in one of four languages. He is interested in radiology because he loves to handle expensive hardware.



**Joey** (Fig. 1.5) has just managed to make the right histological diagnosis off just one radiograph—and seems to enjoy the experience. He will hopefully make this a habit. Joey just loves intervention. Every time he watches a difficult angiographic or drainage procedure, his fingers grab for imaginary catheters, guide wires, and needles. The interventional folks have recognized his passion for their trade and let him work with them whenever it is possible. As for his social life, he comes across as the “big loner.” Apart from that he is a cheerful guy from New York who has left that city for the first time in his life to do his radiology “down under.”



And then there is **Gregory** (Fig. 1.6), of course. As already mentioned, he is the young and enterprising senior resident with a special interest in neuroradiology. He has made it a habit to take care of the medical students—with very definite preferences and in more than one way. He is hoping for an academic career. His hormonal status is acknowledged with benevolent interest by many in the department. A nice guy at heart, he can turn into a son of a . . . at times. When you come right down to it, he is just one of us normal guys in academia.

---

## 2 Radiology's Role in Medicine

### What Is So Different in Radiology as Opposed to Other Clinical Disciplines?

A radiologist primarily approaches the patients by looking at images, in a procedure quite similar to the one pathologists normally follow but quite unlike what any other clinical specialist would do. The unbiased analysis of the image is the first, and undoubtedly an abstract, intellectual step. This certainly implies that radiologists must be pretty brainy, or else they can lay down their arms right there. Thus, there should be a little Sherlock Holmes in every one of them, although county sheriffs have also been reported to survive. It is in a secondary step that we study the clinical symptoms in order to verify, improve, or—yes—dump our diagnosis and go back to square one. This procedure has many advantages, but it makes radiologists vulnerable when information is withheld or cannot be correctly evaluated.

### Which Other Special Aspects Are There to Consider?

The radiology department is basically a consultative service unit for the hospital. Few other disciplines can do without it. For that reason, communication with colleagues from other fields is tremendously important and not always without glitches. At the same time it is rather transparent to the referring doctors what the radiologists do and do not do; few colleagues talk about and document their work as well as radiologists do. Patient management and the administration of reporting as well as image distribution are further cornerstones for swift and effective diagnoses and interventions.

### What Else Could Improve Your Compassion for the Radiologists?

A few, admittedly cocky, statements might get you on the road. A radiologist is:

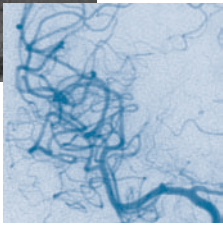
- The heroic person who presents—swiftly and accurately—hundreds of images to a bunch of hotheaded trauma surgeons in their morning round, some of whom have studied those very images with much more time and with the patient and her or his symptoms at hand. Any surgeon will tell you: There is nothing like chewing up a radiologist for breakfast before a great day in the operating room. You need a big heart and a lot of sympathy for all these colleagues whose psychological pressure at times surpasses that suffered by the radiological profession.
- The person who—on a single day—pronounces hundreds of patients to be healthy in heart and lung just on the basis of a single chest film. He or she then dares to put this down in writing, for all colleagues to see and question from then on to eternity.
- The person who—on the basis of rudimentary clinical data, if any—presents available image material at the noontime general medical radiology meeting, with listing of delicately weighted differential diagnoses for every patient, while at the same time out of the dark of the back of the room miraculously appears the hitherto unknown information that renders two-thirds of these differential diagnoses ridiculous.
- The person who has to reconsider all diagnostic and interventional procedures every half year because rapid technological and scientific developments in radiology make this absolutely necessary.
- To call it an end, the person who starts to shiver, groan, and giggle foolishly when finally coming across the splendid example of a pigmented villonodular synovitis that has been the missing link in the personal teaching file.

This has to be sufficient as justification for this book and as a peek into the soul and life of radiology.

# A Short Run through Radiological Basics



# 3 Tools in Radiology



## 3.1 Projection Radiography

Good old projection radiography remains one of the staples of radiology, although a little over 100 years old. And it is by no means obsolete even in times of multi-million-dollar high-tech imaging equipment. The bulk of all diagnostic imaging studies is still done with this technology. Mammography, a prominent representative of this group, is the only imaging study that has been proven to lower patient mortality significantly—if performed correctly and, of course, only in women. The basic technical principle of projection radiography is simple. However, the complete chain of events from generating the x-ray beam to viewing the developed image can be full of surprises to keep even the “pro” busy making sure everything is done properly and the radiograph at hand is a quality product. With insufficient knowledge or lack of experience and care, things can easily derail—there are enough catastrophic studies to prove that point.

### Generation of X-Rays

A high-voltage current is built up between a cathode and an anode, all of this inside a vacuum tube (Fig. 3.1). The cathode is heated to about 2000°C by a specific heating filament. Electrons are emitted by the cathode, accelerated by the electric field between cathode and anode, and hit the anode with considerable energy, where they induce electromagnetic radiation of the type called x-rays. These rays are richer in energy the higher the applied voltage. The area where the electrons hit the anode is called the focus. As a lot of heat is generated in the process, the anode consists of a heat-resistant disk covered with tungsten in most cases. The disk rotates quickly to disperse the heat along its circumference, thus forming a focal track. The vacuum tube is surrounded by oil inside a lead-lined housing that features only one small opening for the radiation to escape.

The generated radiation has a spectrum, or spread of energies, only a part of which can be used for imaging. Some of the so-called “soft” or very low-energy rays would be completely absorbed by the body’s soft tissues and thus only increase the dose to the patient without contributing anything to the image. For that reason, they are filtered out, typically by an aluminum or copper sheet. In addition the radiation exiting the tube housing is also constrained by lead collimators that keep the beam strictly limited to the body area of interest.

### Attenuation of X-Rays

X-rays are attenuated as they pass through the patient’s body. Two processes play a role: absorption and scatter. With lower-energy radiation (corresponding to lower exposure voltage) **absorption** dominates. It correlates well with the atomic number of the irradiated matter. Mammography makes proper use of this characteristic and employs low-energy radiation to detect minute spots of calcium in the breast that may indicate cancer. With high-energy radiation (corresponding to high exposure voltage) **scatter** is mainly responsible for attenuation. In this process the radiation beam loses energy and is diverted in all directions (scattered). The scattered radiation increases with irradiated body volume. It is hazardous for patients and their immediate vicinity, i.e., the angiographer standing alongside the patient to work with his or her catheters. When scatter reaches the detector, it causes an unstructured shade of gray that diminishes the contrast of the image. A scatter grid (Fig. 3.1) positioned in front of the detector reduces this “diverted” radiation.



#### The Guy Who Took Care of the Scatter

Gustav Bucky’s name is known to radiologists all over the world for his invention of the scatter grid in 1912. After the initial presentation at a medical convention, some colleagues suggested that the images were so good it must be a hoax. Having been forced into emigration by the Nazis, he left Berlin for New York, where he continued his innovative work. With his invention of the grid that is in use in every x-ray machine to this very day he eventually earned the lump sum of \$25—ingenuity is definitely not a monetary unit.

### Detection of X-Rays

A variety of detectors can make x-rays visible. The simplest is **photographic film**; because of the high spatial resolution one can achieve, it is used in nondestructive testing of industrial materials such as alloy car wheels or gas pipelines. To expose film alone an incredible dose of x-rays is necessary, but that does not matter in this instance. Film is much less sensitive to x-rays than to light—any airport security x-ray scan will show you the inside of your camera without significantly damaging your valuable vacation photos, which proves the point. As light exposes film much better, in diagnostic radiology a combination is used of film and **intensifying screens** that are made of rare earth materials (gadolinium, barium, lanthanum, yttrium). These screens fluoresce when irradiated (just like

## Generation of x-Rays

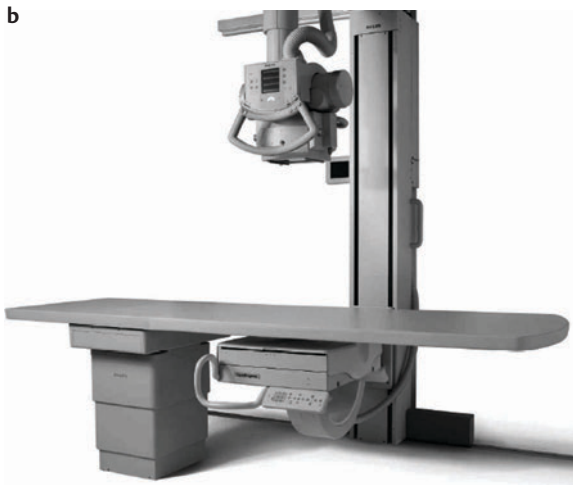
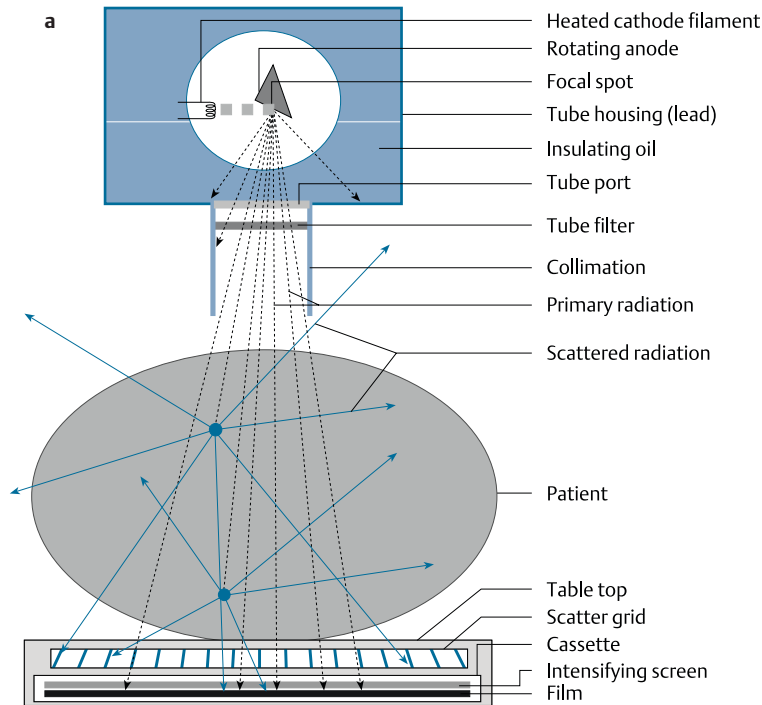


Fig. 3.1 **a** The figure shows the generation of x-rays, their attenuation due to scatter, and their detection.

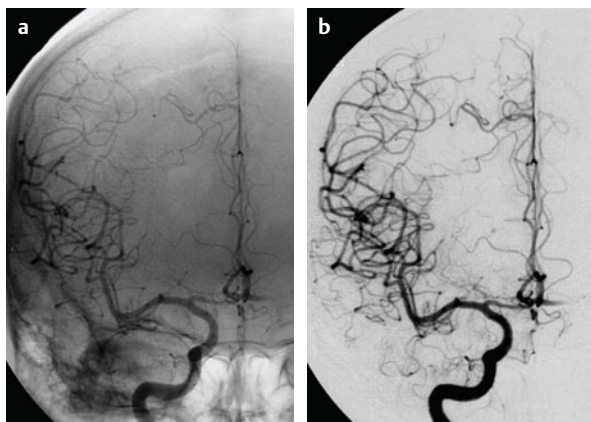
**b** This is a modern digital projection radiography unit used primarily for skeletal work (by Philips Medical Systems).

the foil of “Bariumpatincyanür” that Wilhelm Conrad Roentgen used in his initial experiments) and thus expose the film. Usually the film is sandwiched between two intensifying screens inside a light-tight cassette.

**!** Film–screen combinations vary greatly in their x-ray sensitivity and spatial resolution and thus have to be selected according to the specific imaging problem to be solved. If the depiction of fine detail is important, the required dose is generally higher. If the dose must be kept as low as possible, such as in children, fine detail must often be sacrificed.

Some intensifying screens emit the main fraction of their light only after stimulation by a laser beam. These screens are called **storage phosphors**. After their exposure they are scanned in a read-out system and their information content is immediately digitized. These screens can register a larger bandwidth of radiation intensity, which is why “over- or underexposure” is widely tolerated by the digital system. The information content of the image and the dose to the patient, however, may be inadequate although the image looks normal at first glance. Another digital detector that is currently becoming popular consists of a layer of **cesium iodide** crystals on top of

### Digital Subtraction Angiography (DSA)



**Fig. 3.2a** The arterial vasculature of the brain is very complex. The bony skull is not simple either.

**b** If a precontrast image is subtracted from the image after contrast administration, the bony structures, especially at the skull base, disappear and the visualization of the vascular tree improves considerably.

an amorphous silicon photodiode panel. The crystals light up when hit by x-rays and their light is then converted into an electronic charge by the photodiode. This is immediately read out by special electronics.

For fluoroscopy (e.g., in small-bowel follow-through or in vascular intervention) **image intensifier systems** are used. A luminescent layer that covers a large-area cathode absorbs the x-rays. The emitted light liberates electrons in the cathode material. These electrons are focused by electronic lenses and hit a small screen that serves as anode. All this happens inside an evacuated large tube. The resulting very bright image is registered by an external television camera and shown on a viewing monitor.

Other digital detectors are used in computed tomography (see p. 9) or are being tried out for projection radiography. The resulting signal is always a digital one, permitting post-processing of images and archiving and image communication with an ease unheard of in analog systems.

### Techniques of Exposure

**Projection radiography:** The usual radiograph is a summation image of the exposed body part. A nodule seen over the lung fields, for example, cannot generally be assigned to the lung, the anterior or posterior chest wall, or even the skin surface, because all these structures are superimposed on each other. Clinical inspection, a little brain work, a lateral projection, a fluoroscopy, or a conventional or computed tomography might help.

**!** In projection radiography, a decrease in transparency or a “shadow” (e.g., a tumor) is bright; an increase in transparency (e.g., air in the bowel) is dark.

**Conventional tomography:** In conventional tomography, only a single slice of the body (e.g., in the hip joint) is depicted while all others are blurred by motion. During the exposure the x-ray tube and the detector move in opposite directions parallel to the imaging plane. A steel beam connects the two and swivels around a movable axis. The

position of the axis marks the body layer that is imaged motion-free—the tomographic plane. By moving the beam axis ventrally or dorsally, other planes can be selected. Conventional tomography is a beautiful but dying art—well-equipped departments continue to use it for special, mostly skeletal, studies.

**Fluoroscopy:** In a considerable number of diagnostic and interventional examinations, the function and morphology of, for example, hollow organs are first evaluated in real time under fluoroscopy with image intensifier systems. Exposures of specific regions, projections, and findings are then performed separately but often with these same systems. The exposures can be viewed immediately on a monitor.

### Contrast Media Examinations

To take a closer look at the **gastrointestinal tract**, it is filled with iodinated contrast solution or a barium suspension. Iodine and barium have high atomic numbers; they therefore absorb x-rays splendidly and are very visible on the radiograph. Barium suspensions can also be prepared and instilled to beautifully coat the interior wall of the air-filled or fluid-filled bowel (for example, in double contrast barium enemas).

To look at the **vascular system**, for example, in interventional procedures such as balloon dilations of the arteries, iodinated contrast solution is injected into the vessel. In angiography, subtraction is used to improve the depiction of vessels: the images before contrast are subtracted from the images after contrast administration. The resulting radiographs show only the vascular tree without the anatomical background. This is especially helpful in the abdomen and the skull base (Fig. 3.2).

### Image Processing

Rest assured that the chemistry of traditional film processing or the post-processing of digital radiographs is all but trivial. The effects on image quality and patient dose can

### 3D Reconstruction

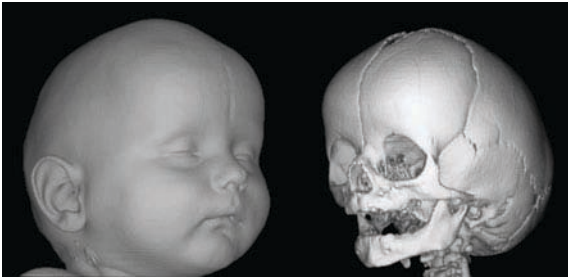


Fig. 3.3 This complete 3D reconstruction of a child's head was performed as a special service to the plastic surgeons: They wanted a precise documentation before surgically approaching a congenital skeletal abnormality. The left part of the image shows the head with surrounding soft tissue and also the finding that worried the patient's parents. What do you make of it? There is an accessory median suture of the frontal bone.

be tremendous. It is a regular and exciting pastime of experienced radiologists to detect and correct any mistakes that the numerous systems may come up with.

## 3.2 Computed Tomography

Computed tomography (CT) is currently the workhorse of radiology. Recent technical developments permit extremely fast volume scans that may serve to generate two-dimensional slices in all possible orientations as well as sophisticated three-dimensional reconstructions (Fig. 3.3). The radiation dose, however, remains high and continues to require a very strict indication for every intended CT.

### Working Principle

In computed tomography the x-ray tube continuously rotates around the cranio-caudal axis of the patient. A beam of radiation passes through the body and hits a ring or a moving ring segment of detectors. The incoming radiation is continuously registered, the signal is digitized and fed into a data matrix taking into account the varying beam angulations (Fig. 3.4). The data matrix can then be transformed into an output image. In today's modern CT machines the tube rotation continues as the patient is fed through the ringlike CT gantry, thus generating not single slice scans but **spiral volume scans** of larger body

Table 3.1 Attenuation of different body components

Body component	Hounsfield units (HU)
Bone	1000 to 2000
Thrombus	60 to 100
Liver	50 to 70
Spleen	40 to 50
Kidney	25 to 45
White brain matter	20 to 35
Gray brain matter	35 to 45
Water	-5 to 5
Fat	-100 to -25
Lung	-1000 to -400

### Working Principle of Computed Tomography

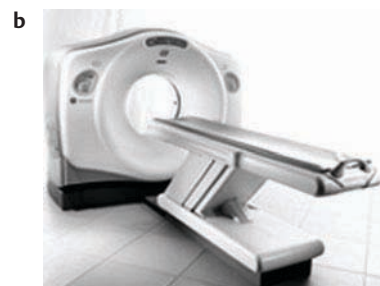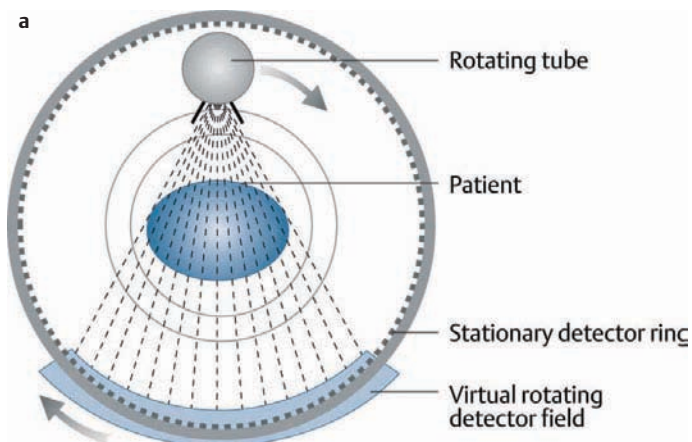


Fig. 3.4 **a** The x-ray tube rotates continuously around the longitudinal axis of the patient. A rotating curved detector field opposite to the tube registers the attenuated fan beam after it has passed through the patient. Taking into account the tube position at each time point of measurement, the resulting attenuation values are fed into a data matrix and further computed to create an image. **b** This is a modern volume CT scanner (by GE Medical Systems).



segments. For each picture element (pixel) the attenuation of the radiation is calculated and expressed as Hounsfield units (HU) (Table 3.1). Water has, by definition, a Hounsfield unit value of 0.

### Contrast Media

Contrast media are used in CT to visualize vessels and the vascularization of different organ systems. They attenuate radiation because of their high atomic number (e.g., iodine and barium). Contrast media containing gadolinium (which also has a high atomic number) normally intended for use in magnetic resonance tomography could theoretically also be used in CT if the administration of iodine is contraindicated. They are, however, incredibly expensive and not registered for this use yet. To better appreciate the inside of hollow viscera, iodine or barium contrast media are also given orally or instilled into the rectum.

**!** Fat and air are always black in CT; bone cortex and high-atomic-number contrast media are always white.

## 3.3 Ultrasonography

Ultrasonography (“ultrasound”) is the cheapest and most “harmless” technology in radiology. For these reasons many physicians outside radiology also use the modality. Wherever ultrasound provides sufficient information and wherever radiation dose must be minimized at any cost (pediatrics and obstetrics), it is the primary imaging modality of choice. For the examination of vessels and blood flow, color-coded Doppler ultrasound may be used.

### Working Principle

Ultrasound technology is simple—any bat knows how to do it. In medical ultrasonography the sound waves are generated artificially by means of **piezoelectric crystals**. These crystals are magic gadgets: when connected to an alternating current of a certain frequency, they will vibrate and thus emit a sound wave of the same frequency. If, on the other hand, they are exposed to sound waves of a certain frequency, they will produce an alternating current of that frequency.

**!** For medical purposes sound waves of 1–15 MHz frequency are used—in audible ultrasound waves.

If, by way of ultrasound gel, the crystal is brought into direct contact with the body, the emitted **ultrasound waves** spread through the tissue. The tissue absorbs, scatters, or reflects them.

*Absorption* and spatial resolution increase with higher frequencies. For that reason the maximum penetration of ultrasound waves and the depiction of fine image details correlate with frequency: in breast imaging high-resolution 7.5–10 MHz systems may be used, while in

abdominal imaging 3.5–5 MHz systems are adequate to view also the deeper regions. Bone and calcifications absorb sound totally, which is why we see an acoustic “shadow” behind them (Fig. 3.5). Very little sound is absorbed in fluid-filled viscera, leading to the opposite effect: the echo-signal behind the fluid is stronger than in the tissue around it.

Only the *reflection* of sound back to the piezoelectric crystal will result in a signal as the basis for an image. Large and minute tissue interfaces reflect the sound. If it is an interface between soft tissue and air/gas, reflection is total—structures behind it cannot be imaged, also resulting in an acoustic shadow (Fig. 3.5). The ultrasound scanner calculates a two-dimensional image—how on earth does it do that? From the time passing between seeing a lightning discharge and hearing its resulting thunder we can estimate our distance to the thunderstorm. The ultrasound system measures, for each crystal separately, the time between each emitted sound pulse and the received echo pulses reflected by the tissue. The elapsed time defines the pixel matrix row that the signal is assigned to. The intensity of the echo pulse defines the respective gray value of the pixel. Hundreds of piezoelectric crystal elements are arranged in a row, and their combined data are fused into one two-dimensional ultrasound image.

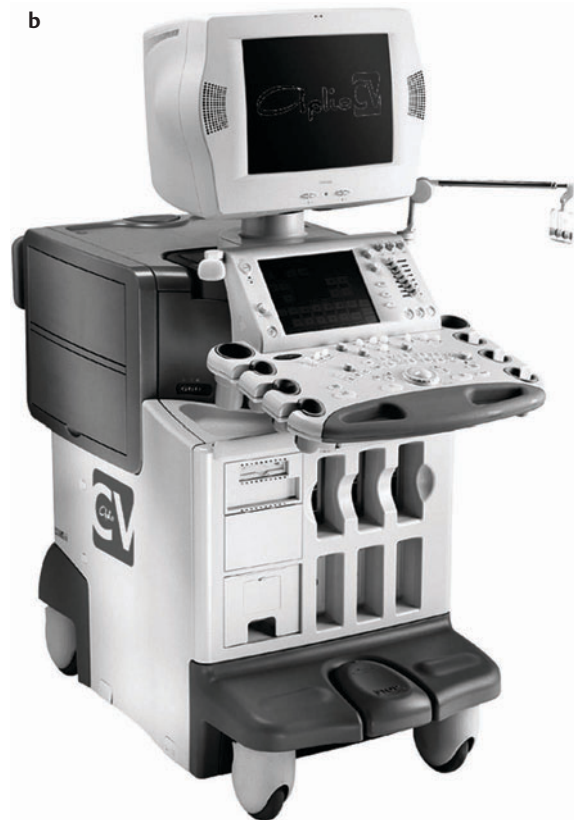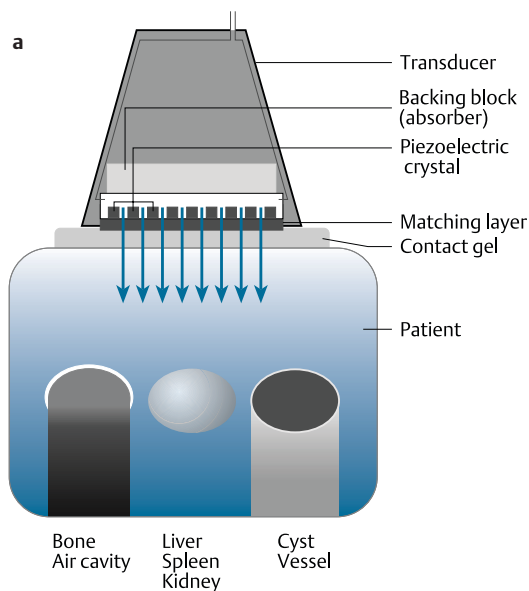
**!** In ultrasound, cystic structures are dark and show signal increase behind them. Bone and air are bright and cause an acoustic shadow.

**Color-coded Doppler ultrasound:** By listening to the sound of a passing motorcycle we can find out whether it is coming or going and estimate how fast it is. If ultrasound waves are reflected by moving interfaces (such as erythrocytes in flowing blood) at an angle of 10–60°, the same effect (the Doppler effect) comes into play: the echo undergoes a frequency shift dependent on the speed and direction of the blood flow. This information can be color coded into a normal ultrasound image. In color-coded Doppler ultrasound, color type and intensity tell us the direction and speed of the blood flow. As a convention, venous, centripetal flow is coded as blue; arterial, centrifugal flow as red. But take note: You accidentally rotate the scanner probe by 180° and the colors switch! And as your probe approaches a 90° angle relative to the vessel, your Doppler signal vanishes altogether. Special ultrasound contrast media further increase the Doppler effect.

## 3.4 Magnetic Resonance Tomography

Magnetic resonance tomography is the technically most complex imaging modality in radiology but it also holds the largest diagnostic potential. Many are terrified by the prospect of having to understand the basic principles of magnetic resonance (MR). All of this is completely unnecessary, of course: the thing is in essence nothing but a bicycle dynamo. But let’s start at the beginning.

## Working Principle of Ultrasonography



**Fig. 3.5a** If an alternating electric current is sent through a piezoelectric crystal, it vibrates with the frequency of the current, producing sound waves of that frequency. In medical ultrasound, typical frequencies vary between 1 and 15 MHz. Ultrasound gel acoustically couples the ultrasound transducer to the body, where the ultrasound waves can then spread. Inside the body the sound is absorbed, scattered, or reflected. Fluid filled (cystic) structures appear dark and show acoustic enhancement behind them. Bone and air appear bright because they absorb and reflect the sound, showing an “acoustic shadow” behind them.

**b** This is a modern US scanner (by Toshiba Medical Systems).  
**c** These are transducers for different purposes.

## Generation of the MR Signal

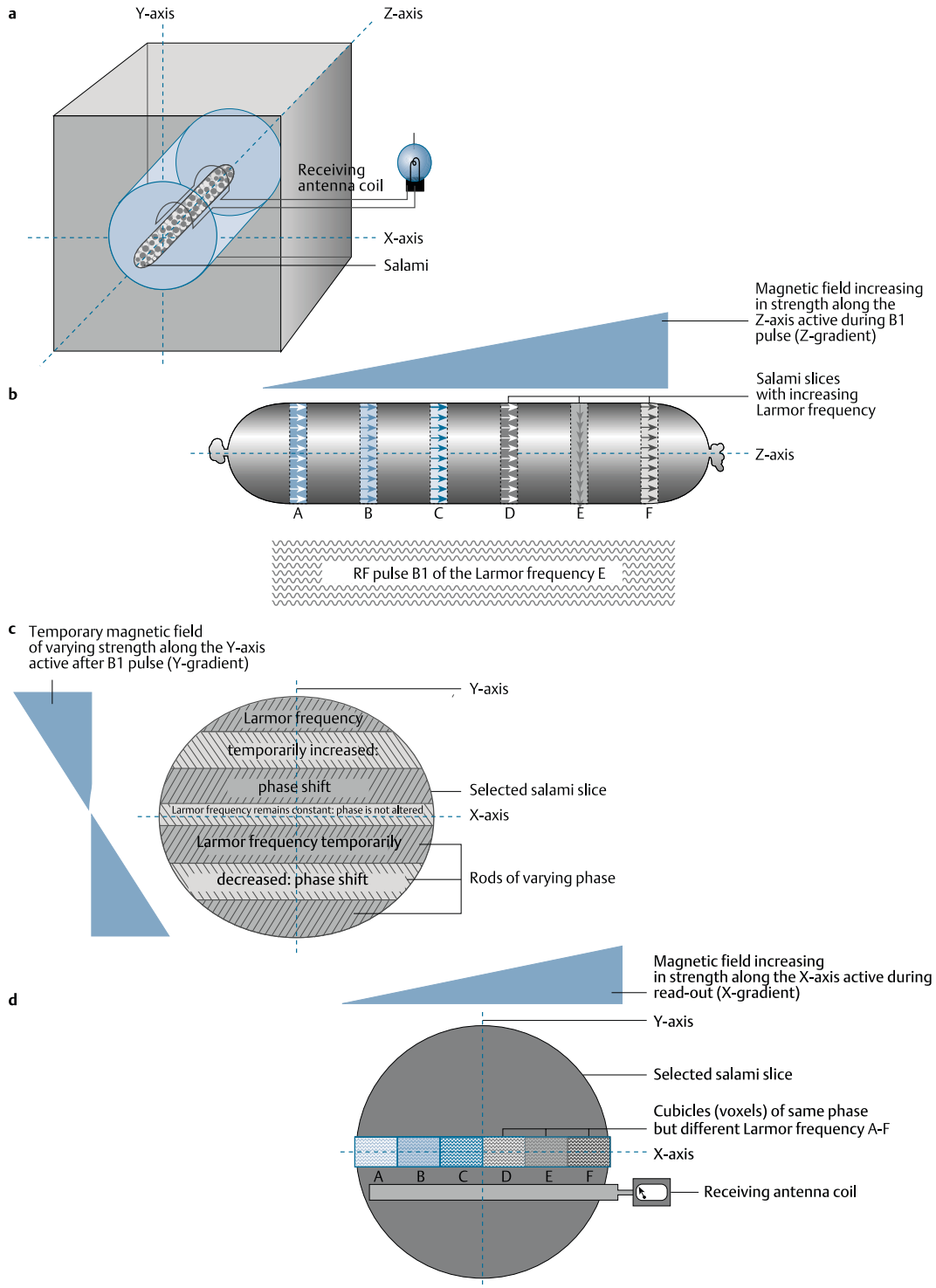
### Do You Know about the Larmor Frequency?

Anyone who has sat on a swing moving legs and trunk in slow rhythm to swing ever higher, or who was the “swing pusher on duty” for a little sister or brother, daughter, or son, realizes that objects have a certain inherent frequency at which they swing (or resonate): their **resonance frequency**. If you do not know or feel this frequency or are not able to move your body accordingly (like a small child), you will never be able to swing on your own. If you are,

however, able to apply the frequency appropriately, you will go a long way with very little force. The same holds true for atoms and molecules, of course.

The nuclei of atoms spin about their axes with high frequency and some nuclei (such the hydrogen nucleus—the proton) have resultant magnetic moments. We are actually looking at small rapidly spinning “magnets.” As the atoms move randomly, these “magnets” tumble about chaotically and thus neutralize each other’s magnetic fields. A call to order is necessary before anything good can come out of this.

**Magnetic Resonance Tomography**



You probably remember this physics experiment from back in school: iron dust arranges itself along the lines of a magnetic field. In MR a constant external magnetic field (called  $B_0$  by the MR physicists) calls the little nuclear “magnets” to order. The protons align themselves along the axis of the magnetic field and, in addition to their spin, begin to rotate around the axis of the  $B_0$  magnetic field much like gyroscopes wobble in the Earth’s gravitational field.

! This rotational frequency is identical to the resonance frequency, which is also named the **Larmor frequency**. This frequency varies with the strength of the magnetic field.



### The Irishman Whose Frequency We Cannot Do Without

Sir Joseph Larmor was an Irish physicist who taught in Cambridge, England, around the beginning of the last century. One of his special fields was the mathematical theory of electromagnetism. The Larmor frequency is just one of several physical phenomena

that carry his name. He was a conservative man, at times opposing most of Einstein’s ideas and the introduction of baths in his college in Cambridge: “We have done without them for 400 years, why begin now?” As it turns out, he became an avid bather right after the public baths were installed.

## What Is So Special about the “External” and “Internal” Magnetic Fields?

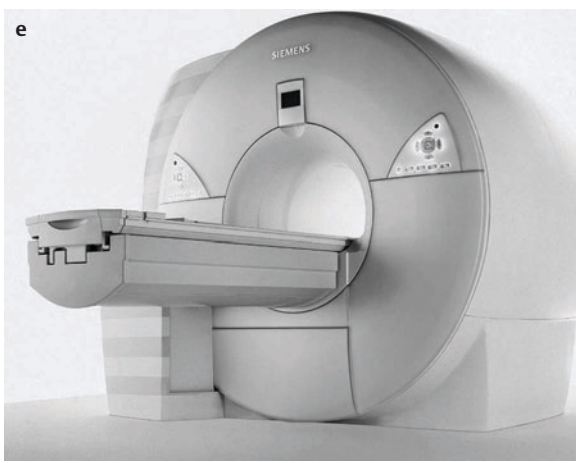The magnets for the external applied magnetic field ( $B_0$ ) are large and incredibly strong (0.5, 1.0, or 1.5 tesla, the last corresponding to 30 000 times the force of the natural terrestrial magnetic field). Why do we need such a strong field? Our protons do align themselves along the field axis and wait patiently for coming sensations—they may, however, choose a parallel and an antiparallel orientation. This is where the simple magnet story comes to an end. The parallel orientation is the least energy-consuming, which is why more than half of the protons choose it. The other protons assume the antiparallel orientation. As the external magnetic field increases in power, the antiparallel orientation requires ever more energy and thus becomes less and less popular. The dominance of the parallel protons increases and thereby the magnetization of the examined body. This “internal” magnetic field initially has the same orientation as the external field  $B_0$ . Its axis corresponds to the longitudinal axis of the MR gantry, also called the Z-axis (Fig. 3.6a). Now the stage is set: Enter a biological sample to examine—how about a nice salami?

## How Do We Generate an MR Signal in a Salami?

It so happens that protons (i.e., nuclei of hydrogen atoms)—which can be beautifully studied by MR—are abundant in salamis and other organic material: in excess of 90% of organic material consists of hydrogen. After having been moved into the  $B_0$  external magnetic field of the MR system the majority of protons inside the sausage have aligned themselves parallel to  $B_0$  and have generated an “internal” magnetic field. If we now want them to tell all, we’d better get them excited. This is done by a **radio-frequency pulse** (RF pulse), a temporary outer RF magnetic field that oscillates with the Larmor frequency of hydrogen (also called  $B_1$  by MR physicists). Remember: Hydrogen protons could not care less about RF pulses of higher or lower frequencies. The longer the  $B_1$  RF pulse is active and the stronger it is, the more the axis of the protons is tilted away from the Z-axis into the X–Y-plane. For simplicity’s sake, let us consider a pulse that has the power and duration to tilt the proton axis by  $90^\circ$ . As this happens not only to one proton but synchronously to many protons in the salami, the “internal” magnetic field also tilts  $90^\circ$  and rotates with the Larmor frequency of hydrogen, much like a propeller—or *the magnet inside the bicycle dynamo* (in the X–Y plane; Fig. 3.6a). If you now position a wire coil along the sausage (corresponding to the receive coil or antenna of the MR machine), a measurable alternating current is induced—much like in the coils of a bicycle dynamo.

◀ Fig. 3.6

**a** The coordinate system with three axes Z, X, and Y inside the MR machine is shown. Inside of the gantry you can see the salami and the antenna alongside it in which the MR signal is induced. **b** If a gradient is superimposed on the static field along the Z-axis (Z-gradient), every slice of the salami gets its own “Larmor frequency address.” An excitation pulse  $B_1$  of a frequency  $E$  will now only excite slice E. **c** Right after the  $B_1$  excitation of slice E, a temporary gradient is superimposed along the Y-axis (Y-gradient). As protons within the slice now rotate with different Larmor frequencies, the signals dephase except in the rod that keeps the original frequency. The phase shift persists until read-out. **d** During read-out, a third gradient is superimposed along the X-axis (X-gradient). Each cube in the rod now has its own “Larmor frequency address.” The measured signal of that specific frequency can now be assigned to a specific voxel in the image. **e** This is a modern whole-body MRI scanner (by Siemens Medical Systems). ▼





This current is the MR signal we can start our work with. Remember for later that the field signal is strongest if all protons are in phase (“listen to the same beat”) which is always the case right after the B1 pulse.

After the RF pulse B1 and the resulting 90° tilt of the “internal” magnetic field, the current measured by the antenna—our signal—decreases again. The reasons are twofold: For one thing, the axis of the “internal” magnetic field moves back to the Z-axis—remember that the “external” magnetic field B0 is always present and is very strong. For another thing, the protons lose the phase synchronization they have been forced into by the RF pulse B1. As they dephase, the “internal” magnetic field power also shrinks. You will learn more about these processes later.

We now have proof that there are protons inside that salami; of course we had a hunch there would be. To look at slices of the sausage we have to assign the signals to locations in a three-dimensional coordinate system.

### Spatial Allocation of the MR signal

The frequency with which I swing or push my swinging child depends, besides other things, on the terrestrial gravity. The Larmor frequency with which I can excite a proton depends on the strength of the magnetic field surrounding it. Magnetic fields can be built asymmetrically so that their strength increases along an axis. These types of fields are called gradients.

**Z-gradient:** If such a gradient is positioned along the longitudinal or Z-axis of the system (Z-gradient) (Fig. 3.6a) the magnetic field increases along the length of the salami, giving every slice of the sausage a different Larmor frequency address. If we now give the B1 pulse, it excites not the whole salami but only one slice—the one with the Larmor frequency of the B1 pulse (Fig. 3.6b). The bandwidth and form of the B1 pulse determine the thickness of the selected slice.

**Y-gradient:** After the excitation B1 pulse is over, a second gradient is positioned along the Y-axis of the system (Y-gradient). During the duration of this gradient the protons thus have different Larmor frequencies depending on their position along the Y-axis; that is, they rotate with different speeds. The subsequent phase shift persists after the Y-gradient is turned off again. The sausage slice now consists of rods of different phase (Fig. 3.6c). Here is the analogy to illustrate the phenomenon: If three different cars drive on a three-lane highway and adhere to a speed limit, they stay side by side. Once the speed limit is lifted, they drive with different speeds and the gap between them grows. As the speed limit is enforced again, they drive at the same speed (same Larmor frequency for the protons) and the gap between them (the phase shift) persists. This applies to law-abiding drivers only, of course. The gradient can be designed to leave the Larmor frequency unchanged in one rod that subsequently does not undergo the phase shift. Frequency and phase are thus identical to the original B1 pulse. We will now dice this rod into volume elements (voxels).

**X-gradient:** The last gradient is switched on during the read-out phase and is positioned along the X-axis (X-gradient). It divides the rod into cubes, assigning a Larmor frequency address to each (Fig. 3.6d).

Now we have the single cubes (or voxels) that we need for a two-dimensional image: a selectively excited slice of a defined thickness, and a rod in correct phase that is subdivided into cubes of different Larmor frequencies assignable to locations in a coordinate system. To calculate the image, a separate measurement must be performed for every rod (voxel or pixel row) of the image matrix; that is, for a matrix of 256 × 256 voxels, we need to repeat the process 256 times. The rest is complex electrical engineering.

## Analysis of the MR Signal

### Which Phenomena Do We Need to Know?

As has been described above, the MR signal measurable directly after the RF pulse decays quickly. This is due to two phenomena that can be quantified separately:

- **Longitudinal relaxation:** This is the process of the “internal” magnetic field returning to the original orientation (Z-axis) along the “external” magnetic field B0. This is a pretty fast process. The corresponding parameter is the **T1 value**.
- **Transversal relaxation:** This is the process of signal loss due to dephasing of the protons. Starting with the same rotational frequency and phase right after the B1 pulse, different protons in different locations are influenced by the magnetic forces of their neighboring atoms and the general inhomogeneity of the field and thus lose their synchronization (they “lose their common beat”). Another analogy to illustrate the phenomenon: Imagine a string orchestra fiddling away at a musical score. It is a special orchestra—the musicians hear only their own music and see nobody but the conductor. It is the conductor who gives the sign to start (B1 pulse). If he were to leave right after the beginning, the individual musicians could continue to play their score but the orchestra’s music would quickly turn disharmonic—or *dephase*. As the protons dephase, the power of the rotating “internal” magnetic field decreases. This process takes time; it is called transversal relaxation and is described by the **T2 value**.

Because the T2 value tells us about the environment of the protons it is a very important parameter. You can imagine that T2 can tell us a lot about the structure of tissues.

### Just How Do We Measure the T1 and T2 Values?

If some time after the excitation pulse B1 we apply an additional 180° RF pulse, we can turn the axis of the rotating protons around and let them rotate backwards to produce a signal echo. Here is the last analogy: If several cars of different maximum speed drive away from the start with top speed, gaps between them will appear and grow over time.

If they all get a radio order to return as fast as possible, they will reach the spot they started from all at the same time. It is the same with our rotating protons: after the 180° pulse the signal increases again, climaxing in an echo (spin-echo) of the original signal. The influence of constant magnetic inhomogeneities that may be due to the external magnetic field is fortunately subtracted in this process.

! The difference in signal strength between the original signal and its echo tells us something about (a) the re-orientation of the internal magnetic field into the Z-axis (T1; longitudinal relaxation) and (b) the local randomly distributed magnetic field inhomogeneities that cannot be compensated by the 180° pulse (T2; transversal relaxation).

If you want a T1-weighted image, you put the 180° pulse right after the primary signal. As the longitudinal relaxation is fast, the loss of signal then represents T1. If you want a T2-weighted image, you wait a long time before you give the 180° pulse to give the dephasing (transversal relaxation) time to occur. The loss of signal then represents T2.

T1 and T2 values of water, fat, muscle, and liver are quite different to each other. This is the reason for the superb soft tissue contrast in MR imaging. If the excited hydrogen atoms leave the excited slice before read-out (such as happens in flowing blood), there is no signal to measure, which is why in most MR images the vessels are black. If there are only few hydrogen atoms (e.g., in bone cortex or in tendons), the signal remains low. A variety of MR contrast media can change the T1 and T2 values. The most popular ingredient is gadolinium.

! On T1-weighted images fluid (e.g., spinal fluid, urine) is dark, while on T2-weighted images it is bright. Bone cortex gives no MR signal—it is always black.

### 3.5 Our Perception

The outcome of an imaging study (or an intervention) does not rely only on the indication or the quality of its technical execution. The diagnostic radiologist with all his or her knowledge and experience is the last link in the diagnostic chain. The radiologist searches for relevant image information, perceives, sorts, and evaluates it, and finally comes to a (hopefully sound) diagnosis. Search, detection, and preliminary evaluation are the dominant components of perception.

! Without intact and optimized perception of the diagnostician, every imaging study, sophisticated as the technology may be, is a waste of time and money. It also increases the patient's risks.

#### What Do We See Best?

In diagnostic images such as mammograms, incredibly small and low-contrast structures such as microcalcifications have to be appreciated.

! A structure is perceived best if it is viewed at a distance at which it subtends an angle of 5° (Fig. 3.7a).

We implement this physiological truth in our daily work by getting closer to an image if we look for very small details—until we hit the limits of accommodation. Accommodation is, of course, phenomenal in children (if they show you a piece of paper to read, they will hold it close to your nose). Radiologists of adequate biological age, however, need to carry a magnifying glass around to compensate for their accommodation deficit. It is interesting to note that the phenomenon also works the other way around: large, low-contrast lesions are better perceived if you view them with a minifying glass. The number of radiologists carrying these around is much smaller, however. The normal crowd just takes a step back and then another look.

How well we view small structures also depends on the brightness, or optical density as the physicists call it. As typical animals of the steppe we see contrasts best at the brightness of a summer afternoon. At this optical density our optical cones work optimally while the intraocular scatter is minimal. If it becomes darker, we turn to rod vision. The detectability decreases significantly, which is why you have a reading lamp at your bedside.

The windows of a typical ward room are only usable as “light boxes” if main rounds take place on a summer afternoon and if clear skies dominate in the region—thus in hospitals for the upper few. Late in the evening, however, a broader public can also check the healing progress while standing in the parking lot.

As our eye adapts to the brightness of the total visual field, an image on the light box should be very well masked if you do not want to miss low-contrast lesions. Room (ambient) light must also be adapted to prevent reflections on the image, and the dilation of the pupils, which would increase intraocular scatter and activation of rod vision.

The proper examination of an image that has been generated with great care is thus far from trivial (Fig. 3.7b). Special computer-assisted light boxes or viewing monitors that also control room light optimize our perception (Fig. 3.7c).

## Perception

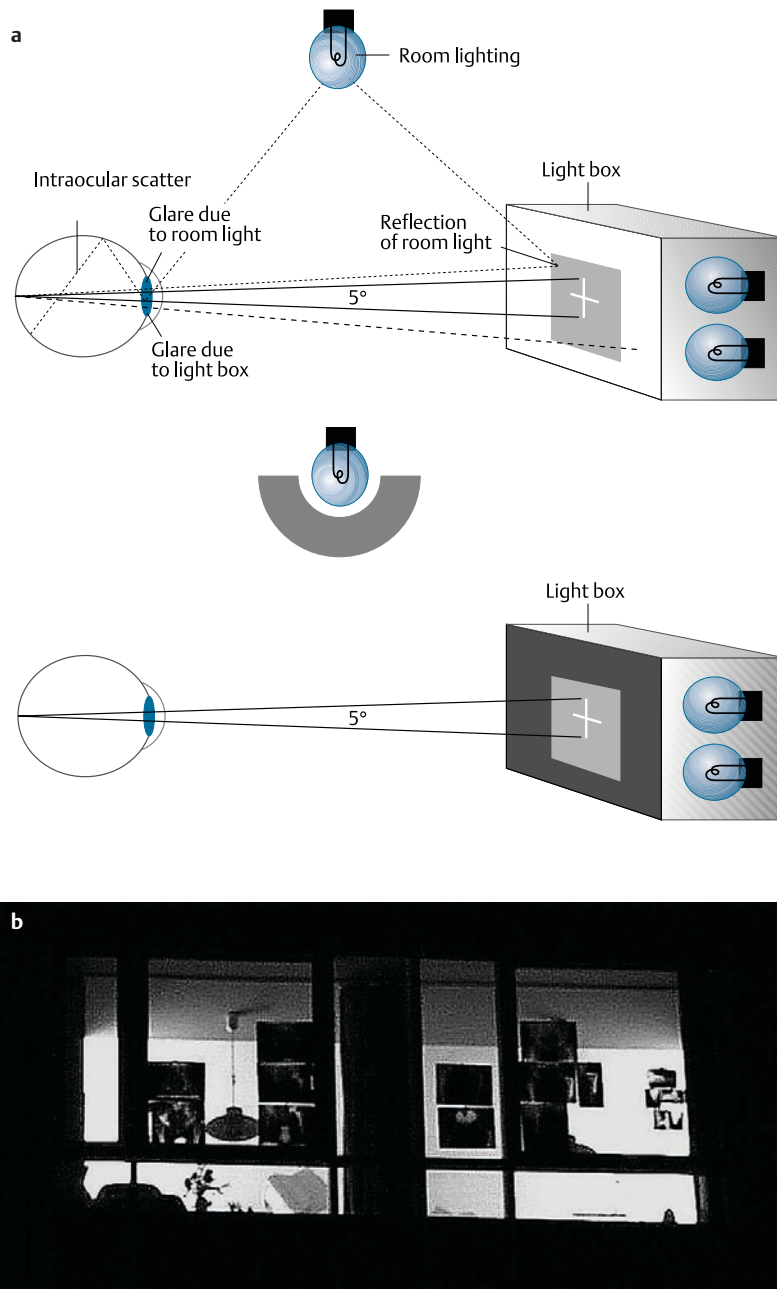


Fig. 3.7

**a** Glare and reflections in the visual field, intraocular scatter, and insufficient masking of the image on the light box are reasons for impaired perception (upper). If these mistakes are corrected and if structures are viewed so that they subtend an angle of  $5^\circ$  perception is optimal (lower). **b** Chief's round on the surgical ward. The films were fixed to the windows. Obviously rounds have to take place before sundown on this ward. Nice to know also that the therapeutic progress can be checked another time late at night while walking over to the parking lot. **c** This is a computer-assisted lightbox that masks the film and adapts ambient light automatically, thus optimizing perception (by Smartlight, Inc.). **d** This is a modern flat panel display used in digital mammography. In this special field the quality requirements are extremely high. The display also needs to be placed in dedicated, light-adjusted surroundings (by Fuji Medical Systems). ▶

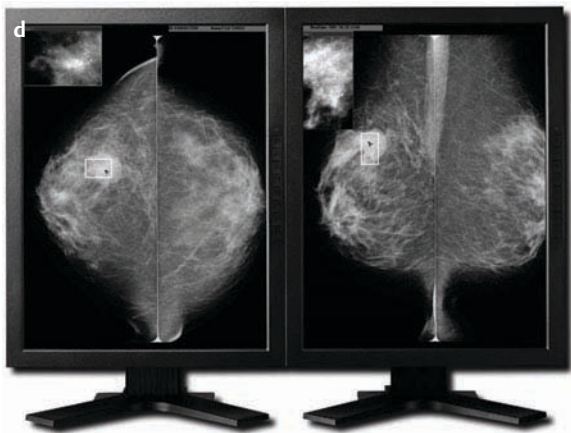
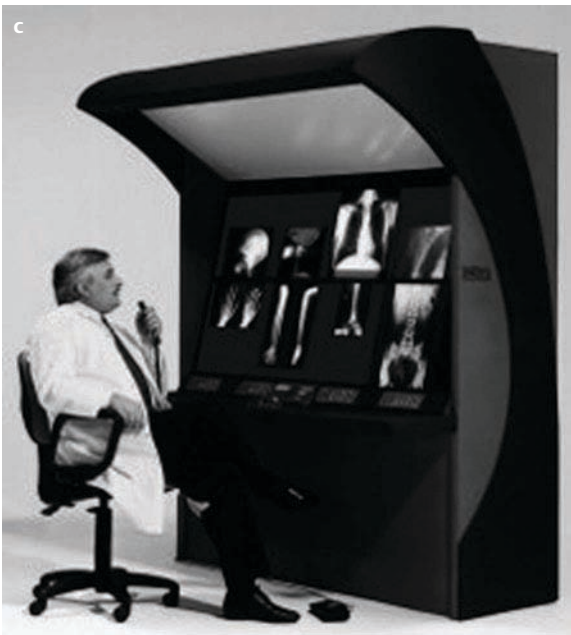## What Else Influences Our Perception?

Even if a structure is optically well discernible it must also be perceived and, eventually, be evaluated and classified. Is the structure pathological, normal, or just a variant of the normal? The image is scanned optically and compared to an internalized standard, the “gestalt” of, for example, a chest radiograph. The more complex the normal image, i.e., the radiological anatomy, the more difficult is the detection of pathology. A given nodule is readily perceived in the periphery of the lung but is easily missed when it is close to the lung hilum, because the large vessels can look like or camouflage the nodule. The negative influence of complex anatomy on the detectability of pathology is also called “**anatomical noise**” (see p. 21).


After you have detected a definitely pathological structure, your attention may fade, especially if you are still inexperienced. This “**satisfaction of search**” effect (see p. 25) hinders the careful examination of the rest of the image. Make it a point to take the time for a second thorough pass over the image!

The independent review of an examination by another colleague (“**double reading**”) can increase its diagnostic value significantly (see p. 32)—four eyes do see more than two!

**!** Images are generated with extremely expensive and sophisticated equipment, sometimes with substantial risk to the patient. They must be studied with great care and under optimal conditions.



# 4 Phenomena in Imaging and Perception



The knowledge of some basic procedures and rules of projectional and sectional imaging is essential for the understanding of the creation of a given medical image. Other phenomena are very helpful in the interpretation of such radiological images. Some of them can be applied to every aspect of imaging, others are crucial only for subspecialties in radiology. What holds true in real life is also true here: If you know the basics and a bunch of little tricks on top of that, your fame will spread quickly.

## 4.1 What Do I Need to Know for Image Analysis?

### Is the Quality of the Study Technically Adequate?

#### Checklist: Determining Study Quality

- Has the best method/modality been chosen in the given clinical context?
- Have the right body parts been imaged and completely so?
- Was the study performed properly or was imaging compromised owing to the patient's state or the situation during the examination?

Every experienced radiologist first eyes the “quality of the study” before starting a thorough image analysis. The objective of a first technical check is not to discard the study or ignore a finding (although this is also necessary in a few cases) but to establish a sound basis for the perception and decision-making process. This is a precious habit that you should also stick to. Obviously first and foremost one must assure that the images at hand indeed belong to the patient in question.

To determine the **quality of a study** we ask the following questions:

- Was the right kind of diagnostic or interventional method selected considering the clinical indication at hand? The indication lists in this book will give you an orientation on what studies are done for what problem based on science and clinical experience.
- Was the right body region imaged and is it completely represented? This is a crucial question. As an example, check Figure 4.1a–c for confirmatory evidence. In addition, for example, a true second projection is an absolute must in skeletal radiography (Fig. 4.2).

- Was the study performed properly or was imaging compromised owing to the patient's state or the situation during the examination? This includes not only study technique (e.g., exposure voltage; the use of a scatter grid in projection radiography; choice of window and filter settings in CT or frequency and probe type in ultrasonography; adequate selection of coil, sequence, and projection in MR imaging [MRI]), but also positioning (Did the patient stand upright?) and the degree of cooperation of the patient (Could the patient keep still [Fig. 4.3]? Did he hold his breath? Did he inhale deeply?). Having finished reading this book you should be able to answer the first two questions in 95% of all cases. If the study is of satisfactory quality, you're on your way to the correct diagnosis.

### How Do I Analyze an Image?

If you track the eye movements of an experienced radiologist, you will find that they appear to be rather unsystematic or even chaotic. Their perception of findings actually takes place in the sub-second range. The neophyte, however, has to adhere to a rigid sequence to accommodate the need for longer average observation time, which conflicts with the individual's momentary attention span. You will find suggestions for such sequences in the individual chapters.

### Tissue Characteristics on Radiographic Images

Speaking in terms of characteristic density on plain radiography, the human body consists of different basic components, specifically fat, water, soft tissue, and bone. These four basic densities are recognizable when a structure contains an overwhelming amount of one particular kind of tissue. Obviously that is not always the case, and, to make matters worse, since conventional radiographs are projectional images we often look at a composite shadow made up of the density of several characteristic tissues. Some additional components such as calcifications or metal are introduced by disease or by external events. Body functions can also be observed with imaging modalities; for example, the flow in blood vessels or the cerebrospinal fluid spaces or the uptake of contrast media into a specific types of tissue.

Every imaging modality has its specific characteristics, strengths, and weaknesses with respect to the depiction of these components and functions. Some modalities



### Attention, This Is Your Wake-up Call!

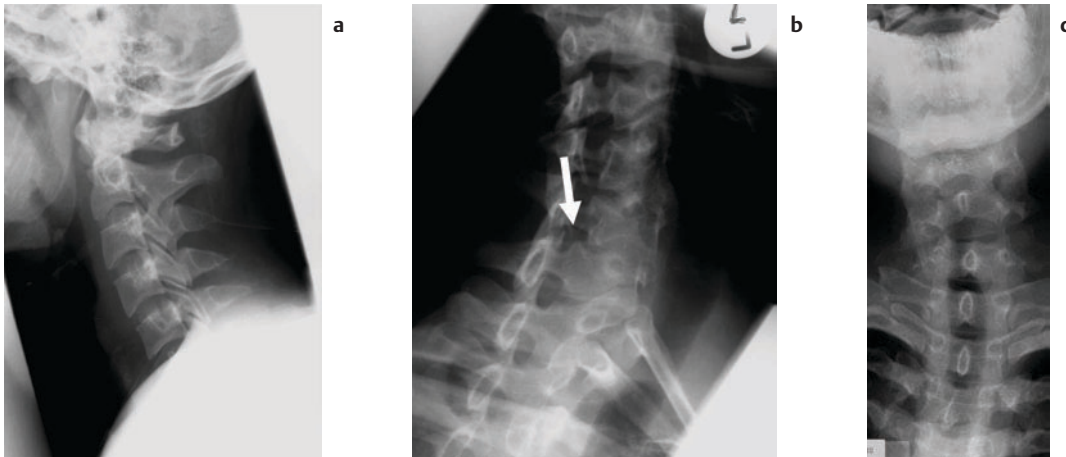


Fig. 4.1 **a** Have a good look at the lateral cervical spine of this patient who fell off his bicycle. Can the stiff neck collar be taken off safely?

**b** The additional oblique view (two sturdy trauma surgeons

pulled the shoulders caudally) shows the dislocation of C6 with respect to C7 (arrow). **c** The anterior–posterior radiograph proves the distortion in the C6/7 segment. Had the collar been taken off without further stabilization, a spinal cord contusion could have resulted.

### Diagnosis at Second Glance

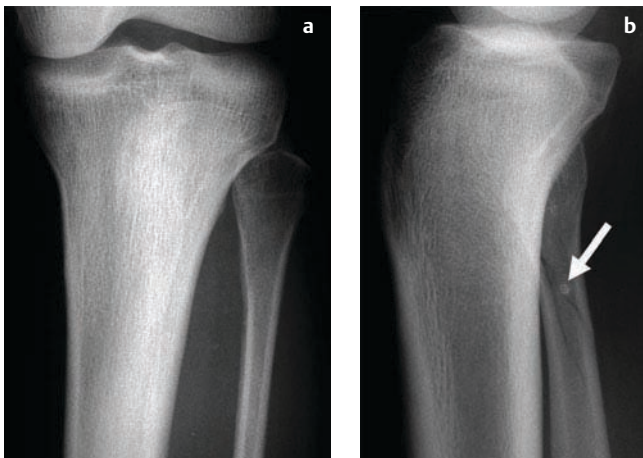


Fig. 4.2 **a** The anterior–posterior radiograph shows no obvious abnormality.

**b** Only the lateral projection demonstrates the fibular fracture (arrow).

### No, Doctor

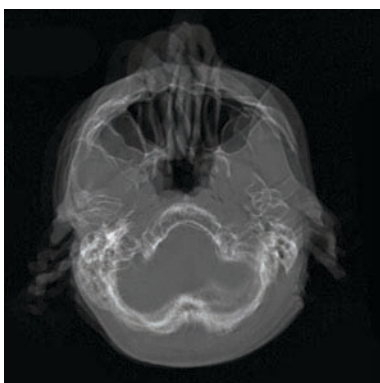
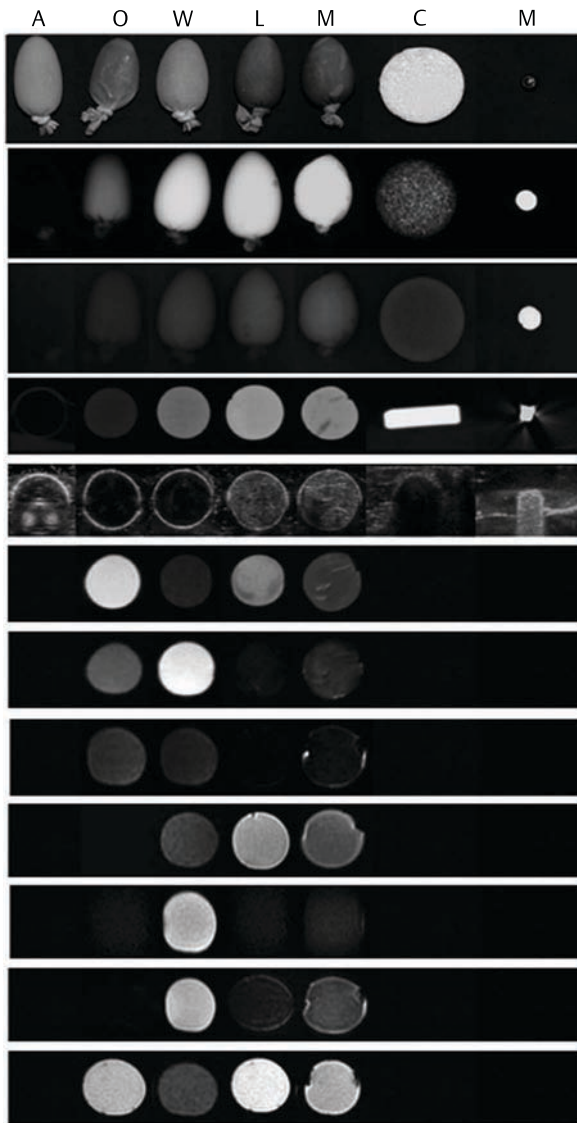


Fig. 4.3 After having been asked whether he could please hold still for just one more scan, this patient only shook his head. Not everything is possible.

What Looks How with What Modality?

a Imaging of body components

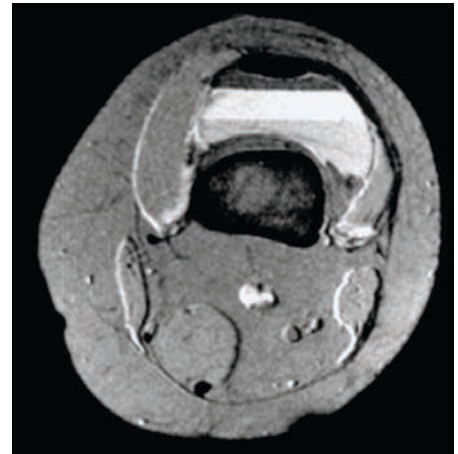

A: air; O: oil; W: water; L: liver; M: muscle; C: calcium; M: metal

Fig. 4.4a Here you see the most important body components as they are depicted by the different imaging modalities. The samples are surrounded by air. Gas, fluids, and tissues are contained in rubber glove fingers. For the ultrasound, the samples were dipped in freshly drawn tap water—the little bubbles are caused by gas in that water. The calcium tablet, of course, could not be dropped into water without dissolving immediately and producing gas, so my own (G.W.E.) radius had to take its place. By the way, which metal did we choose? Copper, lead, or iron? And why?

Of course it is lead. Copper would have been penetrated much better at 100 kV; iron would have flown right into the gantry of the MR machine and would have damaged the system (and what's worse, our department's slush fund).

b Test yourself!



b You see a part of a study of a patient who has suffered an injury. Try to classify the study as precisely as possible and then come up with the clinical diagnosis. Use Fig. 4.4a, a little anatomy, and your gray matter in the process.

This is an axial sectional study of the knee just cranial to the patella. You can see the complete contour of the limb—an ultrasound is thus impossible. The bony cortex and the tendons are black—that proves it is an MR image. The cancellous bone and the subcutaneous fat are comparatively dark—fat saturation would explain that. Three layers within the suprapatellar bursa are appreciated with two fluid–fluid interfaces. The middle layer is bright—compatible with serous joint fluid on T2-weighted images. The lower, dependent, layer has an intermediate signal that would go well with blood. The top layer with low signal is fat again—remember the fat saturation. The whole picture is diagnostic of a joint-involving fracture of the knee, most likely a tibial head fracture. The fat is released into the joint from the bone marrow by way of the fracture line. G.W.E. likes to call this the “Dutch flag” sign.

### “Anatomical Noise”

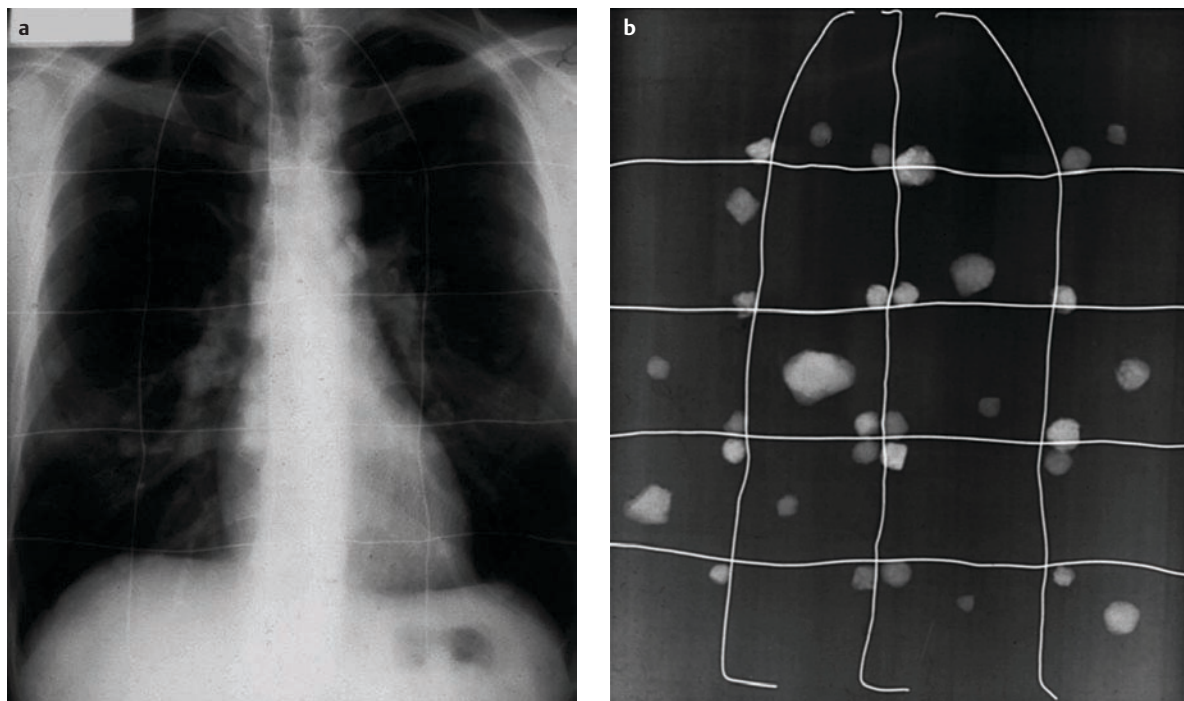


Fig. 4.5 **a** Analyze the chest radiograph of this volunteer, who has an arrangement of wax spheres fixed to his back: large spheres are overlooked in the hilar region. **b** Compare the radiograph of the wax spheres alone: How many did you miss?

may have excellent spatial resolution (such as high-frequency ultrasound) but poor tissue depth penetration. Some have good spatial resolution (the ability to discern two small objects/points in space) but inferior soft tissue contrast resolution (the ability to discern two different types of soft tissue, such as gray and white matter of the brain). Such an example is the choice between CT of the brain versus MRI. In addition there are, in the individual modalities, special ways to enhance one aspect or another. For the beginner it is difficult—if not impossible—to get a comprehensive overview. Figure 4.4a is intended to help you a little. It shows the relevant components and how they are depicted by the pertinent imaging modalities. Figure 4.4b puts your new knowledge to the test. Please keep in mind that in projection radiography it is not only the density (Fig. 4.4) but also the thickness of an exposed object that determines the signal intensity (that is, the radiation attenuation in this case).

### What Is a Normal, What Is a Pathological Finding?

The objective of imaging is the detection and localization of relevant disease or the exclusion of significant findings. What we consider to be pathological depends a great deal on the patient, on the societal context, and sometimes even on the immediate political or socioeconomic situation (a period of clinical depression following a catastro-

phe like 11 September 2001 in New York may be considered a normal reaction rather than disease). Calcifications in the wall of the abdominal aorta or a vertebral disk herniation without symptoms are not pathological in a 90-year-old unless their shape suggests a large aneurysm but would certainly lead to additional diagnostic work-up and possibly therapy in a young adult. Incidental findings like a closure defect of the vertebral arch of S1, a pulmonary azygos vein lobe, or a circumaortic renal vein are anatomical variants that have no relevance at all except under extraordinary circumstances: for instance, when surgery to the region is planned, e.g., laparoscopic resection of a left kidney from a healthy living donor.

As has been mentioned in the previous chapter, the normal anatomy can be so confusing that detection, localization, and classification of findings can be extremely difficult. The vascular tree of the lung, for example, with its intertwined veins and pulmonary and bronchial arteries, is so complicated that large nodules can be completely concealed (Fig. 4.5). This interference of the normal anatomy with the detection of pathological findings is also called “**anatomical noise**” (analogous to the bothersome noise you hear in your Dad’s old stereo system).

### Where is the Pathology?

To assign a lesion to a certain location we need **three dimensions**, just like in stereoscopic viewing. In sectional



## Let Me Have Another Slice!?

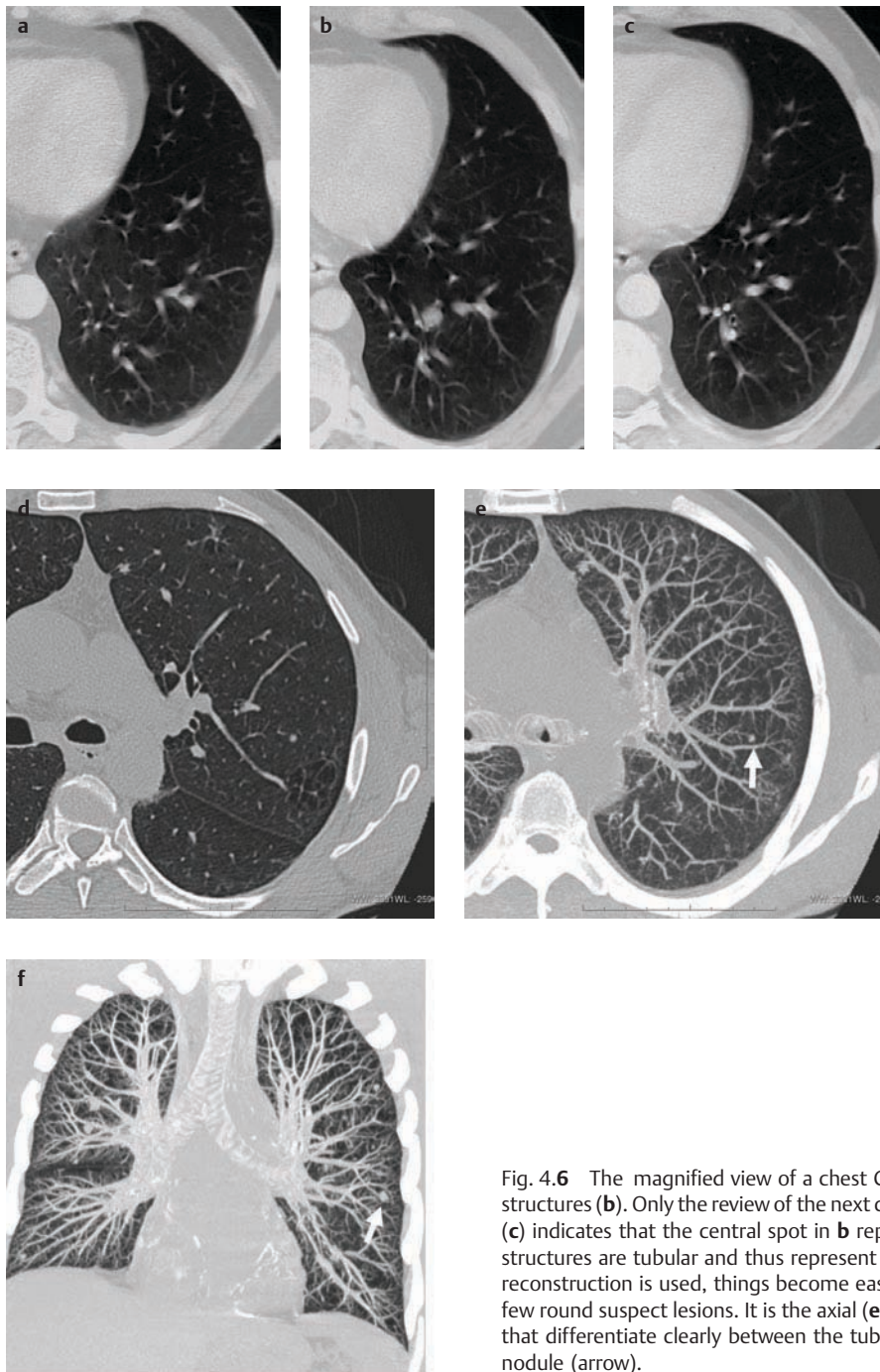


Fig. 4.6 The magnified view of a chest CT shows a number of little round structures (b). Only the review of the next cranial (a) and the next caudal slice (c) indicates that the central spot in b represents a nodule while the other structures are tubular and thus represent pulmonary vessels. If a thick slab reconstruction is used, things become easier: In d a single CT slice shows a few round suspect lesions. It is the axial (e) and the horizontal (f) thick slabs that differentiate clearly between the tubular vessels and the metastatic nodule (arrow).

imaging it is the *neighboring slices*, reconstructions or so-called *thick slab reconstructions*, that convey the third dimension. Interactive review of thin CT images on an electronic viewing system such as a workstation or PACS system is becoming increasingly popular; scrolling through stacks of contiguous images allows the interpreting radiologist to form a 3D impression in his or her head. Looking at the third dimension and the neighborhood is the only way to differentiate between a sphere (such as a lung no-

dule) and a cylinder (such as a vessel section in a chest CT) (Fig. 4.6). In projection radiography, especially of the skeleton, it is the obligatory second oblique or perpendicular projection that gives us this information in conjunction with the initial radiograph (Fig. 4.7)—if we see the abnormality on the other projections, which is by no means always the case. However, a simple single projection performed with a sagittal x-ray beam can also give us hints as to the localization of a lesion. We use this information

### A Valid Second Point of View

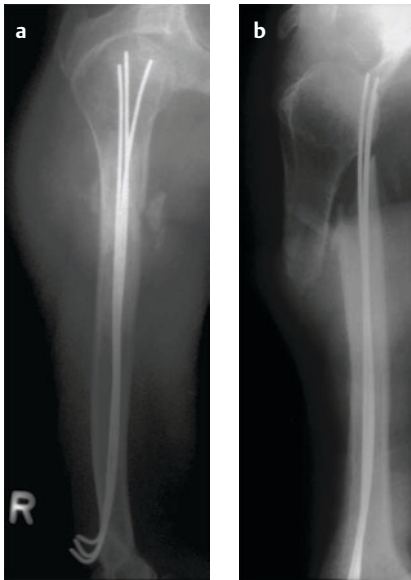


Fig. 4.7 **a** What you see is a fracture of the humerus that has been stabilized with a number of rush pins. Looking at this projection, all looks well. **b** The second projection brings a rude awakening: The rush pins lie outside of the proximal fracture fragment.

whenever a second projection is not present or does not clearly show the lesion in question.

Radiographically perceptible interfaces exist between tissues whenever their density (or signal strength) in the given imaging modality is different enough to be detected by the imaging system used (contrast resolution, see above). This is of special importance in projection radiography. The kidney contour and the border of the iliopsoas muscle, for example, are appreciated well in abdominal films because these soft tissue density structures (of kidney or muscle) are surrounded by retroperitoneal fat of much lower density (Fig. 4.8). If such an interface is lost or its continuity is altered, a pathological process in this region must be suspected. In the kidney the phenomenon could point to a renal carcinoma that has broken through the renal capsule; in the case of the iliopsoas muscle, retroperitoneal fibrosis or a large psoas abscess could result in the loss of its contour. When taking a closer look at the analysis of chest radiographs we will make extensive use of this phenomenon (also called “silhouette sign”).

**Exposure geometry** also influences the image appearance and can help us to assign a finding to a specific location. For the naked eye of an observer, far objects result in a small projection and close objects in a large projection on our retina. In projection radiography it is just the other way around: looking at a radiograph we actually see through the patient at a point source of radiation, the focus. Whatever is closer to the focus, i.e., farther away from the detector, projects larger on the detector. (It is like looking at your own shadow on a wall—the closer you get to the wall the smaller the shadow gets, and the closer you get to

### Radiologists Just Love Fat!

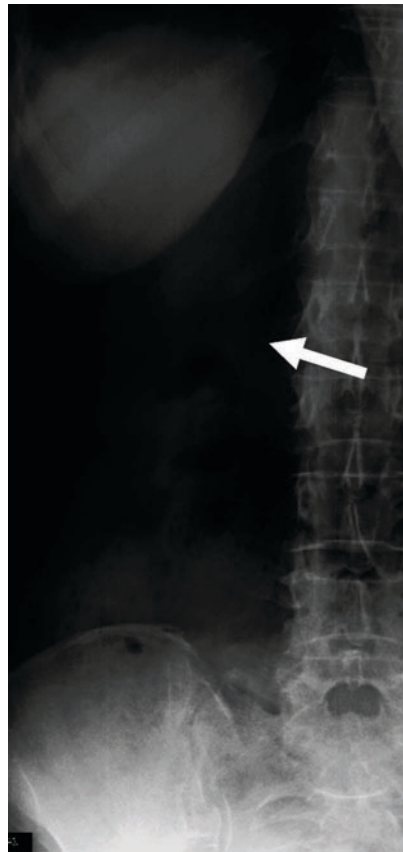


Fig. 4.8 The collimated view of an abdominal radiograph shows the oblique course of the iliopsoas muscle as it extends from the spine into the pelvis, made visible by its interface with the surrounding fat (arrow). The renal contour is also obvious. Sitting on top of the kidney one can, with a little imagination, appreciate the adrenal gland. The patient’s breast is superimposed over it. All these retroperitoneal structures are perceptible owing to their interface with surrounding fat, which is of different radiopacity. The dark, irregular areas represent intestinal air.

### A Sharper Image, Please!

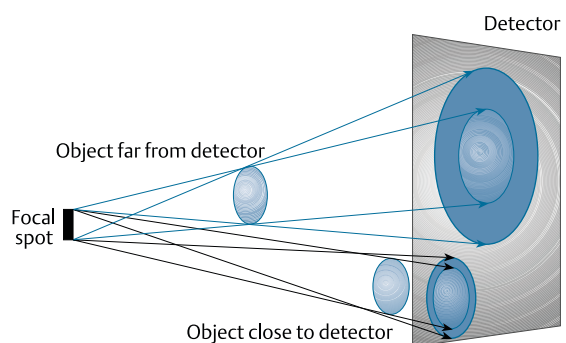
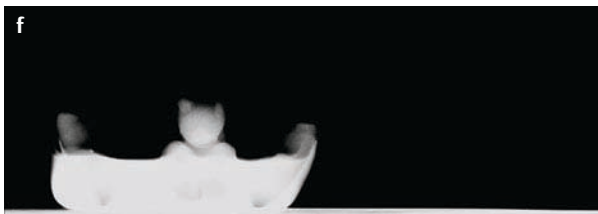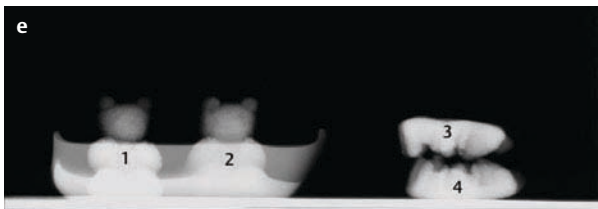
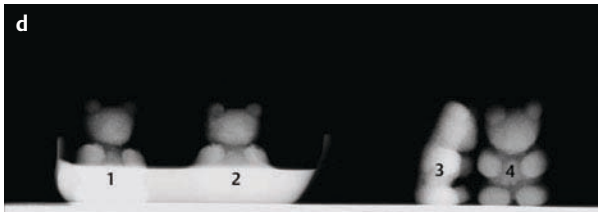
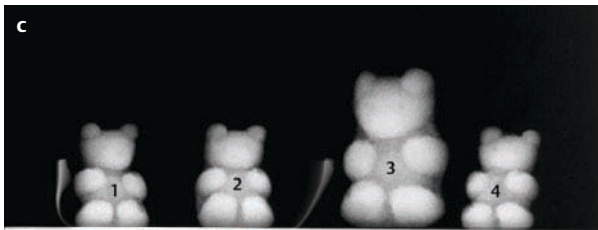
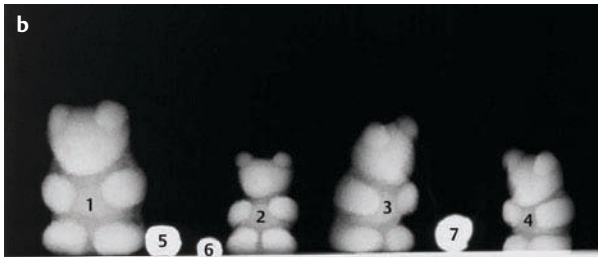


Fig. 4.9 The finite size of the focus causes unsharpness of the object margins that increases with growing distance to the detector.

Gummy Bears to Make You Exercise



**Fig. 4.10 a** A gummy bear made of soft-tissue-equivalent gelatin with a sugar coating. All his colleagues are of the same size and type. **b** Four gummy bears (1–4) play “lead” ball (5–7). Which bears stand close to the detector, which distant from it? Which ball is the smallest? Which ball is the largest?

**c** After the game: The gummy bears have retired into the bathroom. Bears 1 and 2 want to have a bath, bears 3 and 4 are not so sure. Which bear sits in the tub? What does it bathe in? How close to each other are bears 3 and 4? Do they have eye contact?

**d** Ten minutes later: One bear is in the tub. Which? Bear 3 has changed its position.

**e** The evening progresses slowly. Go ahead and analyze the situation. What has happened in the tub?

**f** The party is coming to an end. All bears are sitting in the tub – or has one of them left prematurely and frustrated? And what on earth is the matter with the tub?

No, nobody has left. Two bears are sitting in full harmony in the middle of the tub facing each other (do not try this in your own bathtub)—their densities add up to a higher value than the bears imaged sideways. There is another fluid in the tub now. The bears displace this fluid, showing less density than the surrounding fluid. The fluid must thus have much higher radiation attenuation than whatever these bears are made of. It is iodine contrast medium.

There are two fluids in the tub now. Bear 2 must still be the one in the tub because its contour is still lost in the lower fluid. Its silhouette remains discernible in the upper fluid, though. The density of this fluid must be significantly lower than the gelatin's density. What wondrous fluid could that be? Of course, it is an oil bath for luxurious relaxation: The water remains at the bottom, the oil or liquid fat swims on top. Bear 1 still sits outside the tub in apathy. Bears 3 and 4 now both project laterally; bear 4 is now as bright as bear 3 because they absorb the same amount of radiation.

Bear 2 must be sitting in the tub since its contour or “silhouette” is lost—it displaces the fluid (water), which is of the same approximate density as gelatin. Bear 1 must sit outside of the tub since its shadow is added to the attenuation of the tub's water which it does not displaced—its silhouette remains visible. Bears 3 and 4 have approached each other and discuss the further course of events. Both are close to the detector. Bear 3 stands at a 90° angle to bear 4. In this lateral projection it absorbs more radiation than bear 4 in the anterior–posterior position. The same is true for human beings: a lateral chest radiograph requires triple the dose of standard view! Remember this when you get a chest x-ray yourself or if you order one for a young patient.



### Summation Effect

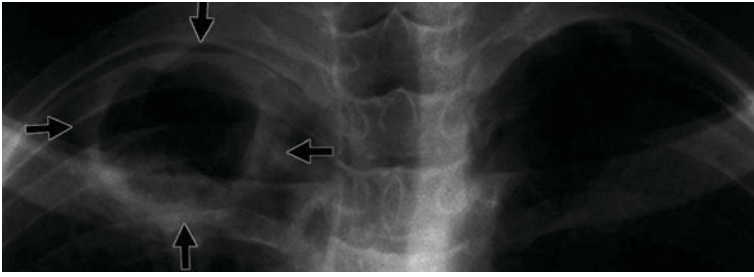


Fig. 4.11 You can see hyperlucent areas in both lung apices. On the patient's right side it is a real finding representing an abscess with thick walls that can be followed around the full perimeter of the lesion. The hyperlucent area on the left is bordered by the first and second ribs, the clavicle, and the spine. This is a typical summation effect—your brain tries to fool you.

the light source the larger the shadow gets). We also have to consider that the focus of the x-rays has a physical size (in plain radiography between 0.1 and 2.0 mm), and that the size predicates the inherent *unsharpness* of the image. The larger the focus or the closer an object is to the focus, the less well defined are the apparent visible margins of structures on the corresponding radiograph (Fig. 4.9). You can go ahead and try out your new abilities by analyzing Figure 4.10b–f. Figure 4.10a shows a gummy bear and all the gummy bears shown have the same physical size.

### What Can Go Wrong in Perception?

The fact that a lesion exists in the body of a patient does not automatically mean that it is visible. And the fact that a lesion is visible does not mean that it is always perceived by the observer. The diagnostic process is not complete, nor is it worth a penny to the patient, until the diagnosis has been communicated in writing or verbally to the responsible clinician in a timely manner and can be acted upon. During the perception of a visible lesion, a number of interesting neurophysiological and cognitive effects come into play that one should be aware of.

Like human faces, radiographic images have a “gestalt” that one can appreciate and remember after very little training. If we see the face of a good friend on the bus, we recognize them at once—we will perceive the new pimple on their face with a glance of the eye. A trained radiologist will also detect the nodule on a chest radiograph at once, in less than a second and thus without systematic search. The standardized way of generating and presenting the image supports this rapid detection. If a friend were lying on their back on the beach and you were passing behind them, you would find it much more difficult to recognize their face with certainty and even more so the pimple of course. It is the unusual orientation or “gestalt” of the otherwise well-known face that poses the problem. The same is true for other representations: Looking at fragments of an image data set (such as in multiple narrow windows of a digital image or by analyzing an image with the magnifying glass only) does not make the overall analysis of an image superfluous. Rather the combination of detailed observation and larger context of the entire image permit proper perception and interpretation. Experience and science make a strong case always

to generate, present, view, and analyze radiological images (such as chest radiographs or mammograms) in a highly standardized fashion.

Sometimes during the analysis of a radiological image we discover lesions that are not real but are conceived by our visual system as such: parts of different anatomical structures are fused into an apparent “lesion,” which is a “**summation effect.**” This effect can make rib crossings

### “Satisfaction of Search” Effect

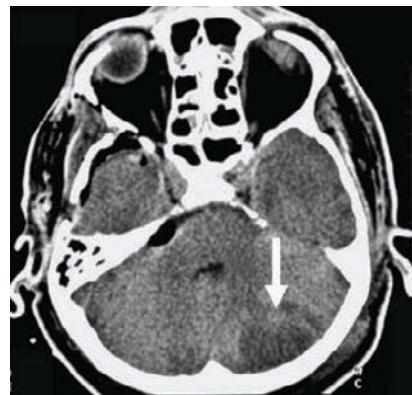
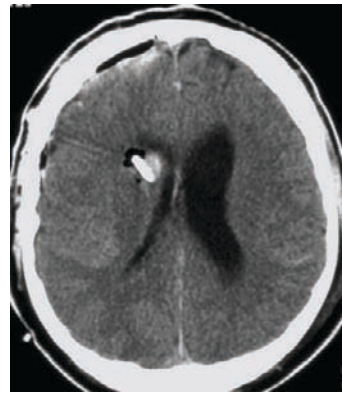
Fig. 4.12 a This CT scan of the head shows a dislocated ventricle drain that led to a hemorrhage in the brain's white matter. The responsible surgeon was present. The finding was discussed animatedly, communicated, and shown to other colleagues. b The additional infarction of the left cerebellar hemisphere (arrow) escaped attention in this setting and was diagnosed in a later review.

appear as “nodules.” The lung apex is another area where the superimposition of first and second rib, the clavicle, and the spine can simulate a pseudolesion—a zone of “overinflation” in this case (Fig. 4.11). If we assume such a phenomenon, we have to trace the contours of the pseudolesion and dissect it into its individual components. But beware not to merely try to explain away all findings; do not automatically call all small apparent nodules in a smoker summation phenomena just because you know about this now—we do have other modalities to ensure that in fact there is no reason to worry. Comparison with previous radiographs, additional imaging, or follow-up examination after a few weeks may help work out what is going on.

Prior knowledge or findings can influence our subsequent analysis and distract us from relevant findings on the image. The discussion continues whether the patient history should be read before or after the initial analysis of the study. We suggest a preliminary analysis of the image without any knowledge about the patient’s symptoms to get an unbiased first impression. Subsequently the patient history is read and the study is analyzed with this information in mind. The physician’s focus on the patient’s complaints is not always an advantage as it can divert from less straightforward findings and incidental diagnoses. The role of patient history and complaints with regard to the interpretation of findings is, of course, undisputed: relevant clinical points must be communicated to the radiologist or the diagnostic process goes awry. The final diagnosis then takes both perspectives into account and ideally consists of a list of differential diagnoses in the order of plausibility and probability.

A particularly tricky phenomenon has already been mentioned in Chapter 3—the “**satisfaction of search**” effect (see p. 17). If the (often inexperienced) observer has managed to find a first relevant lesion, further interest in the image may deteriorate quickly: additional relevant information is overlooked or ignored (Fig. 4.12). So while it is great for the neophyte to make a sound first finding right away, the analysis of a study should be continued with great discipline and care.

## 4.2 Can We Reach a Diagnosis that Approaches Histological Certainty?

If a pathological finding has been detected, it must be classified and the differential diagnoses must be contemplated. Going through the following questions in your mind may help you come up with a more concise list of potential diagnoses.

### Are There Any Volume Changes?

Scars in parenchymal organs and pulmonary atelectasis are associated with volume loss; that is, neighboring

elastic tissues move toward the pathological process. Abscesses, tumors, and metastases act quite differently: they tend to increase in volume and occupy space—they displace neighboring elastic structures.

### What Happens to the Surrounding Anatomy?

Many radiographic findings (alone or in combination) can suggest an aggressive process: If neighboring vessels are invaded, bones are destroyed, fat planes, muscles, and organs are infiltrated. If the lesion has an irregular margin and/or enhances strongly after the administration of contrast, inflammation or malignancy need to be strongly considered. If the body has had time to form a capsule, if there is a sclerotic margin in bone, if a lesion is well circumscribed, a slowly developing, benign process is more likely.

### What Is the Internal Structure Like?

The inner structure and potential contrast enhancement can be homogeneous or inhomogeneous. Fat, fluid, calcifications, ossifications, or even the presence of teeth (i.e., in a teratoma) help to narrow down the differential diagnosis. Fluid–fluid or fluid–gas interfaces in liquid-filled spaces permit conclusions about their constituents (see Fig. 4.4b).

### What Pathology Commonly Occurs in a Particular Anatomical Region?

Every region has a number of typical pathological findings that tend to relate to the local organs or the function of the specific body part. A nice example is the differentiation of space-occupying lesions in the anterior mediastinum—the four great Ts: “**t**hymoma, **t**hyroid, **t**eratoma and ... **t**errible lymphoma.”

Sex, age, and the acute and/or general patient history further narrow down the number of differential diagnoses. At the end of it all one takes a deep breath and calls the list of “surviving” diagnoses. Depending on your individual frame of mind and your sense of suspense and drama, you call the most probable diagnosis first or last. The satisfaction achieved by reaching a relevant, complex diagnosis through crystalline logic, comprehensive knowledge, and good familiarity with the literature is difficult to surpass by any other experience—well, except one, maybe.

**!** Please never forget: Rare things are rare and common things are common.

The sound of horse hoofs in the developed world does tend to indicate the arrival of a horse, not a zebra, although those may be more interesting to look at. More than one “zebra-diagnosis” per week should be highly suspicious, even in teaching hospitals.

## 5 Risks, Risk Minimization, and Prophylactic Measures



Every diagnostic and interventional procedure harbors potential risks to the patient. Risks can be very real and immediate, that is, they can directly harm the patient's health, or they can be indirect, resulting in other risky studies to prove or disprove a preliminary suspicious finding. Counterbalancing the risk of a study is, of course, the potential benefit it brings to the patient: an invasive procedure may yield a comprehensive diagnosis allowing for immediate therapy such as in angiography followed by balloon dilation.

**!** The physician's careful explanation of risks and benefits of a planned study or procedure aims to enable the patient to make an informed decision whether or not to proceed with the study.

The starting point is different for every patient. Because of the radiation dose incurred, computed tomography of the abdomen in a young woman three months pregnant will only be performed in a life-threatening emergency, for example, after severe trauma to the abdomen. In an elderly cancer patient scheduled for radiation therapy, on the other hand, the radiation dose administered during an abdominal CT is without clinical relevance. The cancellation of a study naturally also carries risks: a tumor may go undetected or an inadequate or wrong therapy might be chosen. Thus there are many reasons to take the time for a comprehensive and personal conversation with the patient and to remind yourself of the risks and relevance of your own actions.

**!** In most countries, obtaining signed informed consent of the patient or his/her legal representative (e.g., for children) is an obligatory prerequisite prior to performing procedures that carry a higher risk (administration of contrast media, interventional measures). A preparatory conversation between the patient and the physician needs to take place leaving the patient with sufficient time to ponder the options prior to the study.

Consent should be obtained from the patient prior to entering the procedure room if the administration of contrast is intended. If elective angiography or balloon dilation is planned, consent should be obtained at least 24 hours prior to the intervention. Asking patients to consent while they are already on the procedure table is legally nonbinding except in a life-threatening emergency. A countersignature of the physician is usually necessary. One should make it a habit to jot down explanatory drawings and handwritten notes on the consent form because they prove the very per-

sonal quality of the conversation. If a fully conscious patient rejects the suggested procedure—for whatever reasons—this must be accepted; that is, the patient must have the possibility to decline without further interference. A study or procedure performed in spite of the patient's refusal amounts to inflicting bodily harm, with associated potential legal consequences. If a patient loses his or her legal decision-making capacity in the further course of events—becomes unconscious, develops a psychosis, etc.—the case must be reconsidered in the best interest of the patient.

### 5.1 The Nonindicated Study

A study is not indicated if in a given clinical setting no information can be expected from it that could in any way alter further management. That may sound trivial. The execution of any nonindicated procedure, however, may lead to the delay or prevention of necessary, indicated diagnostic or interventional measures. As a matter of fact, it may sometime prove fatal for the patient:

**Patient Paellé:** Brazil Paellé (56) fell out of the bus that carried him and his friends back home from an out-of-town victory of "his" soccer team. He is not exactly sober and has suffered a bleeding skull laceration. Like all his friends who have brought him to the emergency department, he is in a splendid mood and fully oriented as to the latest league results. A radiograph of the skull is performed to exclude a fracture and turns out to be normal. After his wound has been sutured and dressed by the young doctor on call, Paellé's friends bring him to his luxurious bachelor apartment to rest. That night he becomes disoriented and helpless, and finally becomes unconscious to meet his ultimate "referee" and creator early in the morning. His body is examined by the forensic medicine department. The colleague there discovers a lethal intracranial epidural/extradural hematoma (see p. 236). The public prosecutor confiscates the patient documents. Just what went wrong?

For starters, nobody with a significant head injury should be permitted to remain without close supervision for the next 24 hours—friends or spouses can also monitor the level of consciousness in less severe cases. Secondly, the unremarkable skull radiograph lulled the on-call doctor into falsely believing that no significant injury had occurred. This was a fatal misconception since it is not the potential skull fracture that determines the course of events but the intracranial, space-occupying, and poten-



### Primum Nihil Nocere



Fig. 5.1 “Primum nihil nocere” (“First do no harm”) Hippocrates and/or Galen used to say. In Greek, however. It was then as it is today: Patients undergoing treatment of any kind need to trust us with their lives and they should have every reason to do so.

tially lethal hemorrhage that may develop slowly. A radiograph cannot exclude intracranial hematoma or other significant abnormality and is therefore irrelevant. If any disturbances of consciousness develop after head injury, if a skull fracture is likely, or if the presence of a laceration or the mechanism of an accident suggest the possibility of significant intracranial injury, a head CT is indicated. Much more frequently, however, studies are performed that burden the patient and cost time and money without improving the patient's health or quality of life at all. It is the same here as everywhere in life: an experienced professional may know very well when further investigation may not be warranted. Patients entrust themselves to us and those who cannot or do not want to question our actions must not be disappointed by too cavalier an approach of their physicians (Fig. 5.1).

Now, how can you quickly scrutinize the indication of a scheduled study or find the right procedure for your patient if you are not really experienced? The indication list of the British Royal College of Radiologists “Making the best use of a Department of Clinical Radiology” provides some orientation and has been integrated into this book. An adapted specific excerpt precedes each of the clinical chapters.

! Diagnostic imaging, however expensive and impressive it may be, does not replace a careful physical examination or well-thought-out therapy. In emergencies, clear indications help expedite the diagnostic process; the appropriate choice of modality depends on its power to comprehensively examine the clinical problem at hand.

## 5.2 The Ill-Prepared Study

Any examination can lead you astray or cause erroneous findings if it is poorly executed. Reasons may be the lack of experience of the examining physician, especially when dealing with less frequent clinical problems, or when performing a study that requires considerable technical skill but has not been performed by that particular physician in a while. When considering the choice of a radiographic modality, its particular operator dependence also needs to be taken into account. If your least-talented ultrasound technologist is on duty and is unwell because of a long night on the town the previous evening, you may need to consider doing the examination yourself or choosing a more objective method such as CT.

! Insufficient preparation of the patient, however, is by far the most frequent cause of failed studies.

The responsibility for patient preparation lies mainly with the referring physician. If the patient is restless and unable to cooperate, sedation must be considered. Special preparatory measures have to be communicated and explained to the patient with sufficient care, making sure that the information is understood. A lady undergoing an ultrasound of the abdomen, for example, should preferably be fasting because an air-filled stomach hinders optimal visualization of the pancreas. A nervous older gentleman who is scheduled for an upper gastrointestinal study with barium and air followed by a small-bowel follow-through should also be fasting to allow for a good contrast coating of the gastric mucosa. Fasting in this context means: no breakfast, no coffee, no smoking, no toothbrushing and, of course, no alcohol. For obvious reasons, the study should be scheduled in the morning hours and diabetic patients should be examined first and perhaps need to consider reducing their morning dose of insulin if applicable. Referring physician and radiologist have to cooperate well in these cases; mistakes and failures are more than irritating for the patient:

**Patient Maggie Snatcher:** Mrs. Maggie Snatcher (78) has been complaining about irregular bowel movements for some time. The rectal examination is normal but occult blood has been detected in her stool. You send your patient to radiology to get an air contrast barium enema (see p. 193), to exclude large-bowel pathology. You have, however, forgotten to properly inform and prepare Mrs. Snatcher. She has not been told to take a laxative the day before; she has eaten dairy products until the evening before instead of having only clear liquids and soups for two days prior to the examination. Radiologist Smith does not cancel the examination when he learns about her lack of preparation. He fights hard to make the best of it to spare the patient (and you) having to schedule another appointment. The examination takes three times longer than normal because every piece of fecal residue has to be differentiated from intraluminal tumor. Finally Smith surrenders, stating that no tumor can be found.

Four weeks later the examination is repeated after a textbook preparation and a plum-sized malignant polyp is diagnosed by Smith's special friend, Assistant Professor Newman. You should not be counting on any favors from Smith for a few months to come. And your credit rating with Mrs. Snatcher has also gone down the drain.

**!** A badly prepared study may cost you dearly in terms of time, nerves, and friends at the very least. It will certainly ruin your day.

## 5.3 Studies with Contrast Media

Contrast-enhancing substances are commonly used in plain radiography, CT, MRI, and sometimes even in ultrasound. They serve to improve the visualization of hollow organs, vessels, and parenchymal organs, and to document the perfusion or metabolism of tissues. Contrast media can result in a higher or lower signal intensity of structures of interest relative to the immediate anatomical surrounding—in radiography and CT the radiation attenuation is increased or decreased.

### Contrast Media in Radiography and CT

#### Iodinated Intravascular Contrast Media

→ **Definition:** Iodinated contrast media (CMs), whether administered intravascularly or elsewhere, are currently the most frequently used type of contrast media. For the most part they are nonionic substances of low osmolality. Because of their rather high viscosity they are usually warmed before administration. The use of ionic CMs has declined in recent years because they are associated with a higher rate of allergic reactions. They are also more neurotoxic and nephrotoxic than nonionic CMs.

→ **Dosage:** Intravascular administration: 1 g iodine/kg body weight in adults and 0.6 g iodine/kg body weight in children should not be exceeded. As CMs are eliminated via the kidneys, the patient must be adequately hydrated, that is, he or she should drink a lot or should be given an additional infusion.

**!** Hydration is of paramount importance in contrast administration. Infusion therapy may be necessary in some patients.

**Heart disease, hematological disease, or oncological disease:** Patients with severe cardiac insufficiency (NYHA III and IV) and arrhythmias can decompensate after contrast administration. The same is true for patients with multiple myeloma, polycythemia vera, or sickle cell anemia.

**Metabolic diseases:** Diabetic patients should discontinue metformin medication for two days after the CM study because of the risk of lactic acidosis. If serum creatinine

remains stable after contrast administration (48 hours), metformin medication can be restarted. A low dose of contrast should be used in patients with homocysteinuria.

**Renal disease:** In patients with latent or manifest renal insufficiency (serum creatinine in excess of 2 mg/dl), renal function can further deteriorate or cease altogether. Good hydration needs to be ensured. If needed, an infusion of saline has to be administered, the amount of CM must be minimized, and dialysis must be considered. If there is no renal function left, that is, in terminal renal insufficiency treated with regular dialysis, dosage of CM can be normal. In case of doubt, consult with the treating physician/nephrologist of the patient to determine the best course of action and renoprotective options.

**!** In renal disease, contrast media should only be given after the serum creatinine has been checked.

**Thyroid disease:** In patients with suspected (latent) hyperthyroidism, iodinated CM may only be given after a detailed laboratory analysis (Table 5.1) and in consultation with the referring physician. The sudden iodine load introduced into the patient during CM administration may lead to severe hyperthyroidism and even thyrotoxic crisis in some cases. This is a potentially lethal disease entity that requires intensive care and that can occur weeks or even months after CMs are given.

→ **Allergic reactions to contrast media:** Iodinated contrast media can cause severe adverse and allergic reactions. Slight adverse reactions are seen in about 1% of patients, a life-threatening anaphylactic reaction in approximately 1 out of 1000 patients. It is thus essential to be familiar with the treatment of these reactions and to have the appropriate drugs and other tools available where contrast is administered. Teamwork is extremely important in severe CM incidents, which is why group training including technologists and physicians should be performed on a regular basis.

**!** A large, safely taped venous access line is required in examinations with intravascular iodinated CM. A resuscitation cart well equipped for cardiopulmonary resuscitation is also essential, together with the telephone or beeper number of the resuscitation team clearly visible on the wall.

Table 5.1 Normal thyroid hormone levels (may vary from one laboratory to another)

TSH: 0.23–4.0 mIU/ml	
TT <sub>3</sub> : 0.8–1.8 ng/ml	TT <sub>4</sub> : 45–115 ng/ml
FT <sub>3</sub> : 3.5–6.0 pg/ml	FT <sub>4</sub> : 8.0–20.0 pg/ml

F, free; T, total.



Patients with a history of asthma, atopic dermatitis, and allergies (e.g., hay fever) or reactions to contrast media in previous examinations need particular attention. Reactions to CMs that date back more than 15 years are not as worrisome as those on more recent occasions: the reason is the change of CMs from the ionic to the better-tolerated nonionic type during the course of the 1990s. Always have the patient describe the precise circumstances of a previous CM reaction so as to gauge the significance and severity of the earlier reaction—a period of intensive care after the incident is a big red flag. As a first step, the indication of the requested study should be critically reviewed. Does the potential increased yield of information outweigh the increased risk of CM administration? If the answer is “yes,” the history of moderate CM reactions should prompt the administration of oral steroids (for example, three 50 mg doses of prednisone 13 hours, 8 hours, and 1 hour prior to the examination) and intramuscular antihistamines (for example, 50 mg of Benadryl 1 hour prior to the examination). Patients are advised that it is not safe to operate a vehicle for 8 hours after this medication has been administered because of its sedative effect and they should not be left alone. In patients with a history of severe CM reactions, studies with CM administration should only be performed in the presence of an anesthesiologist or equally qualified physician ready to intervene.

**Moderate adverse reactions:** Heat sensation, unrest, an urge to cough, yawning, sneezing, nausea, vomiting, itching, edema of the eyelid, urticaria, as well as redness and edema of the skin or mucous membranes are signs of moderate reactions. Go and talk to the patient calmly (!), check heart rate and blood pressure, and, if deemed necessary, have the assisting personnel mix H<sub>1</sub>- and H<sub>2</sub>-antagonists in 50 ml of saline and give it via the venous access line over the course of about 5 minutes. In addition, corticosteroids can also be administered intravenously. The responsible physician in charge stays with the patient and conveys tranquility! This is the moment to give the patient the impression that as professionals we are taking good care of him/her even during a minor incident. After such an incident the patient must be monitored for a few hours and should not leave the premises before a physician has had a chance to reevaluate him or her.

#### Checklist: Moderate Adverse Reactions

1. Stay calm and calm down the patient!
2. Ensure functioning intravenous access.
3. Monitor the patient closely; check blood pressure and pulse.
4. Administer H<sub>1</sub>- and H<sub>2</sub>-antagonists in saline infusion.
5. Have corticosteroids available.

**Severe adverse reactions:** Sudden sweating, pallor, generalized exanthema, shivering, fear, back pain, dyspnea, bronchospasm, asthma, glottic edema, tachycardia, loss of blood pressure, loss of conscience, cramps, and lack of pulse are hallmarks of a severe reaction. The first step after recognizing a severe reaction is to declare a med-

ical emergency and to inform the hospital resuscitation team or the local emergency team if you are outside the hospital. If a large venous access is not yet present or not functioning, put one in now. An infusion is started; an ECG is initiated if available. The legs are elevated. The doctor stays with the patient! And remains calm—“It’s the patient, who is sick!” Antihistamine medication is given intravenously; the dosage of corticosteroids is raised. If the patient goes into shock, the usual **ABC rules** apply:

- **Free the Airways:** Lift the chin forward and tilt the forehead back to open up the pharyngeal air passage; if necessary, secure the airway with instrumentation.
- **Ensure Breathing:** Ventilate the patient either mouth-to-mouth or mouth-to-nose if necessary or with airway protector and bag/mask if available; give oxygen (3–6 l/min); intubation is reserved for the experienced physician.
- **Restore Circulation:** In asystole try a precordial thump; if that is without effect, start cardiac massage with intermittent respiration (15 : 2 if you are doing it alone or 5 : 1 if you have assistance). The patient must be resting on a rigid support; the lower third of the sternum is depressed by 4–5 cm with a frequency of 70/min; in children the frequency is higher and depression is less deep. Cardiac massage must be performed with care and tailored force: rib fractures in resuscitation are normal but not desirable. Utilize cardiac defibrillation as indicated.

#### Checklist: Severe Incompatibility Reactions

1. Call the resuscitation team at once.
2. Secure the intravenous access, give volume (fluids), corticosteroids, antihistamines (in infusion) quickly i.v.
3. Clear the airways; oxygen 3–6 l/min; respire via mouth/nose or mask.
4. Monitor blood pressure and pulse; do ECG; use pulse oximeter.
5. In blood pressure loss, elevate legs 60° or more; give volume (fluids); epinephrine (1 : 10 000; 0.1 ml dissolved in 1 ml saline) slowly i.v.
6. In asystole do a precordial thump first; if that fails, initiate cardiac massage; epinephrine (1 : 10 000; 0.5 ml dissolved in 5 ml saline) slowly i.v.

If the risk of a major adverse reaction is deemed too great, the study is performed without CM (for example, in CT) or replaced by other modalities such as ultrasound or MRI. If only very little CM is needed, such as in i.v. line checks, some colleagues have used the extremely expensive but low-risk MR contrast medium gadolinium, which also appears opaque on plain radiography. This represents “off-label” use, however.

→ **Contraindications:** A history of severe prior adverse reaction to iodinated CM represents a relative contraindication for its use because of the significant potential associated morbidity and mortality. CM administration interferes with radioisotope therapy of the thyroid gland, for example, in patients with thyroid cancer or Basedow/

Graves disease with thyroid orbitopathy because the iodine uptake capacity of thyroid tissue may become exhausted for several months by administration of iodinated CM. You should consult the treating physician prior to CM administration in these cases to discuss risks and benefits as well as optimal timing of the study.

### Contrast Media for Extravascular Use

→ **Definition:** Barium-containing as well as iodine-containing CMs are used preferentially for studies of the gastrointestinal tract. Frequently, barium-containing substances are administered together with air or methylcellulose to achieve a radiopaque coating of the luminal surfaces of hollow organs, which stand out nicely against adjacent air during so-called “double contrast” examinations.

→ **Dosage:** These CMs are administered orally or rectally. The exact dosage, viscosity, etc., depend on the clinical question, anatomy, and other circumstances.

→ **Contraindications:** If there is a suspicion of a rupture/perforation of a hollow viscus or fistula formation of the gastrointestinal tract to the peritoneal cavity, barium-containing CMs are generally contraindicated. This is due to the severe foreign body granulomatous reaction that they can induce in the peritoneal cavity when they leave the GI tract. They should also not be given to patients with partial or complete ileus because they tend to agglutinate and aggravate the peristaltic problems further. The same is true in immediately preoperative examinations because peristaltic disturbances are frequent anyway after abdominal surgery. In these cases an iodinated hyperosmolar water-soluble CM may be used, although its diagnostic efficacy tends to be poorer. It has a lower radiodensity and dilutes faster. Its hyperosmolarity also explains the therapeutic effect it has: as the CM is diluted it draws interstitial fluid into the intestinal lumen and thereby triggers peristalsis. For the same reason the patient must be well hydrated. If hyperosmolar CM is aspirated into the bronchial tree the same principles apply—the fluid transfer into the bronchial lumen leads to pulmonary edema. For this reason patients with swallowing disorders in danger of aspiration should be examined with a nonionic iso-osmolar CM, usually administered intravascularly to decrease the risk of pulmonary edema, or with thin barium-containing CMs, which do not irritate the bronchial tree or mediastinum at all (though they tend to hang around for a while ...).

### Contrast Media in Magnetic Resonance Tomography

Contrast media for magnetic resonance tomography tend to shorten the relaxation times of protons. The most frequently used CM type is a **gadolinium chelate**. It is administered with a dosage of 0.1–0.3 mmol/kg body weight and excreted by the kidneys. This type of CM is very well tolerated—significantly better than all iodinated CMs in radiography and CT—and induces considerably fewer allergic reactions.

Another type of MR contrast medium consists of **ferrite compounds** that accumulate in the intact reticuloendothelial system (RES), especially in the spleen and the liver. The contrast between the healthy and pathological tissue is thus enhanced. The development of specialized CMs in MR imaging continues at a dizzying pace and some surprises can be suspected in the future.

### Contrast Media in Ultrasonography

Contrast media in ultrasonography consist of microscopically small galenically stabilized air bubbles. They are very well visible inside the vessels with Doppler ultrasound. They are only rarely used in current clinical routine but promise to be very useful in, for example, characterization of liver lesions or any other situation where vascularization of an organ or disease process is to be examined.

## 5.4 The False Finding

There are two kinds of false findings: the false-negative finding that ignores or overlooks a lesion, and the false-positive finding that indicates a lesion where there is none. Both kinds of false reports can have enormous consequences for the patient but they cannot be completely avoided in daily practice. Their number must be kept as low as possible, though, and false findings discovered in retrospect should always be reviewed to improve the diagnostic process.

**False-negative finding:** A tumor on a chest radiograph, for example, is diagnosed when its conspicuity exceeds the detection threshold of the observer. The level of the threshold depends on the experience and concentration of the observer as well as on objective factors such as exposure of the radiograph and viewing conditions (monitor or viewing box brightness, ambient light, etc.). If the lesion is detected, it must be evaluated. Is it a benign finding, for example, a harmless postinflammatory granuloma, or could it be a malignant process, for example, a bronchogenic carcinoma? Retrospective studies in patients with bronchogenic carcinoma have shown that in up to 30% of cases the tumor could already be detected on previous films that were reported as normal—if one had a real close look and in retrospect, of course. (This is in no way a phenomenon unique to radiologists. Up to 50% of all coronary infarctions are overlooked by internists even in teaching hospitals—when you ask the pathologist.) Even seasoned radiologists with years of experience will not be able to avoid false-negative reports altogether. In the worst-case scenario, life-saving therapy is delayed beyond salvage.

**False-positive finding:** The false-positive finding also bears a considerable risk for the patient. If, for example, a microcalcification in mammography is falsely felt to be suspicious for malignancy, a biopsy is performed. Even though nowadays this will most likely be done as

a stereotactic needle biopsy under local anesthesia on an outpatient basis (rather than a surgical biopsy under general anesthesia), the psychological stress for the patient is still considerable and may induce further complications. Because the incidence of the potentially lethal breast cancer is very high and the distinction of benign and malignant calcifications difficult, false-positive findings are one price to pay for an overall high cancer detection rate. Currently only every fourth biopsy of a suspicious breast lesion turns out to be cancer.

One scientifically proven way to reduce false-positive as well as false-negative findings is to have experienced diagnosticians “double-read” the studies. This is a costly practice but it has been successfully incorporated in most quality-controlled large-scale breast screening programs worldwide.

## 5.5 Risks of Radiological Procedures

### Risks of Projection Radiography and Computed Tomography

The terrifying experiences of the early x-ray pioneers, some of their patients, and the victims of Hiroshima, Nagasaki, and Chernobyl demonstrate the risks of exposure to large doses of ionizing radiation with dire clarity. However, the number of human beings who have been helped by the use of radiation in diagnosis and therapy exceeds that of the victims by several orders of magnitude. The injuries that can be induced by the normal procedures in diagnostic radiology are less frequent and less severe than those that occur in the course of other routine medical therapies (for example, drug intoxications) or other diagnostic procedures (for example, pancreatitis after ERCP). All the same, many patients continue to feel uneasy about x rays. They need to be comforted with truthful information, and we need to strive to limit the use of diagnostic ionizing radiation to proper indications.

#### Effect Does Not Equal Effect

**Stochastic effect:** *Even minimal radiation doses have an effect.* They increase the likelihood of developing malignant tumors (somatic effect) and sustaining genetic damage (genetic effect) that might otherwise also occur without interference by man-made technology though less frequently. There are therefore no real threshold values below which the administration of x-rays is totally safe. This effect is also called the stochastic effect. It is a fundamental effect associated with the use of all ionizing radiation in diagnostic radiology and the major reason for the general radiation protection efforts today.

**Nonstochastic effect:** *Higher radiation doses produce direct effects.* These are, for example, damage to the skin, the hematopoietic bone marrow, and the eye lens, and radiation syndrome. A clear relationship exists between

the severity of the disease and dose. These nonstochastic effects occur mainly in radiation therapy. In interventional radiology and neuroradiology such as cardiovascular stenting or percutaneous treatment of complex arteriovenous malformations in the CNS, nonstochastic effects such as radiation-induced erythema, ulcerations, or hair loss have been reported anecdotally in patients undergoing complex procedures exposed to prolonged fluoroscopy, for example. Obviously this also poses a serious threat to the physicians involved. Radiation-induced lens injury has been reported in interventional radiology.



#### Stochastic Effect?

Wilhelm Conrad Röntgen died owing to an ileus 28 years after his discovery of x-rays. The young and famous surgeon Sauerbruch, a pioneer of intrathoracic surgery, tried to save him with a last-minute operation but was unsuccessful. A large-bowel carcinoma as one likely cause of the ileus could only be attributed to the stochastic effect. X-ray tubes were prohibitively expensive even in those early days—and they survived but a few exposures. For that reason Röntgen’s total radiation exposure was probably low. Apart from that, the cautious old fox used to leave the laboratory while his experiments were running. Interestingly enough, there are no radiographs of Röntgen himself, but there exists one of the hand of—you guessed it—his wife Anna-Bertha.

Figure 5.2 shows a typical nonstochastic effect from the early days of radiology as suffered by Max Levy-Dorn, one of the pioneers and first victims of the new technology.

#### Dose Does Not Equal Dose

**Energy dose:** The *irradiation of a lifeless object* is adequately described by the energy dose. This represents the radiation energy (J; joules) that is absorbed per unit mass (kg) and is measured in units of grays (1 Gy = 1 J/kg). Any impact the radiation may have on an organism is completely ignored by this descriptor.

**Equivalence dose:** The *effect of x-rays on living organisms* is described by the equivalence dose. To calculate it, the energy dose is multiplied by a correction factor that represents the biological effect of radiation. It is measured in units of sieverts (Sv). For the usual x-rays this correction factor fortunately equals 1, which is why 1 Sv = 1 Gy = 1 J/kg. The energy and equivalence dose are of course difficult to measure in any living organism let alone a human being. The patient would have to swallow dosimeters, which would have to be read out after the intestinal passage—a little impractical, to say the least.

**Personal dose:** To quantitate the effect of radiation on an individual, the personal dose was introduced—also measured in sieverts (Sv). It represents the equivalence dose at specific representative locations on the body surface where you can wear a dosimeter. Now dose becomes a parameter you can work with. Dose limits have been

## Nonstochastic Effect

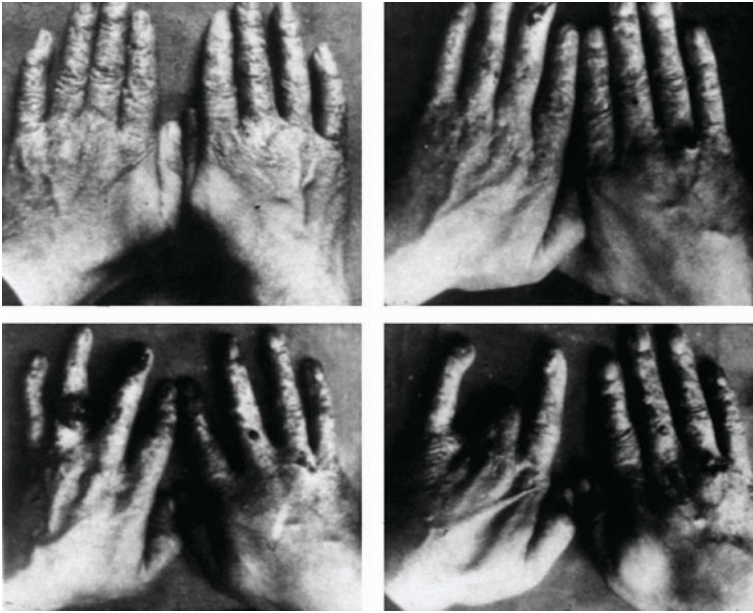


Fig. 5.2 These historical photographs show the development of radiation injury to the hand of Max Levy-Dom, who acquired it over the duration of several years as chief of one of the first radiology departments in the world. Before starting an examination he used to test the function of the “Roentgen” tube—unfortunately using his own hand as a test object.

agreed upon (Table 5.2). To put these into a proper perspective, here is a comparison: The natural radiation exposure of the gonads is about 1.1 mSv/year, while radiation exposure to this area due to human activities (from medical exposures, fallout from atomic bombs, etc.) equals approximately 0.6 mSv/year.

### Protection of the Patient

! The best radiation protection is to adhere to a strict indication list, reducing the number of examinations to the absolute necessary minimum, and whenever feasible to choose other imaging modalities that do not require radiation.

The technical execution of the examination by an experienced diagnostician comes next in line: fluoroscopy times are kept short, the radiated volume is kept small by careful collimation, the distance of the patient to the detector is kept short, and the examination protocols (for example in CT) are dose-optimized by experienced physicians and by

clever scanner technology. Minimal dose means a dose that is just short of decreasing the diagnostic performance of the study. This is also called the **ALARA** principle: **as low as reasonably achievable**. The choice of a dose-saving detector system, that is, a fitting film–screen combination or an optimized digital area detector, plus adequate beam filtration is essential. For the patient, the collimation of the x-ray beam is important to keep the exposure due to scattered radiation low (see Chapter 3, p. 6). Lead protectors should be used minimize the exposure of the gonads if the circumstances allow: in polytrauma, lead protection of the ovaries in women is impossible because fractures of the pelvic ring could be missed. Clever new CT scanners constantly modify the tube current and exposure according to patient thickness at each location as they proceed through an examination.



### Gonadal Protection: When and Where

Radiation protection in women is more difficult than in men, for anatomical reasons. In acute polytrauma, protection is secondary in both sexes. In normal pelvic films, gonadal protection may obscure the region of interest in women. The female fertile phase ends with menopause, which makes gonadal protection less important. The law states that men need protection where appropriate. G.E.’s old chief used to put it this way: “Every man up to the age of 60 gets gonadal protection. Older men get it if they request it—but they get a piece of sweet chocolate with it.”

If you translated a single-study dose into a total-body dose that would result in the same risk of acquiring genetic damage or a malignant disease, the result would be as shown in Table 5.3.

Table 5.2 Legal dose limits for professional radiation exposure

Organs/body region	Dose limit (mSv)
Gonads, uterus, red blood marrow	50
Thyroid, periosteum, skin	300
Hands, forearms and thighs, ankles	500
All other organs	150



Table 5.3 Effective total body dose in radiological examinations

Examination of organs/ body regions	Typical effective total body dose (mSv)	Equivalent number of chest radiographs	Equivalent period of natural background radiation
<b>Radiography</b>			
Limbs and joints	0.01	0.5	1.5 days
Chest PA	0.02	1	3 days
Skull	0.1	5	2 weeks
Cervical spine	0.1	5	2 weeks
Thoracic spine	1.0	50	6 months
Lumbar spine	2.4	120	14 months
Hip	0.3	15	2 months
Pelvis	1.0	50	6 months
Abdomen	1.5	75	9 months
Barium swallow	2.0	100	1 year
Barium follow-through	5.0	250	2.5 years
Small-bowel barium enema	6.0	300	3 years
Large-bowel barium enema	9.0	450	4.5 years
Mammography	0.5	25	10 weeks
<b>Computed tomography</b>			
Head	2.0	100	1 year
Chest, abdomen	8.0	400	4 years
<b>Scintigraphy</b>			
Bone	5.0	250	2–5 years
Thyroid	1.0	50	6 months
Heart (thallium)	18	900	9 years

### Protection of the Examining Physician

Most factors that serve the radiation protection of the patient also diminish the radiation exposure of the radiologist. These include the adequate experience of the examining physician, short fluoroscopy times, strict collimation of the x-ray beam, dose-minimized x-ray equipment, and a strict adherence to the indication list. One very effective protective measure is to keep the greatest possible distance (dose decreases by the square of the distance) from the primary or secondary sources of radiation (the tube and the patient). Another measure is to protect the physician with lead-lined, sometimes movable, walls, lead aprons, gloves, thyroid protectors, and awkward-looking lead-glass goggles or spectacles (Fig. 5.3).

By the way, British radiologists working between 1920 and 1945 showed the same cancer incidence as their nonradiological clinical colleagues and lived longer than the average general practitioner in the United Kingdom at that time.



#### X-rays Are Everywhere

A standard chest radiograph imparts a radiation dose of about 0.2 mSv; the CT study of the chest exceeds 20 mSv. A mammography takes about 2 mSv. One transatlantic flight from cool New York to old, old Europe for that cultural weekend, or vice versa, amounts to 0.1 mSv of cosmic radiation. The healthy life on an Austrian high mountain pasture increases the natural exposure to up to 10 mSv/year.

### Paul Gets Real Serious



Fig. 5.3 Paul is well equipped for any radiological intervention, wearing a lead skirt that puts the weight on his iliac crests and not on his spine. The lead waistcoat, the thyroid protector, and the trendy lead goggles complete the outfit. In his hand he holds a quartz fiber dosimeter that is worn underneath the lead waistcoat, just like the film dosimeter, during the examination. Behind him you see a movable lead panel. Paul has thrown the clumsy lead gloves that are used in noninterventional fluoroscopy (such as barium enemas) onto the tabletop.

### Risks of Ultrasound

Direct relevant risks of ultrasound techniques are not known. However, the results of an ultrasound examination depend strongly on the quality and experience of the examiner and are often difficult to document. The indirect risk to the patient due to nonultrasound procedures that follow false-positive or incorrect ultrasound findings is thus much higher than any direct hazard. There is, nonetheless, a general agreement that multiple ultrasound examinations of the unborn within the mother's womb without clinical indication ("baby-video") should not be performed because of the susceptibility of the unborn to external perils.

### Risks of Magnetic Resonance Tomography

The extremely strong magnetic fields can cause malfunctions of mechanical and electronic equipment. Self trials with the inherited Rolex or the American Express card are not really recommended, but variations of the theme are reported on a regular basis. Metal buckets filled with cleaning water and carried into the MRI examination suite by inexperienced cleaning personnel off hours, which then miraculously plunge into the system gantry, emptying themselves and leaving the MRI machine unusable for weeks—it has all been heard of. Figure 5.4 shows a particularly worrisome approach to a 1.5 tesla MRI machine that led to a total loss of the system, fortunately without any damage to human life or health. There is the story of an MRI engineer in a Great Lake City in the United States who was trying to repair something from inside the gantry of a running 1.5 tesla MRI machine propped up on a trailer truck. A fork lifter passed by the trailer; the unsecured forks were torn off the fork lifter and pierced through the trailer wall into the gantry of the machine, killing the engineer. That serves to make the point: MRI is by no means a harmless or risk-free technology. The following perils need to be considered:

- The induction of electrical currents
- The movement of metallic objects
- The noise that is generated by quickly switching gradients

### Fatal Affinity

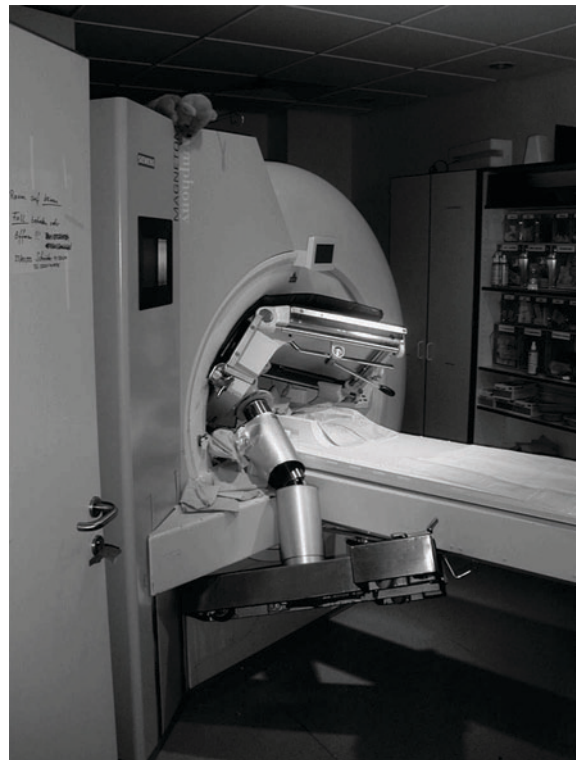

Fig. 5.4 Where raw forces act without reason . . . What you see in the gantry of this MR machine is a 200 kg (31.5 stones or 441 pounds) surgical table.

**Induction of currents:** Currents are not only induced in the MR receive coil or antenna. This occurs in all conducting structures. Flowing blood is such a conductor. The resulting current boosts the ECG curve at the time of the peak blood flow: the T-wave is raised. In cables, particularly in cable loops (cardiac pacemakers), currents are generated that can lead to overheating and even burns. Loops such as these can also be caused by faulty patient positioning: if the patient's hands or bare calves touch each other, burns can result.

**!** Ear implants, cardiac pacemakers and defibrillators (including residual wires), neurostimulators, and implanted electronic infusion pumps prohibit any MR study.

Firmly anchored osteosynthetic material can disturb the imaging process and heat up. Metallic implants longer than 20 cm should be approached with special care. If the patient feels unwell during the examination, it should be terminated immediately. Paramagnetic materials, which are attracted little by magnetic fields, and ferromagnetic materials, which can be magnetized, can also severely compromise imaging. Tattoos may also hinder imaging and heat up depending on their ingredients. For the same reason, eye shadows (which often contain metal) and jewelry of all sorts (rings, bracelets, piercings, etc.) must be removed (Fig. 5.5).

**Movement of metallic objects:** The extraordinary danger due to metallic objects outside the body has already been mentioned. But how about metal within the body? One must ensure prior to the examination (e.g. with an orbital radiograph) that retained shrapnel or other metallic for-

### Piercing, Yes but . . .



Fig. 5.5 This patient is well prepared for his examination. He brought a pair of pliers along to take his jewelry off. It took him about half an hour.

eign bodies are not located in the vicinity of crucial structures such as the eye. The usual prosthetic cardiac valves do not constitute a contraindication for MR imaging. However, as a general rule, patients with loose vascular coils, stents, or filters should not be examined. At least six weeks should go by after implantation before an MR procedure is considered. MRI-induced movement of aneurysm clips on cerebral vessels are really dangerous. Lethal incidents have been reported. The type of clip—which is hopefully documented in the surgical report—and its MR compatibility should be determined with great care. Lists on the MR compatibility of almost all implanted materials are available on the Internet (see the homepage of the Food and Drug Administration, FDA: <http://www.fda.gov>; or that of the International Society for Magnetic Resonance in Medicine, <http://www.ismrm.org>).



### What Does the FDA Say?

“For a properly operating system, the hazards associated with direct interactions of these fields (static magnetic, pulsed gradient and radio frequency) and the body are negligible.

It is the interaction of these fields with medical devices . . . that create[s] concerns for safety.”

**Noise generated in the course of gradient switching:** The extremely rapid switching of gradients, particularly in modern fast and complex MR sequences, can lead to noise levels beyond 100 dB. Just to remind you: music during an exuberant disco night reaches 140 dB, a jack-hammer about 120 dB. Ear plugs or special protective headphones are thus mandatory for the patient and any other person in the same room (and for your disco visit, obviously . . .).

Further risks to human life and health due to the commonly used MR techniques are not known. Elective MR studies of women in early pregnancy (up to the third month) are nonetheless discouraged because of residual safety concerns. In vital indications in this patient group, however, MR is always preferred to CT because of the lack of definitely harmful ionizing radiation and because MR often has the same or a better diagnostic yield.

**!** The MR room may only be entered after a thorough briefing by and in the company of the MR personnel. Any cables inside the body prohibit MR studies.

## 5.6 Risks of Intervention

A considerable proportion of risks in invasive imaging (such as angiography) is due to the use of contrast media, which has already been covered. Further significant risks are:

- In **angiography**, direct injury of the vessel may occur including dissection of the vascular wall, hematoma, arteriovenous fistula formation, or the development of pseudoaneurysms at the site of vascular entry. Furthermore, catheters may dislodge thromboembolic



material adherent to plaques (in older patients) or induce vascular spasm (in younger patients).

- During **embolization** of tumors or aneurysms, embolization material (glue, coils, balloons) may occlude vessels other than in the target areas.
- In the **implantation of stents** (intravascular vessel prosthesis) or **caval filters**, the rupture or occlusion of the target vessel may occur; or a side-branch may inadvertently become occluded.
- In the **drainage procedure** of a hollow organ or an abscess and in **image-guided tissue biopsies**, hemorrhage may occur into organ parenchyma, the peritoneum, or

the pleural cavity; perforation of intestinal structures (with the danger of peritonitis), the lung (with ensuing hemorrhage and pneumothorax), or the vessels may occur; fistulas may form.

**!** All these potential complications are good reason to reserve the patient briefing before an intervention to the physician who actually performs the procedure. Allow at least one good night's sleep for the patient before he or she is expected to make an informed decision about the scheduled procedure, especially if it is risky and not an emergency.



# From Detection to Diagnosis and Beyond

## 6 Chest

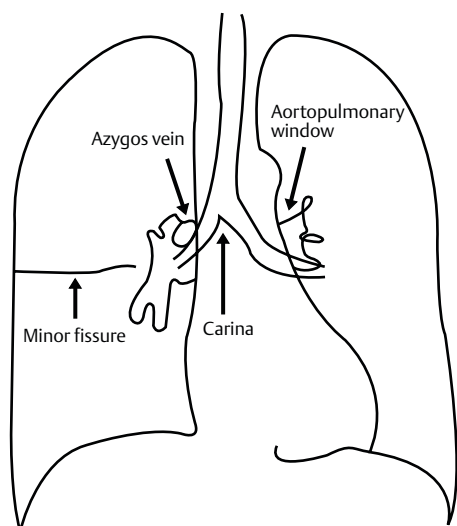


The examination of the chest is the most frequently performed radiological study overall. It is also one of the most important and demanding studies, particularly for the radiological novice, especially when alone at night on-call, and in emergency situations. The comprehensive analysis of a chest radiograph (CXR) is also a rather intellectual affair—just like a good crime story and fortunately just about as much fun.

The basic prerequisite for a correct image analysis is a sound knowledge of the appearance of normal anatomy and other essential phenomena on the CXR. The anatomy and physiology of the thoracic organs must be known as well as important optical and perceptual factors that can influence the diagnostic process. (see Chapter 4). Continuous training of the faculty for image analysis is naturally essential—fortunately there is no shortage of interesting radiographs to practice on. If you master the art of reading a CXR there will be many opportunities for you to successfully score—with your colleagues, in your exams and, what is most important, with your patients.

Of course, one must be familiar with the indications for a CXR—that is, what the method is capable of demonstrating (Table 6.1). The acute chest problems in trauma patients are dealt with in Chapter 14 on “Trauma”.

### A Diagram of the Chest



See some important anatomical structures of the chest

### 6.1 How Do I Analyze a Radiograph of the Chest?

First of all, it is important that you approach the CXR without fear—its analysis is not black magic. Secondly, you should always follow a rigid but commonsense sequence of image analysis in order to not miss an important finding. Why don't you stick to the following suggested scheme for now and try it out on a CXR without abnormal findings (Fig. 6.1a, b).

#### First Determine the Image Quality

**Is the exposure dose adequate?** Can I see the pulmonary vasculature behind the heart and underneath the diaphragmatic contour? (One-third of the lung and thus one-third of the pathological findings are situated in these dense areas.) Can I see the vessels in the central lung around the hilum well or are they too dark to evaluate?

**Is the exposure time short enough?** Is the heart contour really sharp? It is the fastest moving structure in the thorax (at a breathtaking top speed of 7 km/4.3 miles per hour!).

**Was the patient standing or lying?** Do I see an air–fluid level in the stomach (Fig. 6.1c, Fig. 6.2a)? Do the scapulae project outside of the lung fields (Fig. 6.1, Fig. 6.2, standing patient)? Is the medial contour of the scapula projecting over the lungs? Is the mediastinum shortened in the vertical direction and widened (Fig. 6.3, lying patient)?

**Is the patient correctly positioned?** Are the spinous processes centered between the sternoclavicular joints (Fig. 6.1c)? Does the anterior end of the bony part of the first rib just about project over the level of the 4th thoracic vertebral body (Fig. 6.1c)?

**Did the patient stand still and manage to hold the breath?** Are the rib contours and the diaphragmatic outline sharp? Not all patients understand the local language or can do what they have been asked to.

#### Now Go Ahead and Analyze the Thorax

With a quick glance we note name, age, and sex of the patient before we begin the actual analysis of the standard radiograph of the chest.

Table 6.1 Suggestions for diagnostic modalities in chest imaging<sup>1</sup>

Clinical problem	Investigation	Comment
Nonspecific chest pain	CXR	Not indicated initially. Main purpose is reassurance.
Upper respiratory tract infection	CXR	Not indicated.
Chronic obstructive airways disease or asthma; follow-up	CXR	Only if signs or symptoms have changed, asthma is life-threatening, or treatment fails.
Pneumonia	CXR	Majority of patients with community-acquired pneumonia will show radiological resolution at 4 weeks. In smokers, the elderly, and chronic airways disease, resolution may be prolonged. If patients become completely asymptomatic, no follow-up CXR is needed.
Pneumonia, adults: follow-up	CXR	If patients become completely asymptomatic, no follow-up CXR is needed in younger patients or in the absence of a significant smoking history. If symptoms persist, in the elderly and smokers, 6 weeks follow-up is advised.
Acute chest infection, children	CXR	Not indicated routinely. Initial and follow-up films are indicated in the presence of persisting clinical signs or symptoms or in the severely ill child. Children may have pneumonia without clinical signs.
Pleural effusion	CXR	Small effusion can be missed, especially on a frontal CXR.
	US	Indicated. To assess fluid consistency; to guide aspiration.
	CT	CT occasionally needed for better localization, assessment of solid components, etc.
Hemoptysis	CXR	Indicated. P-A plus lateral view. If normal and hemoptysis is significant or out of context of a concurrent chest infection, further investigations are necessary.
	CT	In conjunction with bronchoscopy. May detect malignancies not identified on CXR and bronchoscopy, but is insensitive to subtle mucosal and submucosal disease.
Occult lung disease	High-resolution CT (HRCT)	HRCT can show abnormalities not evident on CXR and may be more specific; may give valuable information about disease reversibility and prognosis.
Myocardial infarction	CXR	Assesses heart size, pulmonary edema, shows paradiagnoses tumor and pleuritis, pneumonia.
Pericarditis, pericardial effusion	US echocardiography	Assesses size of effusion, suitability for drainage, development of tamponade, concomitant pathology. Best for follow-up.
Valvular disease	CXR	For initial assessment.
	US echocardiography	Best method of sequential follow-up. TOE may be needed for prosthetic valves.
	MRI	Useful in congenital heart disease. Contraindicated in many patients after mechanical heart valve replacement.
Hypertension	CXR	Assesses cardiac size and possible associated pathology such as aortic coarctation or rib erosion from collaterals.
	US echocardiography	Most practical method for assessing LV hypertrophy.

CT, computed tomography; CXR, chest radiograph; ITU, intensive therapy (intensive care) unit; LV, left ventricular; MRI, magnetic resonance imaging; NM, nuclear medicine; P-A, posterior–anterior; PE, pulmonary embolism; PET, positron emission tomography; TB, tuberculosis; TOE, Trans esophageal echography; US, ultrasound



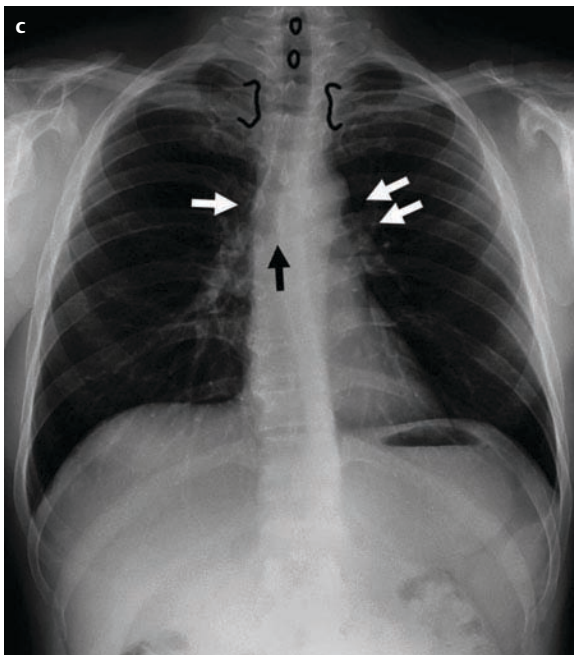
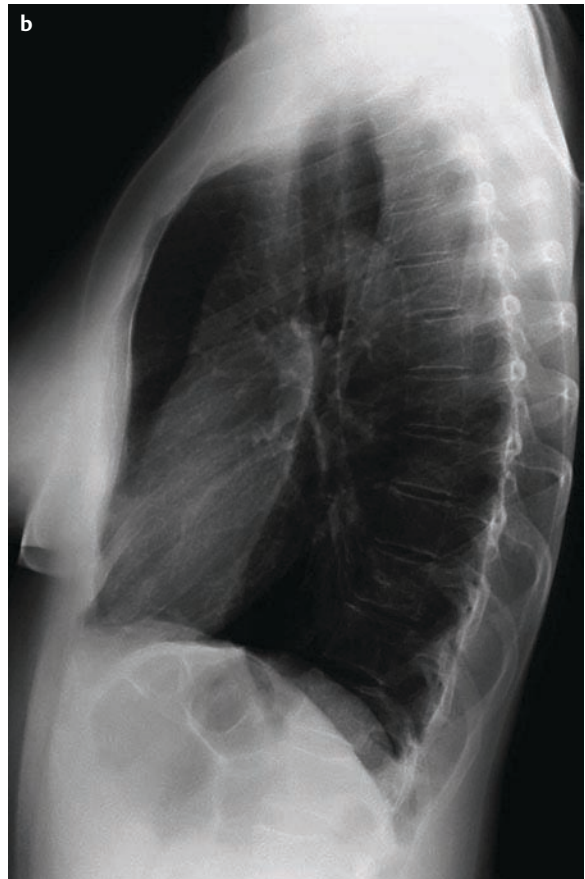
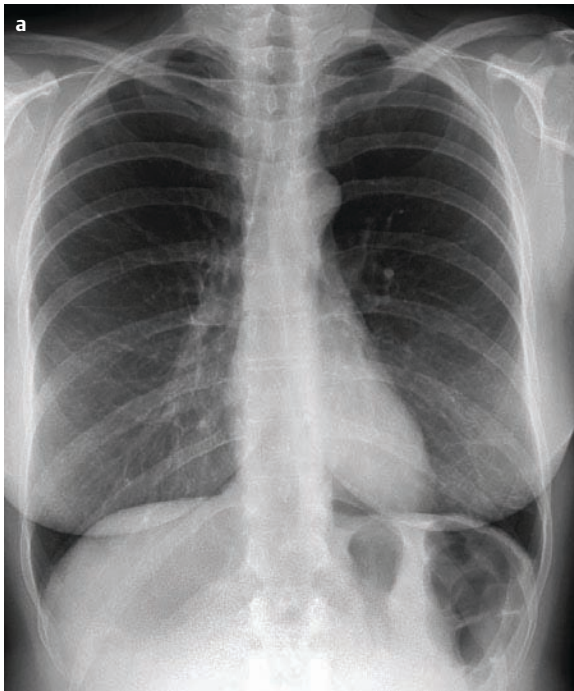
Table 6.1 (continued) **Suggestions for diagnostic modalities in chest imaging<sup>1</sup>**

Clinical problem	Investigation	Comment
Pulmonary embolism	CT	Investigation of choice; will show and exclude relevant pulmonary embolism as well as other differential diagnoses (e.g., aortic dissection); dedicated “one-stop shop” PE protocols will also demonstrate deep vein thrombosis from the knee up in the same procedure.
	CXR	To demonstrate consolidation and pleural effusion; cannot exclude pulmonary embolus.
	NM	Ventilation/perfusion (V : Q) scintigraphy can be diagnostic in patients without COPD and consolidations on CXR. Normal perfusion scintigraphy excludes significant pulmonary emboli.
Aortic dissection	CT	Investigation of choice; will show and exclude dissection as well as other diagnoses (e.g., pulmonary embolism).
	CXR	Baseline investigation to exclude other causes; rarely diagnostic.
Intensive care patient	CXR	CXR is most helpful when there has been a change in symptoms or insertion or removal of a device. The value of the routine daily CXR is increasingly being questioned. CT is a useful adjunct for problem-solving in the critically ill.
Preemployment or screening medicals	CXR	Not indicated. Justified in a few high-risk categories (e.g., at risk immigrants with no recent CXR). Some have to be done for occupational (e.g., divers) or emigration purposes (UK category 2).
Preoperative	CXR	Not indicated routinely. Exceptions before cardiopulmonary surgery, likely admission to ITU, suspected malignancy or possible TB. Anesthesiologists may also request CXRs for dyspneic patients, those with known cardiac disease and the very elderly. Many patients with cardiorespiratory disease have a recent CXR available; a repeat CXR may not be necessary under these circumstances.
<b>Cancer patients</b>		
Diagnosis	CXR P-A and lateral	But can be normal, particularly with central tumors. Marking of nipples may reduce number of fluoroscopies in tumor patients with suspected metastases.
	CT	Many centers proceed directly to bronchoscopy, which allows biopsy. CT is superior in identifying lesions responsible for hemoptysis.
Staging	CT chest, upper abdomen	Indicated. Despite limitations in specificity of nodal involvement, etc.
	NM	Some centers perform bone scintigraphy for possible skeletal metastases.
	MRI	Assists in estimating local invasion of chest wall, particularly for apical and peripheral lesions and mediastinal invasion. Helps distinguish adrenal adenoma from metastasis.
	PET	Specialized investigation. A single expensive investigation to identify small metastatic foci may save a lot of other investigations and inappropriate surgery.

<sup>1</sup>Modified after: RCR Working Party. *Making the best use of a Department of Clinical Radiology. Guidelines For Doctors*, 5th ed. London: The Royal College of Radiologists, 2003.

COPD, chronic obstructive pulmonary disease; CT, computed tomography; CXR, chest radiograph; ITU, intensive therapy (intensive care) unit; LV, left ventricular; MRI, magnetic resonance imaging; NM, nuclear medicine; P-A, posterior–anterior; PE, pulmonary embolism; PET, positron emission tomography; TB, tuberculosis; TOE, Trans oesophageal echography; US, ultrasound

## Chest Radiograph Erect: Normal Findings



**Fig. 6.1 a** This is a normal CXR of a female. Note the increased density of the lower lung due to the mammary glands. The contours of the breasts are not always visible as well as this. In a patient who has undergone mastectomy the operated side may be less radiopaque, resulting in a relative increase on the contralateral side! If one breast is missing, unintended rotation of the patient may ensue when the patient is asked to “hug” the detector or film cassette—how you control for that is outlined in **c**.

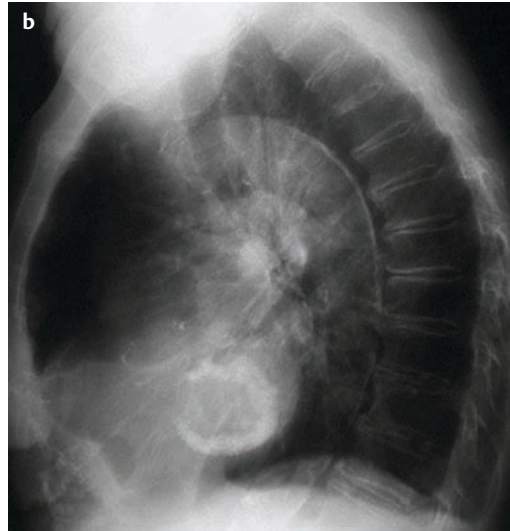
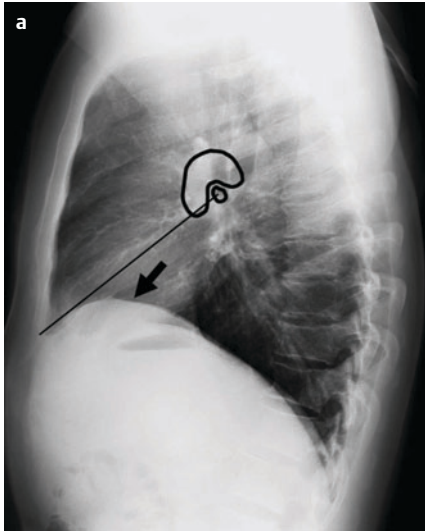
**b** Here you see a normal lateral view of a slim female. Once you identify left and right hemidiaphragms (silhouette sign of the heart, air in the colon and the stomach!), you can also assign the posterior costophrenic sulcus and the posterior lung margin to the proper side. Now find the aortic arch. Draw the pulmonary artery in your mind (see also Fig. 6.2a)

**c** This is a normal CXR of a male. You can appreciate the handy “spirit level” all of us carry around—the gastric bubble. The medial contours of the scapula are visible outside of the lungs. There is no doubt: this radiograph was performed with the patient erect. The spinous processes of C7 and T1 are marked as posterior point of reference, the medial borders of the clavicles as anterior point of reference. This patient is well positioned!

**First follow the diaphragmatic contour:** Is it well demarcated and do the costophrenic sulci show a normal depth and pointed tip? Or is there an upward-curved line (as for instance in a pleural effusion)? The right lower lobe of the lung covers the entire surface of the right hemidiaphragm;

in the left hemithorax the heart abuts the hemidiaphragm anteriorly and the left lower lobe touches the remainder of it. If the lower lobe is not aerated, the hemidiaphragmatic contour is no longer perceptible and we lose its silhouette (this is the “silhouette sign,” see p. 23–24).

“Silhouette Sign”



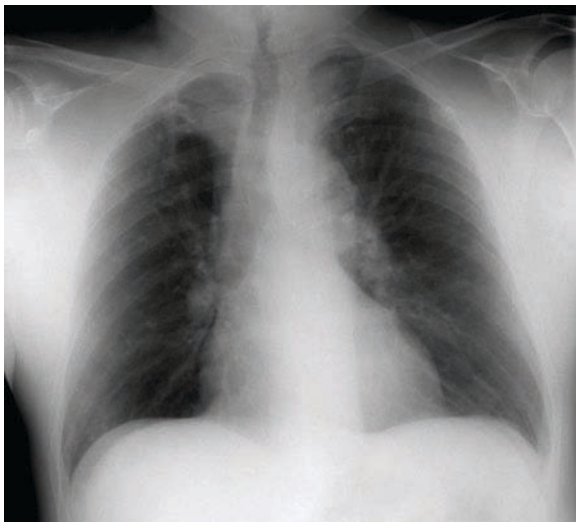
**Fig. 6.2a** The silhouette sign helps us to assign the hemidiaphragms to their correct side. The heart sits on the left hemidiaphragm, which is why the anterior part of the hemidiaphragmatic contour is not visible. Together with the gastric bubble, the splenic flexure of the colon is located underneath the left diaphragm. Got it all lined up? The arrow points to the right hemidiaphragm. Trace its contour back to the right posterior pleural margin and the right costophrenic sulcus. You can now assign pleural lesions such as pleural effusion to their proper side. The inverted comma is drawn for orientation—it corre-

sponds to the left pulmonary artery. Do you recognize the “black hole” that the comma bends around? The major and minor fissures are both easily identified on properly exposed radiographs and they provide clues for orientation in the process of allocating a lesion to a specific lobe. Note how far superiorly the lower lobe extends!

**b** Now go ahead and use your fresh knowledge in the analysis of this image. Which heart valve is calcified in this patient?

It is the mitral valve that is most prominent, but the aortic valve is also visible.

Portable Chest Radiograph: Normal Findings



**Fig. 6.3** This CXR was performed with the patient in bed without a scatter-reducing grid—that is why the inherent image contrast is lower. The mediastinum is compressed, the diaphragm is elevated owing to the increased abdominal pressure. The upper lobe pulmonary vessels are well filled because the hydrostatic pressure in the recumbent patient is similar in the upper lung to the pressure at the lung bases. The superior mediastinum is a little wider than usual in a bedside CXR. Do you need to worry? Have you checked the rotation of the patient?

**Now trace the visible pleural border up to the lung apex:** Is the pleura smooth? Is it fitted tightly to the rib cage or not—as, for example, in pleural scarring, in pleural effusion in a recumbent patient, or in a patient with a pneumothorax?

**Inspect the lung parenchyma:** Is the radiographic density of the lungs homogeneous and symmetric? (Asymmetry may be caused, for example, by freely mobile pleural effusions causing a more radiopaque appearance of the affected side in a supine patient.) Are there increases and/

or decreases in radiolucency (for example, regional over-inflation, opacities)? Can circumscribed opacities be seen (nodules, consolidation)? Do the vessels appear to be sharp and of normal caliber, or are they fuzzy and prominent (as, for example, in pulmonary edema)? Do they branch in a harmonic fashion or like the branches of an old apple tree (as, for example, in emphysema)? Briefly check the position of the minor fissure, the thin pleural leaf that separates the upper and middle lobes on the right side (Fig. 6.1a).

**Have a look at the superior mediastinum:** Is it of normal width? Is the trachea in midline and of normal caliber? Or is the trachea displaced and narrowed (such as in a patient with a goiter)? Does the aortic arch show a normal configuration or is it widened (as can be the case in patients with aortic aneurysm or traumatic pseudoaneurysm)? Is its lateral contour visible (“silhouette sign,” see p. 23–24)? Is the outline of the trachea immediately adjacent to the aortic arch or is there a perceptible separation between these two structures (for example, as caused by enlarged lymph nodes)? Is the azygos vein of normal caliber (approx. 1 cm; Fig. 6.1c), or is it enlarged (as, for example, in superior vena cava obstruction or right heart dysfunction)? Are the tracheal bifurcation and carina normally configured (Fig. 6.1c)? Or do they appear elevated and widened (such as in an enlarged left atrium or enlarged infracarinal lymph nodes)?

**Now let us review the hila:** Is the left hilum about a finger's width higher than the right (due to the left pulmonary artery crossing over the left main stem bronchus)? Or is one of the hila displaced (for example, by loss of volume or scarring in the upper lobe on that side)? Is the aortopulmonary window—the angle between the aortic knob and the left pulmonary artery—empty? Are the hila bilaterally enlarged (for example, in pulmonary hypertension or bilateral lymph node enlargement) or is only one hilum of irregular shape (for example, due to a tumor)?

**Look at the inferior mediastinum:** Is the heart contour of normal size and configuration? The width of the heart may not exceed half the maximum diameter of the chest. Do you see additional shadows projecting over the heart (for example, pericardial calcifications in constrictive pericarditis, coronary or valvular calcifications, metal valve re-

placements, cardiac pacer or defibrillator electrodes)? Are the heart contours visible all around? The right heart contour is adjacent to the middle lobe, the left contour by the “lingula” of the upper lobe of the left lung (these are other potential sites for a “silhouette sign,” see p. 23–24). If the lower left heart contour is rounded and extends far laterally, the left ventricle is enlarged (for example, in cardiac muscular hypertrophy due to arterial hypertension or aortic valve stenosis). If the concavity of the upper left heart contour turns convex, this may be due to pulmonary arterial enlargement in patients with valvular disease or sometimes in patients with severe pulmonary arterial hypertension.

**Observe the heart shadow and the space underneath the diaphragmatic contour:** About one-third of the lung is located in these areas; consequently, about one-third of the pathology also hides there. Try to trace the course of the vessels in the heart shadow and underneath the diaphragmatic domes! In perfect radiographs of perfect patients you can see the anterior and posterior margins of the costophrenic sulci.

**Finish up and check the thoracic wall and soft tissues:** How wide is the soft tissue mantle of the thorax; how muscular, adipose, or edematous is the patient? Is there perhaps a breast missing or are there clips in the axilla in a patient with treated breast cancer? Now analyze the cervical region: Is there any air in the soft tissue (for example, in soft tissue emphysema due to trauma or a leaky chest tube); are the vocal cords visible at the upper end of the trachea (essential to determine the correct position of an endotracheal tube!)?

**Finally have a look at the thoracic skeleton:** A first glance goes to the shoulders and clavicles, the second scans the spine. Then rotate the radiograph by 90° to better appreciate the ribs without your attention being distracted by the heart and lung (Fig. 6.4). Experienced radiologists will applaud this procedure and give you additional points in your oral exam. Now trace every single rib from the spine to its ventral end. Pay attention to discontinuities and irregularities in the rib margins and to soft tissue shadows alongside the ribs: Are variants present such as bifid ribs or do you see fractures, metastases, or destructions due to tumors such as multiple myeloma?

### Checking the Ribs: Normal Findings

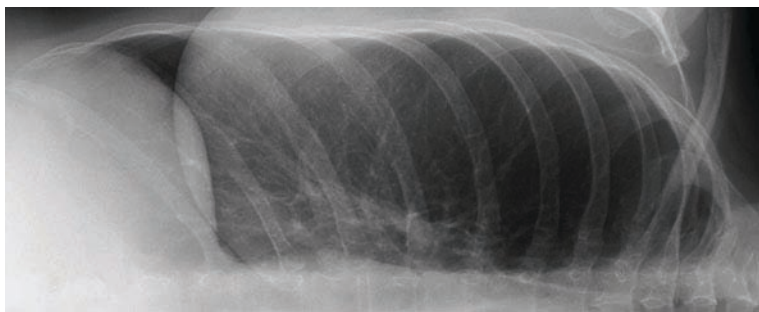


Fig. 6.4 This is how you evaluate the thoracic skeleton best—clockwise or anticlockwise rotation (90°). Trace every single rib over its complete course. For specific bone problems, a dedicated rib series of the affected hemithorax with a different (lower) exposure voltage (approx. 80 kVp) is performed.



## Now Get Additional Information from the Lateral Chest Radiograph

When looking at the lateral CXR, things only get more complicated: both lungs and hila are now superimposed. The first step is to become familiar with the appearance of normal anatomical structures so that you can recognize them on a lateral CXR like good old friends and notice when one is missing.

**Begin with both hemidiaphragms:** Which one is the left hemidiaphragm (see Fig. 6.2a)? Follow the contour of both hemidiaphragms anteriorly, starting at the bottom of the respective posterior costophrenic sulcus. Now trace the posterior pleural border toward the upper thorax. Localize both the minor and the major lobar fissures (by the way, which side was the minor fissure on?).

**Analyze the hila at this time:** The left pulmonary artery swings out of the pulmonary trunk up over the left main stem bronchus, assuming the configuration of an inverted comma. The left main stem bronchus is part of the “black hole” that you see on most films. On a normal CXR, essentially all visible dense structures within the lungs should show a typical vascular, branching course toward the hilum. If that is not the case, you need to explore further.

**What do the heart contours tell you?** The anterior heart contour corresponds to the anterior wall of the right ventricle and is seen behind the anterior thoracic wall, mainly made up of the sternum centrally, which is why this space is called the retrosternal space. If the right ventricular border reaches the mid and upper sternum, the ventricle is enlarged. The posterior heart contour on the lateral CXR corresponds to the left atrium in its upper part and to the left ventricle in its lower part. A small amount of barium swallowed by the patient prior to taking the CXR outlines the course of the esophagus and lets you better appreciate the outline of the atrium if this is of clinical importance.

**Finally put everything else in order:** The contour of the aortic arch is visible throughout most of its course. It runs in a wide arc over the hilum. Atherosclerosis of the aorta is easily appreciated on this projection. The “black hole” mentioned before can help us once more (see Fig. 6.2): If we draw a line from there to the anterior costophrenic sulcus, the aortic valve typically projects superior to the line, the mitral valve inferior to it. Pretty good trick, isn't it? Finally we take a good look at the upper retrosternal space, which should be rather radiolucent because here both lungs meet anterior to the mediastinum. In emphysema this space could be widened; if there is a tumor or goiter present, the space becomes radiopaque.

## I See an Abnormality—What Do I Do Now?

You proceed as systematically as you did during the image analysis described above. First of all the diagnostic thinking needs to be pointed in the right direction!

If the abnormality concerns the **lung parenchyma**, the following questions need to be answered:

- Is it an opacity or an abnormal radiolucency?
- Is it a rather circumscribed or a diffuse process?
- Are we dealing with a solitary lesion or are multiple lesions present?
- Is the lesion homogeneous or heterogeneous?
- Does the diffuse process have a patchy (acinar) or fine linear (reticular) or diffusely nodular pattern of appearance?

If the abnormality is located in the **mediastinum**, it suffices to localize the lesion: hilar region, upper or lower, anterior or posterior mediastinum.

If the lesion is in the **thoracic wall**, any involvement of the ribs needs to be determined.

Additional studies may help to show the lesion more clearly and in more detail; for example, a quick fluoroscopy of a nodule in the central lung or an elevated hemidiaphragm, or an apical lordotic view when dealing with an abnormality in the lung apices (Fig. 6.5). After that the diagnostic approach starts to vary. We will see and exercise this in the respective cases. Now you should be about ready to tackle the first clinical case.

### Hyperlordotic View

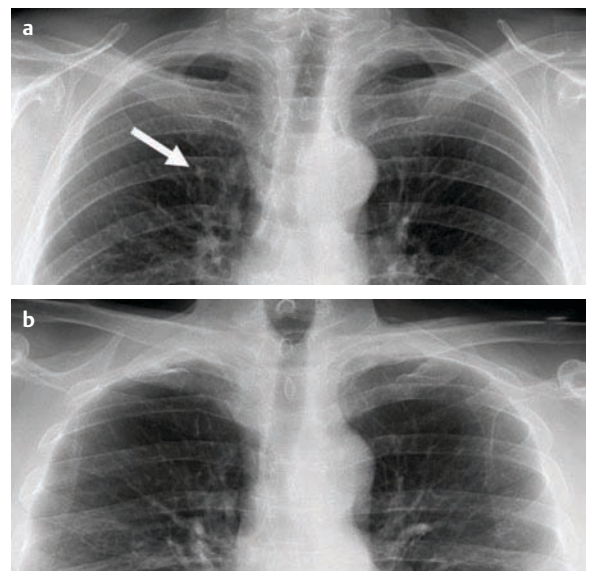


Fig. 6.5a There is a small nodule seen above the right hilum (arrow). Is it a real finding?

b The apical lordotic view shows a normal superior lung (the patient leans back during the exposure and thus elevates the clavicles up over the lung apices). In retrospect the “nodule” must have been a prominent vessel viewed end-on or “down the barrel.”



## 6.2 Opacities in the Lung

### Solitary, Circumscribed Opacity of the Lung

#### Checklist: Singular, Circumscribed Opacity of the Lung

- Is the radiographic appearance of the lesion homogeneous or inhomogeneous?
- Is the margin to the surrounding parenchyma sharp or unsharp?
- Is its contour smooth or irregular, straight or lobulated?
- Are any interfaces to adjacent structures (diaphragm, heart contour, aortic arch) obscured?
- Does the lesion displace its neighboring tissues or cause loss of volume with resulting shift of adjacent structures toward the lesion?

#### All of a sudden—a spot in the lung

Sidel Zastro (78) has come into the hospital to get his inguinal hernia repaired. Since he has not really felt well for the past months (he has not enjoyed his cigars the way he used to) and since he has got some mileage on him, a preoperative chest radiograph is performed. With a patient of this age, Paul anticipates seeing some traces of a life gone by—long, exhaustive work, war, malnutrition, diseases, smoking, surgery, and vice of any kind may leave their traces in the thorax of an individual. He expects apical (Fig. 6.6a) and possibly basal pleural adhesions, irregular vascular markings

such as in old age emphysema, and possibly some scarring due to past pneumonias (Fig. 6.6b). Mr. Zastro did not, of course, bring previous films—why on earth should he have bothered? He last saw the inside of a hospital 30 years ago. Paul and Joey study the CXR (Fig. 6.7) together, following the analysis scheme outlined above (see p. 40, 43–46).

→ **What Is Your Diagnosis?** Paul has discovered that the right basal lung isn't as radiolucent as it should be. Or could that be a delusion? In a woman, removal of the breast on the other side could sometimes give rise to this appearance, argues Joey. How about a chest wall anomaly? The x-ray technician says the patient's chest looked normal to her. Should one consider an emphysematous overinflation of the left basal lung in a patient of this age? In that case the vessel markings should be irregular and decreased, which is not what Paul and Joey see. Both finally agree that the true abnormality is at the right lung base. They go ahead and answer all the key checklist questions one by one:

**Is the internal structure of the lesion homogeneous or inhomogeneous?** *Lesions with homogeneous internal structure:* In this case the parenchyma is devoid of air. A solid tumor will replace alveoli and bronchi with tumor tissue (Fig. 6.8). In a pleural effusion, whether mobile (Fig. 6.9a) or loculated (Fig. 6.9b), the lung is intact but displaced away from the abnormality. In endobronchial obstruction, the air distal to the point of obstruction is resorbed—a postobstructive atelectasis results (Fig. 6.10).

#### A Chest Radiograph Appropriate for Age

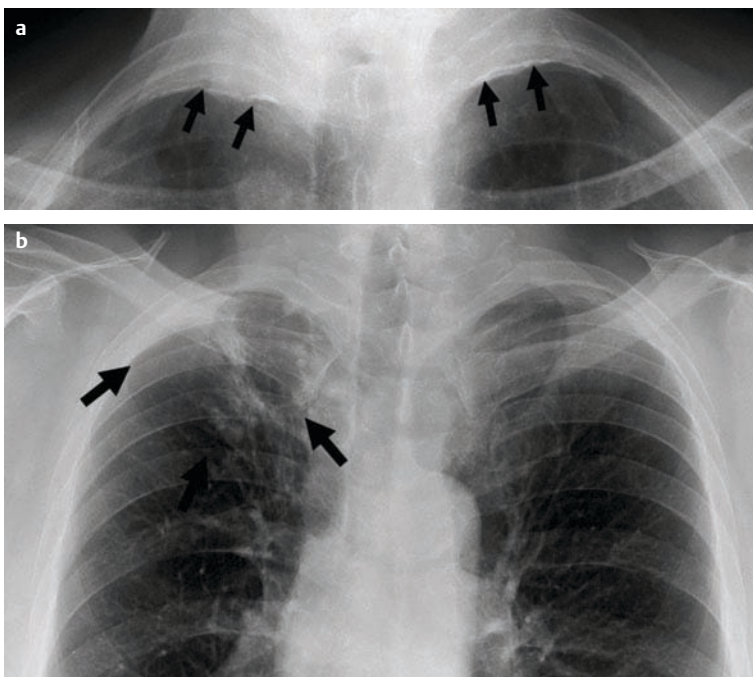


Fig. 6.6a During the course of the usual pulmonary infections of a long life, this patient has developed apical pleural scarring with some calcifications (arrows). No need to get excited—this finding is appropriate for age. b This elderly gentleman must have experienced a severe pneumonia that left a large area of scarring (arrows). Could a bronchial carcinoma hide in there? Of course! Any pulmonary scar may turn malignant (“scar cancer”). It is only the careful comparison with previous films that gives you sufficient certainty. The patient will possibly reassure you by telling you that he has had a scar in his lung for years. He may, however, not realize that there has been a change in size or appearance since the previous radiographs.

### The Case of Sidel Zastro

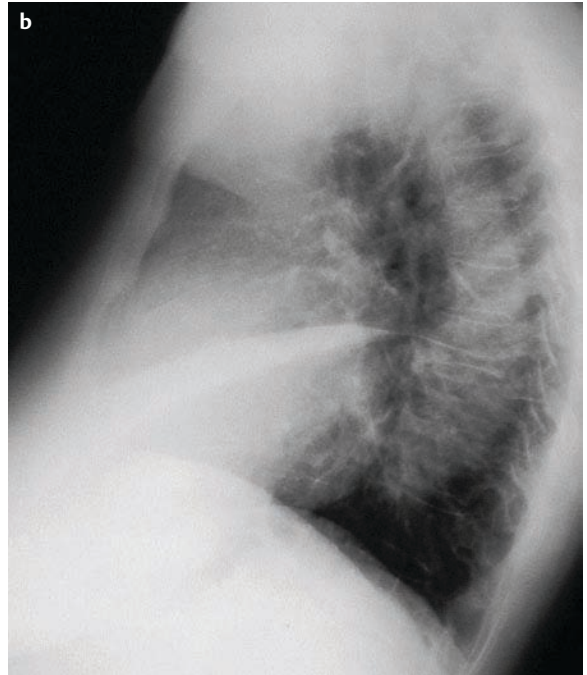
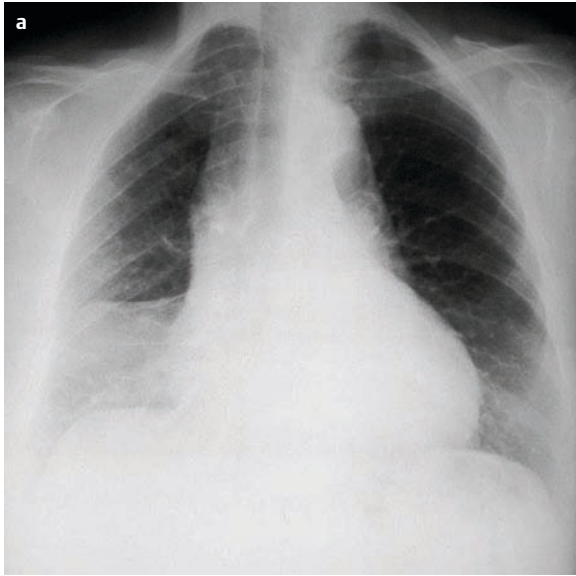


Fig. 6.7 Have a look at the CXRs of Sidel Zastro. Anything remarkable?

### Bronchial Carcinoma

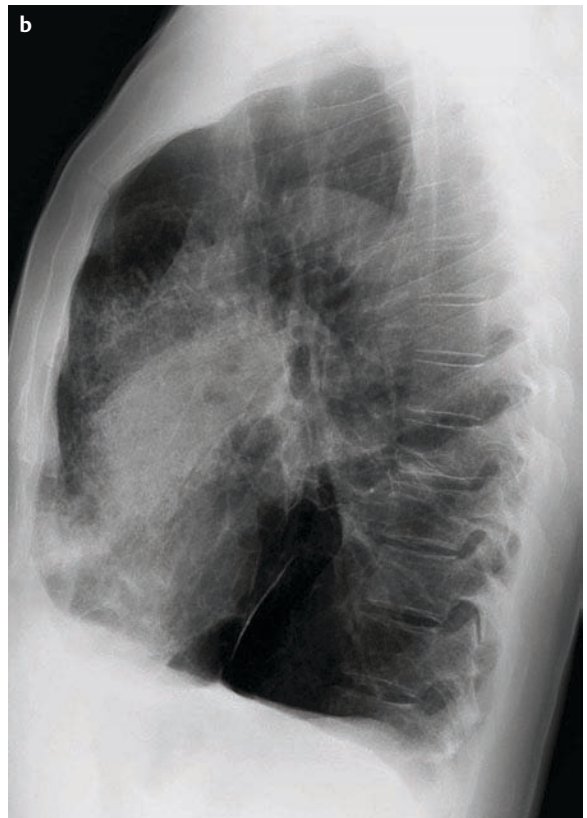
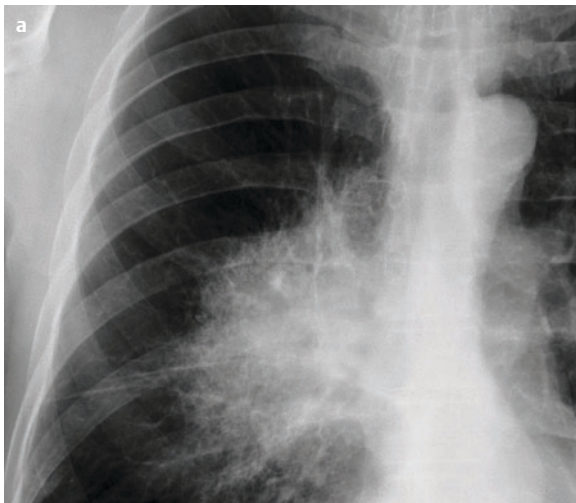
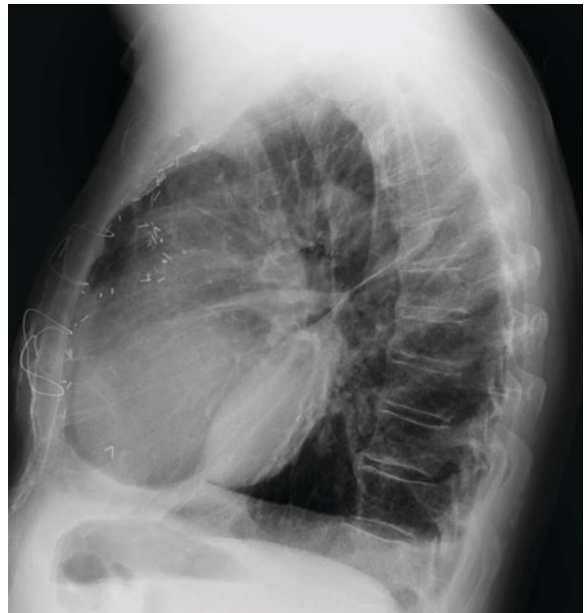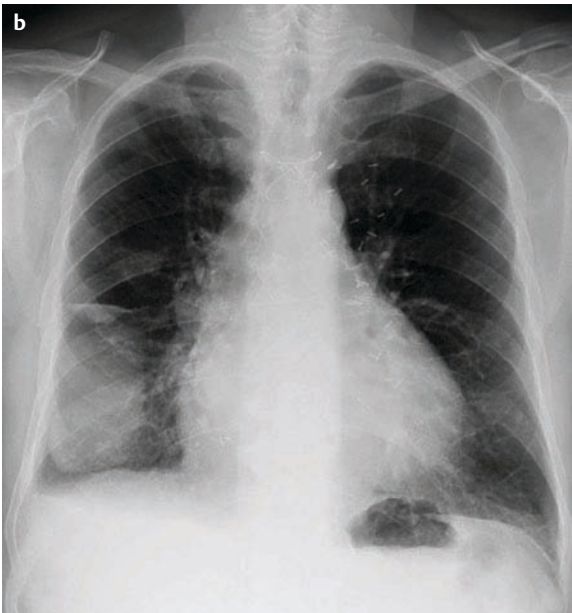
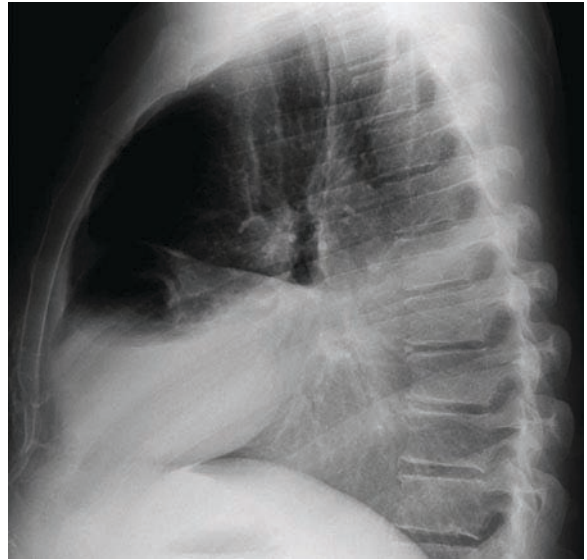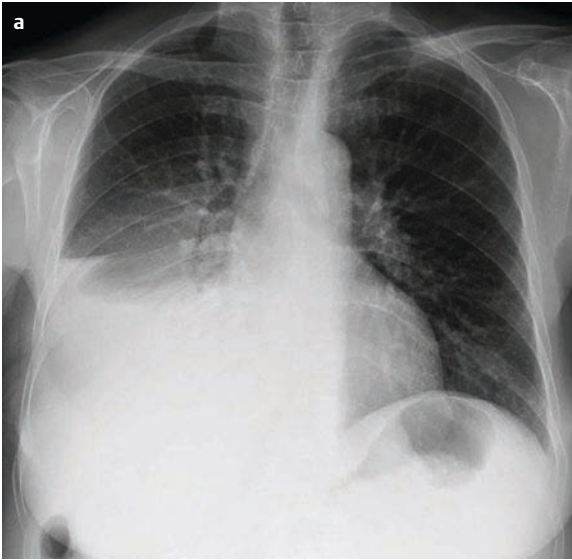


Fig. 6.8 **a** The tumor has a relatively homogeneous internal structure because there are no aerated components. Its margins are irregular. You appreciate the pulmonary parenchyma overlying the tumor. Where is the tumor? In the lower or middle lobe? **b** On the lateral view of the patient you recognize the complete situation: the middle lobe (search for the minor and major fissure!) is homogeneously opacified and shows volume loss—the minor fissure ascends too steeply and runs too far inferiorly. This configuration is typical of atelectasis. Superiorly to the minor fissure the opacity continues, however. There it has an unsharp and irregular margin. In this patient a carcinoma developed in the middle lobe, led to atelectasis, and then continued to invade the neighboring lung tissue.



## Pleural Effusion



**Fig. 6.9a** Note the large right-sided pleural effusion, which obscures any internal structures (it is homogeneous). The middle lobe floats in it; the upper and middle lobes are compressed by the fluid in the pleural cavity. In the left mid-lung close to the hilum (left) you see a dark branching structure—that is the air bronchogram of the middle lobe bronchus surrounded by compressive atelectasis.

**b** In this patient a previous large pleural effusion has been absorbed except for some residual fluid at the base (left) and some loculated fluid along the course of the minor fissure (right). This interlobar effusion can persist and scar down over time.

*Lesions with inhomogeneous internal structure:* These must be analyzed further. Do you see tubular, branching structures of radiolucency, that is, air bronchograms (Fig. 6.11a)? In pneumonia the alveoli fill with pus and exudate while the larger bronchi remain air-filled in the initial phase. For that reason they suddenly become visible against the backdrop of the airless surrounding alveoli (Fig. 6.11b). If the

alveoli are filled with fluid from the interstitium, for example, in edema (Fig. 6.12), or with blood, for example, in a lung contusion (see Fig. 14.6, p. 313), the same phenomenon develops. If the lung is compressed from the outside, for example, by a large pleural effusion, the alveoli collapse while the bronchi stay open owing to the relative rigidity of their walls: compression atelectasis is the end result (Fig. 6.9a).

### Postobstructive Atelectasis

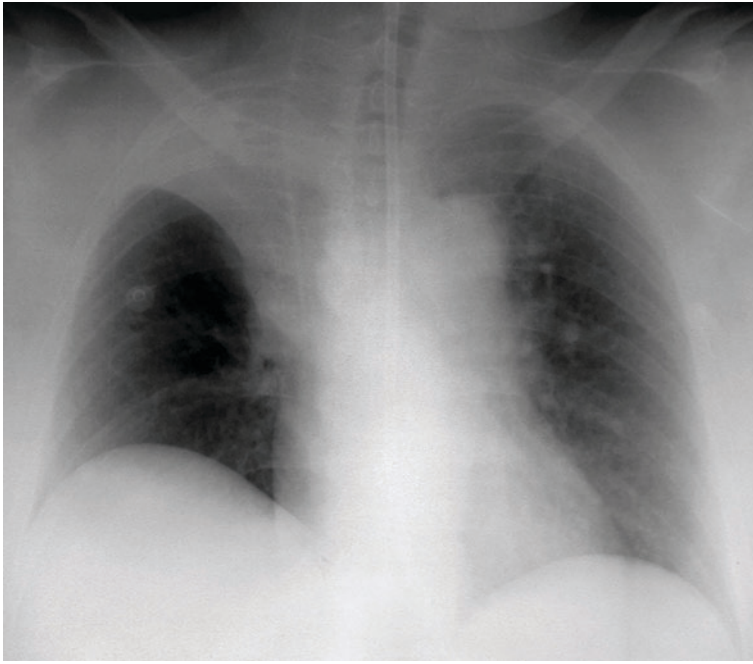


Fig. 6.10 The opacity of the right upper lobe has a homogeneous internal structure. The minor fissure and the hilum are displaced superiorly, which points to a volume loss. The upper lobe bronchus is obstructed and a postobstructive atelectasis has developed. The air in the alveoli and the bronchi has been absorbed.

### Pneumonia

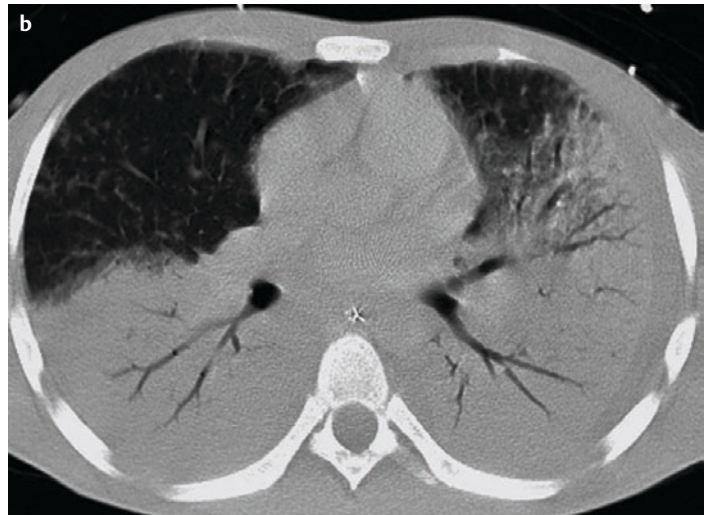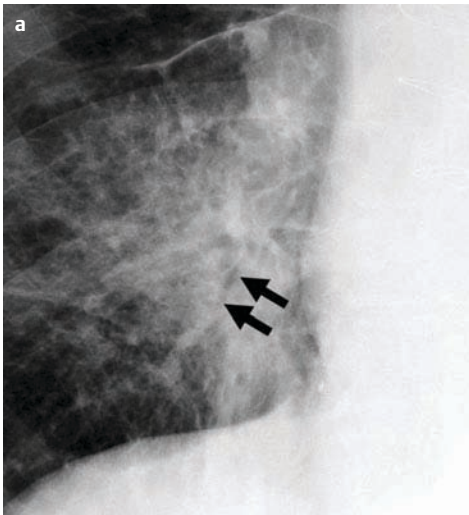


Fig. 6.11 **a** An air bronchogram in a lower lobe pneumonia (arrows). Could a cancer look like that? Unfortunately yes! The bronchoalveolar carcinoma tends to destroy the alveoli first and leaves the bronchi open initially. The complete resolution of any “pneumonia” type infiltration must therefore be docu-

mented radiologically once treatment has been completed, especially in the elderly. **b** In this boy a severe pneumococcal pneumonia has necessitated treatment in the intensive care unit. The alveoli are filled with pus; the bronchi can be traced far into the periphery.

Space-occupying lesions of the lung can also become partially necrotic. If necrosis reaches the bronchial tree, some of the necrotic tissue may be coughed up and air may enter the ensuing cavity (Fig. 6.13a). The contents of a necrotic lesion can be spread along the bronchial

tree (Fig. 6.13b). Almost all infections, especially tuberculosis, can form cavities. But malignant tumors may do the same thing (Fig. 6.14). If the infectious cavities heal, their wall thickness may decrease and they can turn into cysts. Naturally these dark, warm, and humid spaces provide



## Alveolar Lung Edema

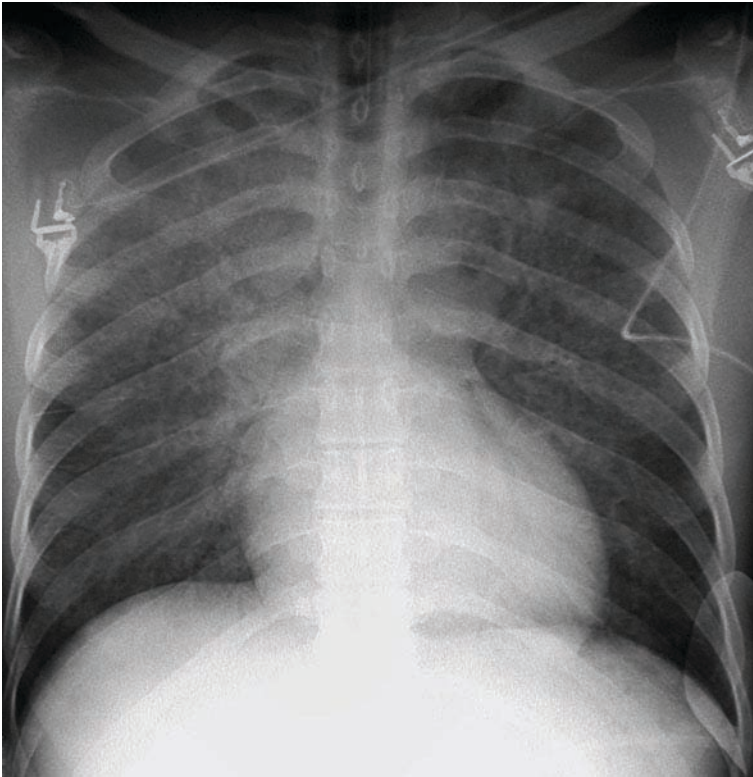


Fig. 6.12 This is the CXR of a polytraumatized patient who received large quantities of intravenous fluid replacement within a short period of time to treat his severe blood loss. It ended up being a little too much of a good thing: The symmetrical opacification of both central lungs with air bronchograms indicates an alveolar pulmonary edema. The minor fissure is prominent, the bronchial walls are thickened, and the interlobular septae, particularly in the periphery of the right base, are well appreciated (Kerley B lines). This is an indication that there is also fluid deposition in the pulmonary interstitium. Conclusion: They'd better get the kidneys to work quickly.

## Tuberculosis

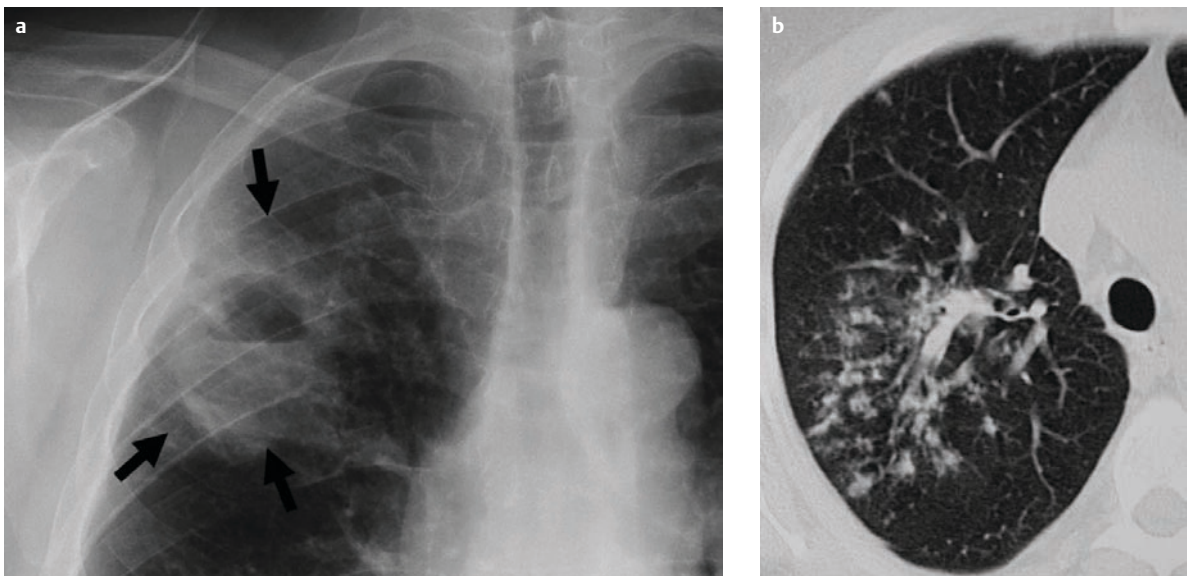


Fig. 6.13 **a** Here we see a consolidation with a central lucency (arrows), indicative of a cavity. This radiograph of a young prison inmate sent the whole chest unit team into a flurry. Before the urgently summoned Gregory had a chance to declare "Hey, mates, this is one hell of a full-blown tuberculosis," the chest unit room had already been sealed and the disinfector been called by the young tech in charge. A rather typical finding,

indeed. The prison guards who accompanied the man immediately got themselves an appointment for a check-up with their own physicians.

**b** This CT demonstrates beautifully what else happens when the cavity erodes into the bronchial system: Infectious material is distributed all over the bronchial system and initiates satellite lesions.



### Bronchial Carcinoma

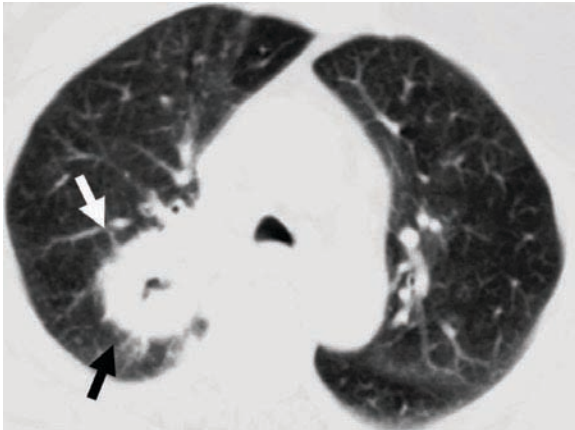


Fig. 6.14 This bronchial carcinoma (arrows) has turned necrotic in its center and eroded a bronchial wall vessel. The patient is coughing up blood—that was his first symptom.

perfect growing conditions for fungi (Fig. 6.15), which can superinfect a preexisting cavity.

Finally one has to realize that a CXR is a two-dimensional projectional image of a three-dimensional object. Several superimposed anterior and posterior pulmonary opacities can create the visual impression of a single inhomogeneous infiltrate when in fact there are multiple focal ones. This can be the case in inflammatory and neoplastic processes.

**Does the lesion have a sharp or unsharp border?** The margin tells us something about the localization and type of the lesion. Borders that are smooth and straight at the same time are often formed by an adjacent fissure (see Fig. 6.10). If you recognize the involved fissure, you know which lobe the lesion most probably occupies. If the lesion has a smooth interface with the thoracic wall, first check whether there is a pleural effusion or whether the ribs are destroyed. If the borders toward the thoracic wall and toward the lung are smooth, a pleural process such as a loculated pleural effusion or a lipoma (Fig. 6.16) might be present.

**Is the contour regular or irregular, straight, or lobulated?** A lobulated, relatively sharp contour is found in many pulmonary nodules, for example, in metastases (Fig. 6.17). An irregular, pointed, and jagged margin implies a disturbance of the surrounding pulmonary parenchymal architecture and is seen not only in primary pulmonary tumors, for example in bronchial carcinoma (Fig. 6.18), but also in infections.

**Are any of the physiological air–soft tissue interfaces (diaphragm, heart border, aortic arch) obliterated?** Normal interfaces between soft tissue structures like the diaphragm, the heart and the aortic arch on the one hand and the air-filled lung on the other hand disappear if the adjacent lung loses its air content at the site of contact (see p. 23–24, 44). This phenomenon, also called “silhouette sign,” allows assignment of the location of underlying radiopaque lesions to certain areas of the chest:

### Aspergilloma

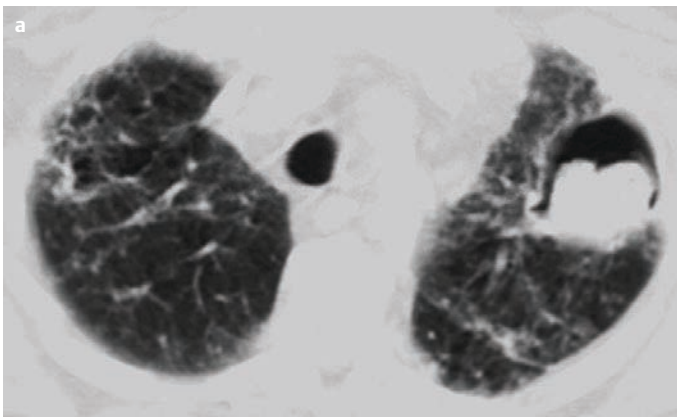
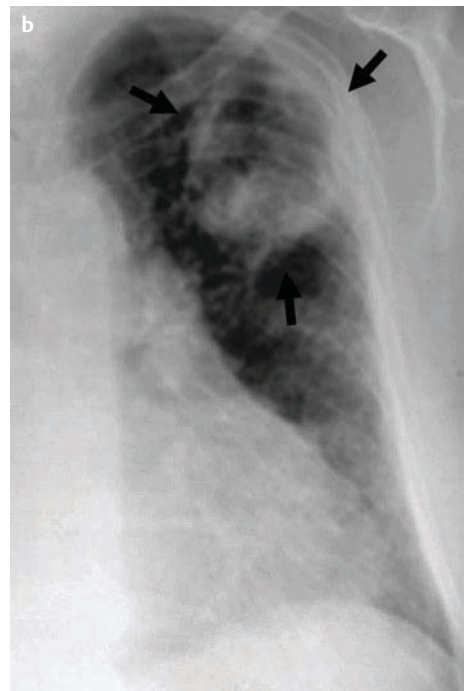
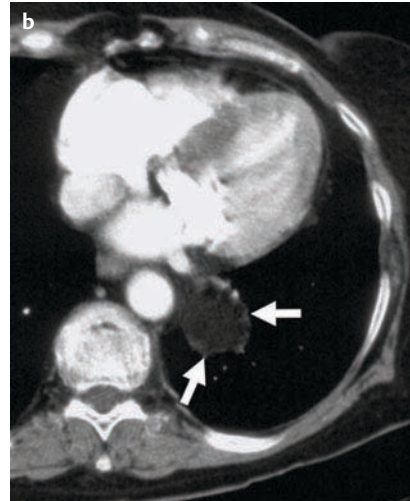
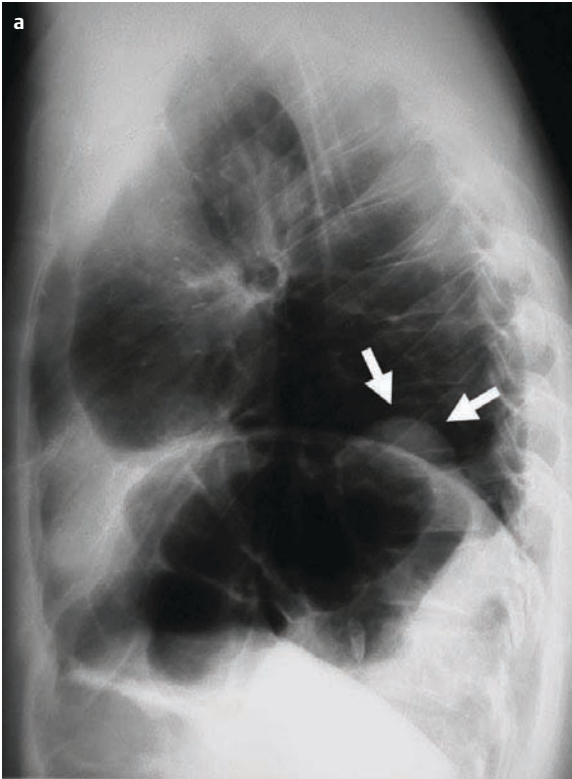


Fig. 6.15 **a** This patient has interstitial lung disease associated with bullae due to previous asbestos exposure. One of the bullae has been colonized by *Aspergillus*.

**b** Under fluoroscopy the fungus ball (arrow) can be seen rolling around in the bulla! A stellar moment for any radiologist and the pathognomonic sign of an aspergilloma.



## Pleural Lipoma

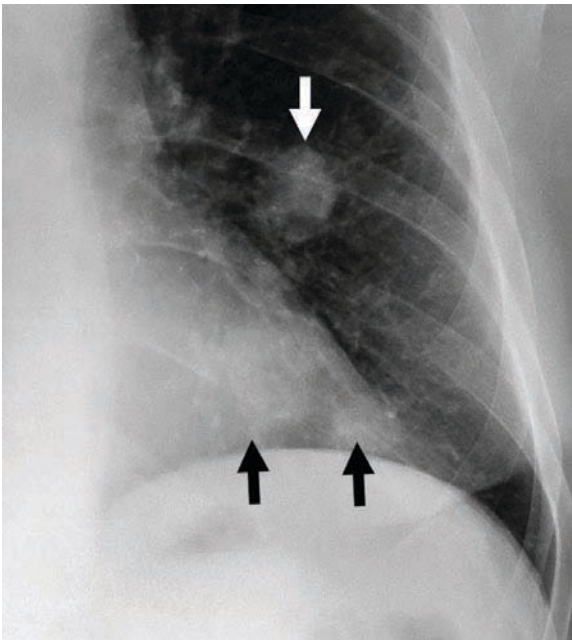


**Fig. 6.16 a** This tumor (arrows) adjacent to the diaphragm (left or right hemidiaphragm?) was found on the occasion of a preoperative chest check-up. It has a smooth margin and is not associated with a pleural effusion. It looks pretty benign.

It is the left hemidiaphragm. The air in the colon directly underneath proves this point.

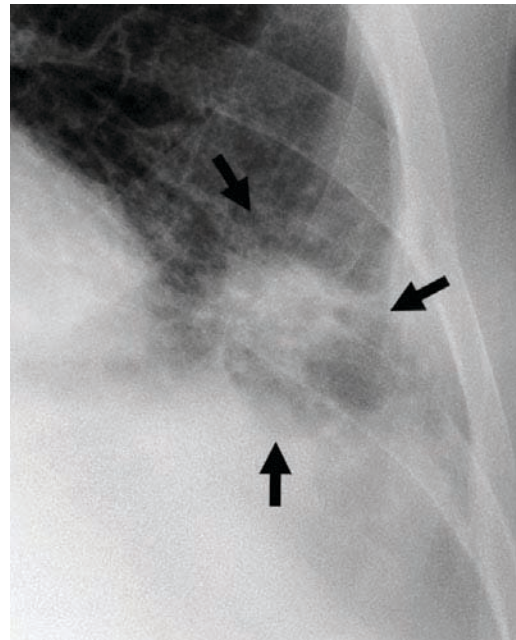
**b** CT confirms the benign character of the lesion: The tumor (arrows) clearly exhibits fat density (compare the density of the subcutaneous fat!). It is a lipoma.

## Metastases



**Fig. 6.17** This is what typical metastases (arrows) look like: multiple round nodules with relatively sharp margins surrounded by pulmonary parenchyma.

## Bronchial Carcinoma



**Fig. 6.18** This bronchial carcinoma (arrows) has a spiculated border. The tumor invades and distorts the surrounding pulmonary parenchyma in the process (see also Fig. 6.8a).

## Atelectasis

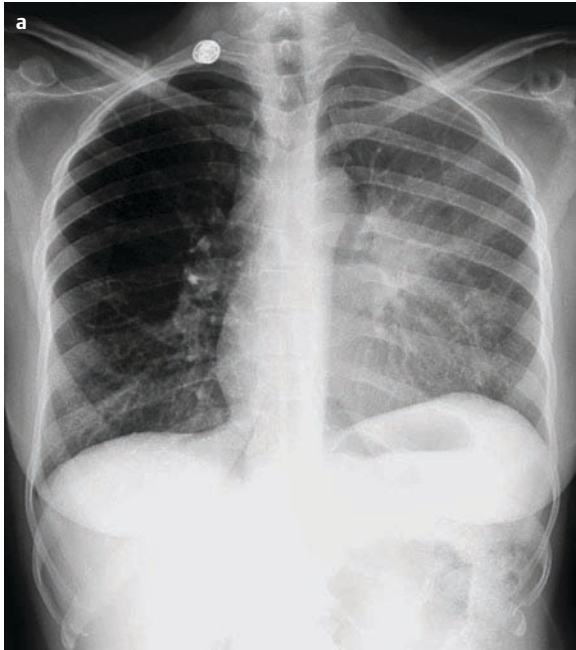
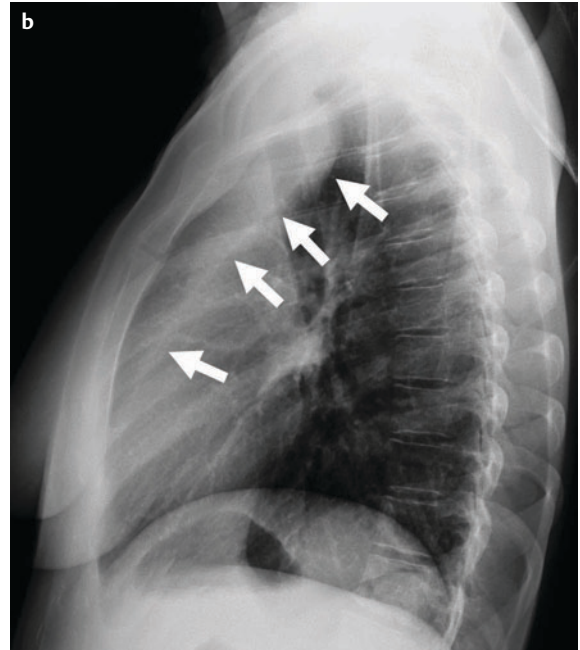


Fig. 6.19 **a** The opacity seen on the CXR obliterates the interface between the left heart and the left lung—which means that it is located in the upper lobe. It demonstrates a homogeneous internal structure indicating that it is airless and it shows asso-



ciated volume loss in the affected lung (the left hemidiaphragm is elevated). **b** The lateral view confirms a dense stripe retrosternally (arrows). This is compatible with left upper lobe collapse (complete lobar atelectasis).

- Loss of the left or right lower heart border: anterior location, middle lobe (right) or lingula (left)
- Loss of definition of the aortic arch contour: mid chest, left upper lobe
- Loss of the contour of the descending aorta and/or the paravertebral soft tissue shadow: dorsal location, lower lobe.

Now you can go ahead and apply your new knowledge to Fig. 6.19a. Where is the pathological finding?

**What is the volume effect of the lesion?** The volume effect is of special relevance. The displacement of surrounding structures (for example, the fissures, the diaphragm, the mediastinum) toward the lesion implies a *loss of volume*: a loss of lung aeration (atelectasis, Fig. 6.19) or scarring (see Fig. 6.6b) causes this behavior, but a slow-growing tumor or a chronic infection may also lead to this phenomenon. An *increase in volume* would point toward an acute infection or a quickly growing tumor (see Fig. 6.8a).

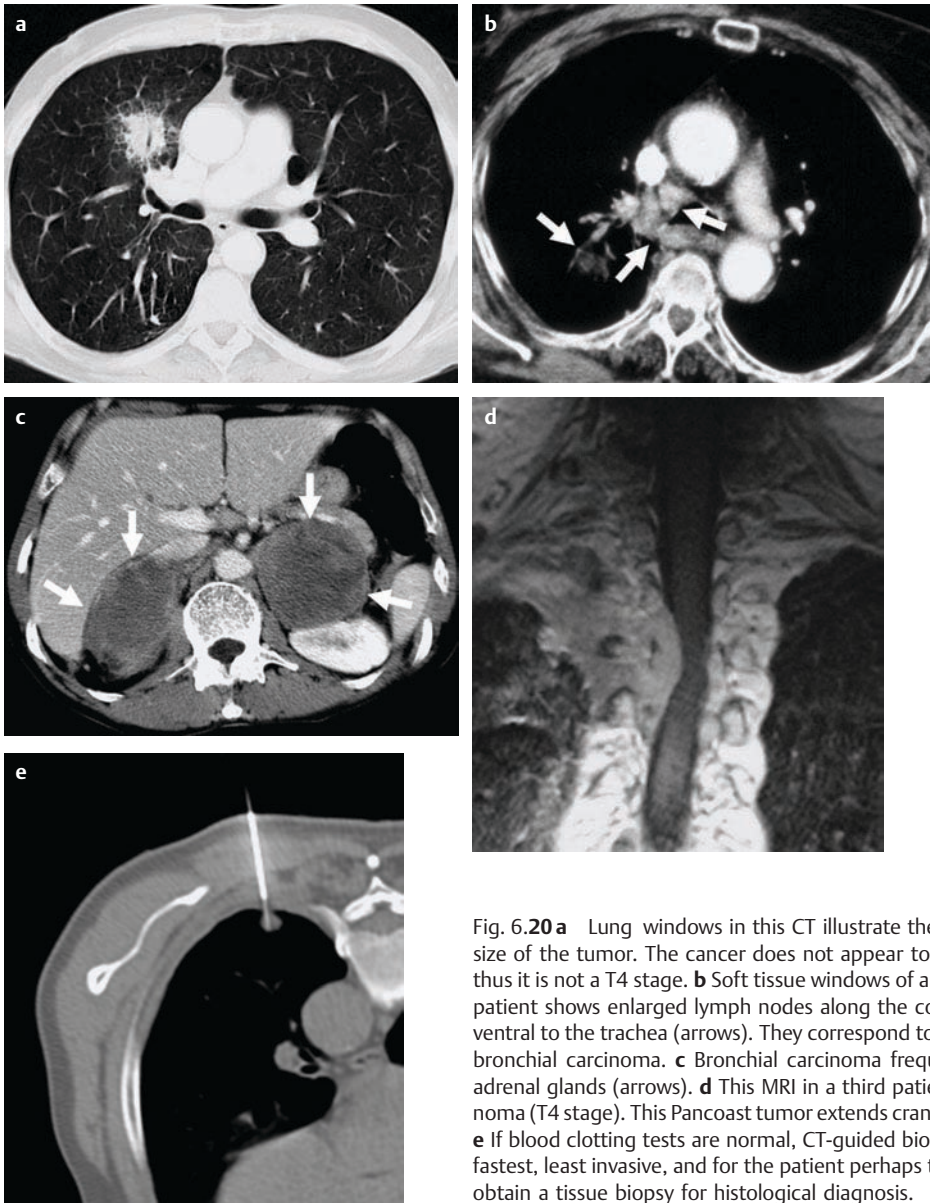
→ **Diagnosis:** Paul and Joey have got it all figured out. Mr. Zastro's temperature is normal. The internal structure of the lesion is homogeneous in their opinion. The contour is sharp and straight: it is the minor fissure. The right heart contour is obliterated. The lesion seems to decrease volume rather than increase it. They have made up their mind: it is obstructive atelectasis of the middle lobe. As they want to go ahead and call up Mr. Zastro's doctor, Greg, the senior resident in neuroradiology, trots by in

his search for Giufeng and stops the students: "Do you think you're done just because Mr. Zastro has an atelectasis? Always think of a bronchial carcinoma in this age group! Look at the hilum again and analyze it carefully, then go ahead and search the lymph node stations." Together they scrutinize the aortopulmonary window, the azygos angle, and the carina underneath the tracheal bifurcation. Nothing! Greg leaves them grumbling. A bronchoscopy will be necessary to find the cause of the obstruction and to verify it histologically.

Should a bronchial carcinoma be the cause a chest CT would be needed to stage the tumor correctly following the TNM system and to determine operability as well as the optimal chemotherapy regimen (Fig. 6.20a, b). Some will have this CT done even before the bronchoscopy is performed in order to give better orientation to the bronchoscopist. In any case, this CT should—as a rule—include the upper abdomen to the adrenal glands (Fig. 6.20c) because they are a frequent and early location of metastases. Rarely a special MR study is necessary (Fig. 6.20d). If tumor tissue cannot be gathered at bronchoscopy, a core needle biopsy may be attempted under CT guidance (Fig. 6.20e).



## Staging in Bronchial Carcinoma



**Fig. 6.20 a** Lung windows in this CT illustrate the spiculated contour and the size of the tumor. The cancer does not appear to infiltrate the mediastinum—thus it is not a T4 stage. **b** Soft tissue windows of a CT obtained from a different patient shows enlarged lymph nodes along the course of the azygos vein and ventral to the trachea (arrows). They correspond to an N2 stage of a right-sided bronchial carcinoma. **c** Bronchial carcinoma frequently metastasizes into the adrenal glands (arrows). **d** This MRI in a third patient depicts a bronchial carcinoma (T4 stage). This Pancoast tumor extends cranially and into the spinal canal. **e** If blood clotting tests are normal, CT-guided biopsy with a core needle is the fastest, least invasive, and for the patient perhaps the most comfortable way to obtain a tissue biopsy for histological diagnosis.

**Obstructive Atelectasis in Children**

Children also develop postobstructive atelectasis. Causes differ from the adult population, however: foreign bodies and mucous plugs are more common. Typical foreign bodies in toddlers are glass eyes chewed off of the favorite teddy bear or aspirated peanuts that have just the right caliber to block the trachea or a main bronchus. By the way, children in the Netherlands know just what to do to decrease this risk: As a rule of thumb, any kid who manages to reach over his or her head and insert a finger into the opposite external ear canal may eat peanuts. As you can see, Philipp may enjoy peanuts, but Paula is not ready for them yet. Her airways do not have a large enough caliber.



**!** The times of a purely “contemplative” radiology have definitely passed. The analysis of a finding is essential, but the next diagnostic or therapeutic step should always be considered. Try to reach conclusions that directly improve the patient’s management in terms of time needed to diagnosis and recovery. Getting the patient back on the right track with minimally invasive diagnosis and therapy—that is the goal!

## Multiple Lesions in the Lung

### Checklist: Multiple Lesions in the Lung

- Do the lesions have sharp or unsharp margins?
- Are they calcified or ossified?
- Are they solid or necrotic?
- Do you know the age, history, and symptoms of the patient?

### And There Are More and More Every Month

Isadora Pumpkin (65) has been feeling unwell and depressed for a few months. She has lost some weight and her primary care physician has diagnosed anemia. He has sent her for a thorough diagnostic check-up. The ultrasound of the abdomen has been unremarkable. Joey and Ajay are hanging out in the chest imaging unit and are the first to review Mrs. Pumpkin’s CXR (Fig. 6.21). The finding is obvious: multiple nodules in both lungs. They discuss the relevant differential diagnoses.

### → What Is Your Diagnosis?

**Metastases:** The most frequent multiple lesions in the lung are, of course, metastases (Fig. 6.22). They tend to be round and sharply demarcated (see Fig. 6.17). Breast, kidney, and colon cancers as well as carcinomas of the head and neck region are the most frequent primary tumors to give rise to metastatic involvement of the lung; in young men testicular cancer takes the lead as source of pulmonary metastases. Some types of tumors show specific characteristics: osteosarcomas, for example, have a tendency to ossify, not only at the primary site but also their metastases. Multiple ossifying pulmonary nodules are therefore almost pathognomonic for this tumor in the respective—unfortunately often young—patient group (Fig. 6.23).

### The Case of Isadora Pumpkin

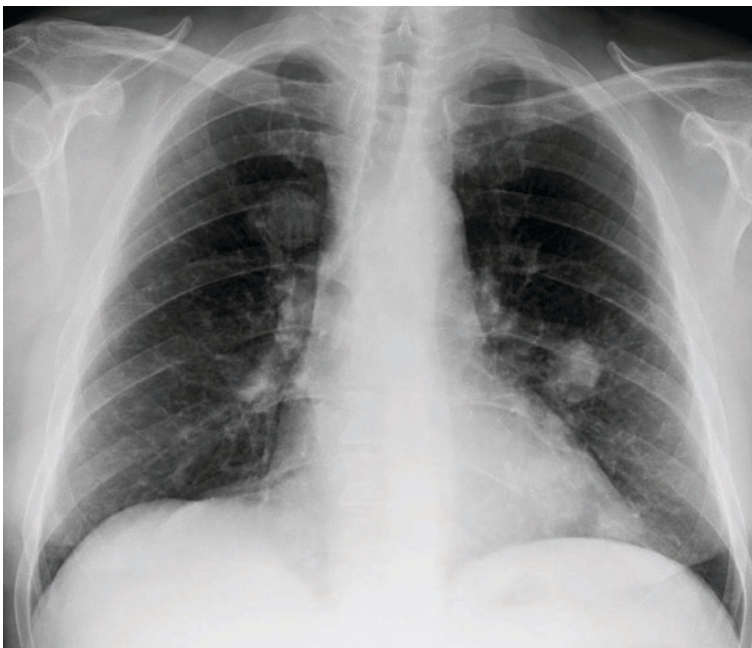
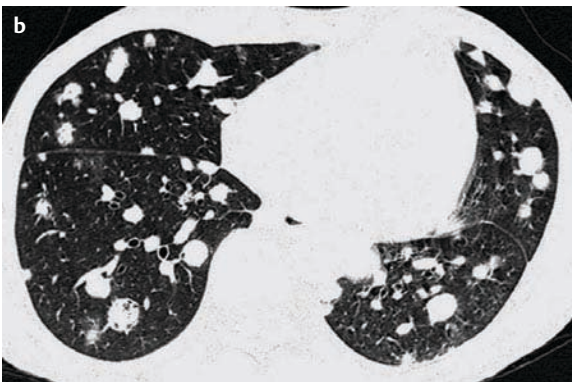
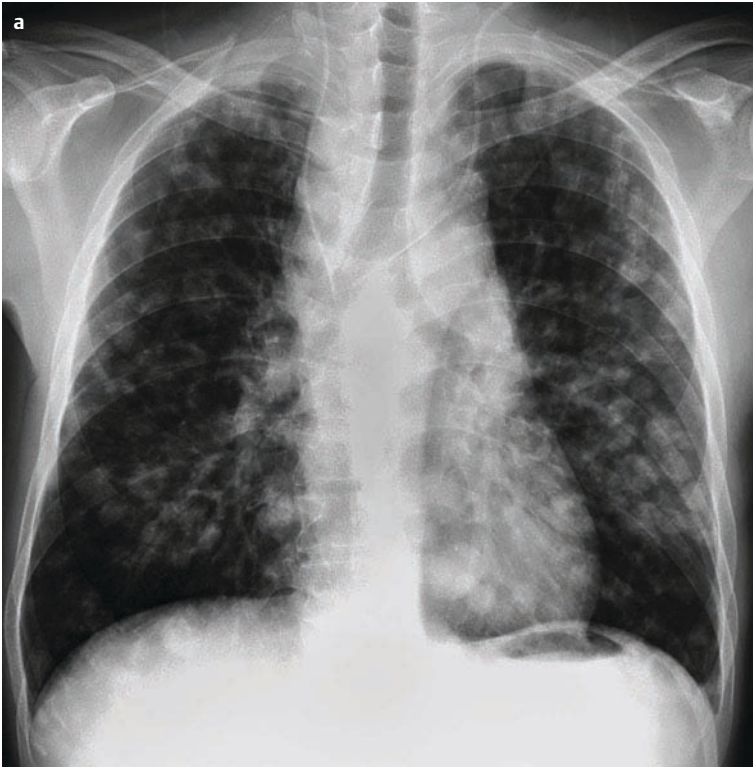


Fig. 6.21 This is the CXR of Mrs. Pumpkin. Which diagnoses do you consider?

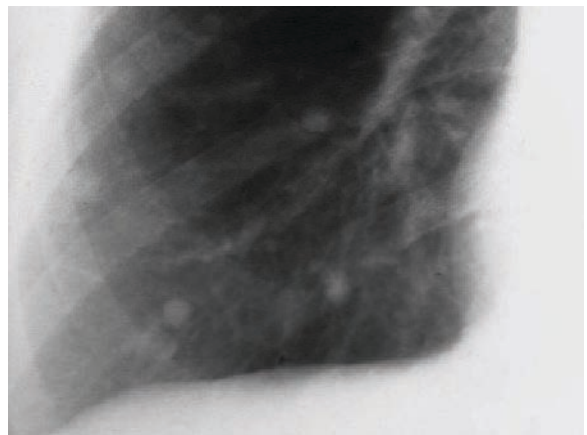


## Metastases of Testicular Carcinoma



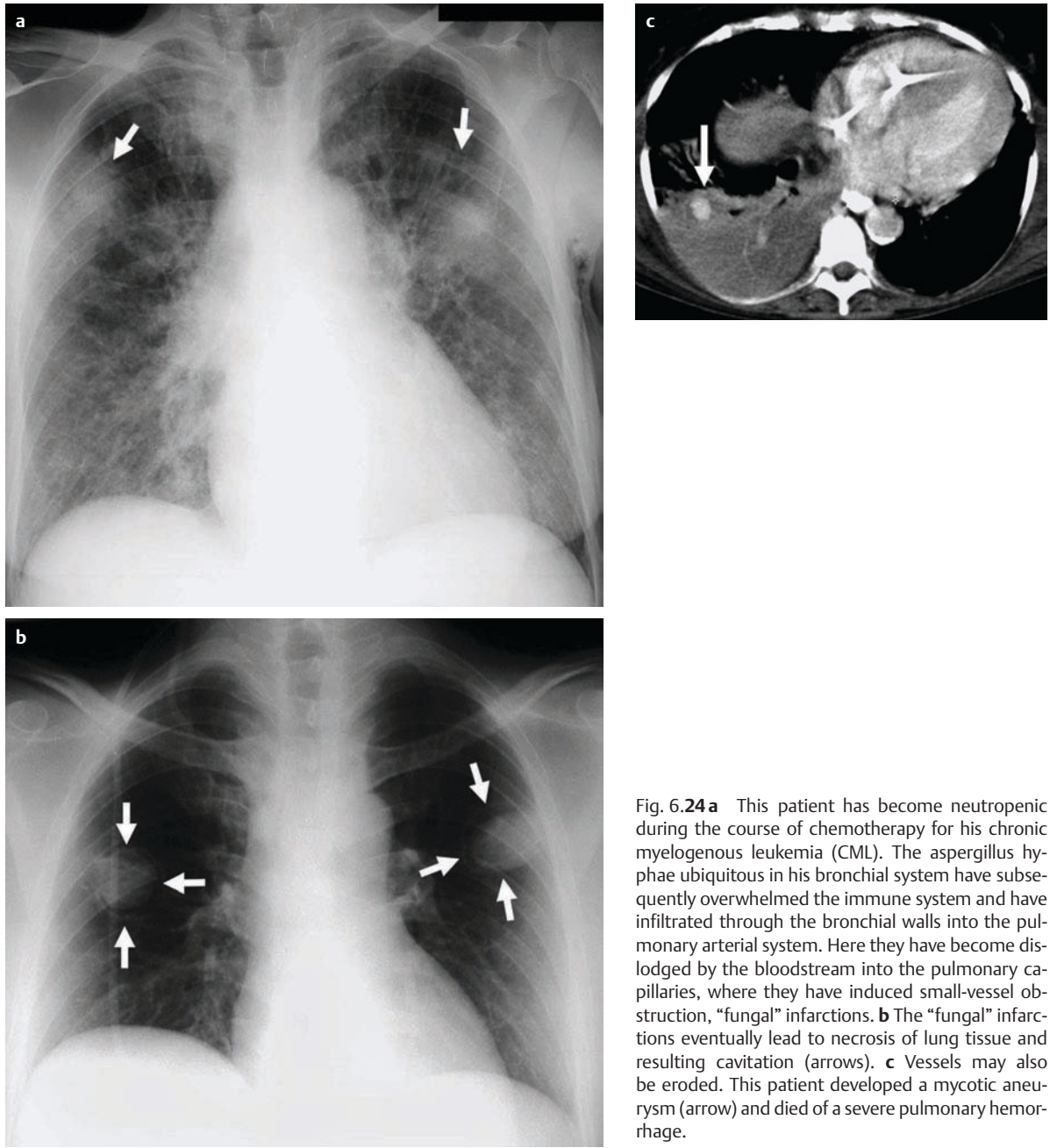
**Fig. 6.22 a** You see the horrific findings on a CXR of a young man with a history of testicular carcinoma. Metastases of up to walnut size are observed scattered throughout the lungs. Take note of the nodules projecting over the heart shadow and underneath the diaphragmatic contour. You have to search there, too! Have you noticed the widening of the upper mediastinum? The aortopulmonary window and the azygos angle are filled with enlarged lymph nodes. The paratracheal stripe is widened considerably for the same reason (compare Fig. 6.1). **b** With just a little luck these masses will all but disappear with modern combination therapy and only a few scattered scars will remain.

## Metastases of an Osteosarcoma



**Fig. 6.23** The nodules in this lung are rather dense—denser than the rib intersections! The increased density suggests ossification; in a 17-year-old an osteosarcoma is an unfortunate but likely diagnosis. Of course, calcified granulomas following an infection with tuberculosis can also be very dense. However, we tend to expect them in older patients or in patients from endemic areas.

### Septic Emboli Caused by Fungal Infection

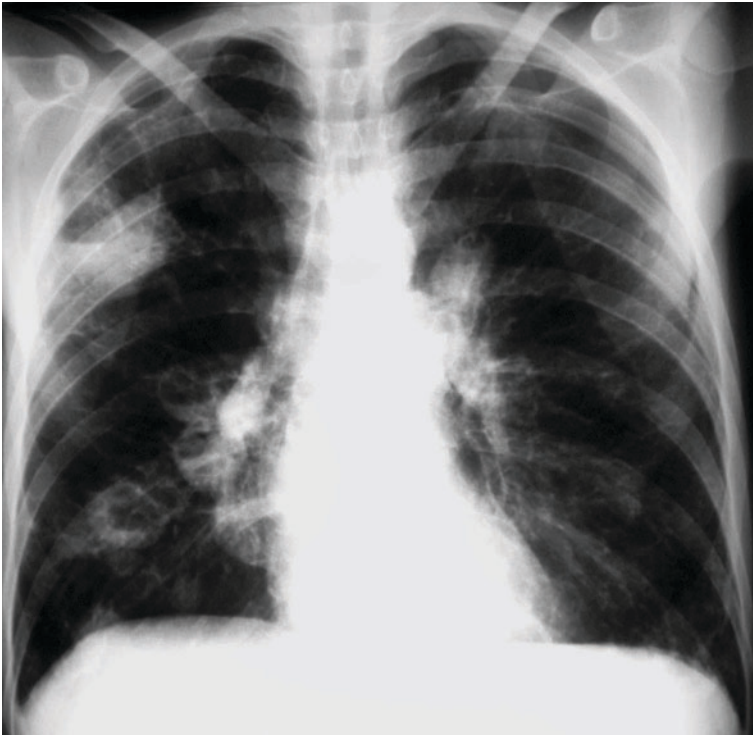


**Fig. 6.24 a** This patient has become neutropenic during the course of chemotherapy for his chronic myelogenous leukemia (CML). The aspergillus hyphae ubiquitous in his bronchial system have subsequently overwhelmed the immune system and have infiltrated through the bronchial walls into the pulmonary arterial system. Here they have become dislodged by the bloodstream into the pulmonary capillaries, where they have induced small-vessel obstruction, “fungal” infarctions. **b** The “fungal” infarctions eventually lead to necrosis of lung tissue and resulting cavitation (arrows). **c** Vessels may also be eroded. This patient developed a mycotic aneurysm (arrow) and died of a severe pulmonary hemorrhage.

**Septic emboli:** Septic emboli can also give rise to multiple nodules in the lungs. They tend to become necrotic centrally. If, for example, the mitral valve is colonized with bacteria in endocarditis, some of the vegetations can be dislodged into the lung vasculature and settle in the pulmonary parenchyma. In immunosuppressed patients (cancer, transplantation, long-lasting corticosteroid therapy, HIV infection), ubiquitous fungi such as *Candida albicans* and *Aspergillus* can invade the vessels and settle in the

parenchymal periphery, causing life-threatening infections of the lung (Fig. 6.24). The reasons for septic emboli can be bizarre. In drug addicts the injection of contaminated material can cause multiple infections and abscess formations in the lung (Fig. 6.25). Whether you will see them in your life greatly depends on the type of community you work in (inner cities, etc.) and the existence of clean needle programs in that community.

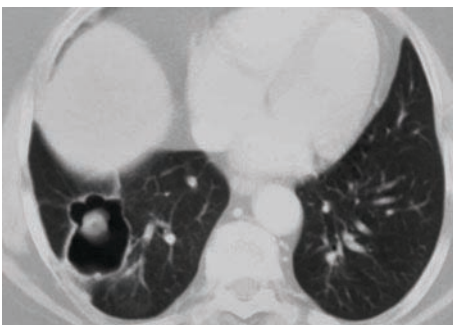
### Septic Emboli in Intravenous Drug Abuse



**Fig. 6.25** This young drug addict was brought into the emergency ward absolutely run-down and severely sick, straight from some abandoned harbor shack. A lot of lesions are visible in the lung, the majority of which appear centrally necrotic—septic emboli. Can metastases look like that? Yes, but infrequently. If you are looking for reasons in favor of methadone substitution therapy for intravenous drug addicts, here is one.

**Wegener disease:** Solitary or multiple pulmonary lesions (granulomata) can occur in Wegener disease, an autoimmune vasculitis that is frequently associated with glomerulonephritis. They tend to necrotize centrally (Fig. 6.26).

### Wegener Disease



**Fig. 6.26** This pulmonary lesion is centrally necrotic. If the clinicians do not consider all of this patient's findings, diagnosis and therapy may go awry. A bright radiologist might include Wegener disease in the differential diagnosis and prompt a search for the respective clinical signs (sinus and joint problems, glomerulonephritis, and the presence of antineutrophilic cytoplasmic antibodies [c-ANCA]).

**Skin tumors, nipples:** As an exception, skin tumors may look like multiple lung nodules—just think of neurofibromatosis (Fig. 6.27). Nipples can also look suspicious. In some departments small lead markers are taped onto them to facilitate their differentiation from lung lesions. In other instances a quick fluoroscopy with a metal paper-clip taped to the areola will solve the problem.

→ **Diagnosis:** Joey and Ajay have talked to Mrs. Pumpkin. She has been pretty healthy up to now and is not the adventurous, easy-going type. For these reasons the lesions are metastases until proven otherwise. Ajay suggests an examination of the breast physically and mammographically, which would certainly be a good next step as breast cancer is a common malignancy in women of her age; someone should also take a look at her colon. If this and other tests fail to find the primary tumor, a CT-guided biopsy of one of the metastases would be the way to go (see Fig. 6.20e) because the appearance of the tumor cells under the microscope may provide a clue as to their origin. Bronchoscopy, perhaps with bronchial lavage, would be the next step in an immunosuppressed patient with a suspicion of a fungal infection of the lung that needs specific therapy urgently. Of course, CT-guided biopsies should only be performed if blood clotting is normal and if bronchoscopy does not provide the material with more ease.



### Skin Tumors

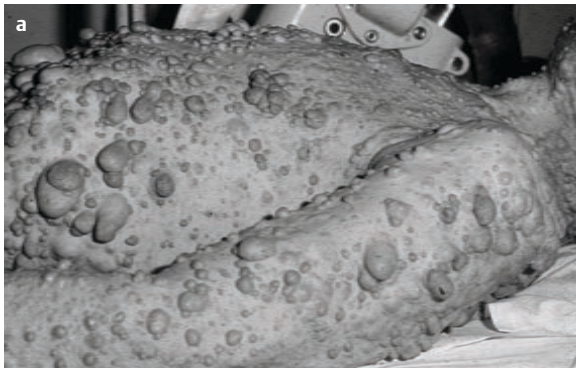
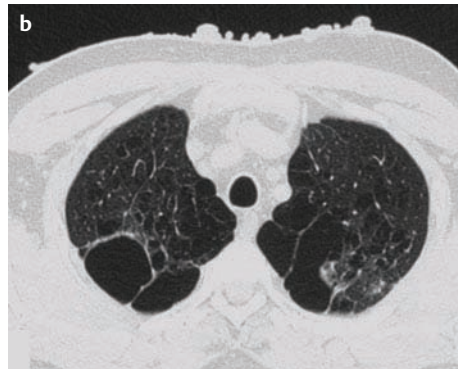


Fig. 6.27 **a** The cutaneous tumors in neurofibromatosis may certainly become visible on the CXR just as prominently as nipple shadows. A precise physical inspection and perhaps a short fluoroscopic examination after marking the nipple or any cutaneous tumors will clarify the situation.



**b** If the CXR becomes too complex, a CT may be necessary. In patients with neurofibromatosis it frequently also shows pulmonary emphysema.

### Diffuse, Homogeneous Opacity of the Lung

#### Checklist: Diffuse, Homogeneous Opacity of the Lung

##### Unilateral

- Is the patient well positioned?
- Has the contralateral breast been resected?
- Is there any volume loss?

##### Bilateral

- Has the patient taken a deep breath?
- Has the film been adequately exposed?
- Is the patient exceptionally adipose?

#### Shortness of Breath in Search of a Cause

Jonathan Bootleg (53) has developed shortness of breath while on dialysis for his terminal renal insufficiency. The internist in charge has requested a CXR (Fig. 6.28). Hannah is alone this late morning in the chest unit and takes a close look at the film. She considers the list of differential diagnoses.

### The Case of Jonathan Bootleg

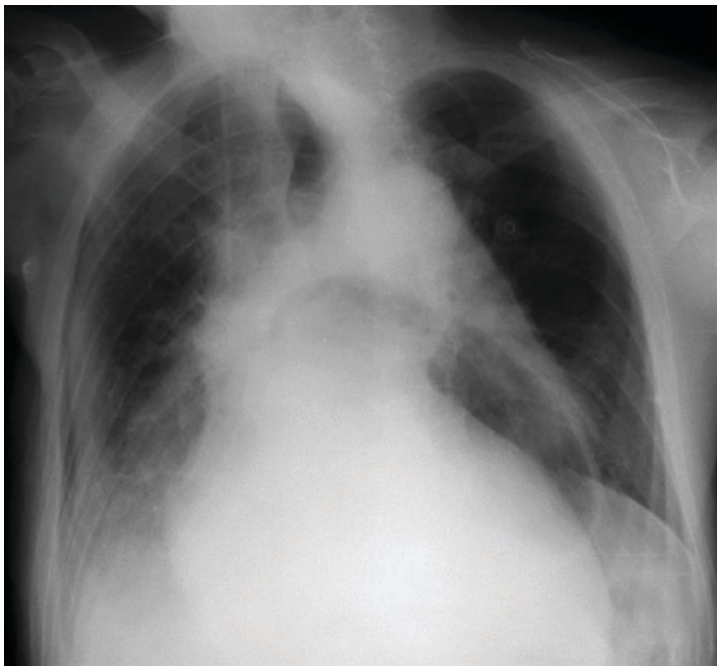

Fig. 6.28 Analyze the CXR of Mr. Bootleg. Does anything appear abnormal?

### → What Is Your Diagnosis?

**Pleural effusion:** A multitude of diseases, for example, pleural tumors (metastases, mesotheliomas) can result in a *unilateral* effusion. A homogeneous opacity of both lung fields can naturally also be caused by *bilateral* pleural effusions. The bilateral effusions may be different in quantity (Fig. 6.29), especially in cardiac decompensation and subsequent pulmonary venous congestion.



#### Do You Know Other Causes for a Diffuse Homogeneous Opacity of the Lung?

Portable CXRs are frequently performed without a scatter grid. The scattered radiation reaches the detector and uniformly increases the image density. If a grid is used it may not be properly aligned with the tube and may partially block diagnostic x-rays in one half of the chest causing an asymmetric exposure of the film. In insufficient inspiration, the density of the lung parenchyma also increases bilaterally owing to low lung volumes. Finally, any imaging technology may fail because the wrong exposure parameters have been chosen or because the patient simply was not built for imaging: patients who weigh more than 140 kg/300 pounds may need to be imaged with dedicated veterinarian equipment.

**Posttraumatic loss of radiolucency:** Trauma can result in a diffuse unilateral opacity of the thorax; a chest wall hematoma, possibly due to a serial rib fracture, or a hemothorax (Fig. 6.30) after an injury of intrathoracic vessels (intercostal arteries or the aorta) may be the cause.

**Atelectasis:** An atelectasis of the left upper lobe or of a total lung can increase the density of a complete hemithorax (see also Fig. 6.19a).

**Swyer–James syndrome:** Sometimes it is difficult to differentiate between an opacity on one side and an increase in radiolucency on the other. An early childhood pneumonia causes a circumscribed hypoplasia of the lung in Swyer–James syndrome. The change is characterized by a decreased vascularity and an increased aeration due to air trapping (Fig. 6.31).

→ **Diagnosis:** Initially Hannah was going to report a pleural effusion in Mr. Bootleg’s chest, but the dark stripe along the right thoracic wall has made her hesitant: Could this also be a pneumothorax? Sitting in front of the view-box, she scratches her head as Joey, Giufeng, and Ajay come by to pick her up for lunch. “It’s a skin fold,” Giufeng declares, “the density slowly increases laterally and then suddenly falls off. Above the aortic arch on the left side you can see two more of those folds.” “That does not explain it all, Giufeng,” Joey throws in, “the patient is rotated to the right quite a bit. Just have a look at the trachea and the unfolded aortic arch! This is one poorly taken radiograph. The rotation is another reason for the increase in density.” “OK, OK, I’ve got the message,” mumbles Hannah, “and which one of you smart alocs can tell me now why the patient is short of breath?” A long silence ensues, then Ajay replies softly: “Hannah, I would worry about that large air-filled structure in the heart shadow. How about this being a large hiatal hernia or even an ‘upside-down-stomach’! That could explain the dyspnea.”

### Pleural Effusion

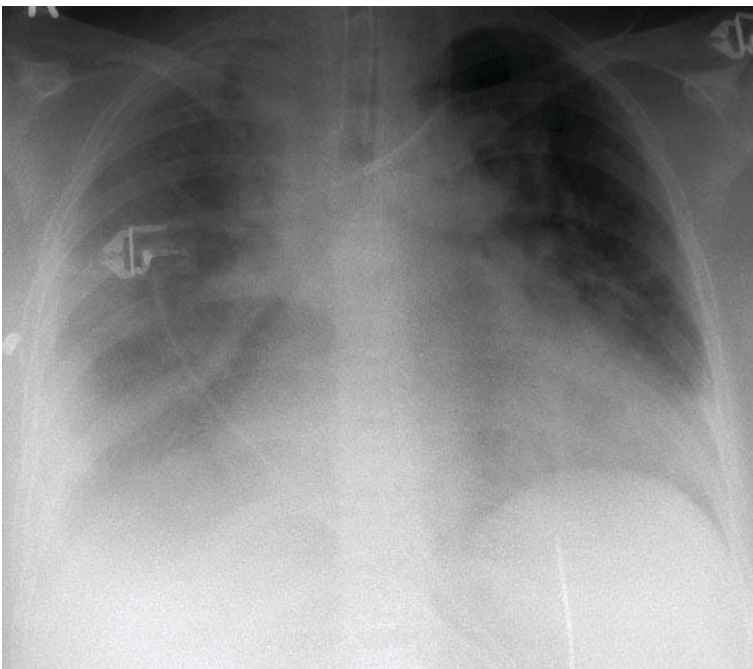


Fig. 6.29 This large right-sided and smaller left-sided pleural effusion extends far superiorly in this portable chest film obtained from a recumbent patient in bed. For this reason the complete lung appears homogeneously opacified. The interface between diaphragm and lower lobe is obliterated on the right side—go ahead and compare it to the left side. The vessels close to the hilum are enlarged and their margins are unsharp. The bronchi can be traced far into the lung core. The heart appears enlarged, even for a portable supine study. This is compatible with cardiogenic pulmonary venous congestion with subsequent edema.



## Hemothorax

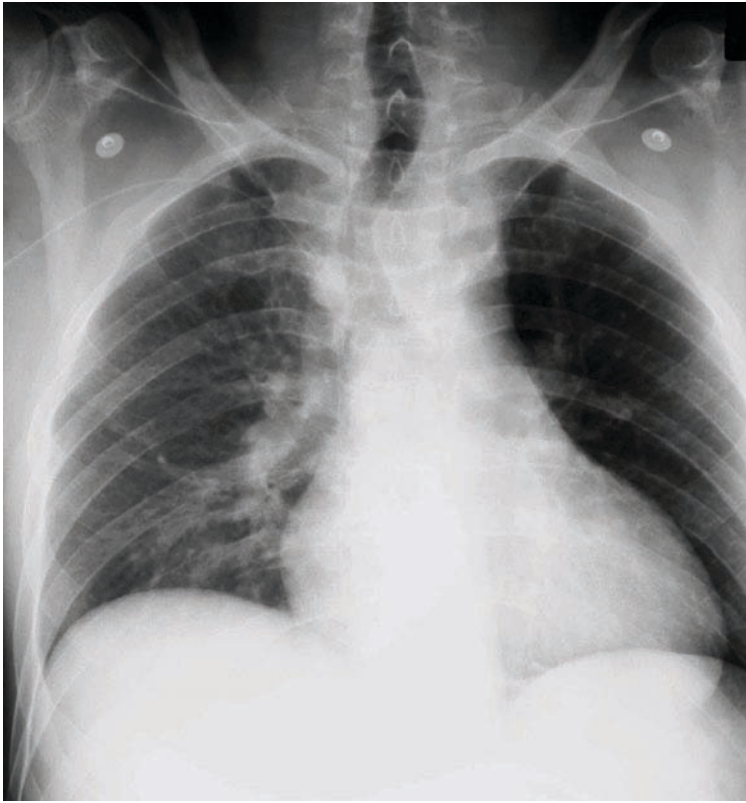


Fig. 6.30 The right-sided loss of normal radiolucency is due to a hemothorax that is subtle but is a consequence of a severe deceleration trauma in a motor vehicle accident (MVA). The upper mediastinum is widened, indicating a possible large-vessel rupture, which was in fact the case in this patient.

## Swyer–James Syndrome

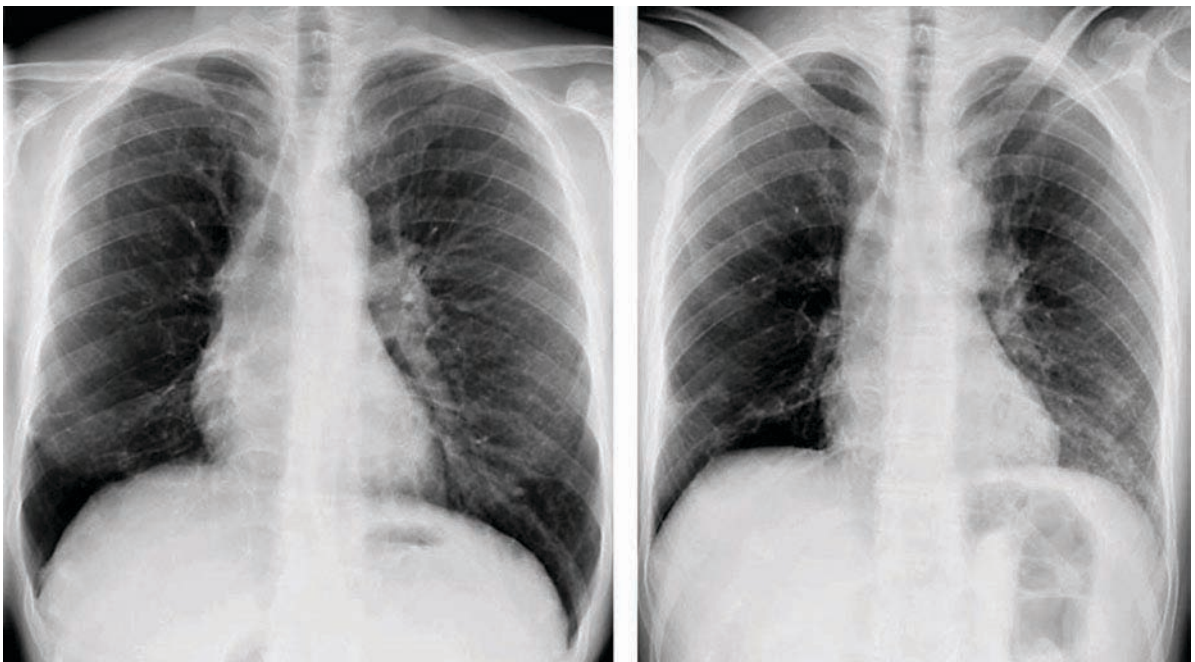


Fig. 6.31 These CXRs in inspiration (left) and expiration (right) show decrease in vascularity in the right hemithorax (also compare both hila) and hyperinflation of the right lung (also called “air trapping”). The right hemidiaphragm does not move at all.

All are impressed—a real team effort. Hannah jots down the preliminary report. “Well, I should be depressed. But thanks anyway. Talking about gastrointestinal stuff,” she goes “I’m starving. Let’s go for lunch!”

## 6.3 Acute Pulmonary Changes

### Acute Diffuse Linear, Reticular, Reticulonodular (Interstitial) Pattern

#### Checklist: Acute Diffuse Interstitial Pattern

- Are the increased markings linear, reticular, or made up of small nodules?
- Are they associated with segmental or lobar consolidation?
- Do the vessels appear unsharp or enlarged cranially?
- Can you detect air bronchograms?
- Are the increased lung markings more evident centrally or basally?
- Are there areas of increased radiolucency and decreased vascularity?
- Are the bronchi dilated, their walls thickened?
- Is the heart enlarged?
- Are the hila plump in appearance?

#### Patterns of Evil

David Shortbreath (57) has been brought to the emergency room. He has had chest pain at work several times over the past few weeks; it has been just absolutely awful because he felt severely short of breath at the same time. His colleagues at the construction site grabbed him, sat him in the car, and rushed him to the hospital, breaking all speed limits on the highway. During that ride Mr. Shortbreath could breathe in more easily when he held his head out of the window and breathed against the airstream with his mouth open. Now the ER docs are taking care of him, studying the laboratory parameters and getting an ECG. A chest radiograph is also done (Fig. 6.32). Paul stands close to the lightbox to get a quick first glance at the image.

#### → What Is Your Diagnosis?

**Left ventricular failure with pulmonary venous congestion:** Pulmonary venous congestion is a typical consequence of left ventricular dysfunction, for example, after coronary infarction. The mounting pulmonary venous pressure is reflected on the CXR by a number of specific findings:

- **Pulmonary venous redistribution:** The first reaction of the pulmonary vasculature to an increase in vascular pressure is to make use of the vessels’ reserve capacity. In this process the blood is redirected from the basal lung vessels, which normally hold more blood owing to the hydrostatic pressure gradient, to the cranial pulmonary vessels (see Fig. 6.1). This phenomenon is also called pulmonary venous redistribution.

#### The Case of David Shortbreath

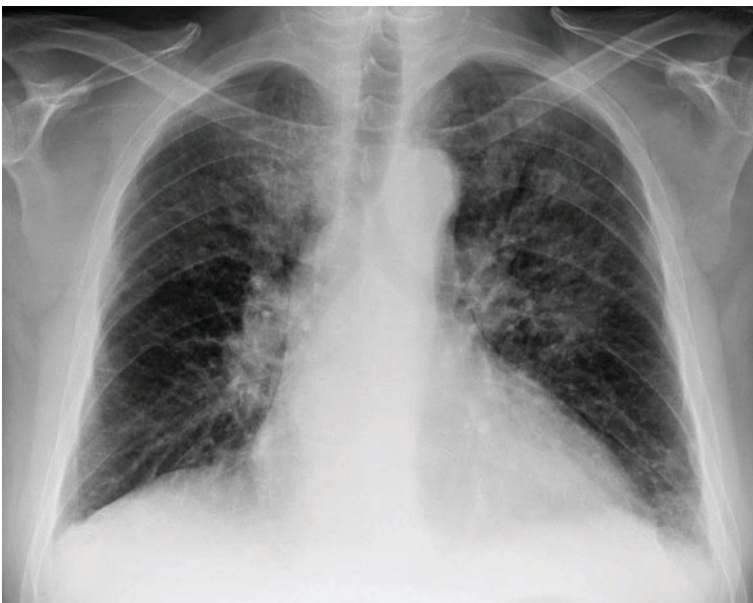


Fig. 6.32 Have a look at the CXR of Mr. Shortbreath. What are the pertinent findings?

**!** The normal size relation of the basal to the cranial vessel calibers is about 2 : 1 (at identical distance from the hilum).

The basal vessels may even contract a little during this process. Naturally these changes are only noticeable if the patient is upright at the time the CXR is taken (hydrostatic pressure!) (Fig. 6.33). In the recumbent patient the pulmonary venous redistribution cannot be diagnosed because the vessel calibers even out; the vector of the hydrostatic pressure gradient has now changed to the anterior–posterior direction, which is not visible on a frontal supine radiograph (see Fig. 6.3)!

- *Fluid exudation into the interstitium:* If the reserve capacity of the vessels is exhausted, fluid begins to leak into the interstitium. This process can be observed on the CXR if one looks for these four different structures:

1. *The interlobular septae:* Fluid in the radially oriented interlobular septae is best appreciated where the septae are parallel to the x-ray beam and where they cannot be mistaken for vessels. This is the case in the peripheral 1 cm of the parenchyma of the lung where vessels are so small that they are beyond the limits of radiographic

visualization. The resulting linear structures on the CXR are called Kerley lines: Kerley B in the basal periphery (these are the most important ones, Fig. 6.34a) and Kerley A in the cranial periphery. If the thickening is so pronounced that it becomes visible as a reticular pattern in the central perihilar lung, this is called the Kerley C pattern. Kerley C lines are rarely seen in pulmonary venous congestion but do occur when the interstitium is infiltrated by malignant cells. This dreaded but frequent complication of, for example, advanced breast carcinoma is called lymphangitic spread or carcinomatosis (Fig. 6.34b).

2. *Fissures:* Interlobar fissures are made up of two layers of pleural lining and thus two layers of interstitium as well. Furthermore, a little fluid may enter the pleural space between the two pleural linings. If the fissures appear particularly prominent or thickened on the CXR, the reason may be fluid overload in the interstitial space (Fig. 6.34a).

3. *Bronchial wall:* The thickness of the interstitium can also be evaluated by looking at the walls of the larger bronchi in the neighborhood of the hilum that are running parallel to the x-ray beam and therefore appear

### Upper Lobe Pulmonary Venous Redistribution

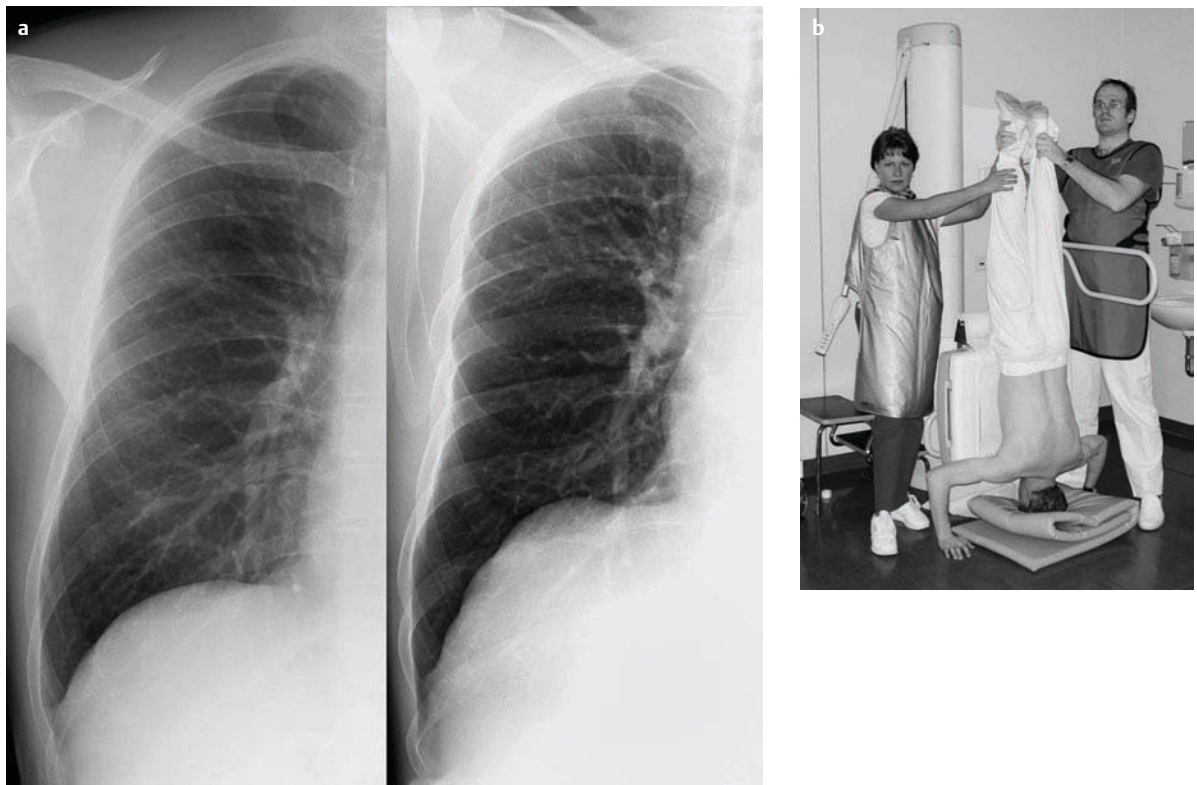


Fig. 6.33 a On the left you see a normal chest exposed in the standard erect position. Compare the vessel calibers at the same distance to the hilum both at the lung base and apex. The size relation of the basal vessels in comparison to the upper lobe vessel is about 2:1. On the right, the same

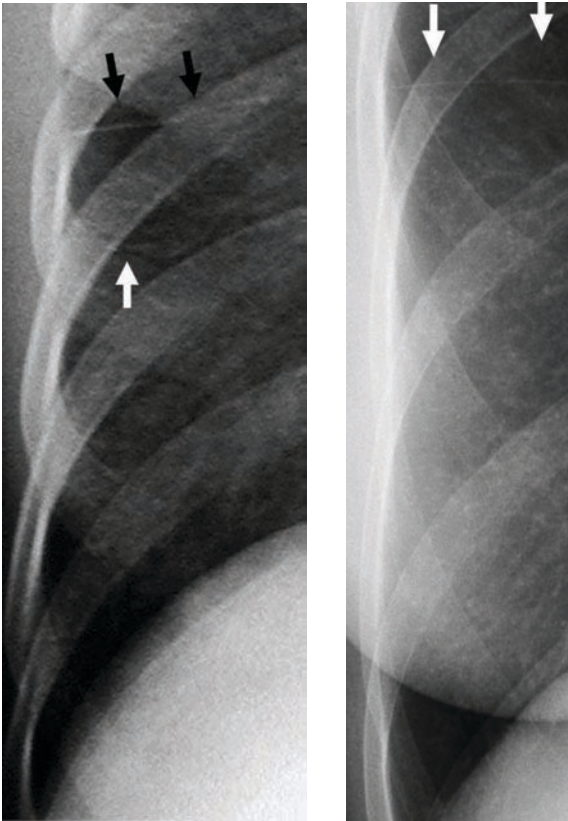
volunteer has changed body orientation, with a subsequent redistribution of the pulmonary perfusion. Check the vessel calibers!

b The documented position is not unusual at large academic institutions and reverses the natural hydrostatic pressure gradient.

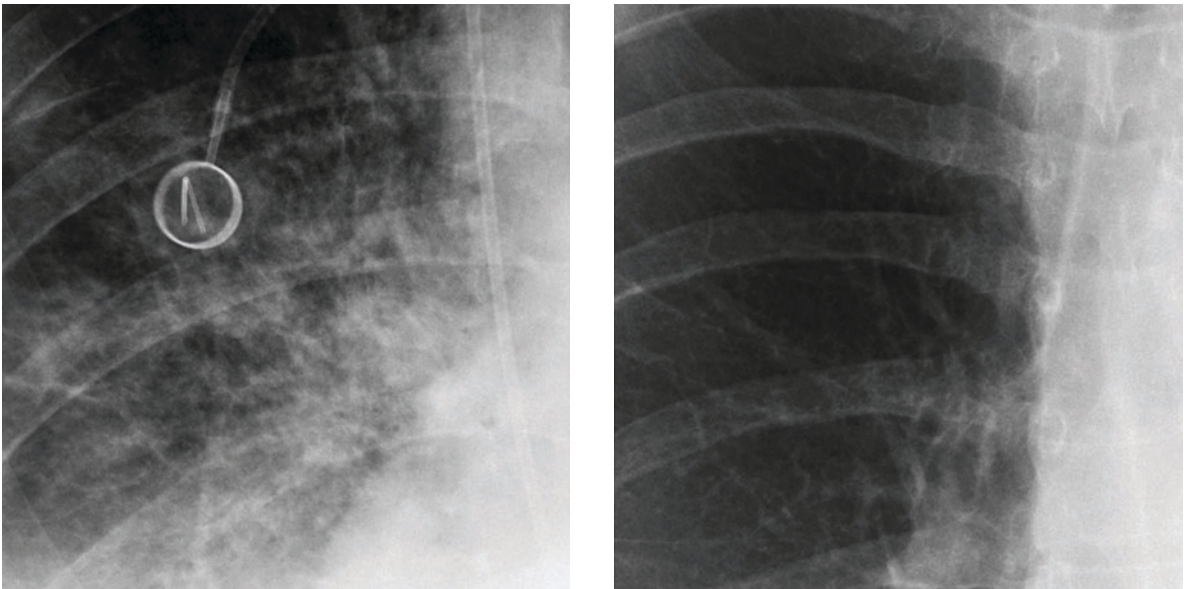


## Kerley Lines

### a Kerley B lines



### b Kerley C lines



**Fig. 6.34 a** On the left you see a section of a CXR in severe lung edema. Note the thickening of the minor fissure (black arrow) and the horizontal interlobular septae (white arrow) in the pulmonary periphery. Vessels do not normally show in this parapleural stripe. Compare to a normal section below.

**b** On the left is a section of an erect CXR. The lung interstitium with the vessels, bronchi, and the surrounding fibrous tissue is irregular, micronodular, and reticular in pattern. This is a case of lymphangitic carcinomatosis in a breast cancer patient. The tumor cells grow along the interstitium and form knotty cell nests. Compare to a normal anatomy below.

### “Bronchial Cuffing”

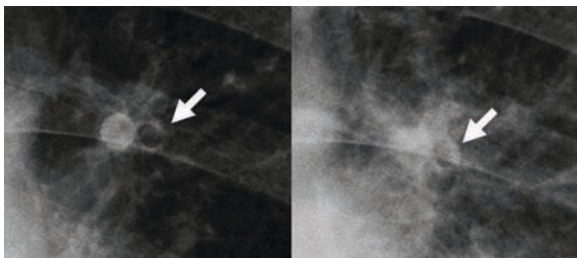


Fig. 6.35 Bronchus and artery appear in a typical “number 8” configuration when imaged head-on or “down the barrel.” The bronchial wall normally does not exceed 1 mm (left section, arrow). In pulmonary edema the thickness of the interstitium around the bronchial wall and the artery increases (right section, arrow) rendering their contours unsharp.

as ringlike structures when imaged “end-on” (“down the barrel”). The normal bronchial wall is about 1 mm thick and barely perceptible. If its thickness increases and its contours become unsharp, this is called “bronchial cuffing” (Fig. 6.35).

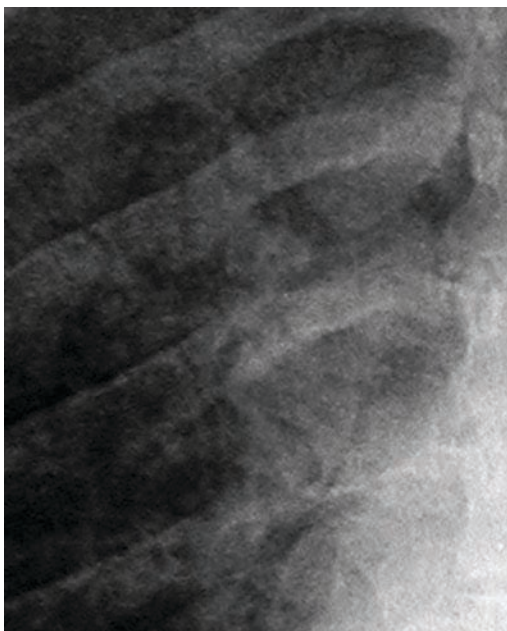**!** You can recognize a bronchus by searching for the accompanying artery: The combination of the two structures looks like an “8” with one ring of it filled.

4. *Vascular wall:* Naturally, the same occurs in the vessel walls but it cannot be observed that well. (Do you know why?) Eventually the caliber of the vessels increase and their contours become hazy (Fig. 6.35).

- *Fluid leaking out of the interstitium into the alveolar space:* If the pulmonary venous pressure remains high or continues to increase, the interstitial lymph drainage is eventually overwhelmed and the fluid is pressed into the alveoli. The subsequent corresponding radiographic pattern is that of patchy and confluent density; this is also called an alveolar pattern. Radiographically the lung tissue now appears much denser than the bronchi, which is why they now become visible against the backdrop of the alveoli. This phenomenon is also called “air-bronchogram” and is typical for alveolar disease (Fig. 6.36a). Frequently, fluid exudation begins in the perihilar region and then expands toward the periphery. It may do so simultaneously in both lungs, sparing the lung periphery: a “butterfly distribution” or “bat’s wing” pattern (Fig. 6.36b) results that is the hallmark of severe alveolar edema. In patients who are severely compromised, perhaps in the intensive care unit, who have been lying on one side for a prolonged period of time, the distribution of alveolar fluid may be asymmetric. Furthermore, patients with severe inhomogeneously distributed bullous emphysema can only produce the radiographic appearance of alveolar edema in the “good” portions of their lung, because the remainder of the lung is made up of large air-filled spaces with very few if any blood vessels.

### Acute Alveolar Pulmonary Edema

#### a “Air bronchogram”



#### b “Butterfly or batwing edema”

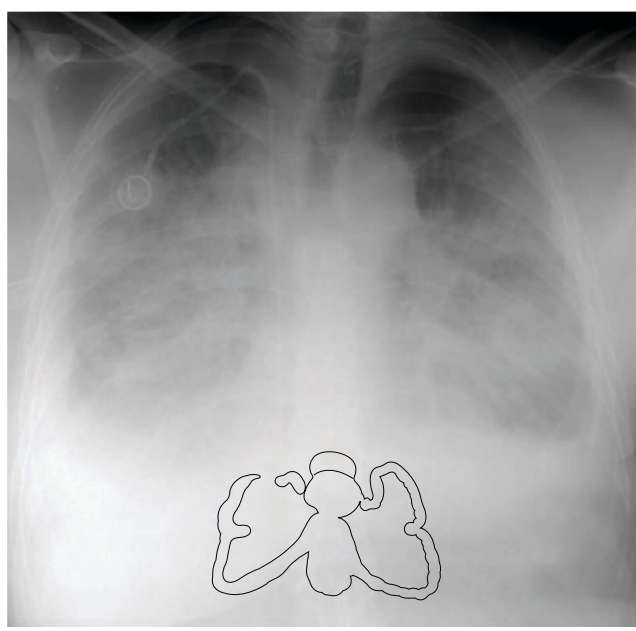


Fig. 6.36a If the bronchial tree can be traced from the hilum to the central lung parenchyma, this is also called “air bronchogram.”  
b The edema spares the lung periphery initially. The typical butterfly or batwing configuration results.





### The First Descriptor of Pulmonary Lines

Peter James Kerley was an Irish radiologist who trained in Vienna during the Golden Twenties of the last century. He later worked in London at the Westminster Hospital. The Royal College

of Radiologists named a lecture in his honor. He is said to have been a witty fellow with a flair for extravagant diagnoses. As a normal human being, you should try for the former and avoid the latter.

**Viral pneumonia:** The interlobular septae can also become engorged in some viral pneumonias, for example, in CMV pneumonia (Fig. 6.37). Again, you see the infamous Kerley lines. Of course, the pulmonary venous redistribution typical of pulmonary venous congestion is usually absent and the clinical presentation is quite different from pulmonary edema.

**Miliary tuberculosis:** Acute widespread small nodules in the lungs of a patient with clinical signs of an infection point to a miliary tuberculosis (Fig. 6.38a) but can also be caused by a variety of endemic fungal infections such as histoplasmosis, coccidioidomycosis, and blastomycosis, depending a little on which part of the world you work in. If this disease is overcome, the little granulomas tend to calcify (Fig. 6.38b).

→ **Diagnosis:** Paul finds enough signs of pulmonary congestion on the CXR and is convinced that the symptoms are so straightforward that he does not hesitate to diagnose cardiogenic interstitial lung edema. The follow-up CXR supports his interpretation because it shows the progression into typical alveolar edema (Fig. 6.39). The registrars have by now been able to confirm their suspicion of a myocardial infarction with ECG and laboratory findings and have initiated the appropriate therapy. They are still puzzled, however, about the “breathing out of the car window” bit of the history. Paul has already discussed the issue with Joey and both have the same explanation: Being driven at high speed, Mr. Shortbreath breathed against the airstream and thus simulated a PEEP (positive end expiratory pressure) respiration, which serves to keep the terminal airways open. That helped him a lot. (Go ahead and try it out on your way home—but make sure your seatbelt is fastened, stay clear of other cars, and dodge insect swarms!)

### Viral Pneumonia

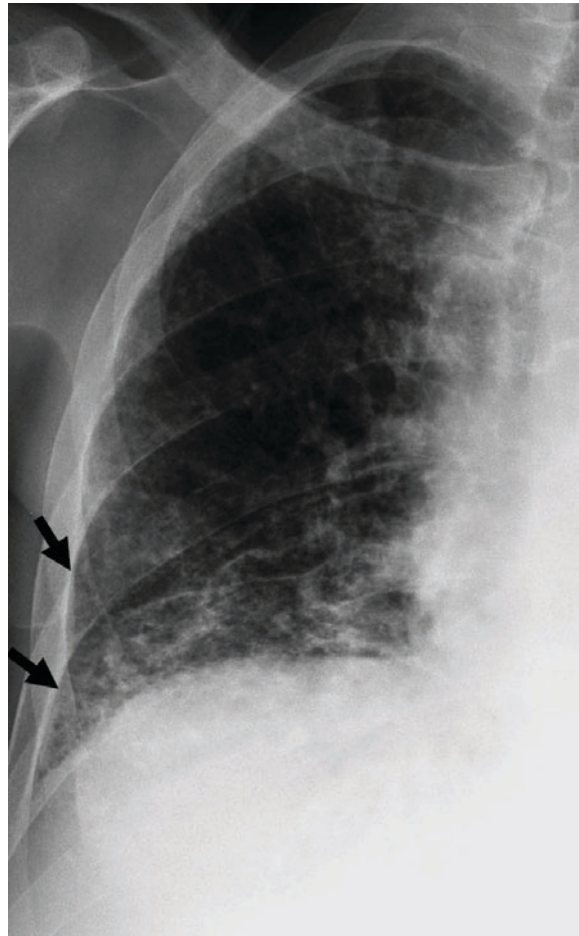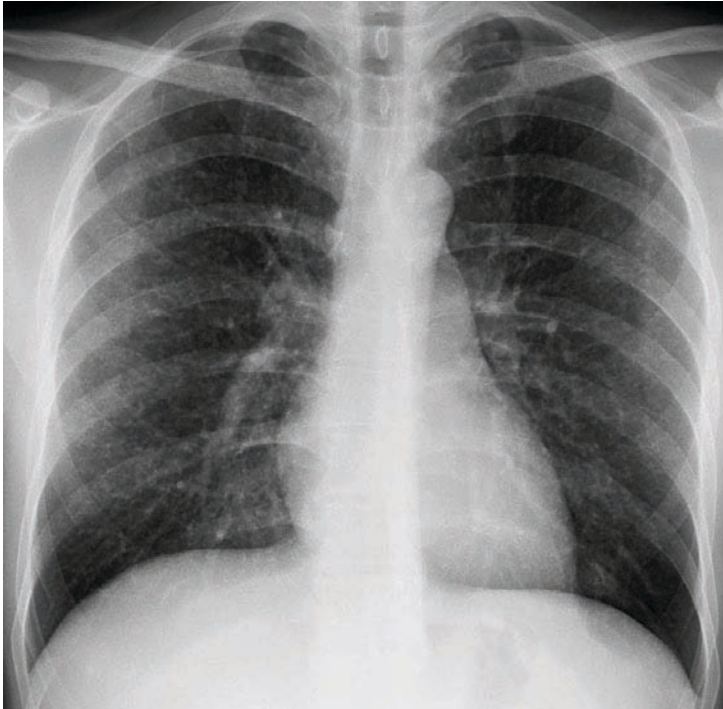


Fig. 6.37 This is a section of the CXR of a patient with a cytomegalovirus (CMV)-induced pneumonia; the interlobular septae are thickened. This patient was immunosuppressed after organ transplantation.

! If you ask different people “Does this patient’s CXR show pulmonary edema?” you frequently get different answers—the decision is not always that simple. Try to use the above-mentioned criteria and listen closely to the clinical impression of the registrars in charge of the patient. After a little while you and your perception will be adequately tuned to diagnose this condition with some certainty.

### Miliary Tuberculosis

**a Active**



**b Inactive**

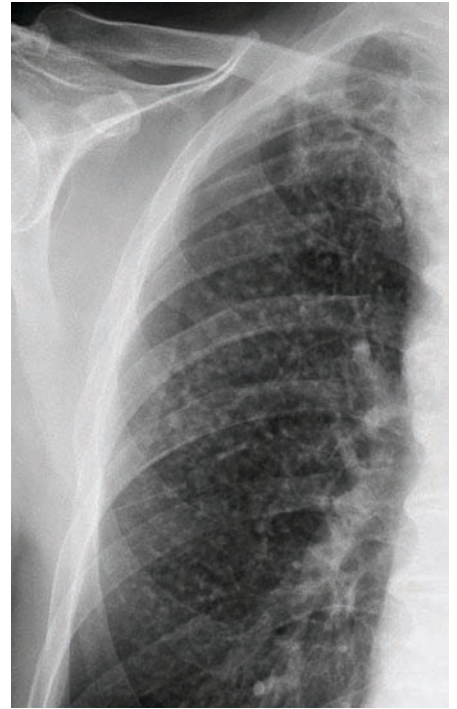


Fig. 6.38 **a** This immunosuppressed HIV patient developed an active miliary tuberculosis. **b** The tiny, very dense nodules on this radiograph are typical for an inactivated miliary tuberculosis (milium= millet or sorghum). This patient had been admitted for a replacement of his total hip arthroplasty.

### The Case of David Shortbreath

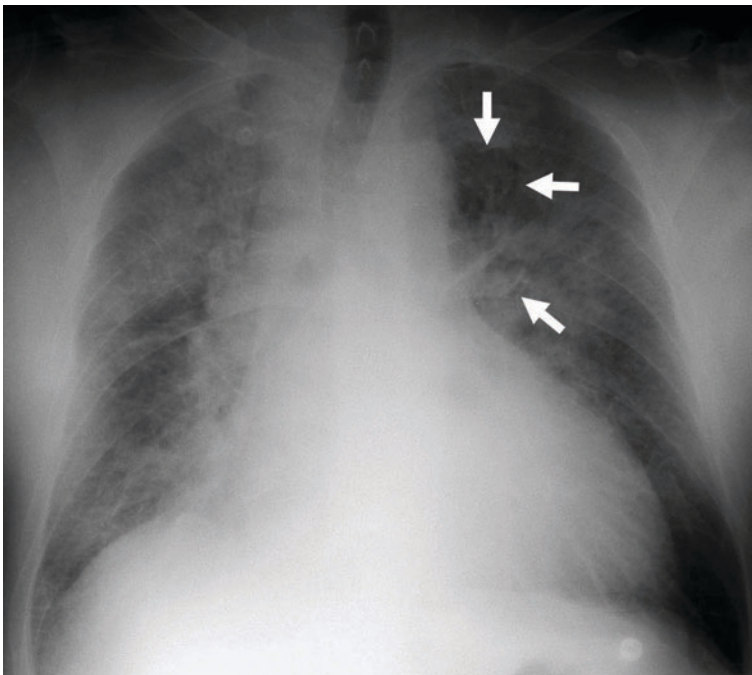


Fig. 6.39 This is the follow-up study of Mr. Shortbreath—a portable radiograph that shows an increase in pulmonary venous congestion. In the perihilar region the exudation of fluid into the alveoli is documented by spotty and/or cloudy opacities. The heart is significantly enlarged.

## Acute Diffuse Acinar, Confluent (Alveolar) Pattern

### Checklist: Acute Diffuse Alveolar Pattern

- Is the consolidation predominantly central or peripheral?
- Do the vessels appear unsharp or cranially distended?
- Are the perceptible bronchial walls thickened?
- Is the heart enlarged?
- Are there symptoms of a myocardial infarction?
- Could the fluid balance be positive (patient on hemodialysis, intensive care setting, infusion therapy)?
- Are there signs of infection?
- Could an allergic or toxic reaction be present (organic dusts, gas, drugs)?

### Something is Filling Up

Mary Chang (57) has been brought to the emergency room straight from her apartment in Bondi. Her neighbor called the ambulance after having found her wheezing at her front door. Currently Mrs. Chang cannot be questioned because the ambulance medics had to sedate and intubate the distressed patient. Giufeng tries to get some information from the friendly neighbor who accompanied her to the hospital: Yes, she overheard a loud argument and the slamming of doors in Mrs. Chang's apartment quite a while before she

found her. But she is not really close to her next-door neighbor. Giufeng is a little perplexed as she returns to her viewbox where the CXR and Hannah are already waiting for her (Fig. 6.40). Hannah has spotted a policewoman together with a detective in the emergency waiting area.

### → What Is Your Diagnosis?

**Pulmonary edema:** A lung edema due to an increase in the pressure of the pulmonary circulation could certainly be present (see Fig. 6.36b, Fig. 6.39). This could be due to a myocardial infarction, which must be excluded in this case. A patient with renal insufficiency in dire need of a dialysis could also present with an image like that.

**Pulmonary hemorrhage:** In pulmonary hemorrhage, as may occur in Wegener granulomatosis or in Goodpasture syndrome, the alveoli fill with blood (Fig. 6.41).

**Hypersensitivity pneumonitis due to exogenous allergens:** The inhalation of many different allergenic organic substances such as bird excrement, the dust of bird feathers, moldy hay or barley, paper or sawdust can initiate a massive pulmonary hypersensitivity reaction including exudation of fluid into the alveoli.

**Pneumocystis carinii pneumonia:** In an AIDS patient with the symptoms of a pulmonary infection, *Pneumocystis carinii* pneumonia is very probable (Fig. 6.42).

## The Case of Mary Chang

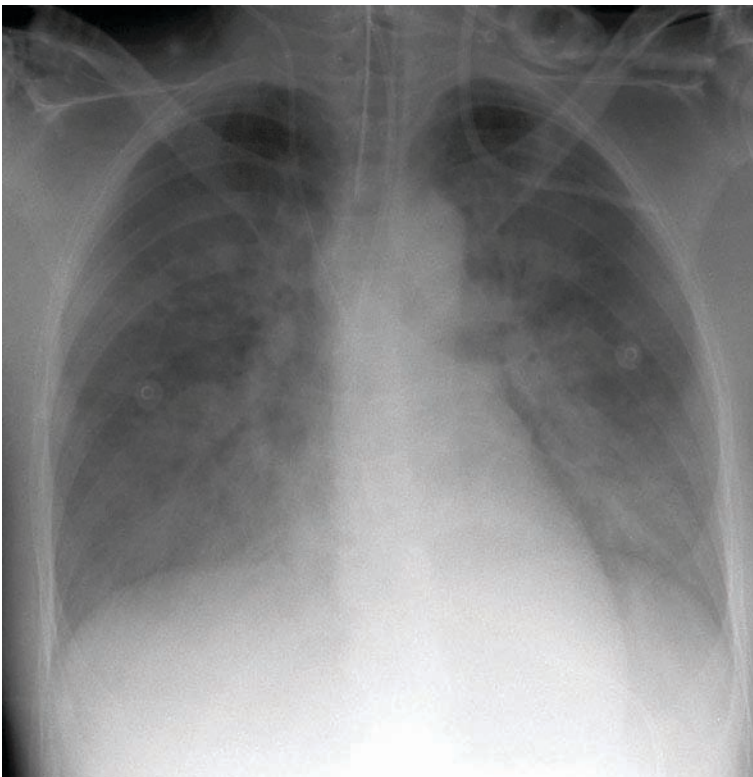


Fig. 6.40 Observe the CXR of Mrs. Chang. Which diagnoses must be discussed?



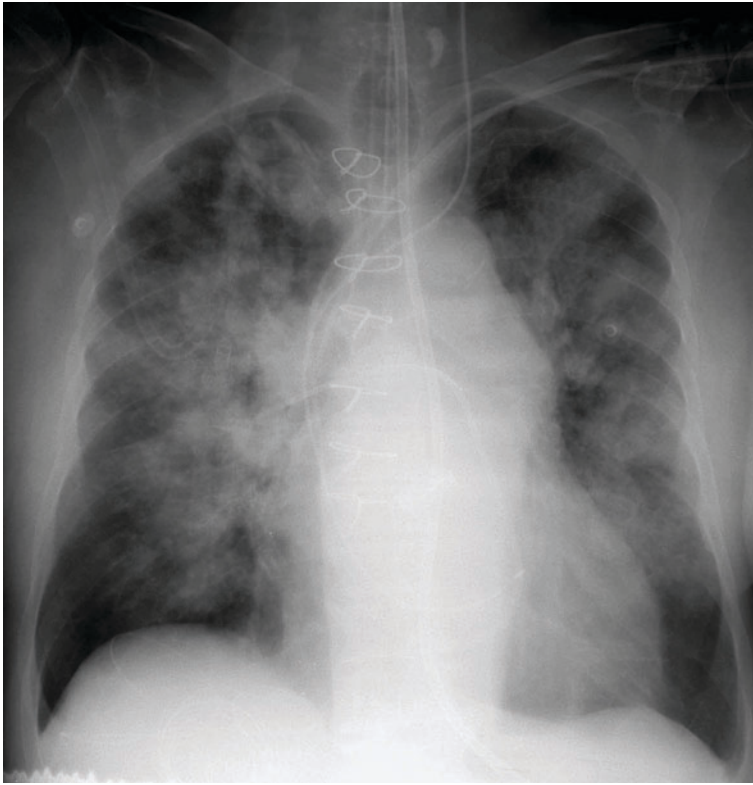**Lung Hemorrhage**

Fig. 6.41 This elderly lady had a heart valve implanted. Postoperatively a fulminant pulmonary hemorrhage resulted that led to this remarkably dense opacification (hemosiderin content!) of both lungs.

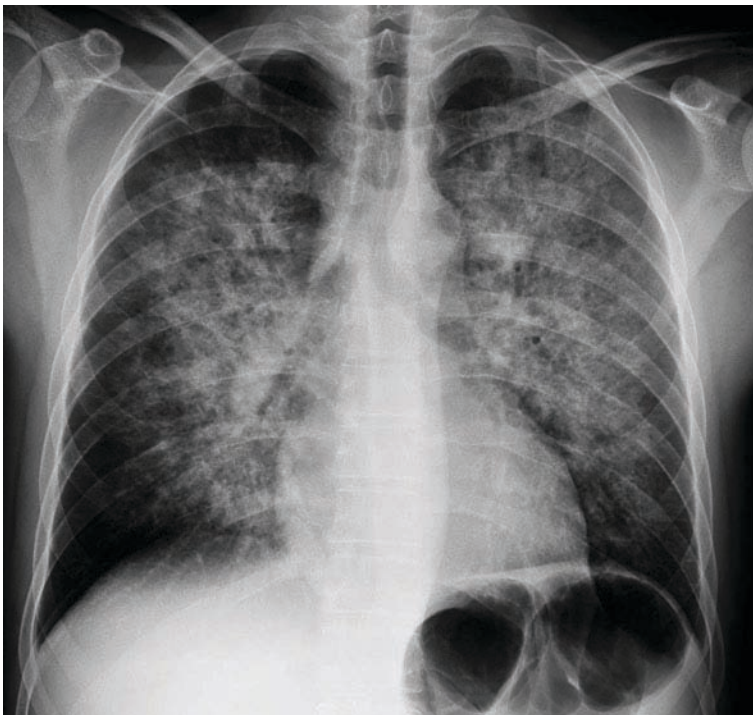
***Pneumocystis carinii* Pneumonia**

Fig. 6.42 A severe *Pneumocystis carinii* pneumonia occurred in this HIV patient. Changes are much more subtle in most other patients. In these less obvious cases a high-resolution CT (HRCT) is recommended.



**Acute respiratory distress syndrome (ARDS):** Finally, this could be acute ARDS. While in normal edema intact tissue barriers are crossed because the pulmonary venous pressure is increased, an injury of the barriers with an ensuing increase in permeability may lead to fluid leakage into the alveoli without a pressure hike in the pulmonary circulation. The result is the so-called ARDS (Fig. 6.43a), also

called shock lung or (formerly) “DaNang lung.” The increase in permeability may be due to a variety of causes. However, severe hypoxemia always develops and must be compensated by ventilating the affected patient with a high oxygen concentration gas mixture. As the patients are being ventilated with high pressures, pneumothoraces are always a danger and must be excluded (Fig. 6.43b). In a

### Acute Respiratory Distress Syndrome (ARDS)

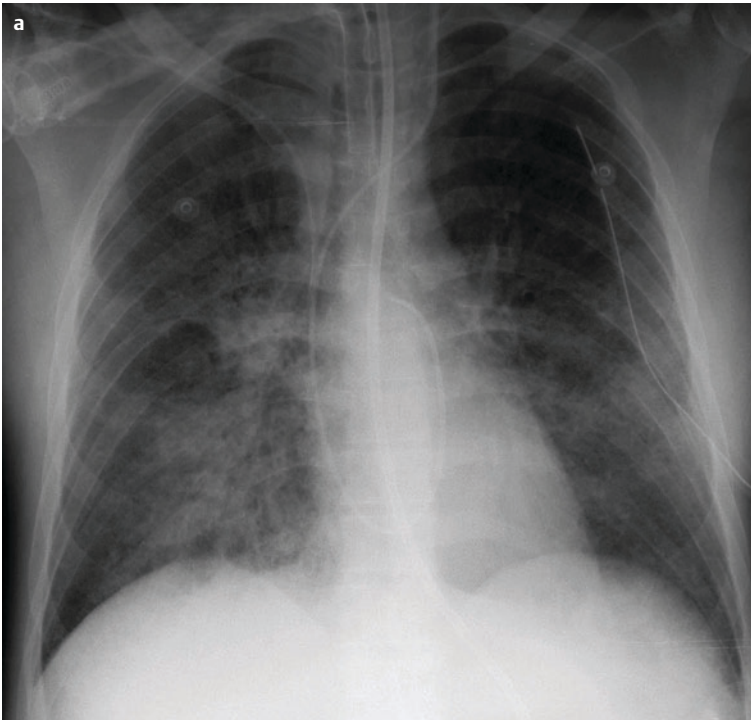
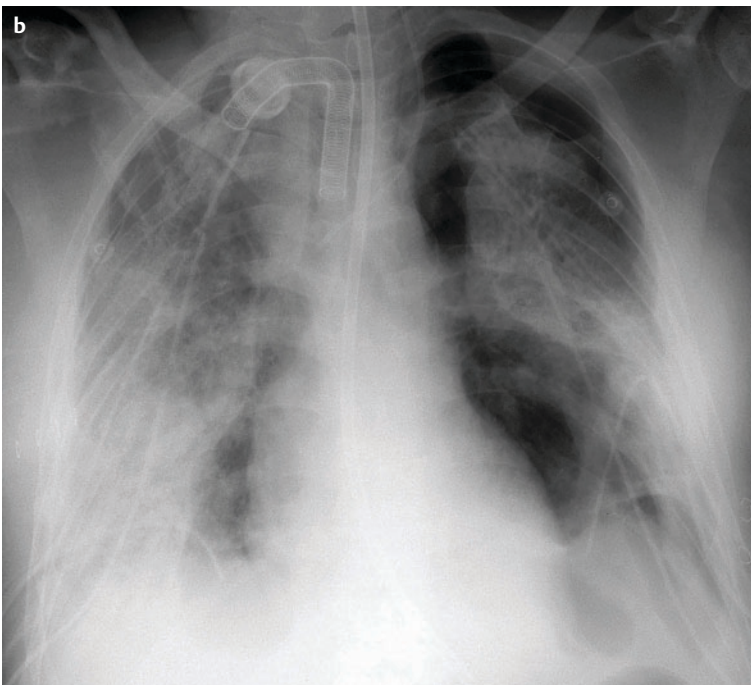


Fig. 6.43 **a** Subsequent to a pneumonia this patient developed a serious disturbance of pulmonary membrane permeability compatible with ARDS.

**b** Patients with ARDS often have to remain on the respirator for prolonged periods and are frequently ventilated with high end-expiratory pressures. Pneumothoraces requiring pleural drainage are a possible complication. In this patient several pleural drains have already been introduced on both sides. The left lung is still not completely expanded.



### Acute Respiratory Distress Syndrome (ARDS)

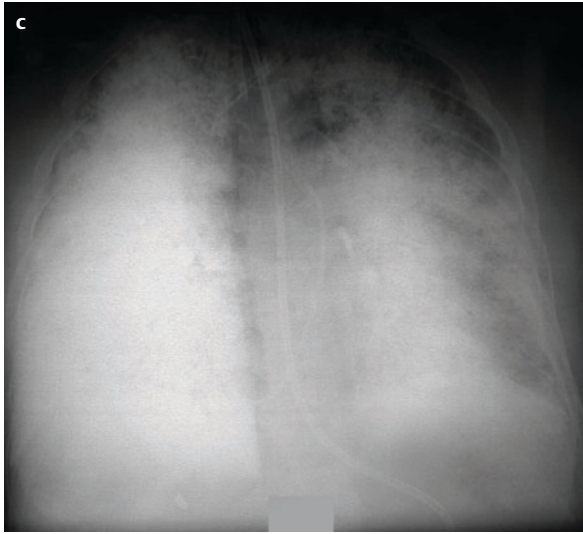


Fig. 6.43 c Mechanical respiration of ARDS patients can also be performed with a fluid containing perfluorocarbon that has a much higher density than water.

few cases a special dedicated technique may help: instead of with air, the patients are respirated with a special fluid that permits extremely good gas exchange and at the same time soothes the pulmonary membranes (Fig. 6.43c).



#### Why Was This Disease Called “DaNang Lung”?

DaNang is a city in Indochina that became infamous during the Vietnam war (1961–1975).

Your parents and grandparents remember the depressing stories in the daily news: helicopters flew wounded soldiers back from the jungle to the modern American military hospital in DaNang. It was there that heavily traumatized soldiers with high blood losses could be transfused with blood and plasma. In these patients a hitherto unknown form of pulmonary edema was observed that developed after the successful therapy of their shock. Prolonged artificial respiration with high oxygen pressures was necessary to treat this disease—ARDS.

**Miscellaneous severe alveolar reaction:** The acute flooding of the lung with particles, such as may happen in sand blasting without breathing protection, can lead to an extensive alveolar disease pattern. The same is true in massive aspiration of fluids (as in drowning) and the inhalation of toxic gases.

→ **Diagnosis:** Giufeng and Hannah are a little frazzled. Gregory, who has dropped by, also does not have a good explanation, lacking any clinical background information on this patient. The heart is in good shape the cardiologist states having looked at the ECG and the laboratory parameters. Pulmonary hemorrhage has been excluded during bronchoscopy. An HIV infection is improbable. Fortunately, under artificial respiration and corticosteroid therapy, Mrs. Chang’s health improves quickly. A few days later, after extubation and further recovery, she tells her story. After her ex-husband’s short visit,

she had cleaned the guest toilet with her very own cocktail of strong toilet cleaners. While polishing the toilet seat in this small room she suddenly began to feel very short of breath, gasped for air, and almost collapsed. It was most likely a case of acute toxic lung edema. Her ex-husband was involved only tangentially, having recklessly or deliberately peed on the toilet seat for old times’ sake.

! The lungs can only react in a limited number of ways to external injury. At the beginning of the evaluation it is important to determine the most likely offending agent, often through pertinent clinical history provided by the patient or witnesses. If specific information is unavailable, the problem is classified according to the symptomatology, prevalence of the disease, and plausibility.

## 6.4 Chronic Lung Disease

### Chronic Linear, Reticular, Micronodular (Interstitial) Pattern

#### Checklist: Chronic Interstitial Pattern

- Is an abnormal radiograph an incidental finding in an asymptomatic patient?
- Is the pathology depicted clear enough or should a high-resolution CT (HRCT) be performed? (Nowadays, HRCT should be performed in all cases where serious treatment such as steroids or other consequences are considered.) Is there any pertinent past medical history?
- Is there any present or past exposure to occupational or recreational hazards that could cause chronic lung disease?

### The Case of Bob Coalfire

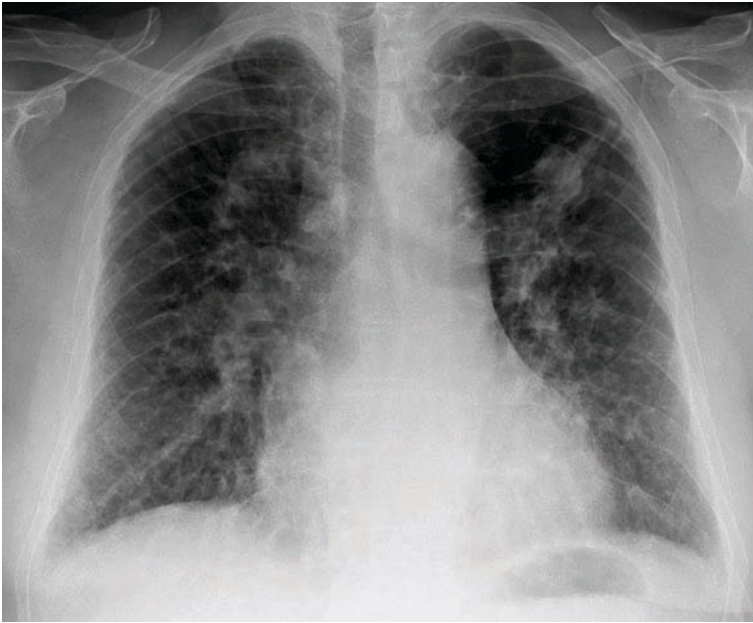


Fig. 6.44 This is the CXR of Bob Coalfire.

#### Traces of a Life

Robert Coalfire (47) has done hard physical work all his life. Since his early retirement owing to osteoarthritis of his hip he has spent a lot of time in his little garden in Bribie close to the beach. He was busy with the spring clean-up there when the dyspnea that has plagued him for quite a while worsened considerably. His wife has finally forced him to see his doctor, who sent him directly to radiology to get a chest radiograph. Paul and Hannah are assigned to the chest imaging unit today. They analyze the image (Fig. 6.44) that comes up on their monitor and debate the differential diagnosis of generalized changes of the lung interstitium.

#### → What Is Your Diagnosis?

**Chronic left heart insufficiency:** The continual vascular congestion in chronic left heart insufficiency causes a constant fluid overload of the interstitium. Over time the fluid is organized and a reactive scarring or fibrosis develops. This process is most pronounced in the areas of the highest hydrostatic pressure, that is, in the basal lung. In the CXR one may observe a fine micronodular pattern (Fig. 6.45).

**Pneumoconiosis:** Chronic occupational exposure to inorganic dusts (carbon, silica) and also fibers (asbestos) has dire consequences for the lung. The bronchi and the interstitium respond with an inflammatory reaction that eventually leads to an irreversible nodular rearrangement of the lung architecture (Fig. 6.46a). Bullae and overinflations may occur as well fibrotic stranding and compaction of lung tissue.

**Silicosis:** In silicosis two other typical manifestations are seen: the so-called progressive massive fibrosis conglomerate tumors of silicotic tissue that can become very large (Fig. 6.46b) and typical eggshell-type calcifications of hilar lymph nodes (Fig. 6.46a). Acute inflammatory processes can be treated with appropriate medication, but the

#### Chronic Left Heart Insufficiency

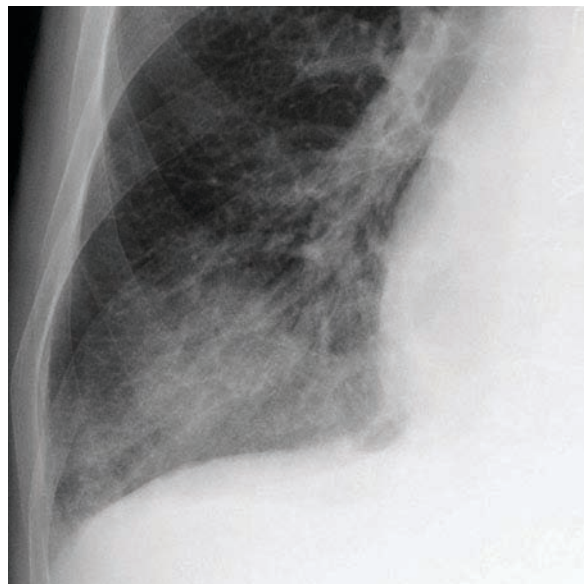


Fig. 6.45 You see the basilar portion of a CXR in a patient with a severe and chronic mitral valve insufficiency. The constant fluid overload of the interstitium has produced a micronodular pattern.



## Silicosis

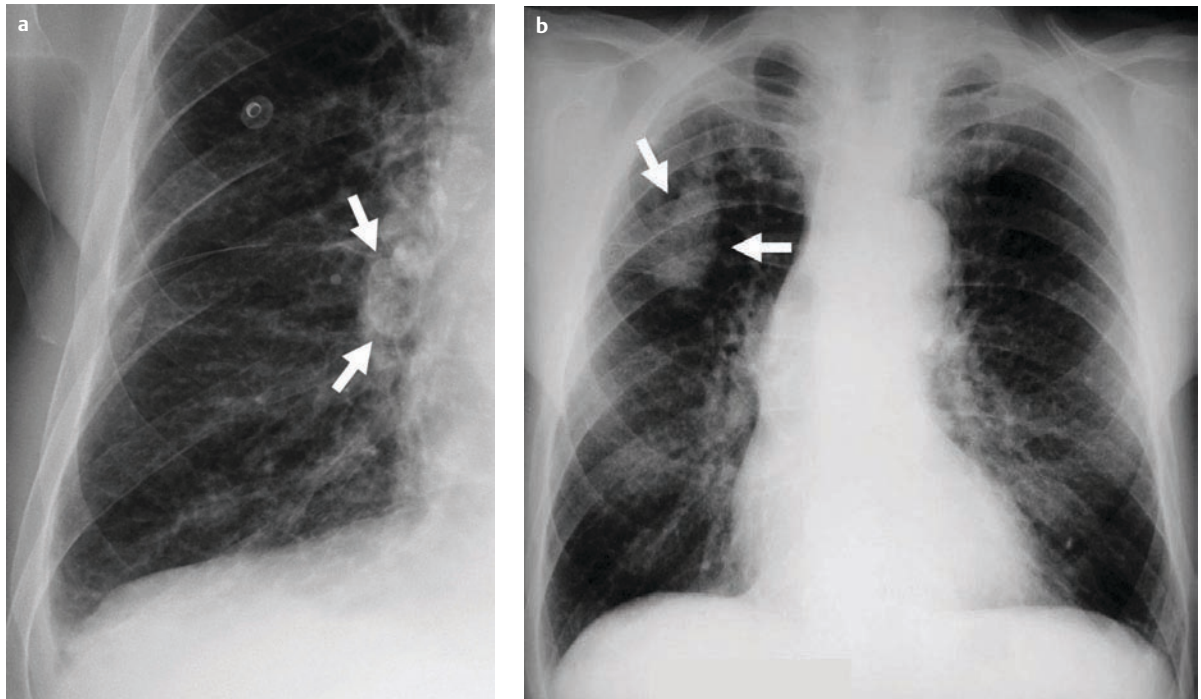


Fig. 6.46 **a** These are micronodular changes as seen in pneumoconioses. The hilar lymph nodes illustrate the typical “egg-shell calcifications” of silicosis. **b** In addition to the micronodular pattern, silicosis may also present with large confluent granu-

lomas (progressive massive fibrosis)—observe the right lung apex. This entity needs to be differentiated from bronchial carcinoma by careful longitudinal comparisons with previous films.

fibrotic remnants and their consequences are more difficult to deal with.

**Asbestosis:** Exposure to asbestos fibers may result in pulmonary fibrosis (Fig. 6.47a) and pleural reactions, so-called asbestos-related pleural disease. Pleural effusions and pleural plaques occur. Often the plaques calcify in a characteristic fashion—a dense, thin calcification on top of a thick soft tissue plaque that has reminded German-speaking radiologists of the famous “Tafelberg,” the flat-topped mountain in South Africa’s Cape Town (Fig. 6.47a). In patients with recurring pleural effusions and pleural plaques, the lung may collapse and, because it is connected to the pleural abnormality by fibrous bands, may spiral up to form the so-called “rounded atelectases” (Fig. 6.47b).

**Sarcoidosis:** A chronic micronodular pattern is frequently found in sarcoidosis, a granulomatous disease that almost always manifests itself in the lung. Clinical symptoms may be absent or very nonspecific. Often the hilar and mediastinal lymph nodes are enlarged (Fig. 6.48a), which naturally necessitates the differentiation from lymphoma or tuberculosis. Occasionally the characteristic noncaseating granulomas become very large. If the disease does not respond to therapy, severe lung fibrosis develops (Fig. 6.48b, c).

**Miliary tuberculosis, histoplasmosis:** Inactive miliary tuberculosis has already been dealt with (see Fig. 6.38b).

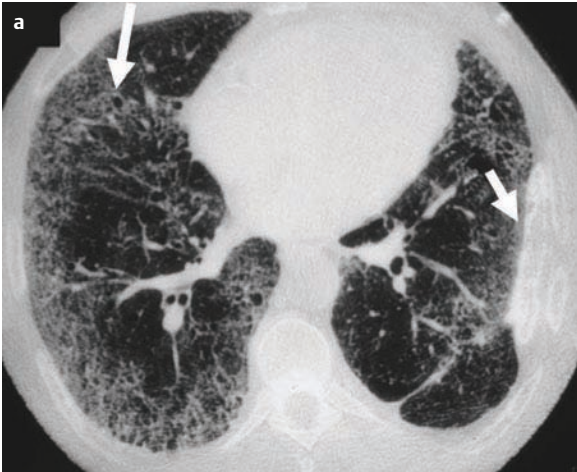If you practice medicine in the Mississippi or Ohio River Valley, in Jamaica, or in a number of other attractive places, and if you handle a population of bat cave visitors, you have to consider histoplasmosis in your differential. Both entities may look alike.

**Lymphangitic carcinomatosis:** Micronodules along the major interstitial structures—that is, the fissures, bronchi, and the interlobar septae—are found in a malignant infiltration of the interstitium: lymphangitic carcinomatosis (see Fig. 6.34b). The infiltration tends to begin in the hilar region and then proceeds to perihilar lung. The differentiation to sarcoidosis is, of course, of paramount importance for the appropriate choice of therapy.

**Idiopathic pulmonary fibrosis:** Idiopathic pulmonary fibrosis may occur in patients without pulmonary risk factors. The basal lung shows thickened interstitial septae, bullae, and bronchiectasis. This appearance of the disease is also called “usual interstitial pneumonitis” (UIP, Fig. 6.49a) (also known in Canada and the United Kingdom as IPF, interstitial pulmonary fibrosis) and it is resistant to treatment. If at the same time acinar/alveolar opacities are detected in an HRCT, a *desquamative interstitial pneumonitis* (DIP, Fig. 6.49b) is more likely to be present. Differentiation between the two is essential since the alveolar component of DIP is successfully treated with corticosteroids and its prognosis is much better. In severe cases,

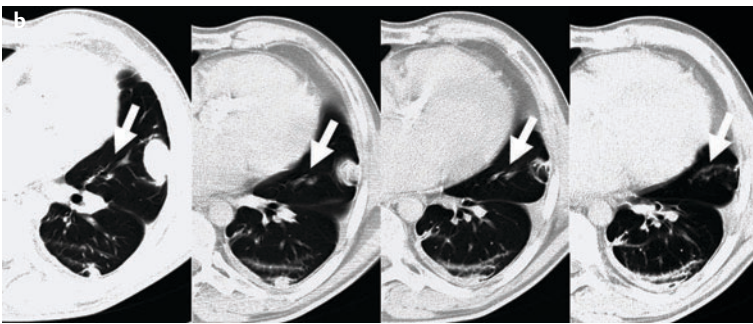


## Asbestosis

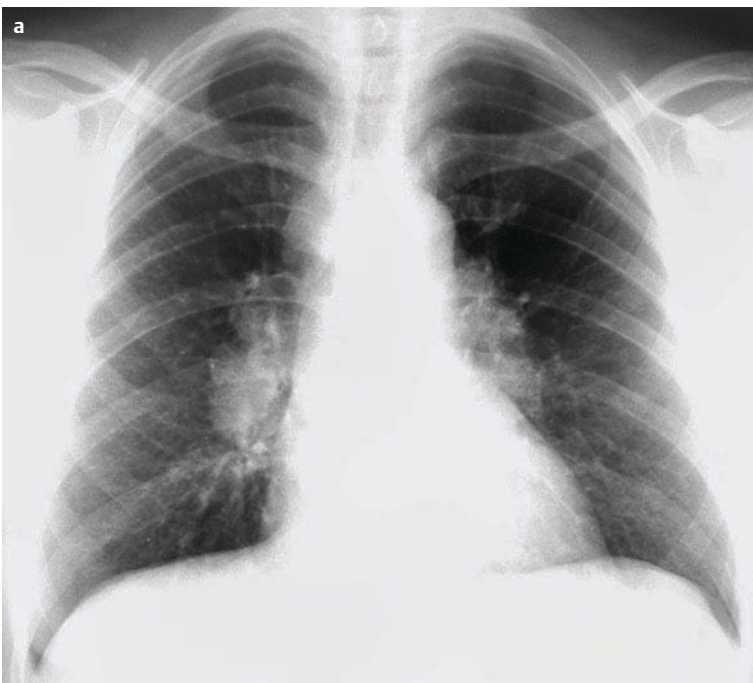


**Fig. 6.47 a** In asbestosis, peripherally accentuated pulmonary fibrosis with scarring, small bullae, and bronchiectasis (long arrow) develops. The pathognomonic extensive pleural plaques often have a calcified flat and smooth top (short arrow), also called “Tafelberg” (tophats).

**b** In recurring and chronic pleural effusions, lung components may collapse and spiral up into a special kind of atelectasis: the so-called “round atelectasis,” which must be differentiated from malignant lesions. The typical comet-tail sign (arrows) that shows the spiral course of the pulmonary vessels into the lesion helps in the differentiation. If the radiographic appearance suggests rounded atelectasis, simple follow-up imaging may be scheduled to assess stability or resolution over time.



## Sarcoidosis



**Fig. 6.48 a** The central lung parenchyma (also see **b**) has an abnormal micronodular appearance. The hilum is notably enlarged—lymph nodes full of noncaseating granulomas are the cause of the change.

## Sarcoidosis

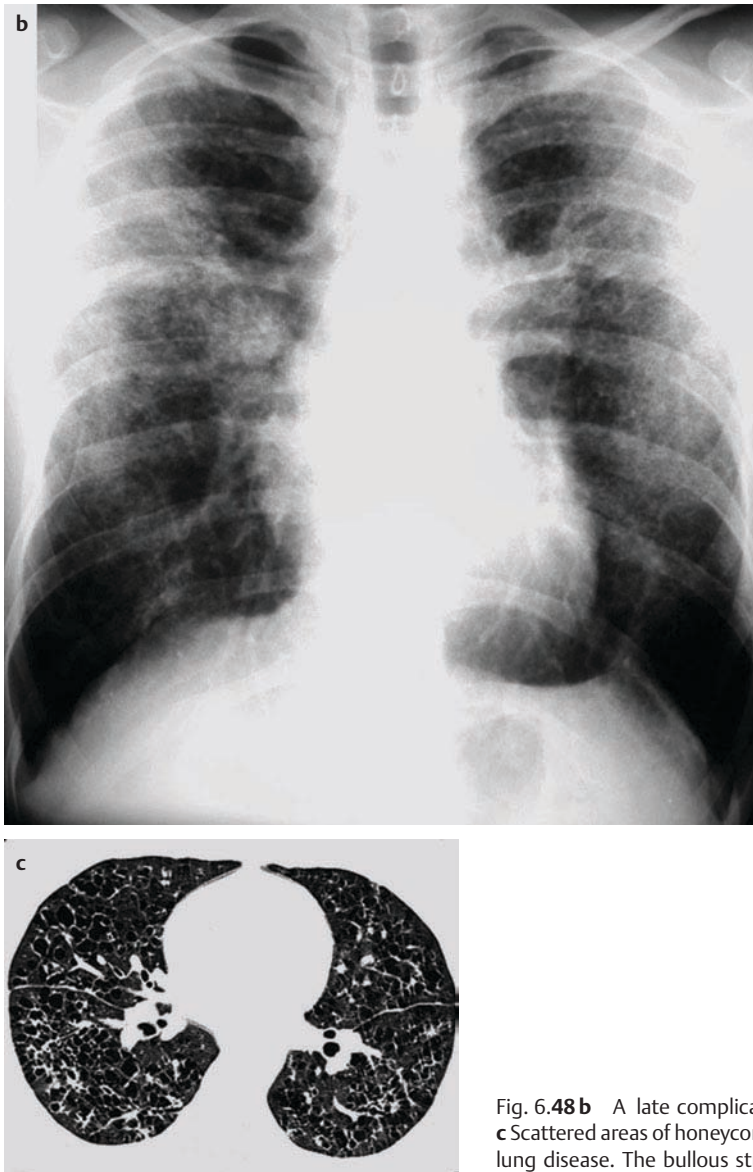


Fig. 6.48 **b** A late complication can be pulmonary fibrosis. **c** Scattered areas of honeycombing are seen, which are hallmarks of end-stage lung disease. The bullous structures are best appreciated in HRCT.

particularly of UIP, lung transplantation is the only treatment option.

**Cystic fibrosis:** If Mr. Coalfire were younger, severe generalized changes of the lung architecture could point to cystic fibrosis (Fig. 6.50).<sup>\*</sup> The rather typical pattern is due to dilated bronchi some of which are plugged with viscous mucus.

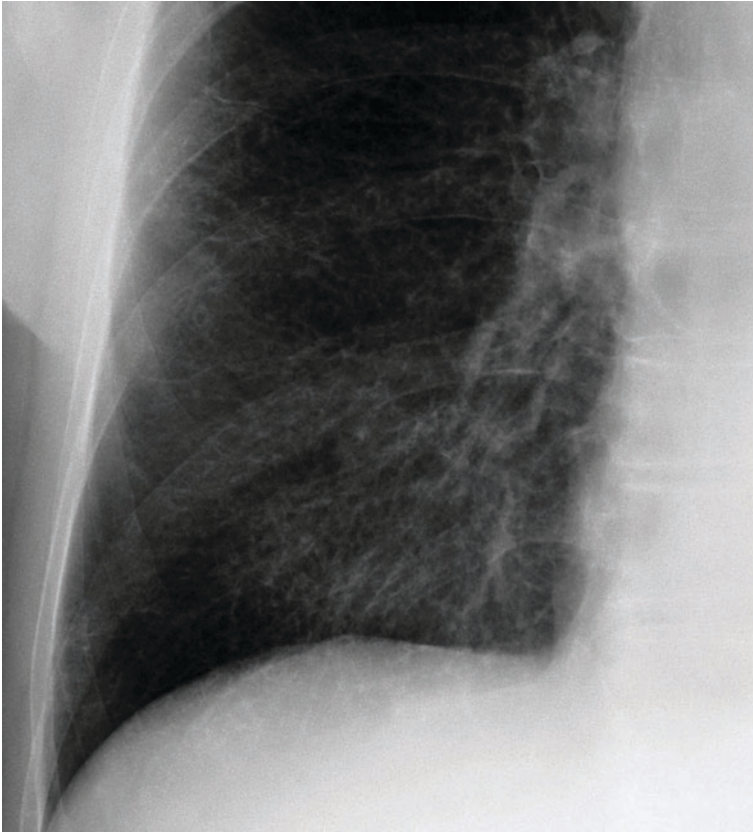
<sup>\*</sup>Only state-of-the-art constant mucolytic and antibiotic therapy lets these patients reach adulthood. They suffer from recurring bouts of pulmonary infections.

**Lymphangioleiomyomatosis:** Lymphangioleiomyomatosis is a disease that occurs almost exclusively in young women, characterized by proliferation of atypical smooth muscle in pulmonary lymphatic vessels, blood vessels, and airways. Gradually progressive interstitial lung disease, recurrent chylous pleural effusions, and recurrent pneumothoraces are among the sequelae of this disease, which leads to the demise of the patient unless lung transplantation is performed. There is a multitude of other special diseases of the pulmonary interstitium. They are difficult to discriminate and, as a student and nonpulmonologist, you will not be asked to do so.

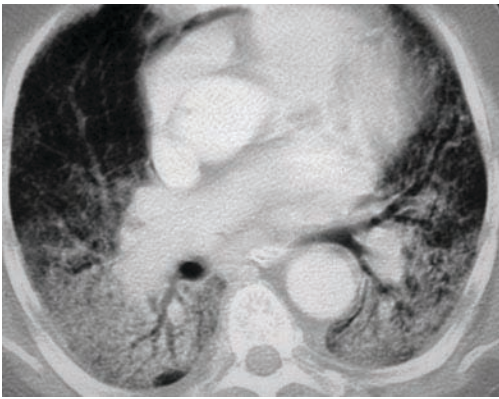
→ **Diagnosis:** Hannah and Paul are a little exhausted after browsing through the differential. They have agreed that

## Idiopathic Lung Fibrosis

### a “Usual interstitial pneumonitis” (UIP)/idiopathic pulmonary fibrosis (IPF)



### b “Desquamative interstitial pneumonitis” (DIP)



**Fig. 6.49 a** The fine linear and reticular structures in the periphery—much like Kerley lines—indicate changes of the interstitium in pulmonary fibrosis. The heart is small, the vascular filling is normal, and there are no clinical signs of pulmonary venous congestion.

**b** Additional alveolar opacities in desquamative interstitial pneumonitis (DIP) point to an active process potentially responsive to therapy with corticosteroids.

this could very well be a case of idiopathic lung fibrosis. They have talked to the patient and have not found anything in the way of an occupational risk: Mr. Coalfire was a bricklayer all his life and has always enjoyed the fresh air—OK, OK, he has smoked quite a bit but quit about 8 years ago. An HRCT will verify the diagnosis and determine whether therapy with steroids has a fair chance of success.

**!** Generations of gray-haired radiologists plus the WHO have committed themselves to the classification of micronodules in CXRs—mainly to classify findings in occupationally exposed workers with lung disease to determine their entitlement to worker’s compensation. High-resolution chest CT has facilitated this effort enormously. Fortunately, the number of exposed workers decreases continuously as occupational legislation is improved and enforced and as technology moves on.



## Cystic Fibrosis

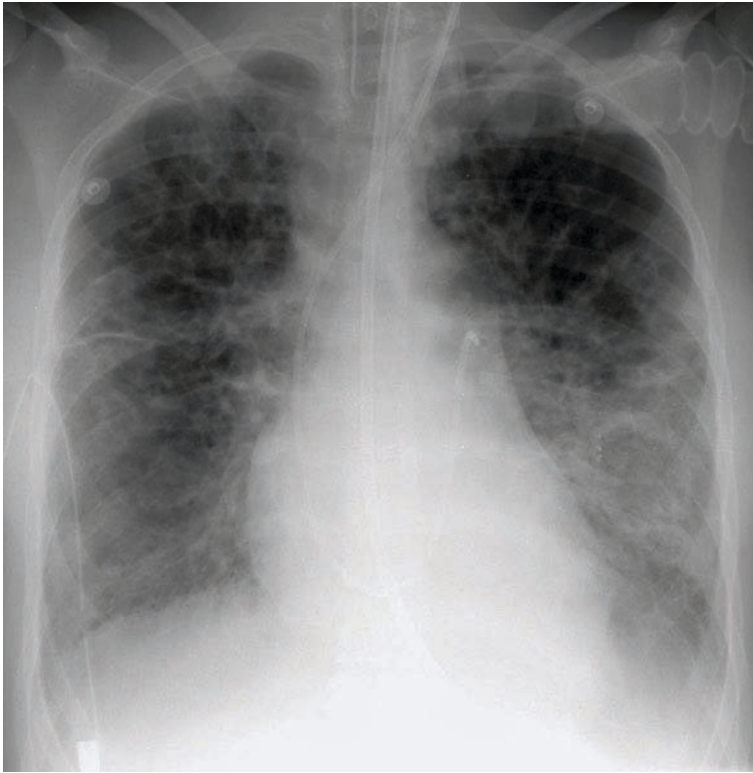


Fig. 6.50 The generalized, irregularly dilated bronchi in cystic fibrosis produce the characteristic bullous pattern. This patient is currently in the intensive care unit for a relapsing pneumonia.

## 6.5 Pulmonary Symptoms without Correlating Findings in the Chest Radiograph

### Checklist: Pulmonary Symptoms without Correlating Findings in the CXR

- Was a myocardial infarction ruled out?
- Has the possibility of a pulmonary embolus been considered?
- Are the symptoms suggestive of an aortic dissection?

### But Those in the Dark Remain Unseen

Undira Candi (65) complains about sudden tremendous chest pain and increasing shortness of breath. An ECG and the laboratory tests have been ordered in the emergency room but the results are not out yet. The CXR is ready for inspection (Fig. 6.51). Giufeng scrutinizes it with great care while Ajay looks over her shoulder. At first glance she cannot find any abnormality. Ajay agrees. Based on their observations they rule out a relevant pulmonary venous congestion as a consequence of left heart failure in myocardial infarction. Doc Reginald, the registrar on call covering the emergency room, stops by and scratches his

head: He worries about a pulmonary embolism, which is the most serious cause of unexplained dyspnea. He wants a venogram or a Doppler ultrasound of the lower extremities and a ventilation/perfusion scan, possibly a pulmonary angiography after that—and he wants Giufeng and Ajay to organize all of it. Giufeng gives him her best irritated look and suggests bringing Mrs. Candi to the CT scanner at once to answer all questions with just one examination—a “one-stop-shop” procedure. That one examination would suffice to cover the whole differential, she declares. Ajay is really impressed and Reginald complies after just a little resistance.

### → What Is Your Diagnosis?

**Pulmonary embolism:** Pulmonary embolism is a frequent disease and also frequently overlooked—in excess of 50%; the CXR tends to be normal.

! Most pulmonary embolisms are not diagnosed because the entity is not considered at all.

Only in extensive lung embolism are platelike atelectases (Fig. 6.52), lung infarctions (Fig. 6.53a), and associated pleural effusions seen on the standard CXR. Owing to the lack of perfusion, the pulmonary vessels may constrict (“Westermark” sign), a phenomenon best appreciated in



### The Case of Undira Candi I

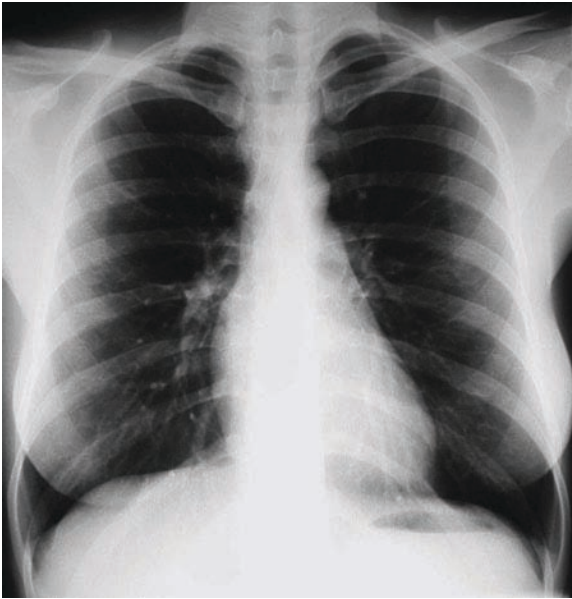


Fig. 6.51 Observe the CXR of Mrs. Candi. Do you agree with Ciufeng and Ajay?

### Pulmonary Embolism: Chest Radiograph

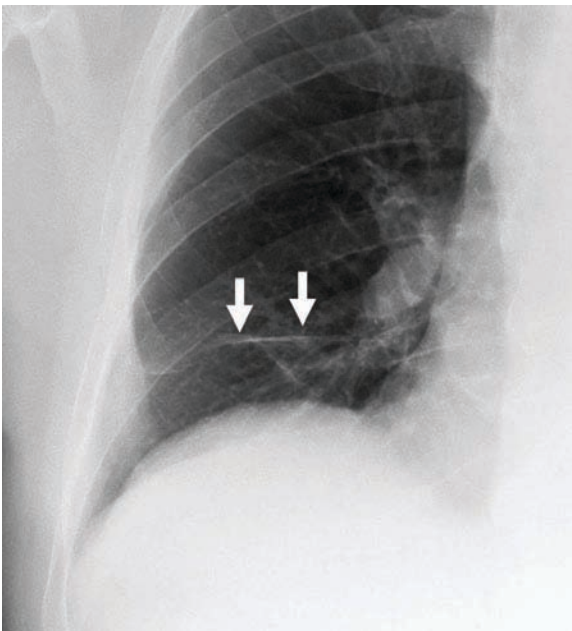


Fig. 6.52 Note the typical basilar platelike atelectasis that is seen in patients with pulmonary embolism but is certainly also a frequent finding in all patients unable to take a deep breath in (for example, after abdominal surgery). The most common finding in patients with pulmonary embolism is a normal CXR.

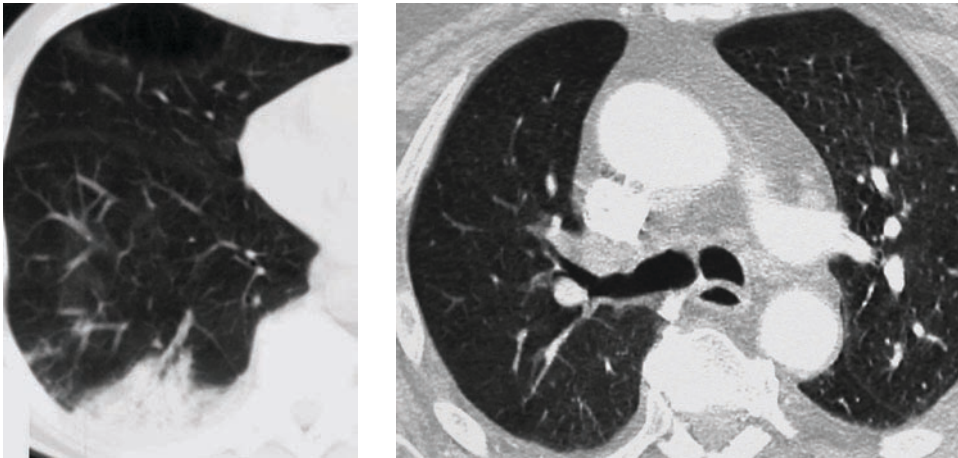
CT (Fig. 6.53a). The ventilation-perfusion scan shows a discrepancy between intact ventilation and missing perfusion to the affected segment of lung, also called “mismatch” (Fig. 6.54a).

! A comprehensive CT protocol for pulmonary embolism nowadays encompasses a CT angiography of the pulmonary arteries (Fig. 6.53b) and a CT venography (performed immediately afterwards and without the need for additional contrast medium administration) starting at the level of the knee joint and proceeding to the confluence of the common iliac veins at the bottom of the vena cava (Fig. 6.53c). Above that level, thrombosis is very rare. Patients with venous thrombosis below knee level do not require treatment with anticoagulation, therefore detection would not alter management significantly.

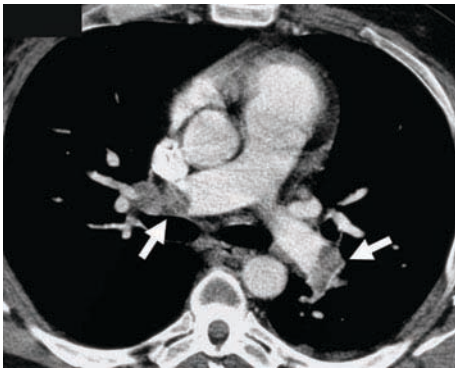
**Aortic dissection:** An aortic dissection starts with an intimal tear, frequently in the ascending aorta just above the valvular level, through which blood enters the aortic wall and separates the aortic wall layers. Aortic dissection occurs frequently in patients with arterial hypertension and those with Marfan syndrome. Excruciating pain and dyspnea occur as often as in pulmonary embolism. If the dissection blocks the origin of a coronary artery, myocardial infarction may ensue. CT angiography of the pulmonary vessels also depicts the aorta in a contrast medium phase that will also demonstrate aortic dissection. In order to exclude both entities in one scan session on a fast multidetector-row CT scanner, the scan delay after beginning of the contrast injection in the CT scanner may need to be increased compared to the exclusion of pulmonary embolus alone, or you need to scan twice in rapid succession in order to ensure that there is sufficient contrast in the aorta. It is very important to determine the involvement of the ascending aorta in aortic dissection (type A), because of the risk of myocardial infarction (Fig. 6.55a, b). A type A dissection thus requires immediate surgery. Fortunately, the cervical vessels exiting the arch often prevent the retrograde extension of dissections originating in the descending aortic arch into the ascending aorta (type B, Fig. 6.55c). Type B dissection is less dangerous and is most often managed conservatively unless relevant organ arteries are occluded. If this happens, the vascular surgeon or the interventional radiologist swings into action: The occluding dissection membrane is perforated with a special technique and/or a stent is applied to restore perfusion (Fig. 6.56).

### Pulmonary Embolism: Diagnosis by CT

#### a Chest CT

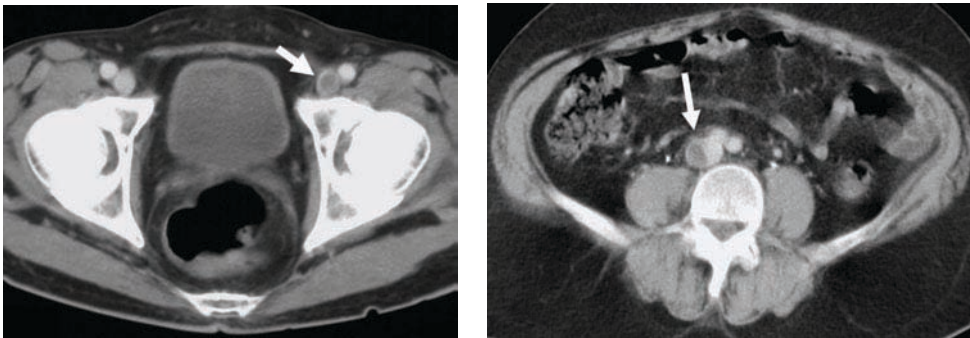


#### b CT angiography

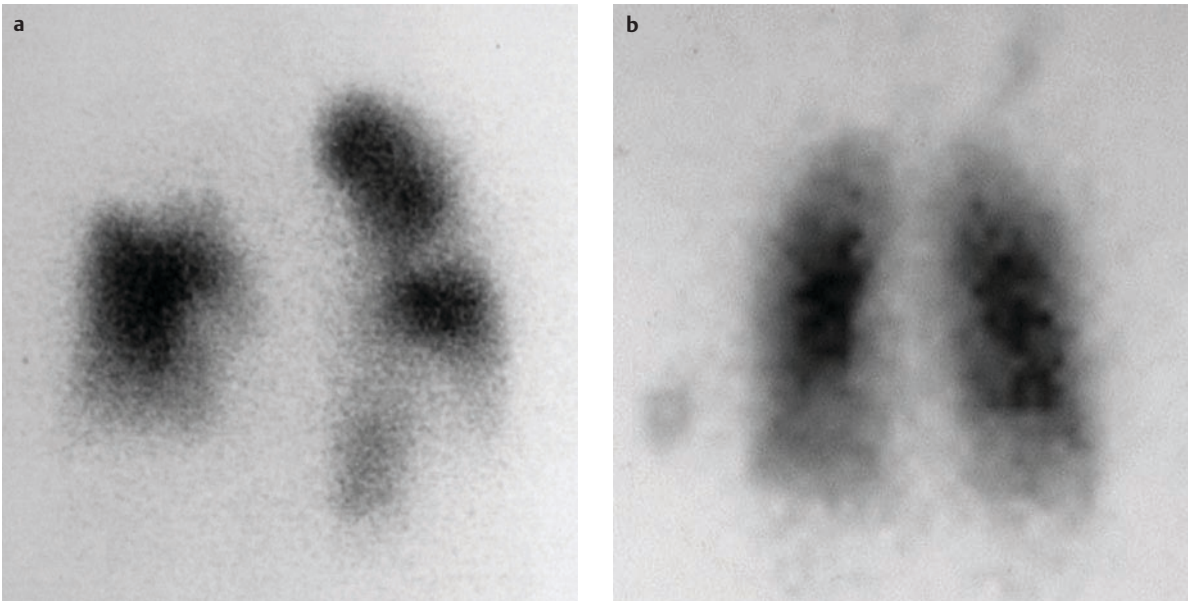


**Fig. 6.53 a** The opacity in the lower lobe shows the typical triangular shape of a vascular territory. This is a classic pulmonary infarction due to pulmonary embolism (left). The reduced perfusion of the right lung is also suggested by the loss of vascular markings (right). **b** The fresh embolic material is appreciated in both pulmonary arteries as central filling defects in the vessel and outlined by the administered intravenous contrast (arrows). An older embolus tends to cling to the vascular wall molded along its circumference. **c** CT venography shows the presumptive cause of the embolism—a thrombus in the left femoral vein (left) that extends up into the inferior vena cava (right). Only the more expensive and cumbersome MR venography rivals the reliability of CT for thrombus detection.

#### c CT venography



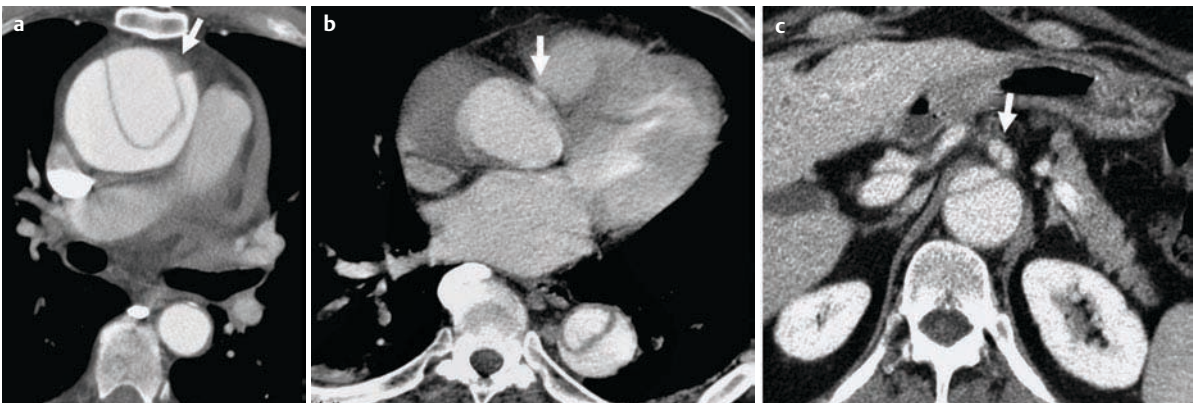
### Pulmonary Embolism: Ventilation/Perfusion Scintigraphy



**Fig. 6.54 a** There is notable absence of radiotracer activity in the right upper lobe on perfusion imaging. **b** On ventilation images, aerosolized radiotracer is normally distributed to the right upper lobe. This mismatch of ventilation and perfusion images points to a pulmonary embolism. With the advent of advanced spiral CT protocols, the importance of this method

in the diagnosis of pulmonary embolism is decreasing continuously. As opposed to CT, the sensitivity of scintigraphy is also hampered by any coexisting pulmonary parenchymal abnormalities such as pneumonia or atelectasis, which are common findings in many patients at increased risk for pulmonary embolus.

### Aortic Dissection



**Fig. 6.55 a** On this scan the dissection membrane is clearly visible within the dilated ascending aorta: It is the detached intima. Along its margins, the intimal flap is still partially connected to the supporting adventitia by arclike fibers (arrow), a phenomenon that helps to decide which is the false lumen. In this case the false lumen is the outer lumen. **b** The large vessels tend to exit from the false lumen. Vessels may also be

obstructed, however. In this patient the outflow of the coronary arteries is still detectable (arrow), but an immediate surgical intervention was necessary. By the way, the aortic dissection is also visible—as in **a**—in the descending aorta. **c** Lastly, the dissection may also extend into larger branch vessels, such as the superior mesenteric artery (arrow).



### Therapy of Aortic Dissection

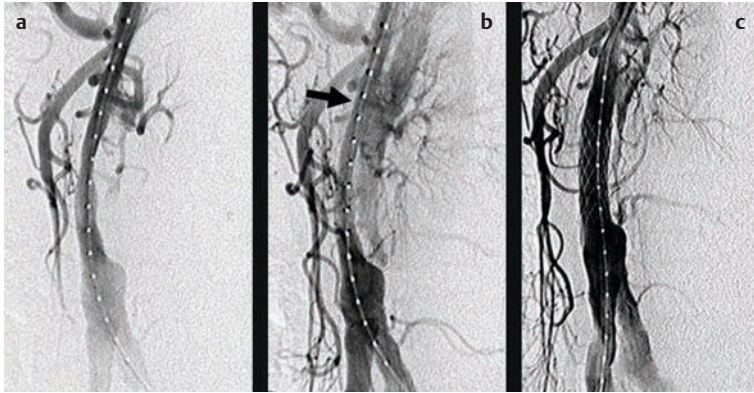


Fig. 6.56 You see an abdominal aortic angiogram of a patient with an iatrogenic type B dissection complicated by extensive claudication. **a** The contrast-filled true lumen is compressed by the unopacified false lumen. The renal arteries are also not opacified. **b** After fenestration of the dissection membrane

(arrow) with a balloon, the renal arteries are reperfused. **c** Because the patient remained symptomatic, the dissection membrane was reapproximated to the vessel wall by deploying a stent (a small expandable wire-mesh tube) distal to the fenestration. This procedure finally provided symptomatic relief.

### Non-Hodgkin Lymphoma

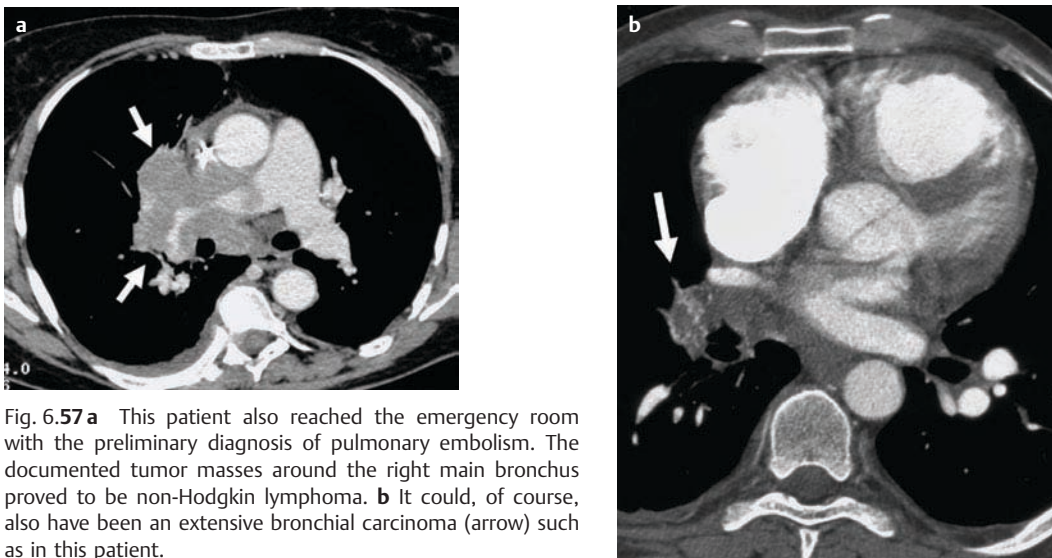


Fig. 6.57 **a** This patient also reached the emergency room with the preliminary diagnosis of pulmonary embolism. The documented tumor masses around the right main bronchus proved to be non-Hodgkin lymphoma. **b** It could, of course, also have been an extensive bronchial carcinoma (arrow) such as in this patient.

**Pneumonia:** Pneumonia can demonstrate similar symptoms and may be all but invisible on plain CXRs—for example, if it is located in the dense retrocardiac area or if the patient is grossly overweight and difficult to image (see Fig. 6.11a). Again, CT will also diagnose this entity without problems.

**Mediastinal/pulmonary tumor:** A mediastinal or pulmonary tumor may also cause clinical symptoms that resemble pulmonary embolism (Fig. 6.57).

→ **Diagnosis:** Giufeng has persuaded Doc Reginald. The immediate CT examination reveals the true problem in this case (Fig. 6.58). A type A aortic dissection is present that needs surgical attention “stante pede” (that is: while standing on this foot, immediately, on the double). Reginald is relieved to have the diagnosis and contacts the thoracic surgeon on call. The senior medical consultant, who has also been alerted, inquires who this bright young lady in the chest imaging unit might be.



### The Case of Undira Candi II

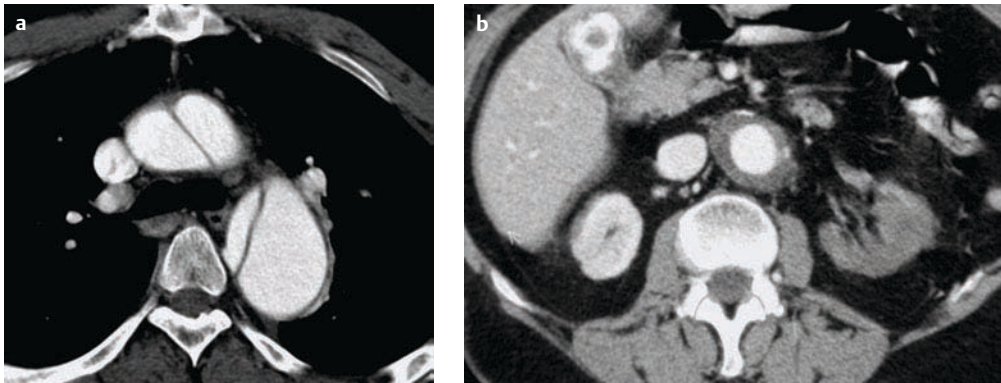


Fig. 6.58 **a** A dissection membrane is well appreciated in the ascending as well as the descending aorta. The coronary arteries are in acute jeopardy. **b** In the abdomen, another problems becomes evident: The left kidney is no longer perfused.

## 6.6 Lesions in the Mediastinum

### Widening of the Upper Mediastinum

#### Checklist: Widening of the Upper Mediastinum

- Was the patient positioned straight?
- Is the trachea narrowed and/or displaced?
- Does the mass pulsate under fluoroscopy?
- Is the mass located anteriorly or posteriorly?

**!** With regard to the etiology of masses in the anterior upper mediastinum, the famous “4 T rule” applies: thyroid, teratoma, thymus, and . . . terrible lymphoma.

#### Truly Large or Just a Matter of Unfortunate Perception?

Robert Waggoner (36) has recently noticed a swelling of his neck. While jogging in the morning he becomes short of breath pretty early these days. The enlarged veins at the neck get in the way of his wet shave. His family doctor has sent him for a chest radiograph on short notice. Joey studies the CXR together with Hannah (Fig. 6.59). The upper mediastinum is definitely widened—Mr. Waggoner has been perfectly positioned for the film. The trachea is stenosed. Both students contemplate the range of differential diagnoses.

### The Case of Robert Waggoner I

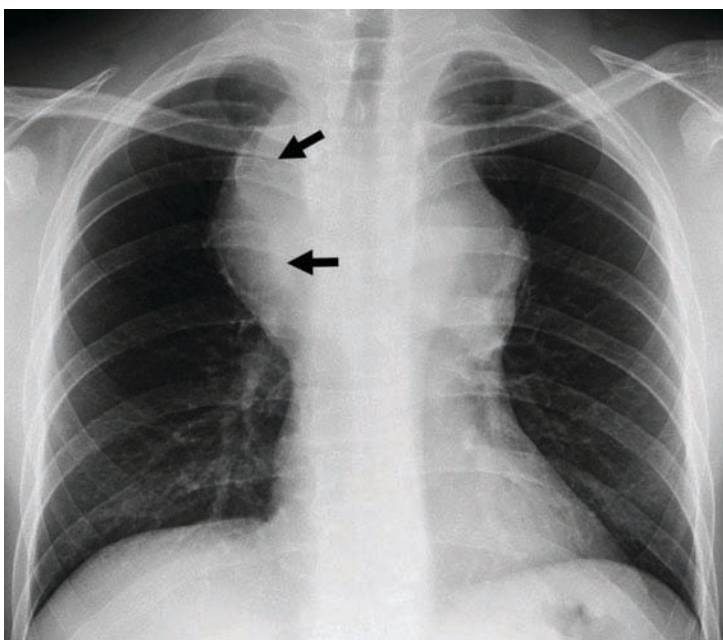


Fig. 6.59 Analyze the CXR of Mr. Waggoner. Which diseases do you have to consider?

## Goiter

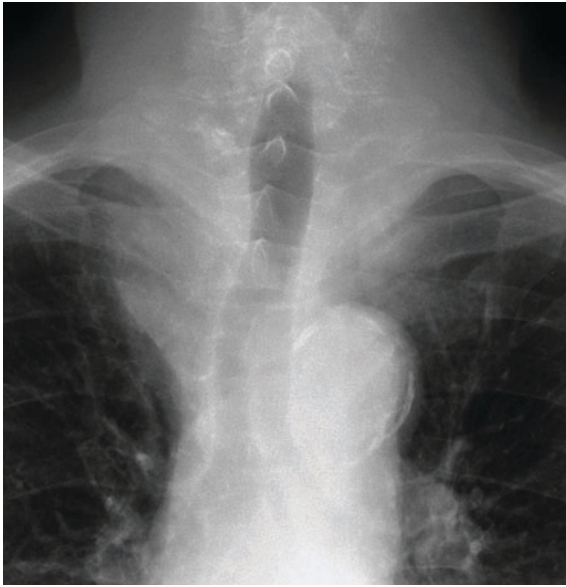


Fig. 6.60 The upper mediastinum is widened, the trachea is compressed by the goiter. Calcified thyroid nodes are not seen.

## → What Is Your Diagnosis?

**Goiter:** Enlarged thyroids are the most frequent masses in the upper mediastinum (Fig. 6.60). They can become enormously large, displace and narrow the trachea, and lead to dyspnea on exertion. Typically they move up and down during swallowing. Frequently nodules develop inside the goiter that calcify coarsely and can become visible on the CXR.

**Lymphoma:** Lymphomas may occur in the upper mediastinum, where they displace the trachea and the vessels. Occasionally a superior vena cava syndrome results that needs therapy fast (and best after sufficient histological samples have been collected by CT-guided core needle biopsy). Naturally, enlargement of the lymph nodes may also be due to inflammatory processes, for example, tuberculosis or sarcoidosis.

**Teratoma:** Teratomas may consist of all elements of the blastodermic layer and therefore can contain fat, rudimentary teeth, and bones (Fig. 6.61). If you unequivocally find any or all of these features on a CT, the diagnosis is a quick and solid one.

## Teratoma

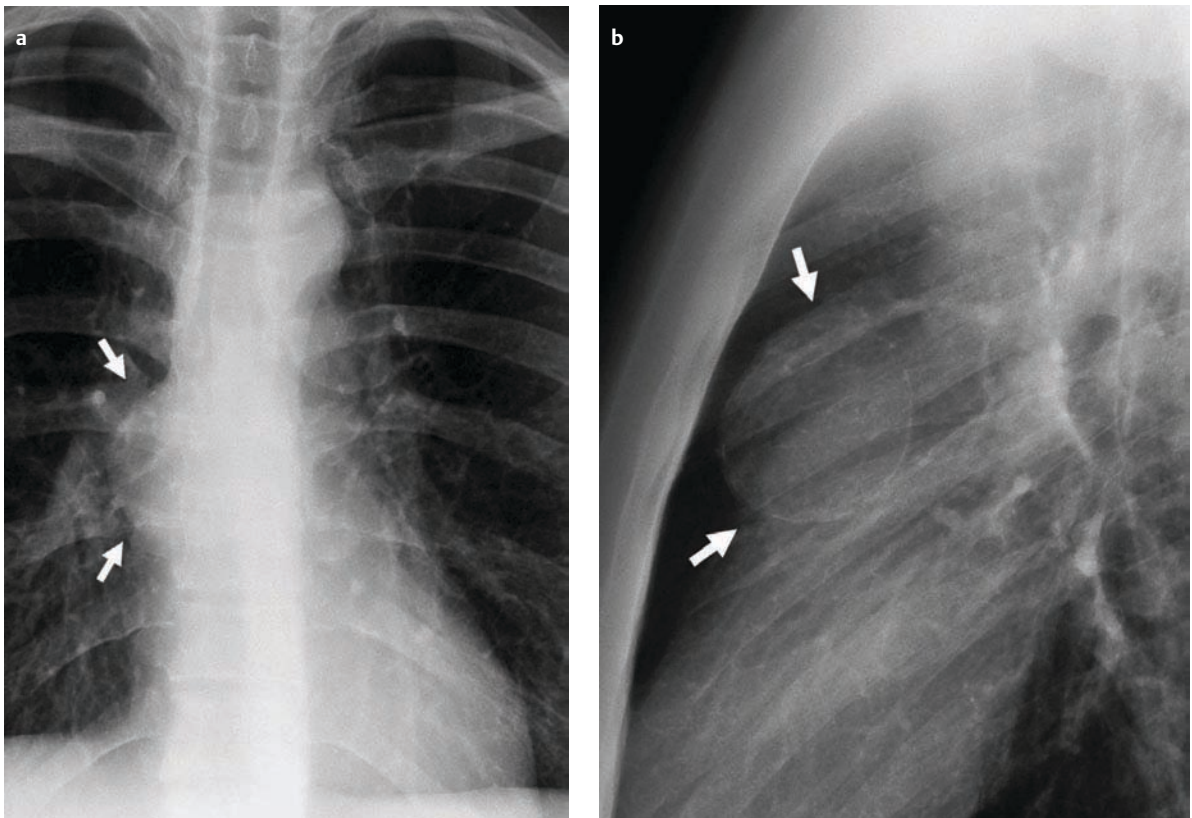


Fig. 6.61 **a** The P-A radiograph of the chest shows a mass projecting below the azygos angle (arrows). **b** The lateral view reveals the anterior location of this partially calcified lesion (arrows). Even if we do not see any teeth, this is a teratoma.

## Aortic Aneurysm

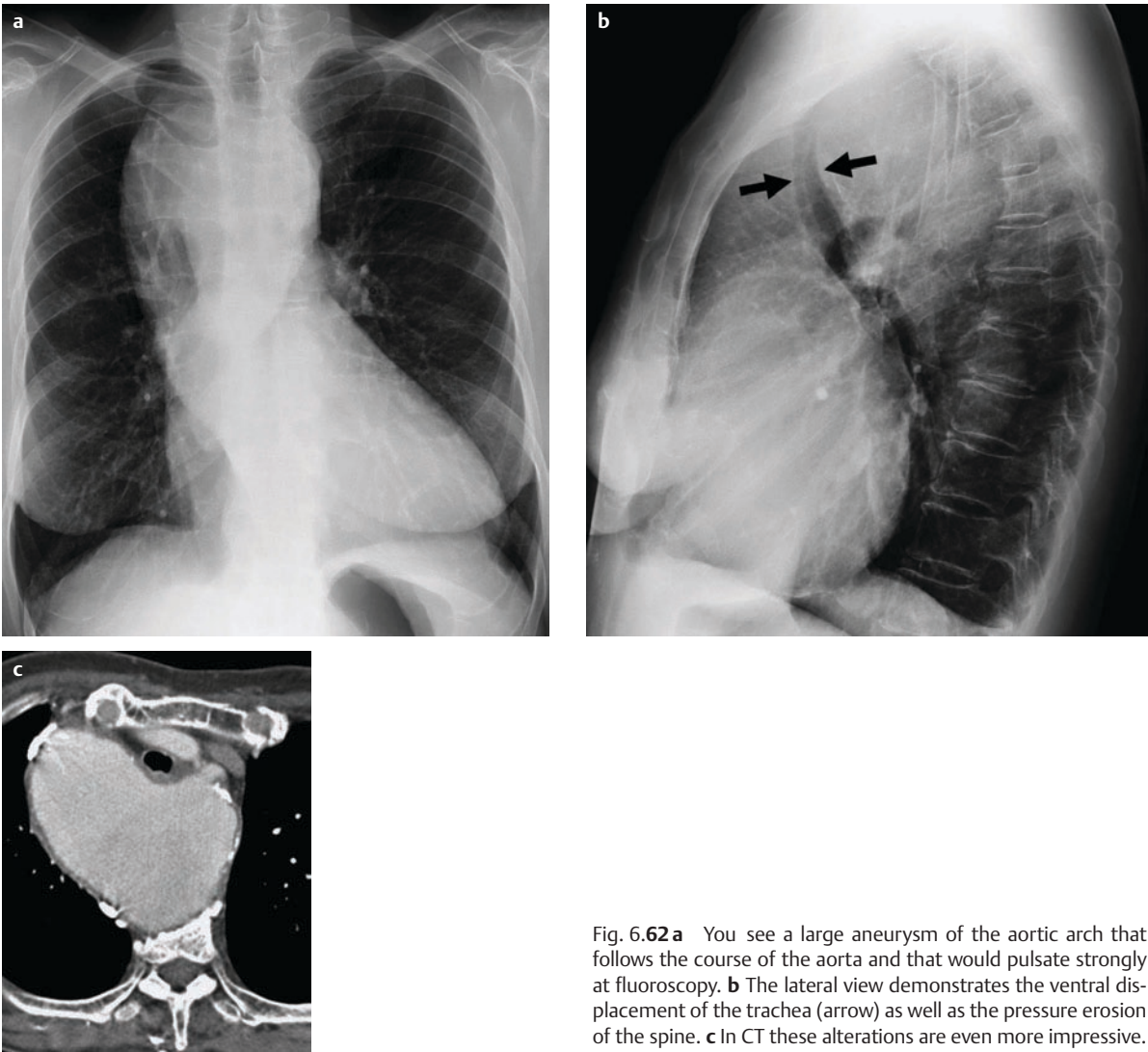


Fig. 6.62 **a** You see a large aneurysm of the aortic arch that follows the course of the aorta and that would pulsate strongly at fluoroscopy. **b** The lateral view demonstrates the ventral displacement of the trachea (arrow) as well as the pressure erosion of the spine. **c** In CT these alterations are even more impressive.

**Thymus/thymoma:** The thymus is large in small children. However, it does not displace the trachea because it is too soft. Its size decreases slowly into adulthood and it may remain visible as a triangular structure in the anterior mediastinum in young adults. This residual thymus can cause problems in lymphoma management: Under chemotherapy lymphoma masses shrink, as does the healthy but stressed thymus. As the therapy is concluded, the thymus recovers and may become larger than before; this “thymic rebound” must be differentiated from residual lymphoma or lymphoma recurrence. Clinically, primary tumors of the thymus are frequently associated with syndrome of myasthenia gravis.

**Aortic aneurysms:** An enlargement of the upper mediastinum can be caused by aneurysms of the aorta and its brachiocephalic branches (Fig. 6.62). These lesions tend to be pulsatile and are located in the middle mediastinum.

**Achalasia:** Certainly diseases of the esophagus can become noticeable on the CXR. They tend to be located in the posterior mediastinum. Particularly impressive is the dilatation of the esophagus, often with impacted food in achalasia (Fig. 6.63).

**!** Achalasia is a premalignant disease.

→ **Diagnosis:** Joey schedules Mr. Waggoner for the next available CT slot (Fig. 6.64). He and Hannah check the CT images and are absolutely convinced that this is a case of superior vena cava syndrome due to lymphoma. They organize a CT-guided biopsy for the same day before the preliminary therapy is started.



## Achalasia

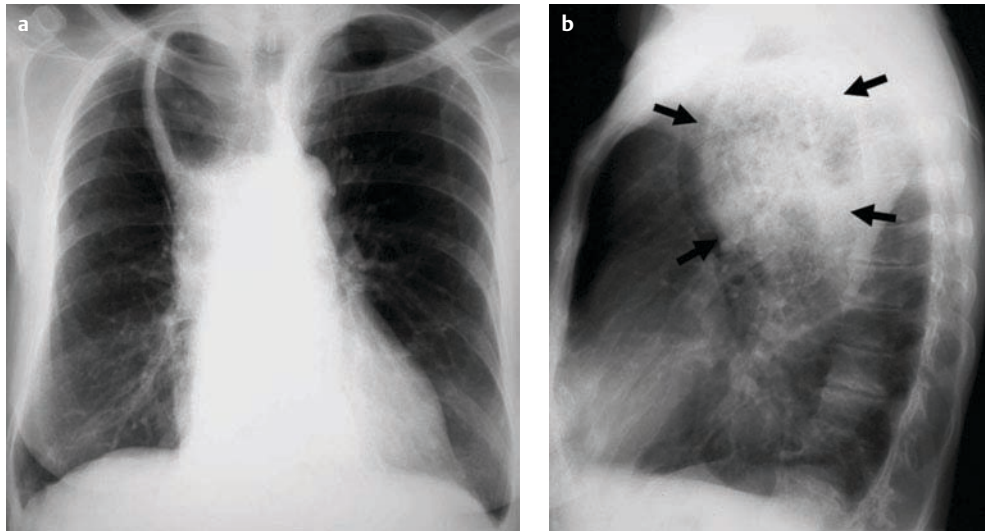


Fig. 6.63 The markedly dilated esophagus in the posterior mediastinum is partially air-filled (a), partially filled with residual food (b, arrows).

! If you see a mass on a radiographic study, ask yourself: Which normal structures in the region could be the source or starting point of the lesion? This approach will jog your mind and help develop a meaningful differential diagnosis.

### Abnormal Findings in the Lower Mediastinum

#### Checklist: Abnormal Findings in the Lower Mediastinum

- Is the heart contour altered in a typical fashion?
- Is the heart contour visible?

#### *In case of a mass*

- Does the mass contain air?
- Does the mass contain calcifications?

### The Case of Robert Waggoner II

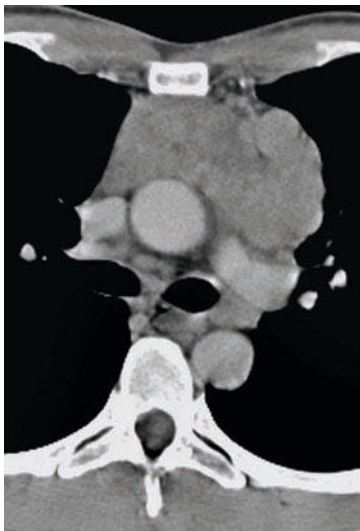


Fig. 6.64 Multiple confluent, enlarged lymph nodes are located in the anterior mediastinum. The interventional radiologist will advance the biopsy needle next to the sternum on the left to get a tissue core.

#### A True Problem of Shape

Martha Myers (56) suffers from urinary incontinence. She has come to get her pelvic floor stabilized surgically. The preoperative CXR is first seen by Giufeng, who notices an abnormality of the lower mediastinum (Fig. 6.65). She considers the most important abnormalities of the lower mediastinum, with special emphasis on cardiac diseases.

#### → What Is Your Diagnosis?

**Cardiomyopathy:** Generalized enlargement of the heart is often due to cardiomyopathy, which may be caused by chronic severe coronary artery disease, can occur as an idiopathic entity, or may be caused by a variety of toxic agents such as alcohol or drugs (Fig. 6.66).

**Pericardial effusion:** A pericardial effusion can enlarge the heart silhouette in all directions. It is best verified with CT (see Fig. 14.29f, p. 327) and, of course, echocardiography.



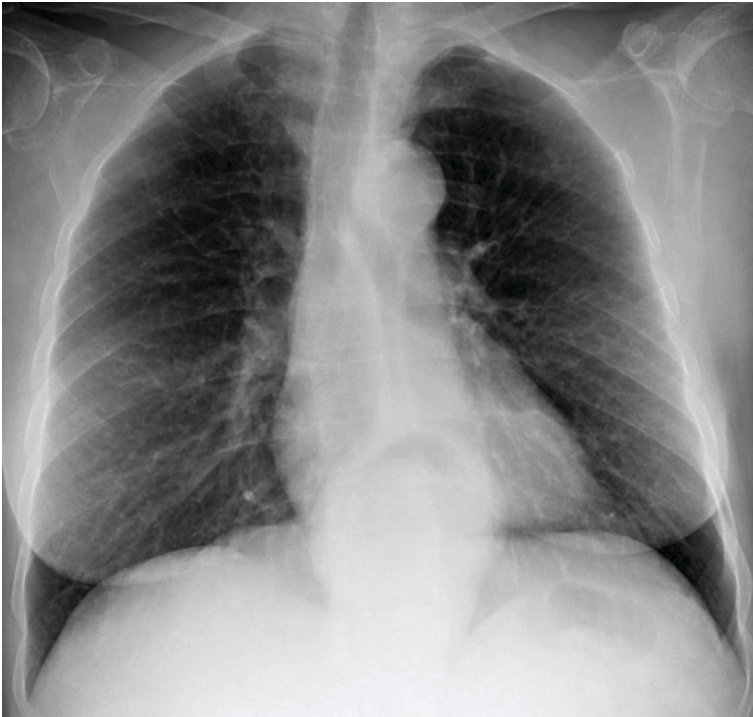
**The Case of Martha Myers**

Fig. 6.65 You see the CXR of Mrs. Myers. What grabs your attention immediately? Can you call the final diagnosis already?

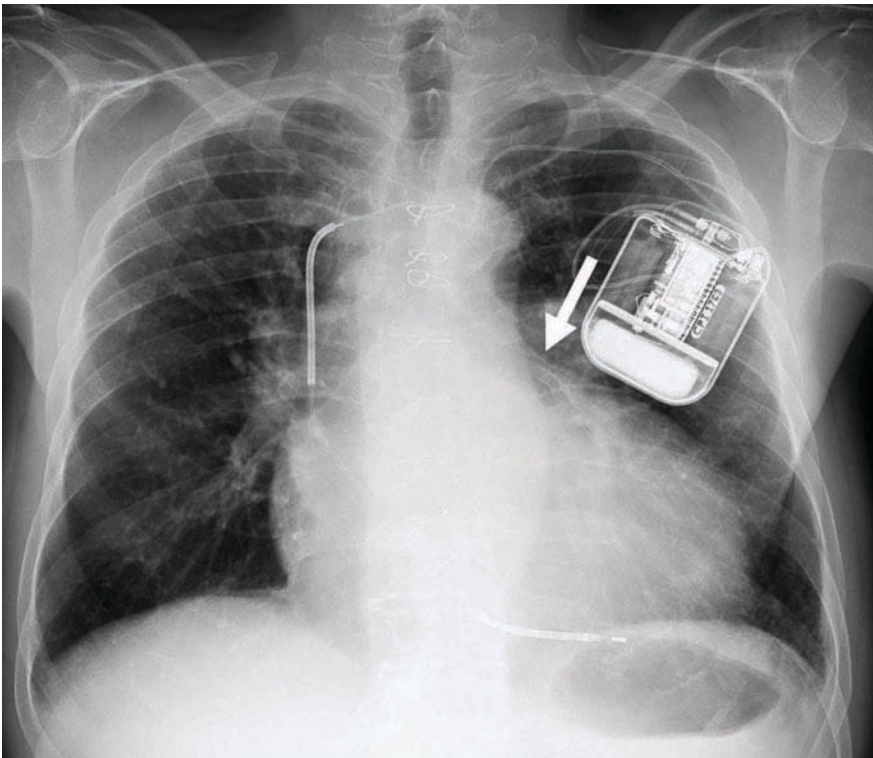
**Cardiomyopathy**

Fig. 6.66 This heart is enlarged as a whole. Coronary artery disease has already necessitated prior stent placement (arrow); arrhythmias have required the implantation of a cardiac defibrillator.

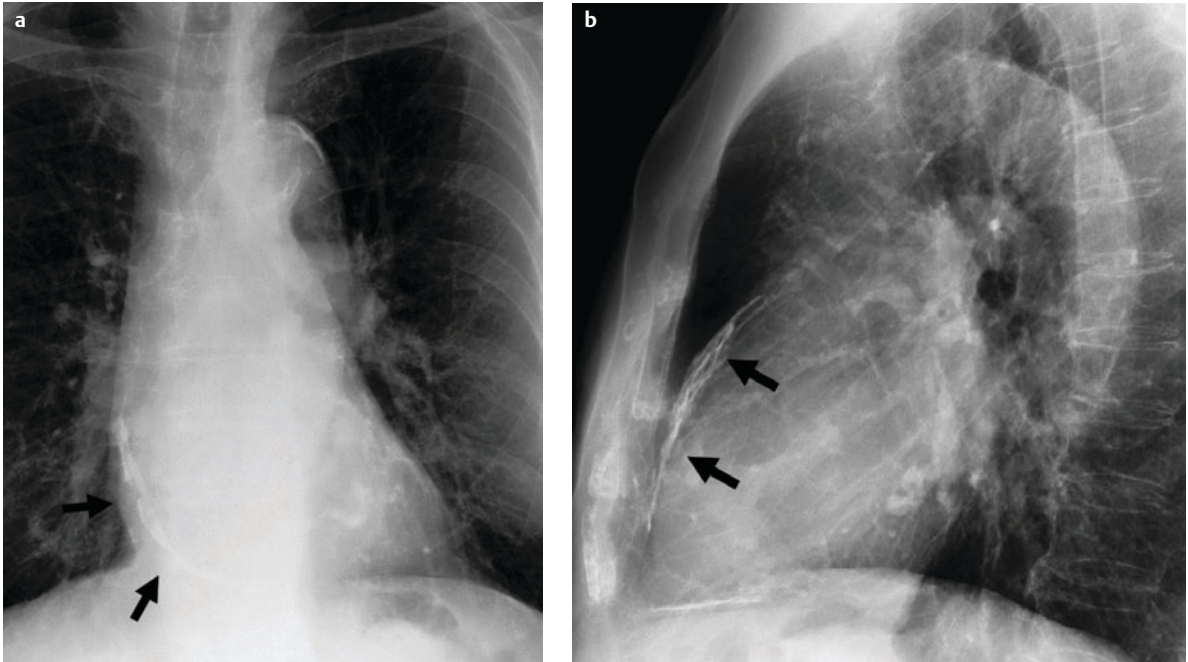
**Constrictive Pericarditis**

Fig. 6.67 Coarse calcifications (arrows) outline the pericardium in this patient. The pericardial mobility is consequently restricted (“Panzerherz”—now how’s that for a German term?).

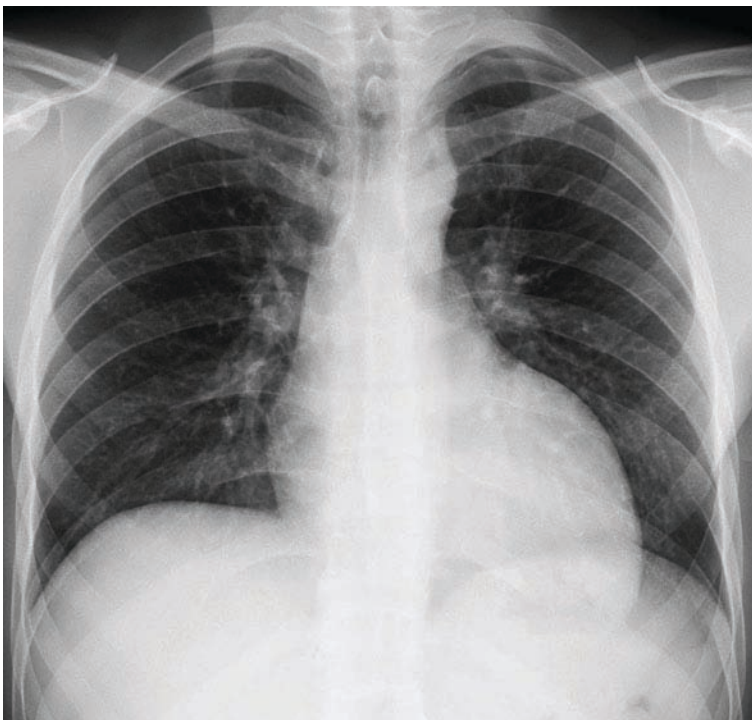
**Left Heart Enlargement**

Fig. 6.68 The left heart contour bulges out significantly as an indication of left ventricular enlargement, due to aortic valve stenosis in this case.



### Right Heart Enlargement

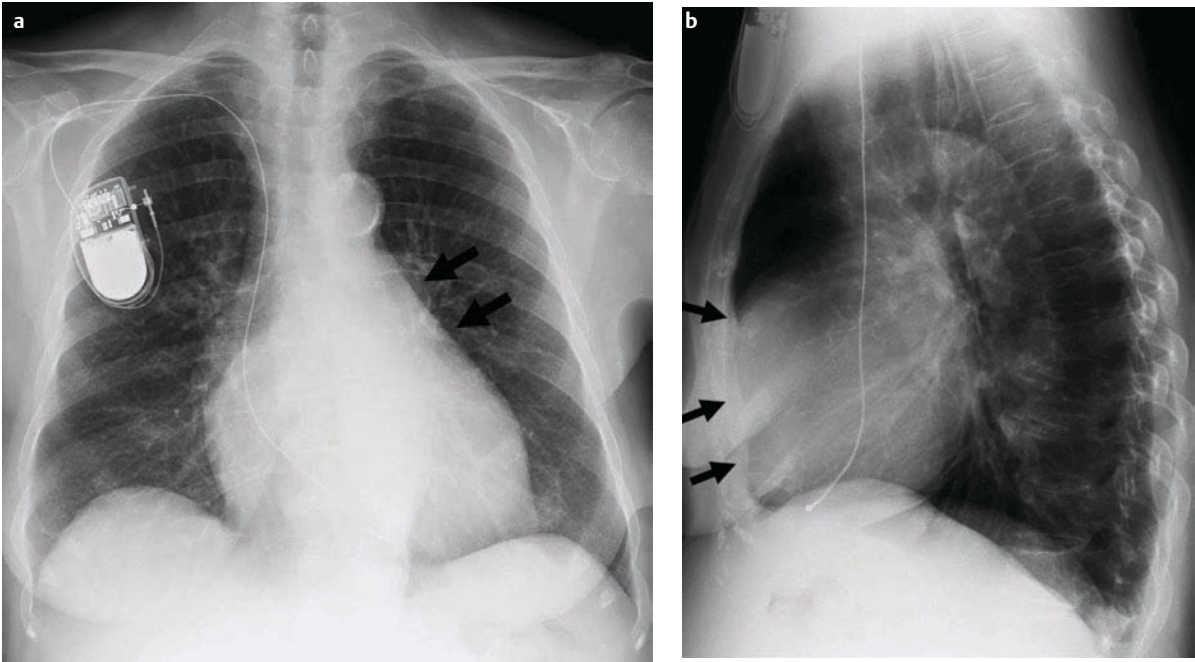


Fig. 6.69 The flattening of the heart concavity (a, arrows) and the enlarged contact area to the sternum (b, arrows) suggest right ventricular enlargement (see Fig. 6.1).

**Constrictive pericarditis:** Constrictive pericarditis is a postinflammatory entity characterized by pericardial calcifications visible especially in the periphery of the heart shadow (Fig. 6.67).

**Valvular calcifications:** Calcifications of the heart valves are best appreciated on the lateral views of the chest and can be assigned to the individual valves (see Fig. 6.2b).

**Left heart enlargement:** Left heart enlargement causes an abnormal but smooth bulge of the left lower heart contour. It occurs in left ventricular hypertrophy, as is seen, for example, in chronic arterial hypertension or in aortic valvular stenosis (Fig. 6.68), and in left ventricular dilatation, for example, in patients with aortic valve insufficiency or decompensated left heart failure, often due to severe coronary insufficiency. In arterial hypertension the left ventricular hypertrophy is frequently associated with an elongation of the aortic arch.

**Right heart enlargement:** Right heart enlargement manifests itself as a flattening or a bulge of the normally concave left upper heart contour. In this location, the pulmonary artery is displaced upward and laterally by the enlarged right ventricle. The enlarged right ventricle occupies the retrosternal space, which is well appreciated on the lateral CXR (Fig. 6.69). If the ventricle is hypertrophic but not enlarged as in pulmonary hypertension due to pulmonary fibrosis, the pulmonary artery is dilated centrally. The result is the typical appearance of a *cor pulmonale* (see Fig. 6.75).

**Left ventricular aneurysm:** A left ventricular aneurysm may develop after an extensive coronary infarction. It appears as a circumscribed bulge of the heart contour (Fig. 6.70).

### Aneurysm of the Cardiac Wall

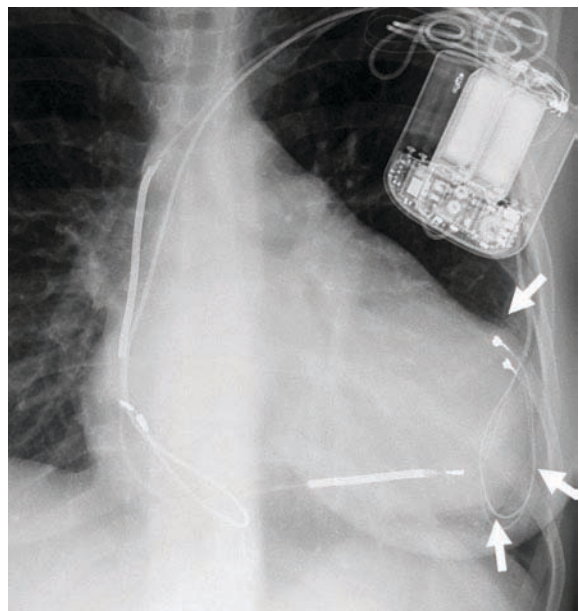
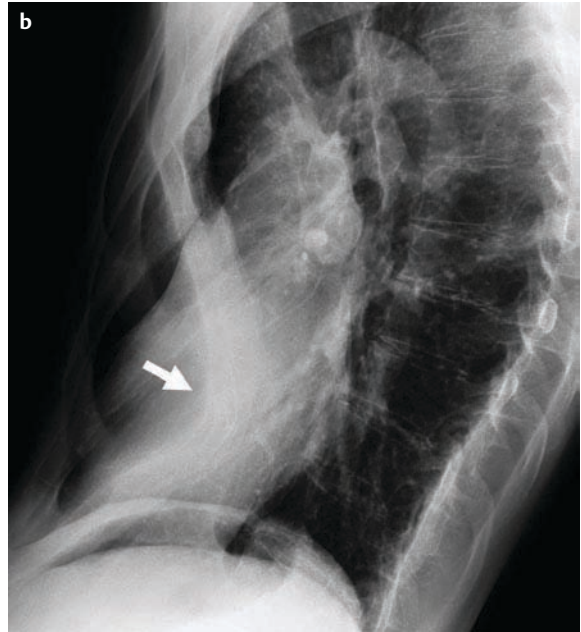
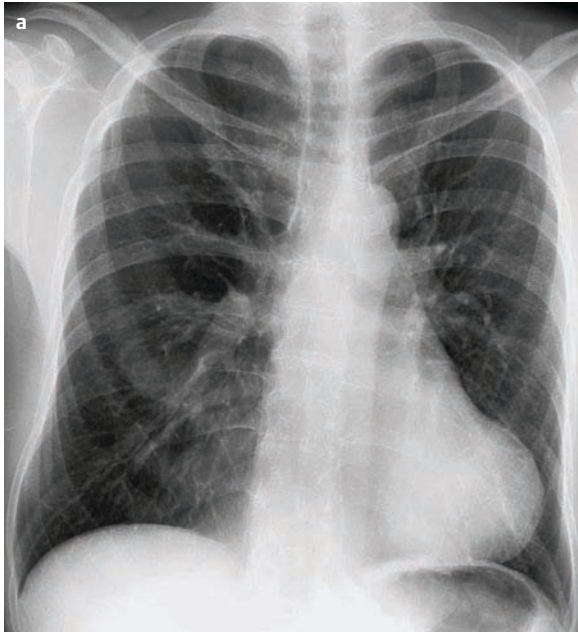


Fig. 6.70 The balloonlike bulge of the left heart contour (arrows) is a left ventricular aneurysm complicating extensive myocardial infarction.

**Funnel Chest**



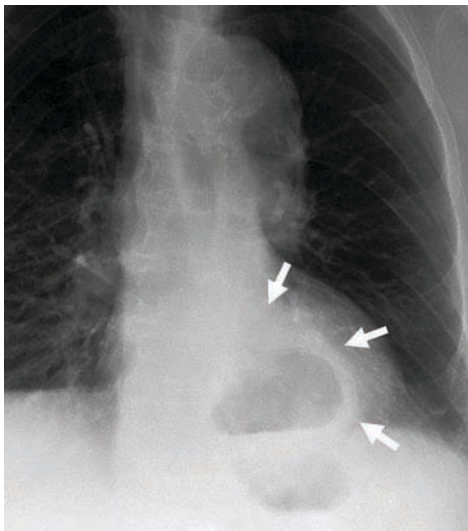
**Fig. 6.71 a** The atypical shape of the heart (do you see the bulge of the left heart contour?) and the obliteration of the right heart contour (“silhouette sign”?) make sense only after inspection of the lateral film.

**b** The sternum (arrow) is located a few centimeters ventral of the spine in funnel chest (pectus excavatum). Of course, the heart is heavily deformed to fit into this chest.

**Funnel chest (pectus excavatum):** A funnel chest can deform the heart silhouette significantly; the underlying sternal deformity can best be identified on the lateral CXR (Fig. 6.71).

**Hiatal hernia:** This entity is the most frequent incidental mass in the retrocardiac space (Fig. 6.72). Owing to its air content and thick wall it is recognized with ease in most cases. If verification is needed, a lateral chest radiograph after ingestion of a small amount of barium will prove the hernia. It must, however, be differentiated from diverticula of the lower esophagus.

**Hiatal Hernia**



**Fig. 6.72** The air-filled thick-walled structure is projecting over the heart shadow (arrows). This is a large hiatal hernia.

→ **Diagnosis:** Giufeng has already seen some hiatal hernias and, as a matter of fact, did not really consider any alternative diagnosis in this case. For Mrs. Myers there won't be any consequence if she has no related complaints.

**!** The analysis of a complex heart configuration on a CXR needs a lot of time and brains and is hampered by a large number of variables. It is a first-rate intellectual challenge. Fortunately for all of us who do not play chess, echocardiography offers answers in less time and with more reliability. In the good ol' days there was more time for analysis—and no alternative. The typical heart configuration on a CXR should, however, be recognized and called by its right name.





### Ben Felson and the Role of Funnel Chests in the Differential Diagnosis

Benjamin Felson was a grand American lecturer and a witty, inspiring radiologist. If you ever get a chance to read his book on chest radiology, go for it. In it he narrowed down a rather long radiological differential to two entities. Of these he picked one because the other one was “about as rare as a funnel chest in the Italian film colony.” Which tells you a lot about humor and Italian movies in the sixties.

## 6.7 Enlargement of the Hila

### Checklist: Enlargement of the Hila

- Is the enlargement unilateral or bilateral?
- Does the hilum in question have a lobulated configuration?
- Are there any hilar calcifications?
- Are there associated pulmonary parenchymal changes (fibrosis, micronodules)?
- Does the mass pulsate during fluoroscopy?

### Just a Few Excess Curves

Hillary Frimpton (42) has called upon her doctor because she has felt unwell for several days and has been suffering from a dry cough. Her doctor has sent her for a chest radiograph. Paul and Giufeng cover the chest imaging unit as Mrs. Frimpton's image pops up on the viewing monitor (Fig. 6.73). The hilar enlargement is obvious.

### → What Is Your Diagnosis?

**Sarcoidosis, lymphoma, tuberculosis, silicosis:** Bilateral hilar lymph node enlargements can be caused by sarcoidosis, lymphoma, tuberculosis, and silicosis. It is the additional findings—clinical and radiological—that help differentiate these entities. In *sarcoidosis* interstitial micronodules are often present in the lung (see Fig. 6.48a, b). In *lymphoma* lymph nodes in other locations are also frequently enlarged (see Fig. 6.59). *Tuberculosis* must be considered particularly in immunosuppressed patients and patients who come from underdeveloped countries. In *silicosis* the enlarged lymph nodes tend to develop characteristic calcifications (see Fig. 6.46a).

**!** A unilateral enlargement of a hilum is indicative of a bronchial carcinoma until proven otherwise (Fig. 6.74).

**Pulmonary hypertension:** Pulmonary hypertension, for example, as a consequence of pulmonary fibrosis or severe chronic obstructive airways disease (Fig. 6.75), triggers dilation of the pulmonary artery as a reaction to the increased vessel resistance. The hila become enlarged accordingly. A contrast-enhanced CT will easily verify the purely vascular nature of the increase in hilar size.

**→ Diagnosis:** Paul checks the CXR very carefully but cannot find any evidence of pulmonary fibrosis or emphysema. The bilateral hilar enlargement is most likely caused by enlarged lymph nodes. Giufeng hopes for sarcoidosis as a cause and the odds are in her favor. If other clinical parameters do not support this diagnosis, a tissue sample will have to be taken—best by way of a bronchoscopy.

### The Case of Hillary Frimpton

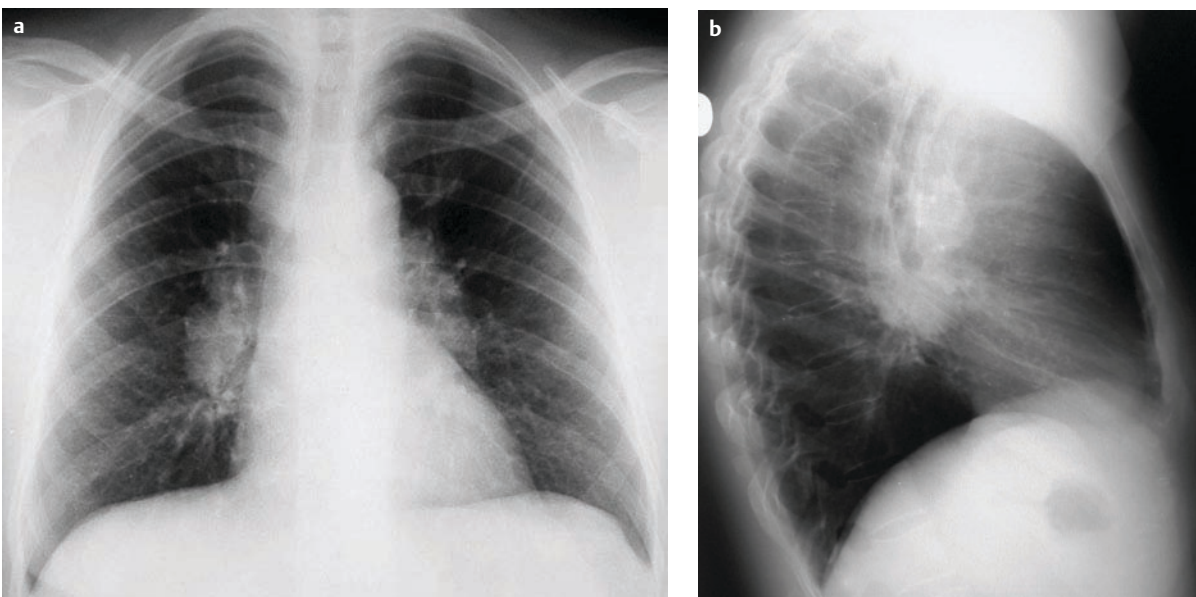


Fig. 6.73 What diseases do you think of when looking at Mrs. Frimpton's films?

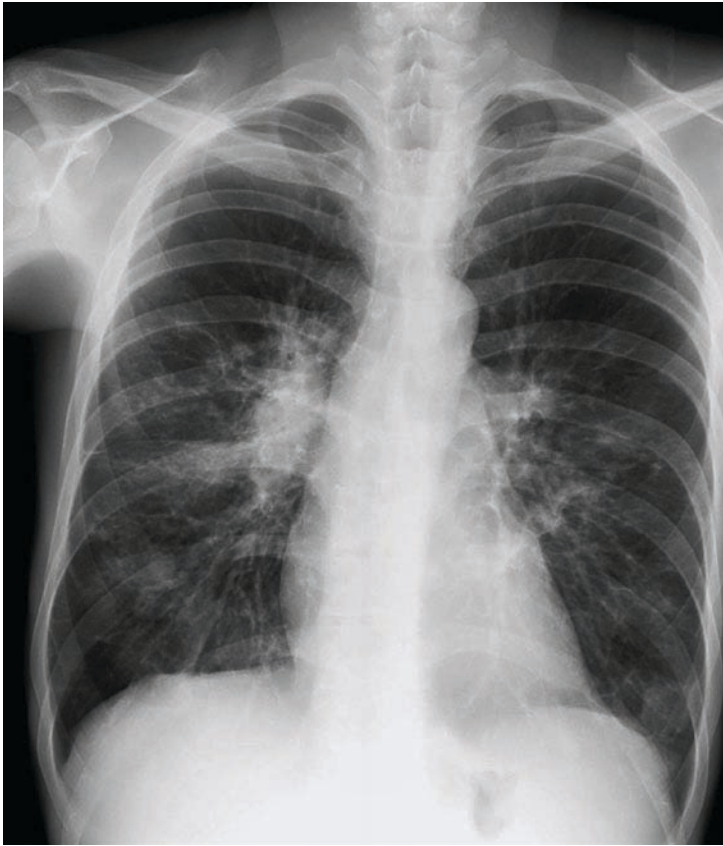
**Bronchial Carcinoma**

Fig. 6.74 The right hilum is definitely enlarged with an irregular margin. This turned out to be a bronchial carcinoma.

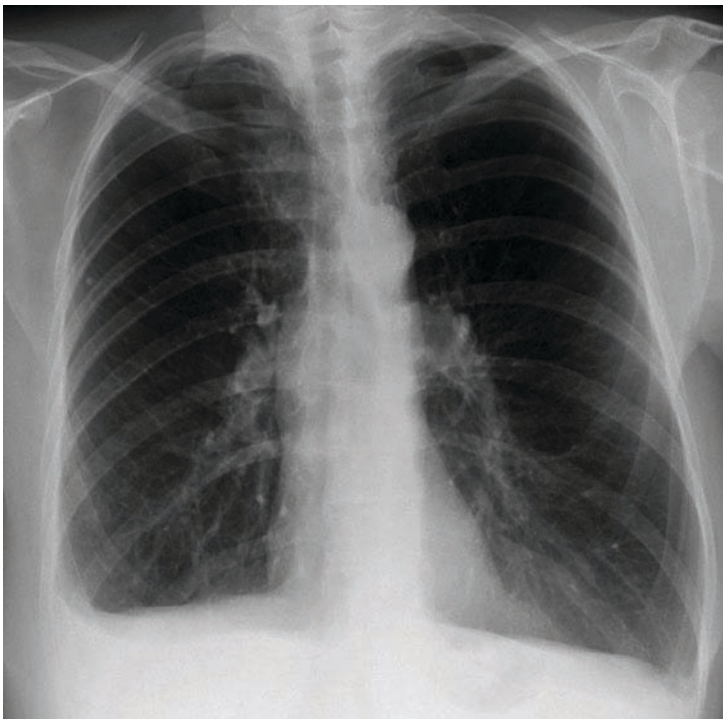
**Pulmonary Hypertension**

Fig. 6.75 The lungs are massively overinflated and the diaphragms are flattened accordingly; the vessels show an irregular course. This is severe emphysema that has led to pulmonary hypertension. The pulmonary artery is consequently dilated and there is a significant step in vascular caliber between the hilum and the lung parenchyma.

## 6.8 The Ultimate Exam

Paul celebrates his last day in the chest unit and has brought along a large box of cookies. It is late in the afternoon and Giufeng eats one biscuit after the other while sipping her cappuccino and listening to Paul's bright

future plans with great amusement. Suddenly Gregory comes around the corner holding a pack of films in his hands. He senses the very special occasion and whips some of his films on the viewbox. "How about a tiny test, Paul?" he roars and pats him on his shoulder. Giufeng stops sipping her coffee and puts the cookies down with a smile, looking forward to a little entertainment. "Histoire

### Test Cases

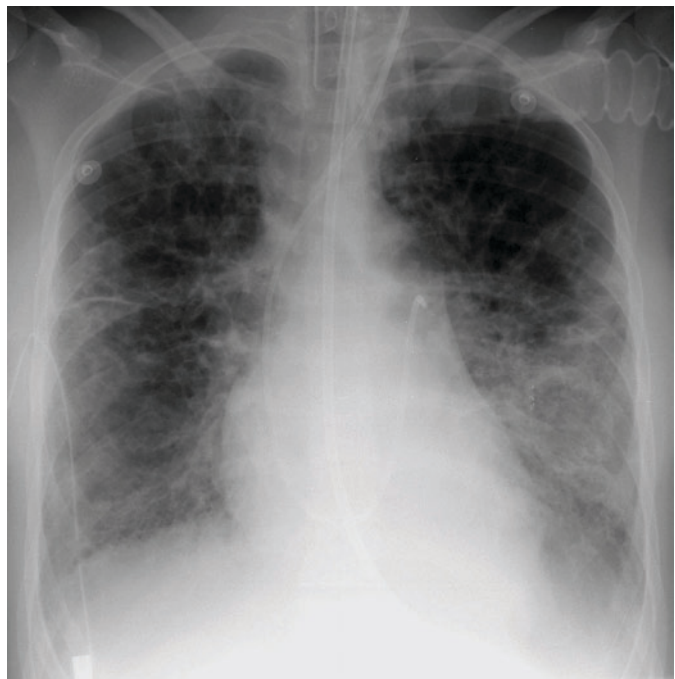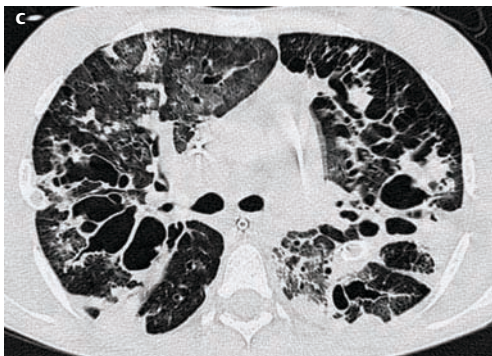
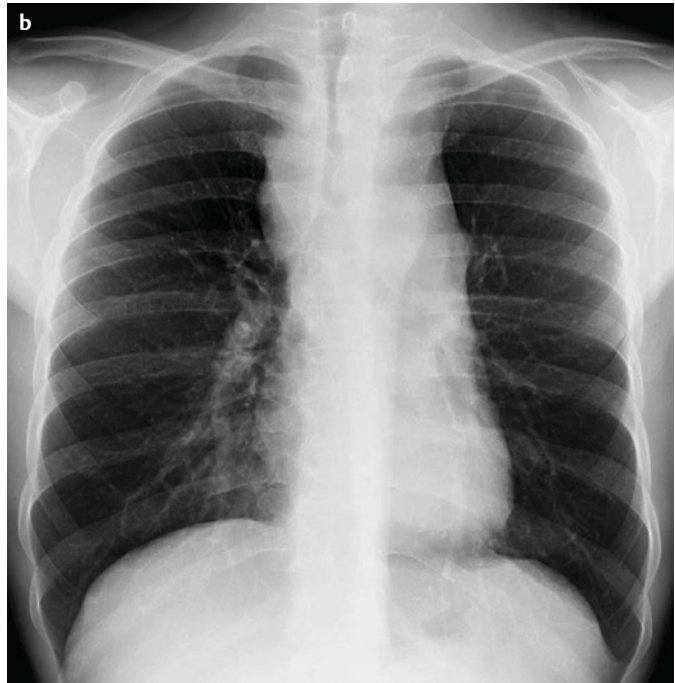
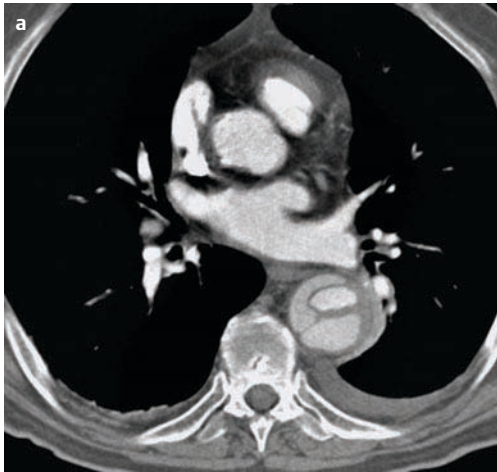


Fig. 6.76a–h

**a** Sudden severe chest pain is the symptom in this patient.

Don't stop with the basic diagnosis! Classify it further.

**b** This patient comes with dyspnea of two days' duration.

**c** History is withheld.



## Test Cases

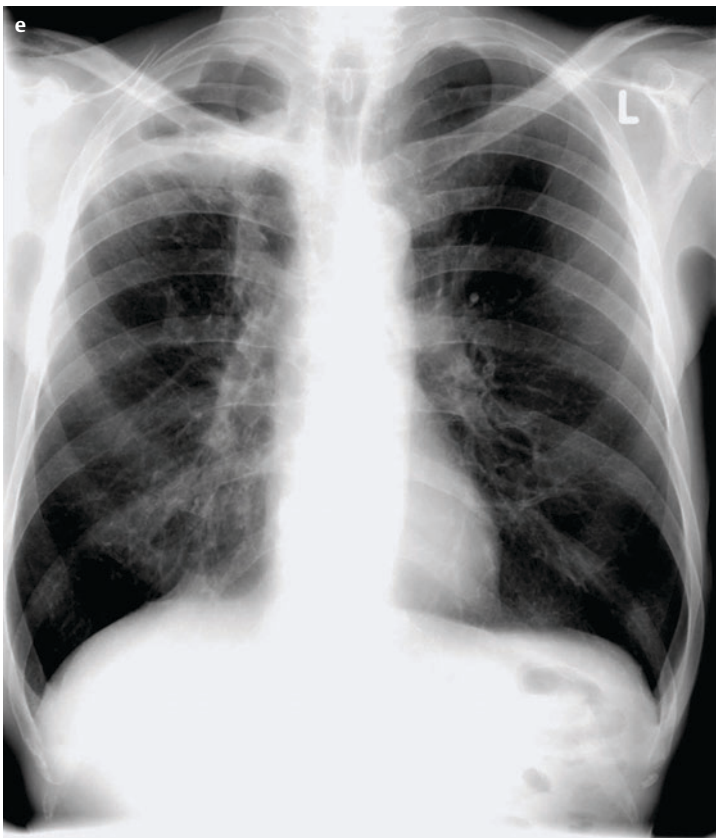
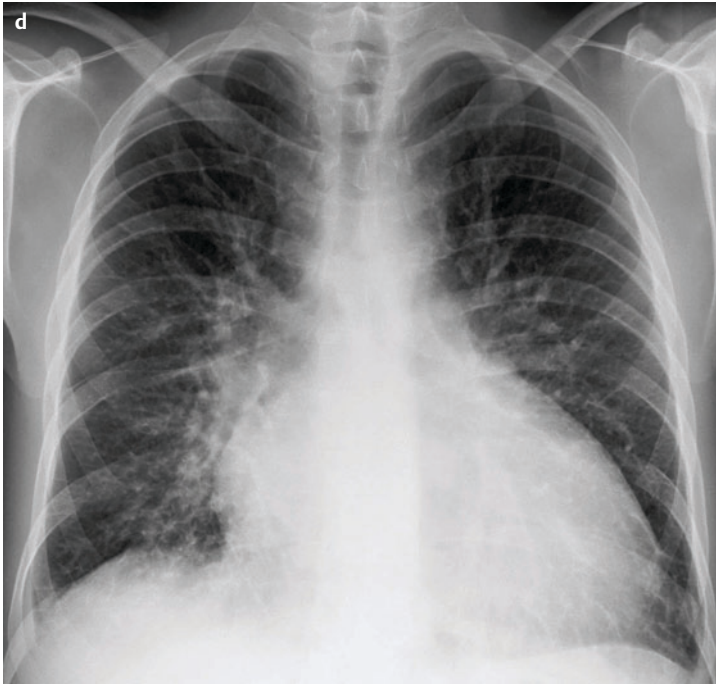


Fig. 6.76a–h

**d** A case that just came in.

**e** This young patient has not been feeling well lately.

inconnue,” adds Gregory with an awful accent (meaning: history withheld)—he has been showing off his French since he stayed in Paris for a three-month neurointer-

ventional course last summer. “You’d better polish up on your pronunciation,” Giufeng says casually. Gregory’s smile freezes. Giufeng’s own French is pretty good.



## Test Cases

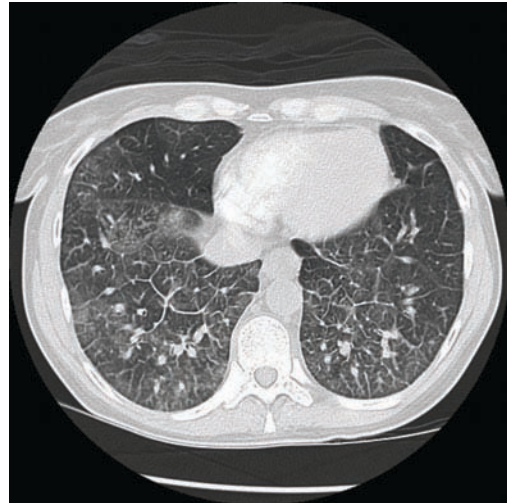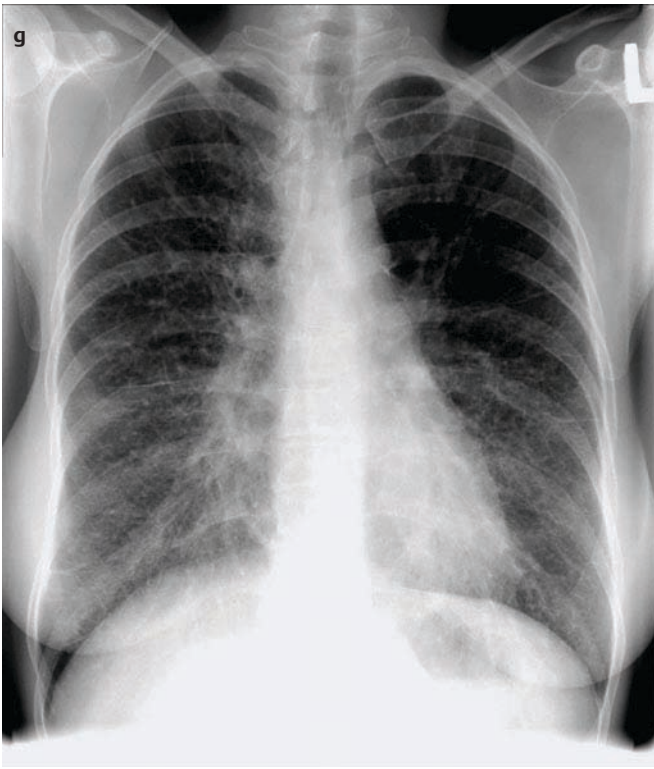
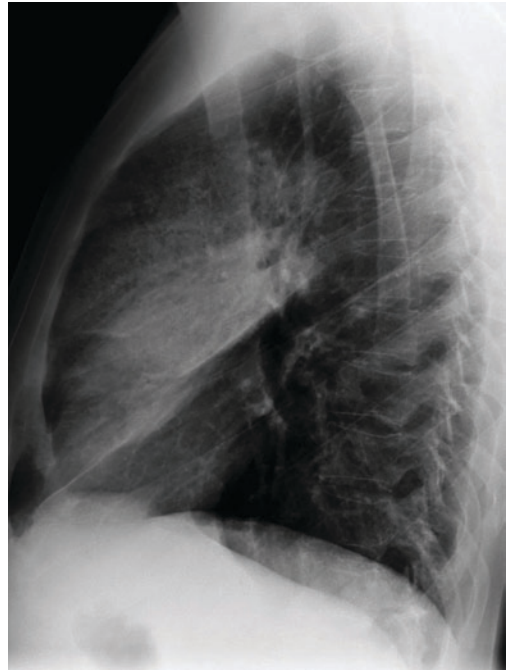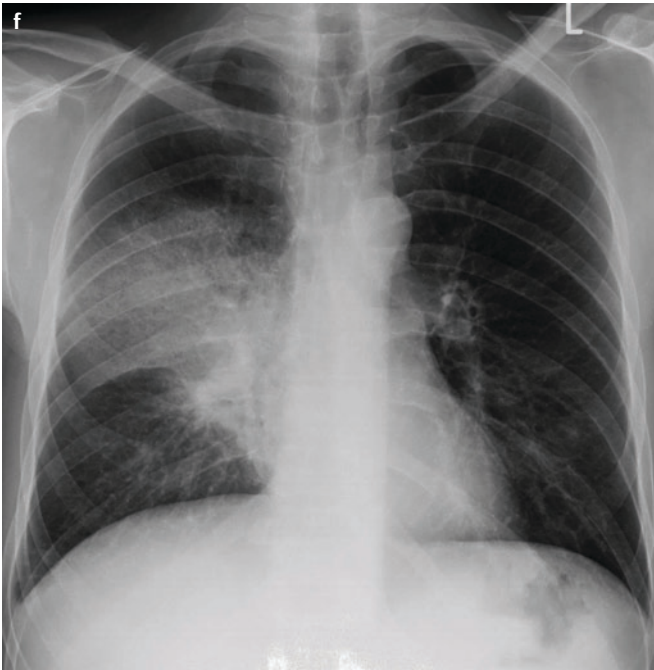


Fig. 6.76a–h

**f** This one is also unwell.

**g** This lady has been a regular visitor to the hospital.

Much to his disappointment, Gregory has not yet heard her speak in her soft Mandarin mother tongue. Paul sits up and focuses on the films: It is now or never. Gregory

has a little surprise stowed away for the two interns (Fig. 6.76a–h). Why don't you go ahead check it out yourself.

## Test Cases

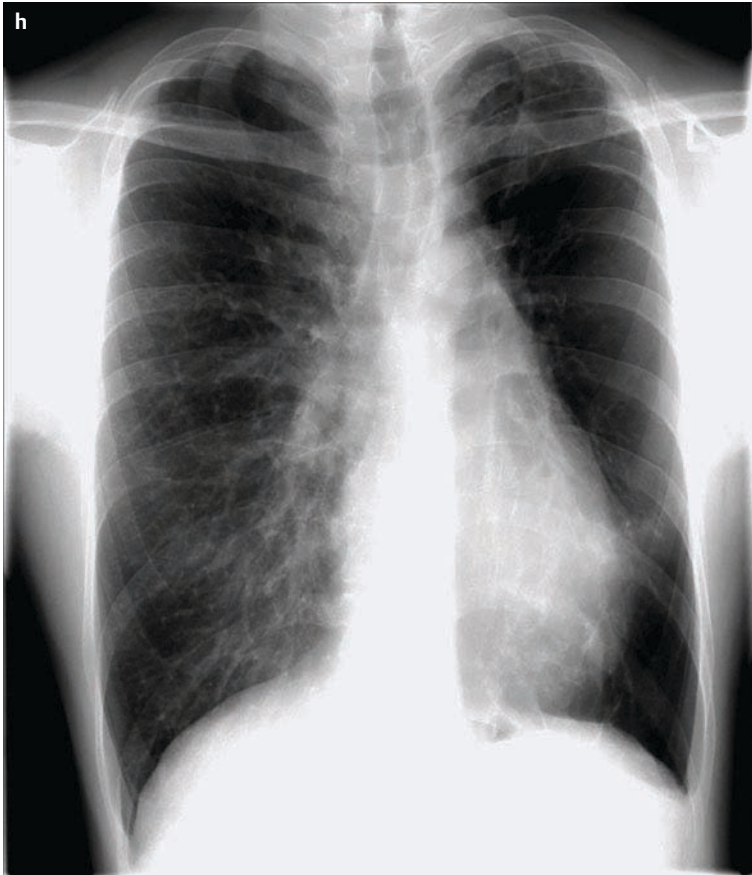
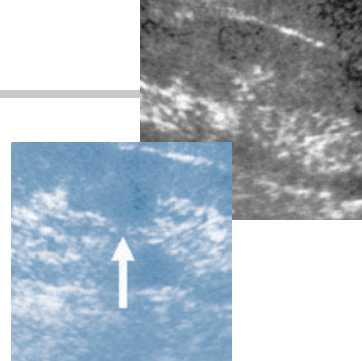


Fig. 6.76a-h  
h This patient sits in front of you and smiles.  
He knows his diagnosis—do you?

## 7 Cardiovascular and Interventional Radiology



As this chapter is being written, the importance of purely diagnostic conventional angiography decreases by the day. Vascular anatomy and disease can be imaged with a multitude of noninvasive modalities: ultrasound, Doppler ultrasound, spiral CT, and MR imaging (Fig. 7.1). These tests alone or in combination can sufficiently address most diagnostic issues. There are circumstances, however, where catheter-based angiography still has its place. It certainly is an integral component of all percutaneous therapeutic interventions for which intravascular access is a prerequisite:

- Dilations (for example, in arteriosclerotic vascular stenosis)
- Stent graft placement (for example, in aneurysms)
- Embolizations (for example, treating acute hemorrhage or to shut off blood supply to tumors)
- Vena cava filter placements (for example, in venous thrombosis and after pulmonary embolism)
- Shunt placements (for example, when performing a transjugular intrahepatic portosystemic shunt, TIPSS)

When the need for an intervention is anticipated, the diagnostic portion of the work-up can be done effectively by

diagnostic angiography followed by the actual therapeutic part of the procedure since they use the same access route, resulting in an “all-in-one” procedure.

Angiography of the veins—called phlebography or venography—has lost its relevance in daily radiological practice. This is due to the advent of new imaging modalities and a change in the therapeutic regimen for treatment of deep vein thrombosis. Ultrasound and Doppler ultrasound are now the first line modalities to assess extremity veins. If pulmonary embolism is suspected, spiral CT is the “one-stop-shop” procedure of choice wherever it is available (see p. 78).

Owing to the development of small-caliber access systems, minimally invasive intervention guided by sectional modalities (mostly CT and ultrasound) continues to be very successful. With few exceptions, virtually any region of the body can be accessed percutaneously and tissue can be sampled for histopathological diagnosis with significantly less risk and cost compared to surgical means. An abscess or fluid collection can be drained quickly, obstructed bile ducts can be relieved promptly.

### MR Angiography

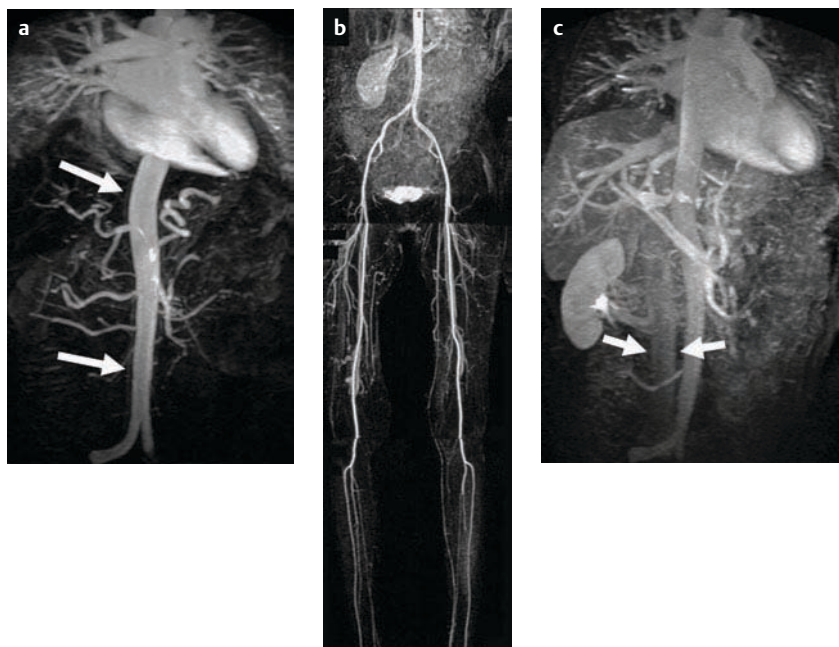


Fig. 7.1 The aorta (a, arrows) as well as its branches down into the lower extremities (b) and the vena cava (c, arrows) can be examined with contrast-enhanced magnetic resonance angiography—all of it completely noninvasive.

Finally, a variety of therapeutic agents may be introduced into the body: In osteoporotic and some pathological fractures of the vertebral bodies, the transpedicular injection of polymethylmethacrylate (PMMA) stabilizes the vertebral body and alleviates the pain (see Fig. 8.24c, p. 133). In extreme pain due to invasive pancreatic carcinoma, denervation of the celiac plexus by a percutaneous image-guided alcohol injection may offer effective palliative therapy; the actual procedure is associated with few risks and morbidity, an important consideration in patients with a very limited life expectancy

For students and beginners in radiology, angiography and intervention have a completely different feel to the stan-

dard radiology experience. A sure instinct and a lot of “touch” in the literal sense of the word (how about “Fingerspitzengefühl” for a great German term), materials science, craftsmanship, precision, and diligence are prerequisites for successful treatment and need to be developed over time during training and even way into practice. A healthy helping of cold-bloodedness and “fortune” (pronounce this the elegant French way to describe the status of being a lucky kid) are other essentials of a successful interventionalist. A certain arrogance toward the noninterventional “armchair radiologists” comes as part of the package and is tolerated if the interventionalist is worth his money.

Table 7.1 Suggestions for modalities in angiography and intervention

Which imaging modality for which indication?	
Indication	Imaging
Arterial problem	Depending on availability, expertise, and problem: angiography, ultrasound, Doppler ultrasound, MRA, CTA.
Venous problem	Depending on availability, expertise, and problem: ultrasound, Doppler ultrasound, CTV, venography, MRV.
Which intervention for which indication?	
Intervention	Indication
Angiography	Planned recanalization, thrombolysis, balloon dilation, stenting of vessels, hemorrhage before anticipated embolization (i.e., gastrointestinal bleed).
Balloon dilation	Vascular stenosis, after recanalization, frequently after thrombolysis, before stenting (attention: small vessels and strong collateralization).
Stent implantation	Irregular plaque surface after balloon dilation, elastic stenosis, dissection, iliac occlusive disease. Stent grafts in aortic aneurysms and dissections should be performed by specialists only and with vascular surgical back-up.
Vena-cava filter	Pulmonary embolism and failed or contraindicated anticoagulation.
Transjugular intrahepatic portosystemic stent-shunt (TIPSS) implantation	Portal hypertension with recurring/uncontrollable gastrointestinal bleeds and ascites (attention: hepatic encephalopathy, cardiac insufficiency).
CT-guided tissue biopsy	Cytological, histopathological, and microbiological verification of disease.
Embolization	Occasionally in inoperable tumors; preoperatively in hypervascular tumors; therapy of arteriovenous malformations; arterial bleeds.
Port implantation	When mid-term intravenous access is necessary, e.g., in chemotherapy.
Neural blockade	When conservative pain medication fails or is not tolerated; to reduce dose of systemic analgesics in special pain syndromes.
Drainage	Image-guided drainage of abscesses and cysts. CT is the best modality for complex drain approach.
Radiofrequency ablation	In patients with small numbers of accessible liver tumors unsuitable for surgical resection.

CT, computed tomography; CTA, CT angiography; CTV, CT venography; MR, magnetic resonance; MRV, MR venography.



**!** In all elective interventions the patient should give informed consent after sufficient time has been given to explaining risks and benefits, complications, and alternative measures to the planned procedure. This should be done at least a day before the procedure. Blood clotting should be sufficient, that is, prothrombin time should be > 50%, partial thromboplastin time < 35 seconds, thrombocyte count > 50 000/ $\mu$ l. Acetylsalicylic acid (ASA/aspirin) should be discontinued a week before deep body interventions are performed.

As all angiographies are dedicated tests undertaken exclusively by specialists, nobody will seriously expect you to interpret the results in your real clinical life as a nonradiologist. You should, however, know the potential treatment options afforded by each modality and be familiar with the most important interventions, their preparation, and their complications. What is true everywhere remains valid here: Technology and new procedures develop extremely rapidly. Problems that seem impossible to solve today will perhaps be dealt with elegantly and ingeniously a year later by some bright brain—come to think of it, it could well be your bright brain!

In all interventions the risks of complications and the potential benefits of the procedure, time requirement, cost, and therapeutic efficiency must be carefully considered. One principle always applies: Inflicting controlled damage on a patient who trusts the physician must only be done with an appropriate indication (Table 7.1). Just assume the worst possible complication happens and you have to explain to a grieving relative of the patient (or worse, a judge) why you did what you did. Now let us have a look at the first intervention.



#### Do You Know Who Started It All?

Werner Forssmann was the first who, in 1929, inserted a catheter into a person's central vessels and heart: He did it to himself—against strict orders from his chief and while wrestling

with a colleague who wanted to save his life. Forssmann also took a chest radiograph of himself to document the experiment. In 1956 a Swedish committee had to hunt him down by police in post-war Germany where he was practicing in a little town. The policeman eventually said to him: “They are looking for a Dr. Forssmann but it can't be you because this guy has won the Nobel prize.”

## 7.1 Interventions in Vascular Occlusive Disease

### Arterial Occlusion

#### Checklist: Arterial Occlusion

- Is the vessel compressed extrinsically or owing to an intrinsic abnormality of the vessel wall?
- Are you dealing with generalized or focal vessel disease?
- Is there a history of diabetes mellitus or tobacco abuse?
- Is there reconstituted blood flow distally through preexisting anatomical collateral vessels or newly formed collaterals?
- What is the normal vessel caliber at the stenotic site?

#### A Window Shopping Bonanza

Gary Sweetblood (45) has had problems walking for quite a while. After just a short stride he regularly experiences cramps in his right calf and must pause for them to cease. That turns his beloved visits to the tobacco shop into a lengthy affair, forcing him to stop at every shop window on the way. His general practitioner has had difficulties finding his foot pulses on the right side and has sent him for diagnosis and potential therapy. Senior consultant Poznansky has sensed Joey's special gift for and his sincere interest in intervention. He looks on as Joey examines Mr. Sweetblood and tries to feel the arterial pulses: the foot pulses are gone and the popliteal artery is barely palpable. Poznansky lets Joey puncture the left femoral artery and advance a catheter into the vessel.

#### → Procedures

**Arterial puncture and sheath insertion:** After the patient is positioned comfortably on the angiography table and the left groin has been disinfected properly, Joey localizes the pulse of the left femoral artery below the inguinal ligament (Note: If possible, gain access on the healthy side!) with the fingertips of the index finger (D2, for the distal pulse) and the middle finger (D3, for the proximal pulse) of his left hand (Fig. 7.2a). Having thus determined the course of the vessel with certainty, he injects 10–20 ml of a 1% local anesthetic (lidocaine) subcutaneously; he then incises the skin with a pointed scalpel. Still feeling the arterial pulse with the fingertips of his left hand, he now advances a hollow needle toward the vessel, the hub angled down toward the patient's feet by approximately 45°. As the needle tip gets close to the vascular wall it transmits the pulsation of the wall (“dancing needle”). Now the vascular wall is perforated with diligence. The squirting flow of bright red blood proves the arterial source. If the blood is too dark and

the flow is slow, the needle has been directed too far medially—this is where the vein is located. Puncturing just the anterior wall of the vessel is the preferred method. (Alternatively, employing the technique after Seldinger, one can also stick the needle straight through the vessel in one swift motion, remove the trocar, and then slowly pull back the hollow needle until it pops into the vessel lumen and blood starts to squirt back.) After correct puncture a short guide-wire with a floppy soft tip is introduced through the needle into the vessel and, if possible, advanced into the abdominal aorta. While fixing the wire position, the needle is carefully retracted over the wire and removed, and a plastic sheath is advanced over the wire into the vessel. The sheath has a silicone diaphragm at its end, which prevents blood from flowing back and at the same time permits the introduction and removal of catheters into and out of the vessel as a temporary access route without the need to repuncture.

As Poznansky watches him closely, Joey proceeds to push the catheter into the distal aorta. Injecting contrast at a high flow rate, he performs several contrast series, assessing contrast flow in the main arteries of the pelvis and both proximal legs. The main finding—an obstructing arteriosclerotic plaque—is located at the right iliac level (Fig. 7.2b). “Well done, Joey,” says Dr. Poznansky respectfully and takes over. “We’ll dilate and stent that now. Was the patient briefed yesterday evening and did he consent?” Mr. Sweetblood and Joey nod: “Of course—we discussed the whole thing for half an hour—all the details were covered,” Joey claims.



#### Do You Know What a Sheath Is?

A sheath in vascular intervention is a thin but rigid plastic tube with a tapered tip that is inserted into the vessel over a guide-wire. At the proximal end a valve is attached. The valve consists of a thick, soft silicone membrane with a central perforation through which a catheter may be advanced. If the sheath does not contain a catheter, this membrane seals the sheath off to the outside and the blood stays inside. Many sheaths have a side port that can be used to flush the sheath to prevent blood clots from forming. For port implantations, a special valveless sheath is used.

**Balloon dilation:** 5000 IU of heparin is administered via the sheath. Then another guide-wire is advanced from the left external iliac artery across the aortic bifurcation over to the right external iliac artery and well past the stenosis. The balloon catheter slides into position over this wire. The balloon resembles a sausage when inflated and has the diameter of a normal vessel segment in this location. It is filled with saline under pressure of up to 8–12 atmospheres and kept expanded for about a minute. The first contrast run after the dilation shows a residual stenosis. Of course Joey knows that intimal tears are a regular effect of balloon dilation and they may proceed to full-blown dissections with the danger of acute vascular obstruction. Poznansky asks for a metal stent.

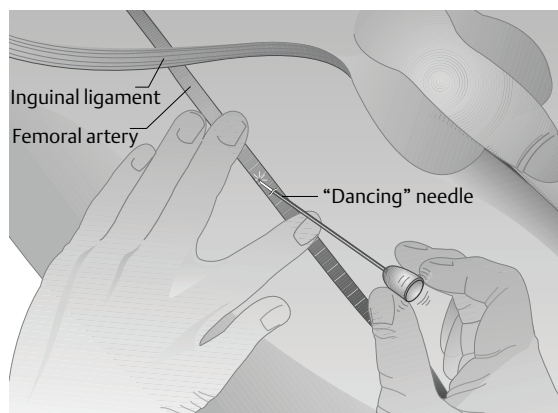


#### Do You Know the Pioneer of Balloon Dilation?

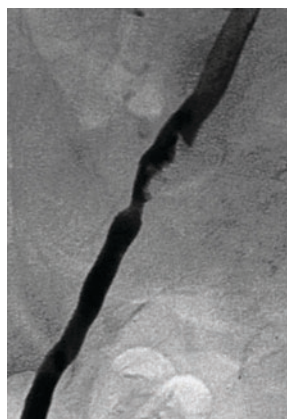
Andreas Grüntzig was the ingenious developer of the balloon dilation catheter in Switzerland. But he also was a lucky guy. It has been said that in the beginning his balloons tended to expand in an unpredictable fashion, bulging eccentrically and following the path of least resistance. These balloons were useless for his purposes. He lamented about this to his department’s secre-

### Interventions in Arterial Occlusion

#### a Technique of arterial puncture in the groin



#### b Angiography



#### c Stent implantation

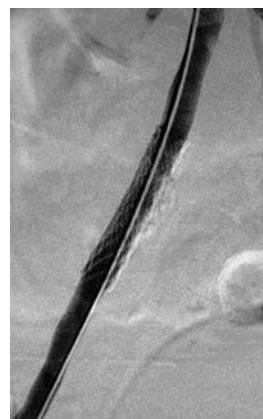


Fig. 7.2a After positioning of the patient on the angiography table and disinfection of the groin, the arterial pulse of the femoral artery is palpated caudal to the inguinal ligament with the fingertips of the index and middle finger of the left hand. The index finger lies distal, the middle finger proximal (please modify if you are left-handed). Then 10–20 ml of 1% lidocaine is injected subcutaneously and the skin is incised with a pointed scalpel. The needle is now advanced toward the vessel in dorsocranial direction with the right hand while the left fingers stay in place. When a pulse-synchronous movement of the needle is felt, the vessel wall has been reached and is perforated cautiously. The squirting flow of bright red blood proves the arterial source. b The primary angiography shows very irregular plaque that narrows down the right external iliac artery by more than 50%. c After the stent implantation, the stenosis has disappeared completely.

## Interventions in Arterial Occlusion

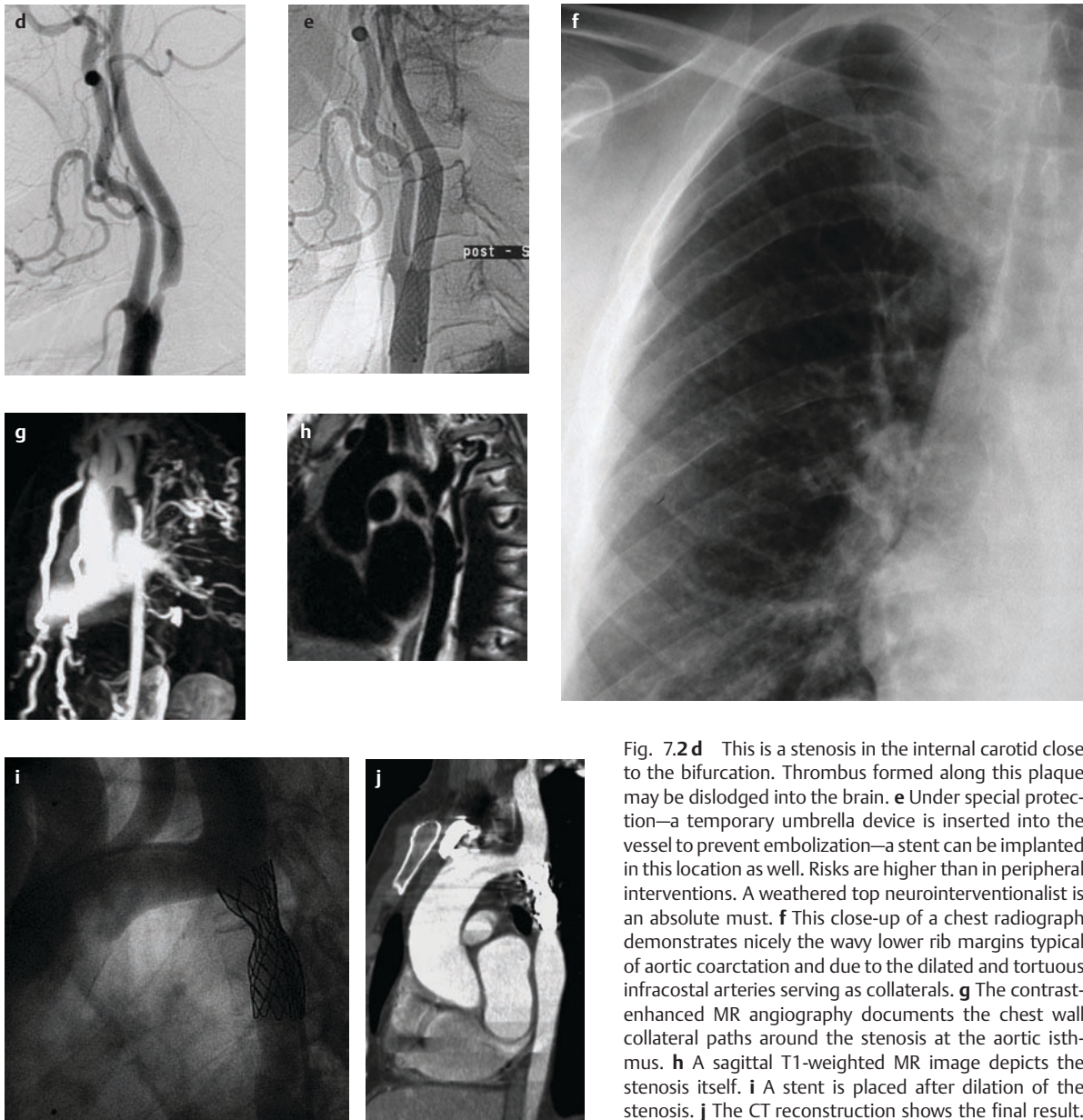


Fig. 7.2 **d** This is a stenosis in the internal carotid close to the bifurcation. Thrombus formed along this plaque may be dislodged into the brain. **e** Under special protection—a temporary umbrella device is inserted into the vessel to prevent embolization—a stent can be implanted in this location as well. Risks are higher than in peripheral interventions. A weathered top neurointerventionalist is an absolute must. **f** This close-up of a chest radiograph demonstrates nicely the wavy lower rib margins typical of aortic coarctation and due to the dilated and tortuous infracostal arteries serving as collaterals. **g** The contrast-enhanced MR angiography documents the chest wall collateral paths around the stenosis at the aortic isthmus. **h** A sagittal T1-weighted MR image depicts the stenosis itself. **i** A stent is placed after dilation of the stenosis. **j** The CT reconstruction shows the final result.

tary, whose husband happened to work in a Swiss factory for pressure-proof garden hoses. From there came the important hint that made all the difference: a spirally woven net of plastic fibers in the balloon wall assured the retention of the form of the balloons. After that everything else was a breeze. Grüntzig had less luck later in his life—he died in the crash of his private airplane. At least he could afford one. (The source of this story we cannot remember and won't guarantee it is at all true. But that is what supposedly happened ...)

**Stent implantation:** The collapsed stent is mounted over the tip of the collapsed balloon catheter, advanced directly into the dilated segment, and expanded there with the help of the balloon. The expansile force of the balloon

as well as the radial force of the stent makes it cling to the vascular wall, smoothes the plaque surface, and repositions any dissection membranes that may be present (Fig. 7.2c). Stents can also be used to treat carotid stenoses (Fig. 7.2d, e) or congenital stenoses such as in aortic coarctation (Fig. 7.2f–j). Fabric-coated stents, so-called covered stents, can also be used to stop bleeds of larger vessels or treat aneurysms (Fig. 7.3).

Joey is amazed about the final result and Sweetblood gives Poznansky and Joey a big smile after seeing the post-therapy angiography on the monitor: “Hey, Doc, that looks as good as new! I gotta go out and have a smoke.” Poznansky sends the patient back to the ward with a grin on his



## Intervention in a Large Arterial Bleed

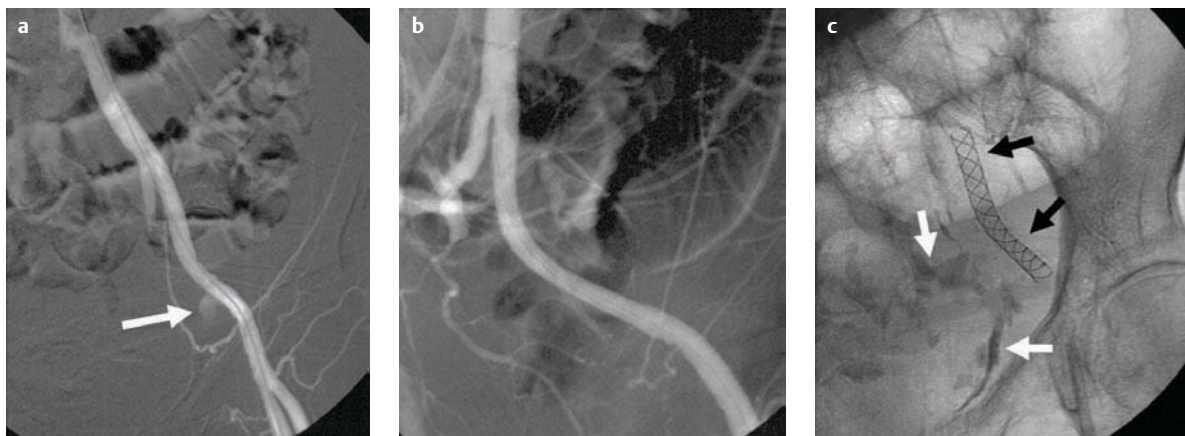


Fig. 7.3 **a** The primary angiography in this patient with an advanced gynecological tumor of the pelvic base shows acute contrast extravasation (arrow) arising from the external iliac artery. **b** The immediate implantation of a fabric-coated stent into the

eroded vascular segment bypasses the leak and stops the bleeding immediately. **c** The final film demonstrates the structure of the stent (black arrows) and the contrast-enhanced free blood in the pelvic cavity (white arrows).

face after ordering a 24-hour perfusion with 25 000 IU of heparin, subcutaneous injections of a low-molecular-weight heparin formulation twice daily for two weeks, and 100 mg of acetylsalicylic acid daily as permanent medication for prophylaxis of restenosis. With Joey he discusses another potential vascular intervention that was fortunately unnecessary in Mr. Sweetblood's case.

**Thrombolysis:** If a fresh intravascular thrombus needs to be removed, local lysis is a possibility. For this procedure a catheter with side holes is advanced into the thrombus. Over the course of many hours, high doses of thrombolytic agents (for example, t-PA) are infused via this catheter. Thrombolysis may induce hemorrhage at other locations, especially intracranially, and must therefore be considered and monitored closely.

The described interventional techniques can also be applied—with some modifications—in hemodialysis shunts.

! After a therapeutic vascular intervention in peripheral arteriosclerosis, the patient has to be put on a lifelong aspirin regimen (100 mg daily).



#### Here Is Another Kind of Pioneer: Felix Hoffmann

Felix Hoffmann was the guy who first synthesized acetylsalicylic acid (aspirin) on 10 August 1897 in Leverkusen, Germany. The drug has been proved to significantly lower the rate of coronary and cerebral infarctions in some of the best and largest studies in medical history. Hoffmann would have loved the success story of this invention, much less the story of his other major invention: on 1 August 1897 he was the first to synthesize heroin.

## Venous Obstruction

### Checklist: Venous Obstruction

- Is the vessel extrinsically compressed or obstructed by thrombi in the vessel lumen?
- Does injected contrast flow around the thrombi or are they adherent to the vascular wall?
- Does the patient smoke or take contraceptives, is he or she significantly overweight, was the patient recently immobilized, postoperative, or pregnant?
- Is there a known malignancy?

### All of a Sudden the Leg Was Swollen

Georgina Truelove (52) noticed a swelling of her left leg yesterday evening that has increased overnight. Now she can only walk with pain. Her general practitioner has sent her for the suspicion of deep vein thrombosis in her left leg. Dr. Goolagong has Hannah working with him today. He explains the common procedure in case of suspected deep vein thrombosis. "Since the internists have stopped immobilizing patients with calf thrombosis, lower extremity venography has lost much of its relevance. Only with venography could one detect small thrombi in the veins of the lower leg. Apart from that, venography is not always trivial to perform in severely swollen legs. Ultrasound and Doppler ultrasound suffice for the confirmation of most clinically relevant thromboses. If pulmonary embolism is suspected you should go right ahead and perform a dedicated spiral PE protocol CT."



### Thrombosis: Venography

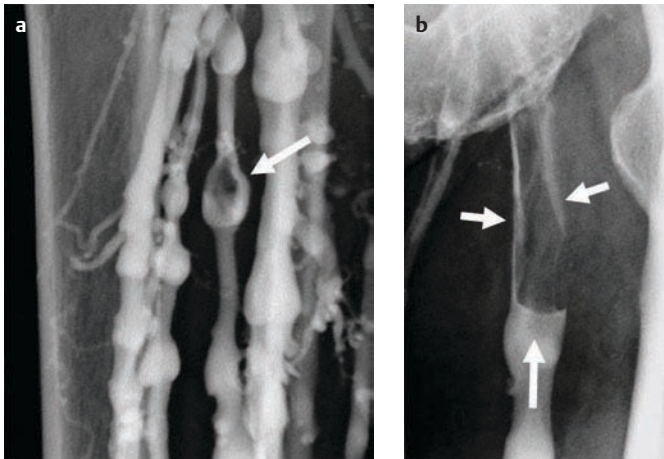


Fig. 7.4 **a** This view of the calf shows a thrombus (arrow) surrounded by flow of contrast in a vein just above a venous valve. **b** In the thigh, another, large thrombus is seen in the femoral vein that reaches up to the inguinal ligament. This finding requires immobilization of the patient to keep the chances of a pulmonary embolism low.

#### → Procedures

**Venography:** In venography, contrast medium is injected into a vein on the dorsum of the foot—preferentially close to the base joint of the large toe—while the superficial veins of the lower leg are compressed at the same time by a tourniquet just above the ankle joint. The examination table should first be tilted head-up at a 45° angle for the venous puncture and for the venography in order to fill the veins from below. As one reaches the level of the iliac veins and the inferior vena cava, the table is tilted slightly head-down quickly to get a rush of contrast from the leg veins into the larger proximal veins, resulting in good filling of these venous segments. Thrombi are depicted as intravascular filling defects surrounded by flowing contrast medium (Fig. 7.4).

**Doppler ultrasound:** In the Doppler ultrasound that Dr. Goolagong performs on Mrs. Truelove he follows the course of the veins from the popliteal level up into the pelvis. Normal veins are compressed with ease by the ultrasound probe, which is what is done every few centimeters along their course. A thrombosed vein is not compressible and does not show flow on Doppler ultrasound examination. Goolagong finds a long thrombosis in one of Mrs. Truelove's deep veins in the thigh that reaches up to the inguinal ligament (Fig. 7.5c). Goolagong turns to Hannah: "Here we have the diagnosis: Thrombosis of the superficial femoral vein." "You are going to relax comfortably in bed for a week: television, magazines, good music," he cheers up the patient.

### Thrombosis: Doppler Ultrasound

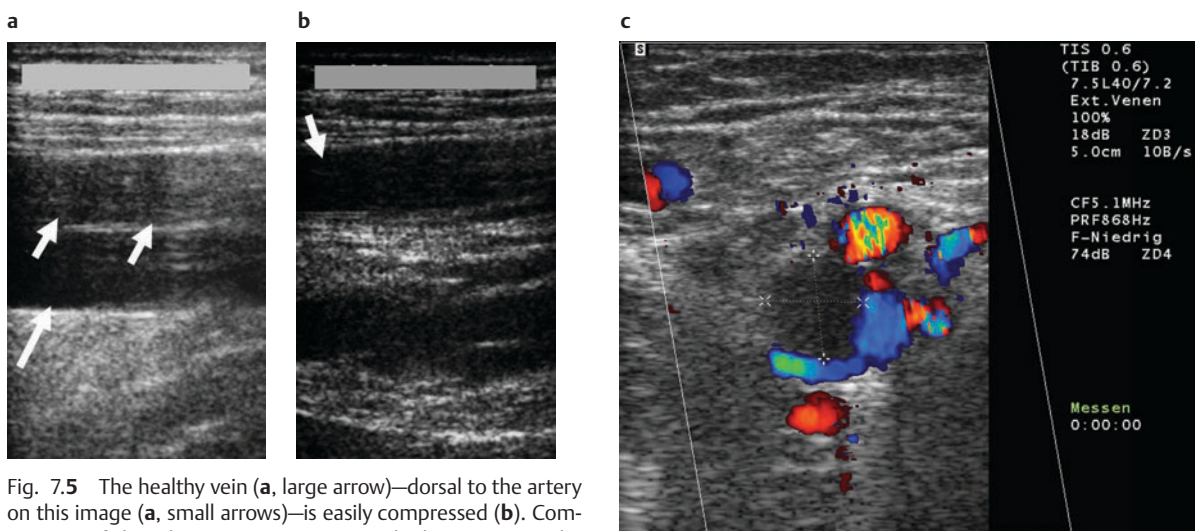


Fig. 7.5 The healthy vein (**a**, large arrow)—dorsal to the artery on this image (**a**, small arrows)—is easily compressed (**b**). Compression of the adjacent artery requires a higher pressure. The thrombus (**c**) shows no flow in Doppler mode and hinders the compression of the vessel.

## 7.2 Tissue Biopsies

### Checklist: Tissue Biopsies

- Is the lesion to be biopsied a true abnormality, adequately documented (CT, ultrasound, MRI)?
- Is the lesion large enough to reasonably expect success targeting it? Is it accessible from the outside? Are there crucial organs in the way of the trajectory that you cannot cross (discuss with interventionalist)?
- Is the blood clotting function adequate?
- Can the patient tolerate a pneumothorax (in chest lesions)?

### We Need Histology—Now!

Ann Hightower (62) has been sent to the oncology department by her general practitioner. She has not felt well for quite a while and has lost weight substantially. The initial tests already showed lesions suspicious of metastases in a number of different body locations, but the primary tumor has not yet been found. The oncologists urgently need the histological identification of the malignancy before they can decide which chemotherapy protocol best to choose. They also want to get more information about possible primary tumors to be able to gauge her prognosis.

Percutaneous tissue biopsies are a special passion of senior consultant Chaban. There is no place in the body his needles have not been, says a popular department rumor. Together with Hannah he scrutinizes all the imaging studies performed so far to find the most secure and most promising biopsy target area. He then sits down with Mrs. Hightower. He tells her all about complications (hemorrhage; infection; trauma to the nerves, vessels, and organs) as well as about the alternative procedures (surgery) and the potential emergency surgery. Mrs. Hightower gets just a little nervous after all this information. Chaban puts her hands into his and gives her a warm smile: "I can't remember the last complication of that sort—it is so long ago. And I will be at your side for the whole time. The two of us will do the job!" he beams at her. Mrs. Hightower relaxes a little and returns his smile.

Chaban explains to Hannah the essential technique of tissue biopsy. The main objective is, of course, to get enough tissue for the histological and microbiological analysis and to hand it to the pathologists and microbiologists in an optimal condition for further processing and diagnosis:

- Tissue cores for the histopathological analysis are stored in little containers containing 5% formaldehyde solution.
- Fluids for cytological analysis are deposited as small drops at the end of a microscopy glass slide, drawn out over it very carefully with a second glass, and then left to dry.

- Material for bacteriological analysis is deposited in sterile, dry or agar medium-filled plastic containers.
- Material for mycological analysis is deposited in sterile, dry plastic containers (if transport is anticipated to take time add a few drops of saline solution).
- Material for virological analysis is deposited in sterile plastic containers filled with saline solution.

### → Procedures

**Lung biopsy:** When performing a percutaneous lung biopsy, pneumothorax is the most frequent complication and measures should be taken to minimize this risk. Lesions close to the pleura are often associated with adhesions in the pleural space, which reduces the risk of pneumothorax. To harvest several tissue cores without subsequent increased pleural injury, a coaxial outer needle is advanced through the pleural cleft into the lung parenchyma and the immediate vicinity of the lesion (Fig. 7.6a). The inner biopsy needle is then advanced through the coaxial outer needle and redirected until it touches the lesion (Fig. 7.6b). This needle consists of a hollow cutting needle surrounding an inner trocar with a specimen notch or chamber. The trocar is then slowly advanced through the lesion, where some tissue settles in the specimen notch (Fig. 7.6c). This tissue is then separated from the rest by the rapidly advancing cutting needle (Fig. 7.6d) and withdrawn with the biopsy needle (Fig. 7.6e). This procedure is repeated until a sufficient amount of material has been collected.

If a pneumothorax develops despite the precautionary measures, the pleural air can be sucked out of the pleural space via the coaxial needle toward the end of the intervention (Fig. 7.7). If that is not successful, a little drain can be inserted to prevent further complications from a clinically significant (symptomatic or enlarging) pneumothorax.

**Mediastinal biopsy:** When attempting a mediastinal biopsy, the interventionalist must face the following obstacles:

- Frequently the lesion is located retrosternally, always close to large vessels or the heart and often close to the pleura.
- The needle caliber must match the respective anticipated risk. The danger of an erroneous puncture of arteries is low with a biopsy needle that is advanced slowly because the pulsation of the vascular wall is—as in femoral artery puncture (see p. 100)—palpable and visible.
- Vulnerable relevant structures can be pushed out of the way: here's how it works. The coaxial needle is advanced into the immediate vicinity of the pleura or the vessel that is to be avoided (Fig. 7.8). Then the stylet is removed and a pocket of saline fluid is deposited that shifts the vulnerable structure out of the way. The needle is then advanced with caution in this so-called "saline tunnel" technique.

## Lung Biopsy

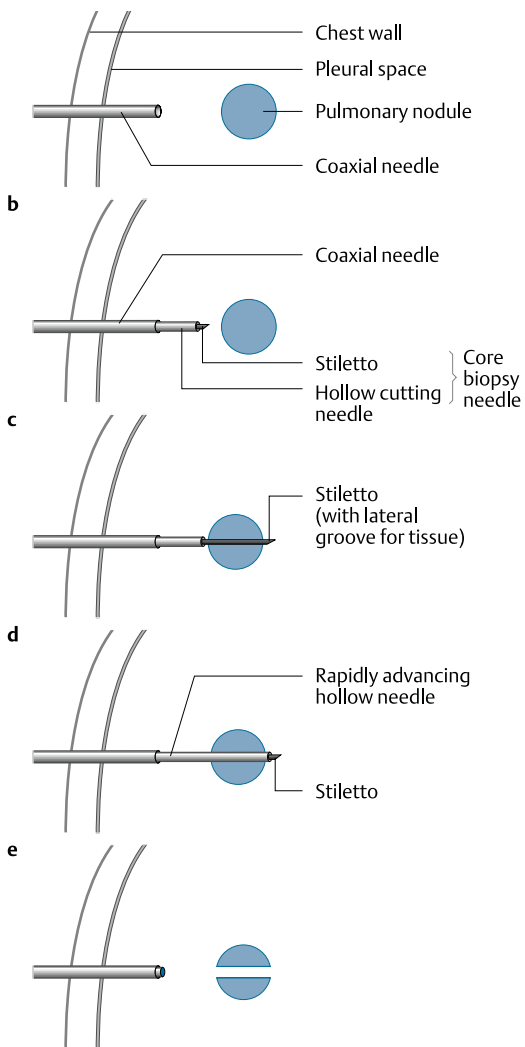


Fig. 7.6a To prevent tearing injury to the pleura when gathering several tissue samples, a coaxial needle is used to pass the pleural space. It is positioned in the immediate neighborhood of the lesion. **b** An inner cutting needle with a trocar (see text) inside is advanced into the margin of the lesion. **c** The trocar with a tissue chamber/notch is pushed into the lesion and some tissue comes to rest in its notch. **d** This tissue is separated from the rest by a swift forward motion of the outer needle, which has a cutting edge at its end. **e** Trocar and cutting needle are withdrawn together with the tissue sample and can be reused for subsequent runs.

**Abdominal, pelvic, and retroperitoneal biopsies:** Any needle inserted into the abdomen must avoid transgressing the colon and vessels to avoid infection and hemorrhage. Under CT guidance—preferably on a scanner with optional CT fluoroscopy mode—vulnerable structures can be evaded more easily (Fig. 7.9). Biopsy of parenchymal organs in the upper abdomen is undemanding if the lesion is not too small and the patient is cooperative.

But beware: if you are trying to biopsy a lesion that is small and only visible on the arterial phase of a multiphase CT, you'd better find some adjacent anatomical landmarks that you can recognize during the noncontrast guidance CT situation. Tissue biopsy of a solid renal tumor is generally contraindicated because the dissemination of malignant cells along the needle path is a rare but real risk in this entity.

**Bone biopsy:** Percutaneous biopsy of bone requires a different technique and can be much more painful than many other tissue biopsies. After subcutaneous and periosteal local anesthesia (Fig. 7.10a) and a little incision of the skin, an outer cannula with an inner trocar is advanced to the bone cortex and screwed through the cortex in a forceful turning motion. The tip of the cannula is threaded to facilitate the penetration of the bone. The cannula should hit the cortex at a 90° angle to prevent skidding of the cannula tip (Fig. 7.10b). Once in the marrow space, the trocar is then withdrawn and the cannula is screwed further into the bone (Fig. 7.10c). The bone core is retrieved under vacuum by retracting the cannula out of the bone. The specimen is removed from the lumen of the cannula with a blunt pusher and transferred into a formaldehyde solution.

Chaban selects a larger paravertebral mass for Mrs. Hightower's biopsy. He retrieves a sizable number of samples through his coaxial needle to give the pathologists enough tissue for their histological tests. Hannah and Chaban talk with their patient about all kinds of things during the intervention to keep her distracted and cheerful. And Chaban works rapidly. As he removes the coaxial needle and throws it into the bin, the patient asks just when Chaban is going to start that awful biopsy. "Why, it's all done with, Mrs. Hightower. You'll go back to the ward now and have a smashin' good cup of tea. You want to see the little worms we pulled out?" Mrs. Hightower gazes with interest at the fine stripes of tissue as they swim in the container with the formaldehyde. She expresses her gratitude and is brought back to the ward.

During the intervention Hannah has pondered some thoughts that she now confides to Chaban: "What if you had really hit the aorta? Or another important vessel?" "You don't do anything as long as the patient doesn't crash; scan them a little later to assess the damage and then sit tight if you can. The blood clotting must be OK, that's for sure. If that's borderline, you'd better monitor the patient. But in the early days of angiography our forefathers thrust gigantic—in comparison to today—needles directly into the aorta via a paravertebral route—routinely and for angiographies of the lower extremities. Complications then were hardly reported. But—come to think of it—before the advent of CT and ultrasound they didn't have the means to see the complications," chuckles Chaban.

! Tissue cores, patients, and clinicians must be treated right and have no time to spare.



## Pneumothorax after Lung Biopsy

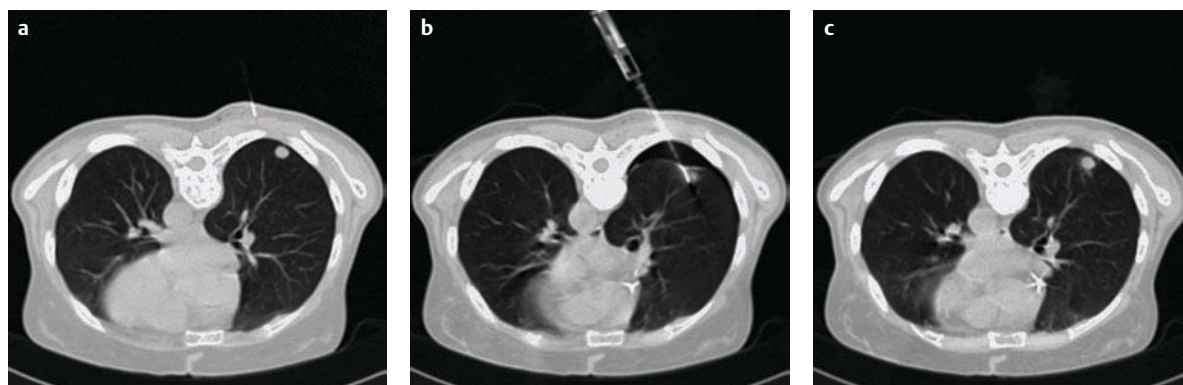


Fig. 7.7 **a** A needle inserted for application of local anesthetic marks the approximate puncture site for the coaxial needle. **b** During the procedure, a pneumothorax develops owing to the peripheral location of the nodule. **c** After sucking out residual air with the coaxial needle after the biopsy, the pneumothorax is gone. A follow-up chest radiograph four hours later was normal.

## “Saline Tunnel” Technique

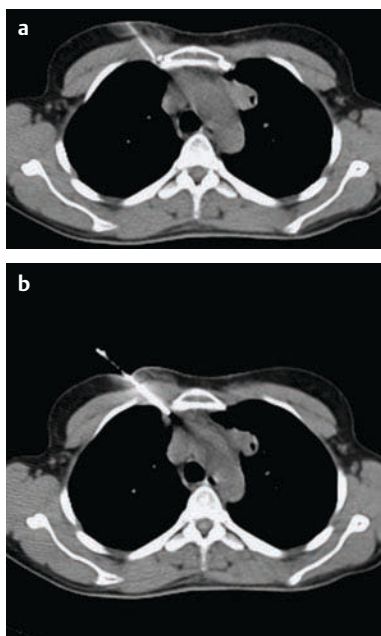


Fig. 7.8 **a** The coaxial needle touches both the sternum and the pleura. The retrosternal mass must be reached. **b** After the creation of a saline pocket, the pleura moves away from the sternum, opening up a path to the target region. The needle is advanced cautiously.

## Pelvic Biopsy

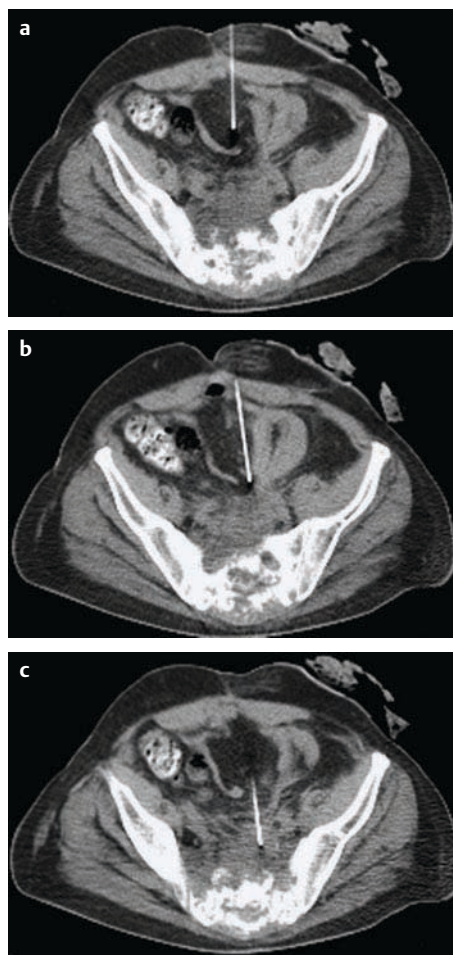


Fig. 7.9 **a** An intestinal loop lies in the path of the coaxial needle targeted for a presacral infiltration. **b** By tilting the needle just a little during the advance, the loop is dodged. **c** Now the needle can enter the tumor. This was a recurring rectal carcinoma.



## Bone Biopsy

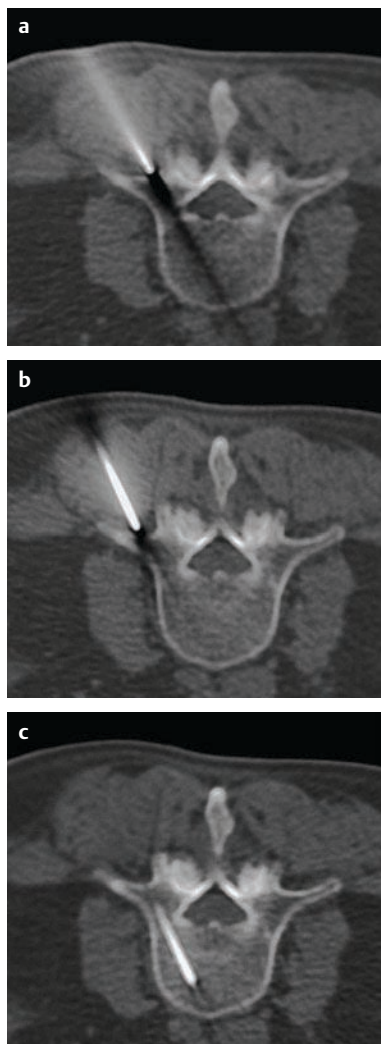


Fig. 7.10 **a** In a first step, a long needle is advanced to the periosteum and local anesthesia is applied. **b** Then the bone biopsy needle is directed to the same spot and screwed into the bone. **c** The position of the bone biopsy needle in the target area is verified.

## 7.3 Insertion of a Drain

### Checklist: Insertion of a Drain

- Is the blood clotting adequate?
- Is the material to be drained viscous, does it contain particulate matter, or is it very fluid?
- How long is the drain intended to stay?

### Radiology, We Have a Problem!

Niles Strongarm (54) has had trouble with his pancreas for a while. He treasures a beer now and then and a brandy after a good meal. Now he has developed his second bout of pancreatitis. The doctors on the ward are nervous because he has developed large areas of necrosis reaching down into the pelvis to the iliac vessels. And now Mr. Strongarm has become febrile. They fear superinfection and abscess formation of the necrotic areas. The situation does not tolerate any delay. Chaban has the patient sent straight down from the ward after having looked at yesterday's CT of the patient (Fig. 7.11a) together with Hannah. He has made sure that Mr. Strongarm's blood clotting is within normal limits. Because the intervention is urgent, he briefs the patient directly before the procedure in the waiting room.

→ **Procedure:** Mr. Strongarm brings along a strong pain reliever from the ward. Hannah injects the drug slowly as he is positioned on the CT table. Chaban chooses the CT image (Fig. 7.11b) that shows the access route best, injects a local anesthetic, and incises the skin with a pointed scalpel directly ventral of the target area. He advances a thin, long needle toward the fluid collection and aspirates to verify the diagnosis: bloody pus enters the syringe. He gestures toward Hannah—the clinicians were right to be alarmed. He advances a guide-wire into the abscess. The wire is specially designed for this purpose, with a floppy tip so that it curls up in the collection and the rest of the wire stiff enough to provide sufficient “backbone” for later insertion of dilators and the actual drain. The needle is withdrawn over the wire and a number of dilators with increasing diameters are subsequently advanced over the guide-wire and retracted again to widen the path. Finally, he introduces a large-bore drainage catheter with multiple side holes along the tip into the fluid pocket. Now the guide-wire is removed and the contents of the abscess are aspirated. Again creamy pus fills the syringe. After the drain has been fixed to the skin with a few sutures, a bag is connected to it. Using a 3-way-stopcock and a 50 ml syringe (used for perfusors), Chaban withdraws about 150 ml of pus out of the collection (Fig. 7.11c). Mr. Strongarm feels the relief and the drop of tension in his abdomen right away. Chaban sends a sample of the material for microbiological testing. At the end of the procedure another limited CT is performed to ascertain that the drain is in correct position and the collection is well drained. By the time Hannah hands him over to the perfect care of sister Magdalena, who is in charge of the postinterventional monitoring, Mr. Strongarm is cracking jokes again.

! Take special care to fix the drainage well to the skin. Abscess drains must be flushed regularly with saline to remain functional.

### Insertion of a Drain

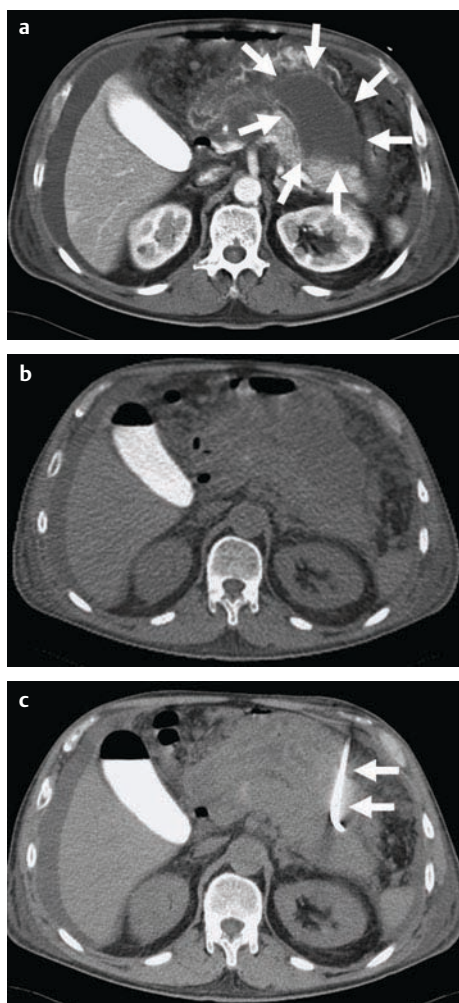


Fig. 7.11 **a** A large fluid collection (arrows) has formed anterior to the pancreas as a complication of severe acute pancreatitis. It has now become superinfected—an infected pseudocyst. **b** The noncontrast study before the insertion of the drain shows the same configuration of the pseudocyst. **c** After the insertion of the drain (arrows), the cyst is emptied and the intestinal loops are rearranged.

## 7.4 Implantation of a Transjugular Intrahepatic Portosystemic Stent-Shunt (TIPSS)

### Checklist: Implantation of a TIPSS

- Is the arterial perfusion of the liver sufficient?
- Is the main portal vein open?
- Is blood clotting sufficient despite the liver disease?

### This Esophageal Hemorrhage Has Got to be Stopped!

Sandra Woodworth (49) has developed hepatic cirrhosis as a complication of chronic hepatitis that she contracted a few years ago. Portal hypertension has developed over time and the rising pressure in the portal system has led to the formation of venous collaterals along the lesser curve of the stomach and the distal end of the esophagus and has also caused ascites. Now she has had several upper gastrointestinal bleeds in a row due to esophageal varices. One time the problem was solved by endoscopic injection of a sclerosing agent into the varices; another time a band ligation of the varices was performed. Mrs. Woodworth recalls with horror the treatment with a temporary balloon tamponade (Blakemore–Sengstaken balloon).

The current bleed, however, is too strong and has been impossible to stop by endoscopy. The gastroenterologists have urgently asked for help. The patient's face is pale with fear. Professor Segner is with Joey as he examines Mrs. Woodworth and briefs her about the intervention to be done: The implantation of a stent creates a shortcut between the portal venous and hepatic venous systems to decompress the portal system. Segner tells her that the risk of further hemorrhages will decrease significantly and that the amount of ascites will also decline. He also mentions the risk of hepatic encephalopathy. As Mrs. Woodworth's bed is pushed into the interventional room she attempts a brave smile. Professor Segner and Joey put on the sterile gowns—Joey wants to help Segner in the procedure. Gregory is currently doing his body intervention time and will hold the ultrasound probe during the intervention.

**!** TIPSS needs experienced hands.

→ **Procedure:** After the patient has been positioned on the interventional table and draped with sterile blankets, Segner carefully punctures the right internal jugular vein under ultrasound control. With a dedicated set he advances a needle into the right hepatic vein. He measures the pressure: 6 mmHg. Under ultrasound guidance (“Gregory, I need to see that needle tip!”) he drives a large, gently angled Colapinto needle from the intrahepatic right hepatic vein through the liver tissue in the direction of the portal venous system. He is lucky: his first pass already hits a right portal vein branch of sufficient diameter. He injects a little contrast via the needle and checks its distribution in the vascular territory: Yes, it is a portal vein alright. He measures the pressure once again, this time in the portal vein. It is 31 mmHg. “Normally the gradient between the venous and the portal venous system may not exceed 12 mmHg. Here it is 25 mmHg already!” explains Segner. He pushes a stiff guide-wire with a floppy tip into the main portal vein. “It’s right there where it belongs, mate,” he drawls and gives Joey a wide grin. “You’ve got to be care-

### Implantation of a TIPSS

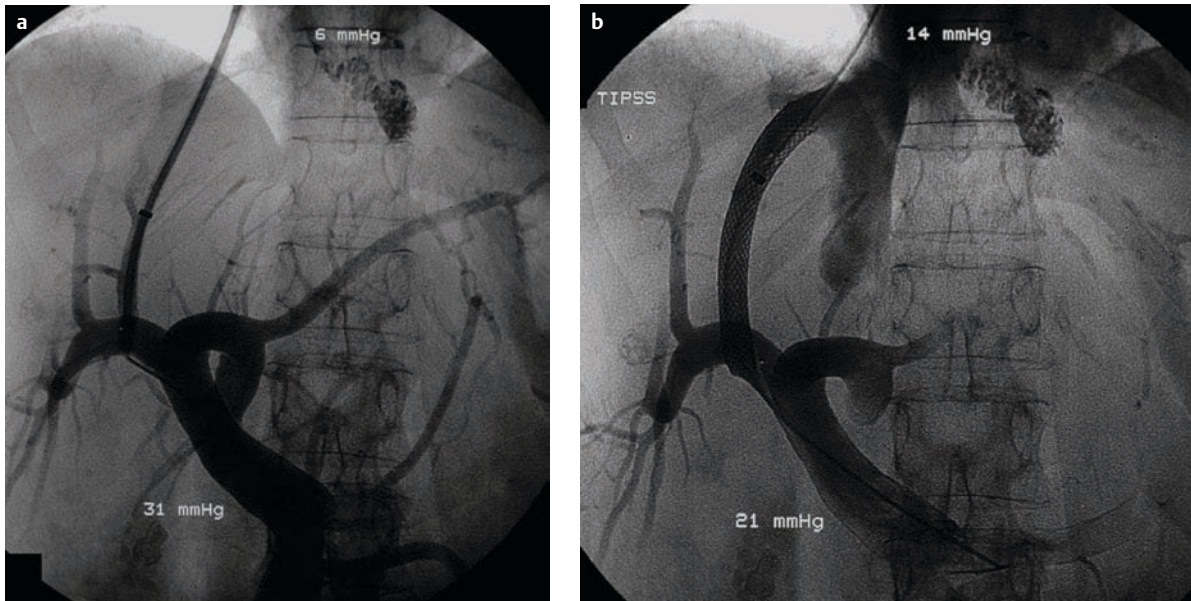


Fig. 7.12 **a** After the right hepatic vein has been entered, a needle tract between the hepatic vein and the portal vein system is generated and the needle is advanced. After injecting contrast into the portal system, it can be visualized back to the level of the splenic vein and the superior mesenteric vein.

Projected over the spine you see tissue glue in inferior esophageal varices—traces of a previous intervention. **b** After dilation of the needle tract and insertion of a covered wall stent, a large-bore communication has been created between the portal vein and the vena cava—the portovenous shunt.

ful to hit the portal vein within the hepatic parenchyma and not in the hepatic hilum—that would cause a potentially lethal hemorrhage. Now the parenchymal channel between the liver vein and the portal system is dilated with a balloon and a beautiful coated stent is implanted.” The stent procedure goes swiftly and without any difficulties. The stent runs in a smooth curve from the liver vein to the portal vein branch (Fig. 7.12**b**). Segner repeats the pressure measurements in the vena cava and the portal vein main trunk. The pressure is now 14 mmHg (vena cava) and 21 mmHg (portal vein). “Look how the gradient has decreased—from 25 to 7 mmHg. That is a splendid result. Of course the gradient must not be made too small because it drives the blood flow through the stent, and if it gets too low there is a higher risk of TIPSS thrombosis.” He turns to the patient: “The danger of recurring hemorrhages should be close to nil now, Mrs. Woodworth.” “Since we now have a great access route to the portal system we could go ahead and embolize directly any varices that might be still bleeding,” Segner explains to Joey. The access set is withdrawn from the jugular vein and the puncture site is compressed carefully by hand. After a little while Joey may take over the compression. Forty minutes later, Mrs. Woodworth is back on the ward again. Should she develop a hepatic encephalopathy despite a protein-reduced diet, an oral lactulose regimen, and fluid substitution, the stent lumen could be reduced in a second intervention.

! The hepatic encephalopathy can be treated conservatively and by intervention. Regular Doppler ultrasound controls are necessary to detect and treat stenoses early.

## 7.5 Implantation of a Vena Cava Filter

### Checklist: Implantation of a Vena Cava Filter

- Is the access route free of thrombi?
- Is a permanent or a temporary filter needed?
- Where do the renal veins enter the vena cava?

### This Patient Cannot Tolerate Another Pulmonary Embolism

Chris Stone (35) has developed a swelling of his left thigh a few days after a dramatic fall from the fourth floor of an office building on George Street where he was cleaning the windows. He has suffered several spinal fractures and crushed both calcaneal bones. Shortly after the swelling of the thigh was noted, he began to be short of breath. The diagnosis of a pulmonary embolism and thrombosis of the deep femoral vein on the left has already been verified by combined CT angiography of the pulmonary vessels and CT veno-



graphy (see p. 80). The symptoms are severe: Mr. Stone will not be able to tolerate any further downturn. The trauma surgeons have asked senior consultant Poznansky to implant a filter into the vena cava. As it turns out this is one of his special passions.

→ **Procedure:** Giufeng has been assigned to Poznansky's outfit today and she enjoys the work in the team. She may hold the ultrasound probe during the puncture of the right femoral vein. "I normally use the right jugular vein but Mr. Stone has already had a thrombosis there," Poznansky explains to Giufeng. He introduces a guide-wire into the femoral vein and on into the iliac vein over which he advances the filter's introductory sheath. A preliminary contrast series via the sheath shows the situation in the vena cava (Fig. 7.13a). "I normally release the filter just below the inflow of the renal veins," he gestures to Giufeng. "Above the renal veins is risky because these veins may be obstructed—that is reserved for exceptional emergencies." He pushes the filter slowly into its proper position and releases it cautiously (Fig. 7.13b). "Sits in there like it's never been anywhere else," he jokes with Mr. Stone. "We're almost at the end. We'll retrieve the filter in a few weeks when you've recovered a bit." The introductory sheath is removed (Fig. 7.13c) and the puncture site is compressed with care for at least 20 minutes until the bleeding has stopped completely. Giufeng wants to do the compression, but Poznansky declines her help: "Compression is not trivial and a lot of complications arise from improper hemostasis at the end. And above all: He who punctures also compresses—that is an old angiographer's rule! You will get your chance."

## 7.6 Implantation of a Port

### Checklist: Implantation of a Port

- Is the vein in question patent?

### How Do We Get That Infusion into This Patient?

Joe-James Fitzpatrick (53) has no more sizable veins after having received several cycles of chemotherapy for his lymphoma. The therapy was quite successful, but there is still residual tumor. The oncologists need a reliable vascular access for the last therapy cycle, which lasts at least six weeks. What they need is a vascular port. Dr. Foxhenry has gotten the hang of these ports lately. Giufeng is joining him for the procedure today.

→ **Procedure:** Under ultrasound guidance—Giufeng is holding the probe again—Foxhenry punctures the internal jugular vein after local anesthesia and a small skin incision. For that he makes sure Mr. Fitzpatrick's head is reclined below the cardiac level to prevent air embolism. He inserts a guide-wire and advances a sheath over it. Foxhenry introduces the port line through the sheath and advances it to the correct position in the superior vena cava under fluoroscopy. After that he opens a little skin pocket for the port reservoir over the pectoral muscle about 10–15 cm distant from the puncture site. The port reservoir is a little plastic or metal chamber with a membranous lid. It can be perforated without permanent da-

### Insertion of a Vena-Cava Filter

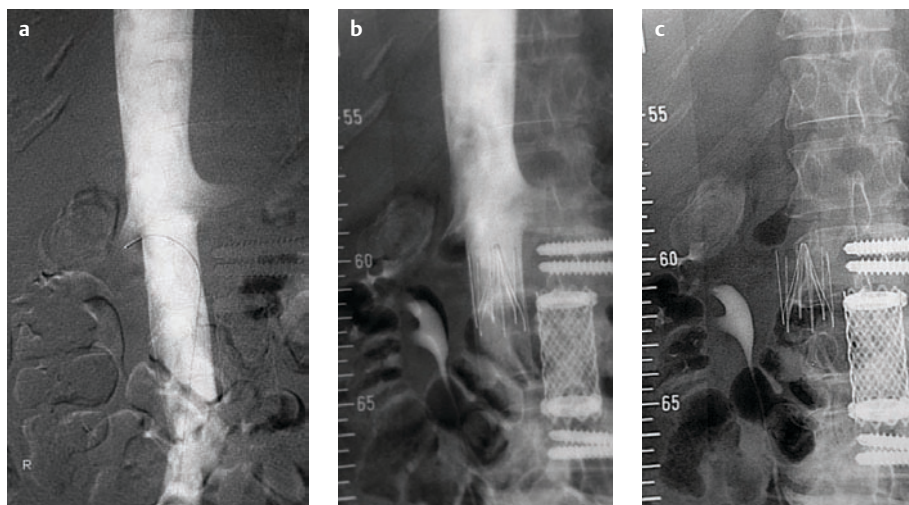


Fig. 7.13 **a** Venography of the vena cava verifies the exact position of the renal vein inflow. **b** After deployment, the position of the caval filter is documented. **c** The noncontrast radiograph

shows the filter at the correct level. Signs of osteosynthetic fusion and repair of a vertebral body fracture and some residual contrast in the renal pelvis after the intervention.



## Implantation of a Port

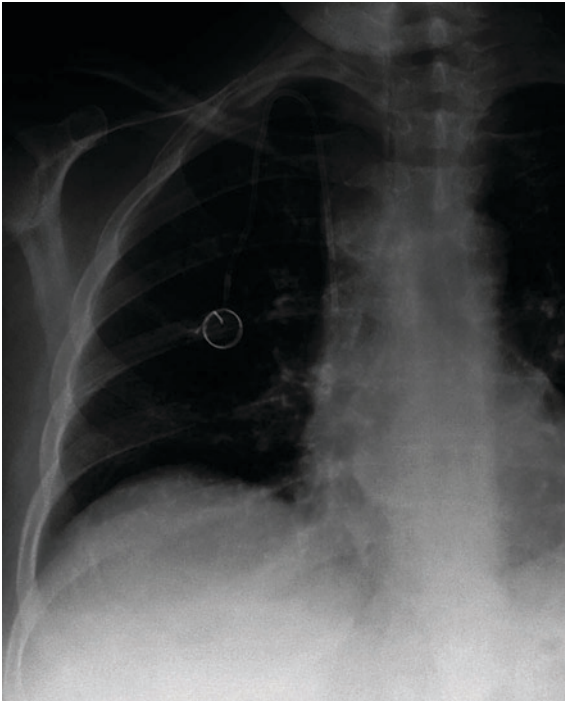


Fig. 7.14 The port reservoir with inserted port needle is located on the pectoral muscle and the tip of the port tube is visualized in the cava at the correct level, that is, just superior to the right atrium.

mage to the lid using dedicated special tip needles (port needles). Foxhenry tunnels the skin from the pocket to the puncture site with a flexible blunt rod and pulls the port tube through. “Now check this out,” he grins to Giufeng. “How do we get rid of the sheath?” Giufeng gives him a helpless glance. “We call this the ‘banana-peel-technique.’ You pull the sheath out of the vessel, then grab those two lashes at its end and pull them apart. The sheath is split in two halves and the port tube is freed. Cunning, isn’t it?” The tube is cut to the correct length, tube and reservoir are connected, and both skin openings are sutured. Foxhenry tests the function of the port using that dedicated port needle and a little contrast and is quite satisfied with the end result (Fig. 7.14).

! A vascular port may only be punctured with a so-called port needle. Normal needles cause leaks! After use, the port must be filled with heparinized saline to prevent clotting of the port tube.

## 7.7 Embolization

### Checklist: Embolization

- Is the region to be embolized dependent on an end artery?
- Does the vascular territory to be embolized feed other crucial vessels?
- Is there a danger of preexistent collaterals into vulnerable regions opening during the embolization?

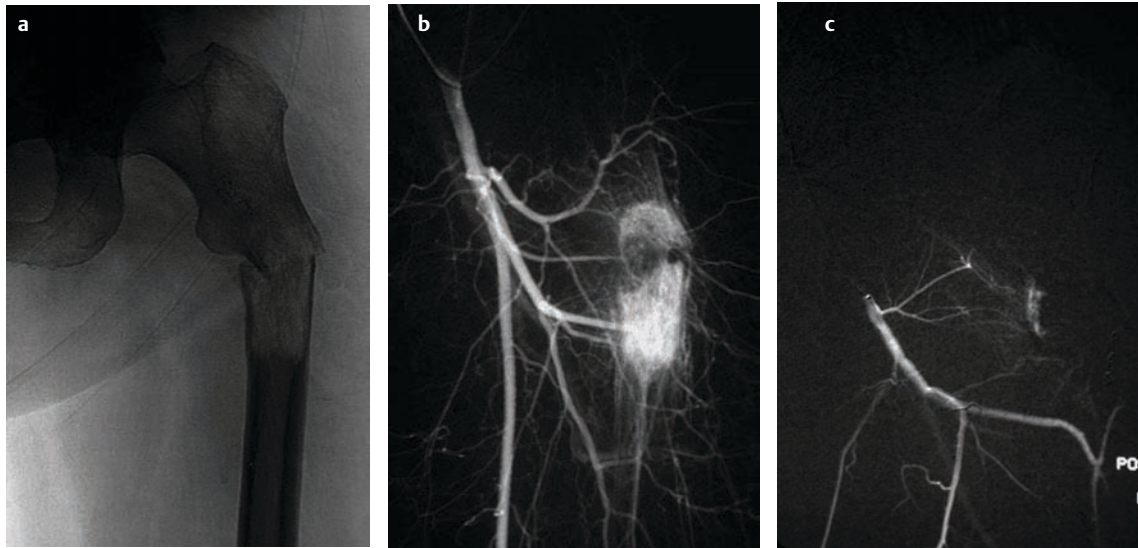
### This Vascular Bed is Put to Rest!

Sid McFlennan (64) had his left kidney removed six months ago because of a renal cell carcinoma. Now he has developed a large swelling in the right thigh after an awkward movement. The radiograph has shown a pathological femur fracture just below the trochanter (Fig. 7.15a). The trauma surgeons want to stabilize the fracture but they fear the large hypervascularized metastatic mass in the area. For that reason they have asked for the preoperative embolization of the mass. Dr. Chaban looks at the images together with Paul and Ajay.

→ **Procedure:** Chaban punctures the femoral artery in the groin in antegrade direction and performs an angiogram of the vascular territory in question (Fig. 7.15b). The large hypervascularized mass lights up with contrast right away—the trauma surgeon’s call for help seems justified. Over a selective catheter Chaban injects tissue glue into the feeding vessels and puts some endovascular coils on top (Fig. 7.15c). “Now it is the surgeon’s game,” he nods to Paul. Ajay wonders where else the technique can be used. “Embolizations of this kind can be performed in all kinds of tumor bleeds. You can, for example, also treat uterine leiomyomas like that. Angiomas and arteriovenous malformations [Fig. 7.16a, see also p. 249] are also dealt with in that fashion. But the action can become extremely tricky if you work in vital vascular territories like, for example, the spinal cord. Obstruction of important vessels with dislodged embolic material or by iatrogenic dissections is the most relevant and consequential complication,” Chaban says with an earnest look on his face. “Fascinating,” says Ajay. Paul is impressed. He has seen enough—intervention is just not his cup of tea.

! Embolizations had better be done by cold-blooded pros.

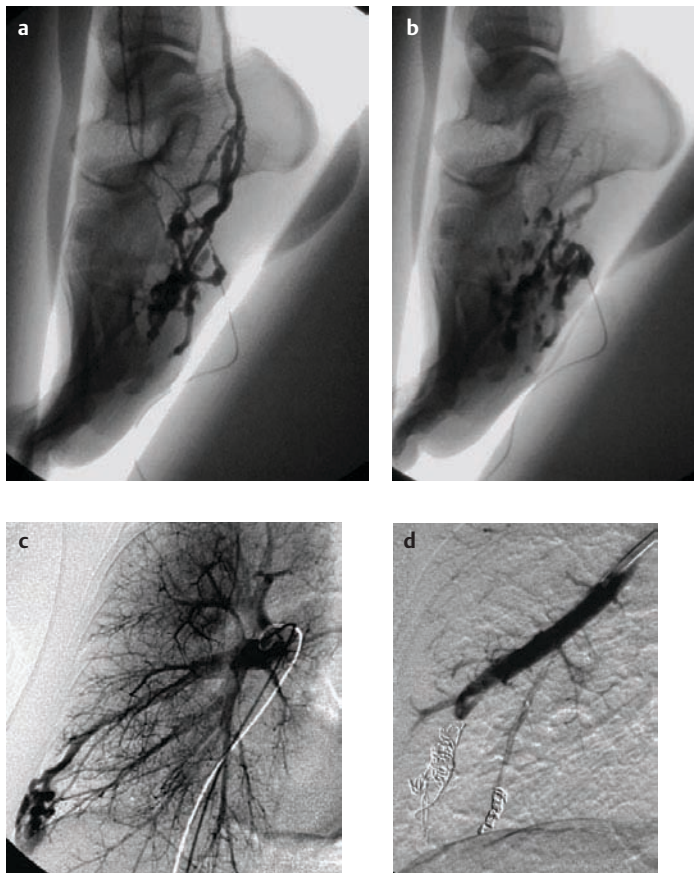
## Embolization of a Metastasis



**Fig. 7.15 a** This metastasis has destroyed the cancellous bone and eroded the cortex. The fragments are scattered around in the adjacent tissue. **b** Selective angiography of the femoral ar-

tery shows the tumor's vascular bed supplied by branches arising from the deep femoral artery. **c** The final run after embolization shows only little residual vascularization within the tumor.

## Embolization of Arteriovenous Malformations



**Fig. 7.16 a** This young man has a vascular malformation of the foot that is the cause of increasing problems: for a start, his shoes do not fit anymore. After percutaneous puncture of the vascular mass with a butterfly needle, the whole extent of the lesion is visualized angiographically. **b** Subsequently, tissue glue mixed with contrast is injected under fluoroscopy. The mass will shrink in the weeks and months to come and with a little luck the symptoms will dwindle. **c** The arteriovenous malformation depicted in this pulmonary angiogram caused relevant shunting. **d** The obstruction of the feeding vessel with a few coils settled the problem.

## 7.8 Neural Blockades

### Checklist: Neural Blockades

- Has conservative pain therapy been given a real chance?
- Has the source of the pain been correctly identified?

### The Pain Relievers Don't Do Their Job Anymore

Hank Podgorny (68) has been a “window shopper” for quite a while, suffering from severe arteriovascular disease. Dilations and stent implantations in his femoral arteries have already been done but they did not really solve his problem. Lately the narrowed small peripheral arteries—those that cannot be dilated with a balloon—have been the cause of his pains. And, well, OK, smoking is the last real pleasure in his life, he says, as his wife sits by his side scowling. The right leg hurts almost constantly and his toes on that side have already turned blue. His family physician has arranged this appointment for him. As Dr. Schaeffer calmly briefs a nervous Podgorny about potential complications such as neuralgia, hypotension, impotence, or failure of ejaculation, his wife leaves the room snorting. Schaeffer turns to Ajay to explain everything about the procedure in the CT control room.

### → Procedures

**Block of the lumbar sympathetic nerve:** “Mr. Podgorny will get a lumbar plexus block. This is a combination of vascular and pain therapy. We block the sympathetic plexus on the right side, thus in effect dilating the peripheral vessels and also treating the pain. Let's measure the temperature of the calf before the intervention.” Mr. Pod-

gorny is already positioned prone on the CT table. The thermometer shows 26.5°C at the medial side of the right lower leg. On the left the temperature is few degrees higher. On a limited CT, Schaeffer has found just the right approach at the level of the L3/4 vertebral bodies. She disinfects the puncture site about 7 cm lateral to the spinous process and injects a local anesthetic. She then advances a long, thin needle along the lateral side of the vertebral body and positions its tip neatly in front of the spine (Fig. 7.17a). She injects a little lidocaine mixed with contrast and waits for 5 minutes (Fig. 7.17b). “Why don't you measure the temperature once more,” she asks Ajay. But Podgorny feels a change already and comes alive: “Sumthin's happenin', Doc,” he declares. The temperature has indeed risen to 32°C. Schaeffer smiles and administers 15 ml of a solution of absolute alcohol mixed with lidocaine and contrast to make the block a definitive one. The final distribution of the mixture is documented once again by CT (Fig. 7.17c). Podgorny is satisfied: “Dad leg ha'n been dis warm for ten years. No pain no more. You ge'me to walk now Doc an' I'm in heaven.” While Podgorny joins his wife who has been chatting animatedly with Magdalena in postinterventional monitoring, Schaeffer explains to Ajay a few other pain therapy interventions that can be elegantly and safely done with CT guidance.

**Block of the celiac plexus:** Block of the celiac plexus is performed in severe pain in the region of the celiac trunk—mostly due to invasive pancreatic carcinomas. The target of the injection that can be done via a dorsal or ventral approach is the celiac plexus around the arterial celiac trunk. After a test injection of lidocaine, approx. 20 ml of a strong alcoholic solution is administered.

**Infiltrations with lidocaine and corticosteroids:** Lumbar nerve root blocks are performed in patients with radicular pain. Peridural infiltrations of the spinal canal are done in cases of spinal canal stenosis. Infiltrations of the intervertebral and iliosacral joints are also possible. All these interventions are best performed with CT guidance.

### Block of the Lumbar Sympathetic Nerve

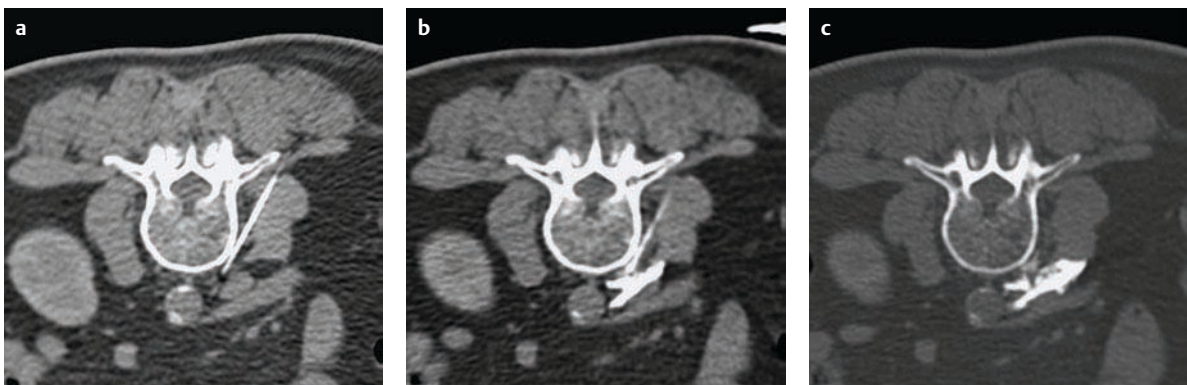


Fig. 7.17 **a** The needle tip is located inside the lumbar plexus directly anterior to the vertebral body. **b** The injected fluid, a mixture of lidocaine and contrast, spreads in the target area. **c** In a second step, 15 ml of a strong alcoholic solution is injected to inactivate the plexus permanently. The final scan documents the sympatholytic fluid in the lumbar plexus.

## 7.9 Gregory's Test

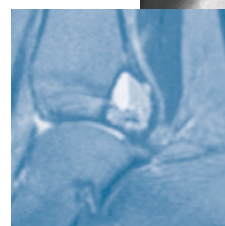Giufeng, Ajay, Joey, and Paul sit around enjoying cup of coffee with some cookies as their day draws to an end. Suddenly Hannah turns around the corner: "You have got to have a look at this," she smiles at them. "Segner is just now taking Gregory apart for good. Greg is all excited and tense." "We should go listen, perhaps we can learn a thing or two," suggests Joey. "Oh, for heaven's sake, why don't you leave them alone. Gregory probably wouldn't appreciate a crowd right now," says Giufeng. "Now, there is a good reason!" Paul grins, and moves to the door together with Joey. "Let's move, mates!"

"This could have gone all wrong and it still may, Gregory," shouts Segner as our students turn the corner. Gregory crouches on the procedure table, his scrubs clinging to his chest like a wet mop. Segner ignores the interns' arrival and continues his yelling sermon with swollen neck veins. "If you do an elective intervention you cannot brief the patient on the table, dammit! When and where must this

happen? And then you did not check the clotting! Just how stupid can one be! Which parameters do you need to know and what are the minimum or maximum levels? And then you had someone inexperienced compress the puncture site—Gregory, you must have had a blackout! Don't tell me about a long intervention! Let me tell you what a long intervention is. You'd better pray that inguinal hematoma does not get larger or get infected. The guys in intensive care will laugh their heads off. Listen, Greg, this is my outfit and this is radiology, not cardiology. You'd better get your act together before you touch another catheter in this department." Segner storms out the door. Gregory takes a deep breath and remains silent—of course he knows that Segner is right. Giufeng pushes the others out of the room "Get lost now, all of you!" she says and returns into the dark room closing the door behind her. Gregory was pretty careless. Giufeng knows why: he learned today that one of his articles has been accepted for publication in *Radiology*. He was absolutely out of it. The hype did not do him any good. Can you help Gregory with the answers to Segner's questions?



## 8 Bone and Soft Tissues



Imaging of skeleton and soft tissues is the cradle of radiology. Here the technology had the greatest therapeutic impact in the early decades. Even today seasoned radiologists are faced with major challenges in this field and must prove their mastery. They share this interest with a sizable number of clinical specialists from other fields with whom—in their own and the patient's best interest—they must be competent partners. Decades of experience, a strong interest in the science behind imaging

phenomena, a substantial library—the most voluminous book on the subject fills about 5000 pages in small print—and an inexhaustible passion for the great interesting case make up a real “bone radiologist.” It is thus nothing to turn into overnight. Students and young colleagues need to constantly search for and learn the key findings to improve their skill in this field. A sound knowledge of the proper clinical indications for the available imaging modalities is a good start (Table 8.1).

Table 8.1 Suggestions for diagnostic modalities in musculoskeletal imaging<sup>1</sup>

Clinical problem	Modality	Comment
Bone pain	XR	Gross assessment of symptomatic areas.
	NM	Bone scan indicated if symptoms persist and plain XRs are negative. Shows number of lesions.
	MRI	Appropriate if symptoms persist and conventional XR and NM fail to diagnose disease.
Suspected primary bone tumor	XR	May help to characterize the lesion; sufficient in many cases; should be carried out when bone pain does not resolve. If XR is suggestive of primary bone tumor, referral to a specialized center is advised.
	MRI	Useful for further characterization and necessary for local staging; should be performed before any biopsy.
	CT	Can show bony detail better at some sites (e.g., spine) and helps analyze internal matrix in some tumors (e.g., osteoid osteoma); easily demonstrates calcification/ossification. Chest CT if CXR is negative to assess pulmonary metastases for many primary malignant lesions. CT-guided biopsy should be carried out in specialized bone tumor centers.
Osteomyelitis	XR	Initial modality of choice, can be normal for first 2–3 weeks.
	NM	Two- or three-phase skeletal scintigram is more sensitive than XR but nonspecific. Labeled white cell scintigraphy may distinguish infection from other lesions.
	MRI	Accurately demonstrates infection, especially in the spine.
	CT	Used to identify bony sequestrum.
Known primary tumor/suspected skeletal metastases	MRI	Primary modality of choice. More sensitive and specific than NM, especially for marrow-based lesions and in the axial skeleton. May underestimate number of peripheral lesions.

CT, computed tomography; DXA, dual-energy x-ray-absorptiometry; MRI, magnetic resonance imaging; NM, nuclear medicine; US, ultrasound; XR, radiography.

Table 8.1 Suggestions for diagnostic modalities in musculoskeletal imaging<sup>1</sup> (Continued)

Clinical problem	Modality	Comment
	XR	Only for specific focal symptomatic areas; correlation with positive NM (exclusion of degenerative disease) and to determine stability.
	NM	Sensitive test but correlative imaging is needed to increase specificity. Useful for overall assessment for skeletal metastases as long as the tumor causes sufficient local bone turnover to become detectable.
Suspected myeloma	XR skeletal survey	For staging and identifying lesions that may benefit from radiotherapy. Survey of limited value for follow-up and to assess response to therapy.
	MRI	Very sensitive, even when limited to spine, pelvis, and proximal femora. Particularly useful in nonsecretory myeloma or in the presence of diffuse osteopenia. Can be used for tumor mass assessment and follow-up under therapy.
	NM	Insensitive test in myeloma.
Osteomalacia	XR	To establish cause of local pain or equivocal lesion on NM.
	NM	Skeletal scintigraphy can show increased activity and some local complications such as pseudofractures. Bone densitometry may be needed.
Metabolic bone disease	XR	May be helpful to differentiate new from old vertebral fractures or to identify different causes of pain. Correlation with NM will be required.
	NM	Skeletal scintigraphy may be useful for differentiating causes of hypercalcemia (metastases, hyperparathyroidism) and of raised alkaline phosphatase (Paget disease).
	DXA	DXA or quantitative CT quantifies bone mineral content.
Arthropathy, presentation	XR affected joint	May be helpful to determine cause, although erosions are a relatively late feature.
	XR hands/feet	In patients with suspected rheumatoid arthritis, XR of feet may show erosions even when symptomatic hands appear normal.
	US or NM or MRI	All accurately show acute synovitis. NM can show distribution. MRI can assess articular cartilage and early erosions.
Arthropathy, follow-up	XR	Needed by rheumatologists to assist management decisions.
Hallux valgus	XR	For assessment before surgery.
<b>Spinal problems</b>		
Pain, suspected osteoporotic collapse	XR	Lateral views will demonstrate compression fractures. NM or bone densitometry (DXA or quantitative CT) provide objective measurements of bone mineral content; can also be used for metabolic bone disease.
	MRI	More useful in distinguishing between recent and old fractures and can help exclude pathological fractures. Excellent modality to assess for extraosseous soft tissue mass in pathological fractures.
<b>Cervical spine</b>		
Neck pain, arm pain, suspected degenerative change	XR	Neck pain generally improves or resolves with conservative treatment. Degenerative changes begin in early middle age and are often unrelated to symptoms.

CT, computed tomography; DXA, dual-energy x-ray-absorptiometry; MRI, magnetic resonance imaging; NM, nuclear medicine; US, ultrasound; XR, radiography.

Table 8.1 Suggestions for diagnostic modalities in musculoskeletal imaging <sup>1</sup> (Continued)		
Clinical problem	Modality	Comment
	MRI	Consider MR and specialist referral when pain affects lifestyle or when there are neurological signs. Myelography (with CT) may occasionally be required to provide further delineation or when MRI is unavailable or impossible to obtain.
<b>Thoracic spine</b>		
Pain without trauma: suspected degenerative change	XR	Degenerative changes are invariable from middle age onward. Imaging is rarely useful in the absence of neurological signs or pointers to metastases or infection. Consider more urgent referral in elderly patients with sudden pain to show osteoporotic collapse or other forms of bone destruction. Consider NM for possible metastatic lesions.
	MRI	May be indicated if local pain persists or is difficult to manage or if there are long tract signs.
<b>Lumbar spine</b>		
Chronic back pain with no pointers to infection or neoplasm	XR	Degenerative changes are common and nonspecific. Main value in younger patients (e.g., less than 20 years), spondylolisthesis, ankylosing spondylitis, etc., or in older patients >55. In cases where management is difficult, negative findings may be helpful.
	MRI	First-choice method when symptoms persist or are severe or where management is difficult. Imaging findings are to be interpreted with caution because abnormalities are frequent and not necessarily related to clinical signs. Negative findings may be helpful.
Back pain with possible serious features such as: <ul style="list-style-type: none"> <li>■ Onset &lt;20 years</li> <li>■ &gt;55 years</li> <li>■ Sphincter or gait disturbance</li> <li>■ Saddle anesthesia</li> <li>■ Severe or progressive motor loss</li> <li>■ Widespread neurological deficit</li> <li>■ Previous carcinoma</li> <li>■ Systemic illness</li> <li>■ HIV</li> <li>■ Weight loss</li> <li>■ Intravenous drug abuse</li> <li>■ Steroids</li> <li>■ Structural deformity</li> <li>■ Nonmechanical pain</li> </ul>	MRI	Together with urgent specialist referral, MRI is usually the best modality. Imaging should not delay specialist referral. NM is also widely used for possible bone destruction, and in cases of chronic pain or where infection is suspected.
	XR	“Normal” plain XR may be falsely reassuring but XR should be done to exclude spondylolisthesis or spondylolysis.
Acute back pain: suspected disk herniation; sciatica with no adverse features	XR	Acute back pain usually due to conditions that cannot be diagnosed on plain XR (osteoporotic collapse and spondylolisthesis are the exception). “Normal” plain XRs may be falsely reassuring.
	MR or CT	Imaging disk herniation requires MRI or CT: MR is generally preferred. Correlation of clinical and imaging findings is important as a significant number of disk herniations are asymptomatic. Either MR or CT is needed before intervention (e.g., epidural injection). MRI is better than CT for postoperative problems.

CT, computed tomography; DXA, dual-energy x-ray-absorptiometry; MRI, magnetic resonance imaging; NM, nuclear medicine; US, ultrasound; XR, radiography.

Table 8.1 Suggestions for diagnostic modalities in musculoskeletal imaging<sup>1</sup> (Continued)

Clinical problem	Modality	Comment
<b>Shoulder problems</b>		
Painful shoulder	XR	Not indicated initially. Degenerative changes in the acromioclavicular joints and rotator cuff are common.
Shoulder impingement	MRI	Although impingement is a clinical diagnosis, imaging is indicated when surgery is being considered and precise delineation of anatomy is required. Degenerative changes are also common in the asymptomatic population.
	US	Subacromial and acromioclavicular joint impingement are dynamic processes that can be assessed by US.
Shoulder instability	CT/MRI arthrography	Glenoid labrum and joint space are well delineated by both techniques. Some gradient echo MR techniques can show the labrum well without arthrography. Arthrography (with or without CT), US, and MRI may all be used in the diagnosis.
Rotator cuff tear	Arthrography, US, or MRI	MRI provides the best global assessment and has highest accuracy when combined with arthrography.
<b>Knee problems</b>		
Knee pain: without locking or restriction in movement	XR	Symptoms frequently arise from internal derangement of ligamentous or cartilaginous structures and these will not be demonstrated on XR. Osteoarthritic changes are common. XRs needed when considering surgery.
Knee pain: with locking, restricted movement or effusion (loose body)	XR	To identify radiopaque loose bodies.
Knee pain: arthroscopy being considered	MRI	Can assist the management decision whether to proceed with arthroscopy. Even in those patients with definite clinical abnormalities, warranting intervention, surgeons find preoperative MRI helpful in identifying unsuspected lesions.
<b>Pelvic and hip problems</b>		
Sacroiliac (SI) joint lesion	XR	May help in investigation of seronegative arthropathy. SI joints is usually adequately demonstrated on A-P lumbar spine or pelvis.
	MRI, NM, CT	MR or CT or perhaps NM when plain XRs are equivocal; earlier detection with MRI, particularly after contrast. MRI is advantageous in children and adolescents.
Hip pain: full or limited movement	XR	Symptoms often transient. Only if symptoms and signs persist or history is complex (e.g., chance of avascular necrosis) or if hip replacement might be considered.
	MR	Useful to demonstrate inflammation. MR arthrography to evaluate acetabular labral tears.
Hip pain: suspected avascular necrosis	XR	Abnormal in established disease.
	MR	Most sensitive in the detection of early avascular necrosis and will demonstrate extent.
Painful prosthesis	XR	To detect loosening.
	NM	Normal skeletal scintigraphy excludes most late complications. Labeled white cell scintigraphy can help distinguish loosening from infection.

CT, computed tomography; DXA, dual-energy x-ray-absorptiometry; MRI, magnetic resonance imaging; NM, nuclear medicine; US, ultrasound; XR, radiography.



Table 8.1 Suggestions for diagnostic modalities in musculoskeletal imaging <sup>1</sup> (Continued)		
Clinical problem	Modality	Comment
<b>In the child</b>		
Nonaccidental injury/child abuse	XR	Age 0–2 years: skeletal survey and head CT mandatory. Age >2 years: XR clinically suspect area. XR should be performed by radiographers trained in pediatric radiographic techniques.
	NM	Skeletal scintigraphy in children >2 years if skeletal survey is equivocal. Findings must be correlated with other patient data.
Irritable hip	US	Will confirm presence of effusions that can be aspirated for diagnostic and therapeutic purposes. Cannot differentiate septic from transient synovitis.
	XR	XR, which may include frog lateral view, is required if slipped capital epiphysis or Perthes disease is suspected and if symptoms persist. If symptoms persist, follow-up should be as for limping child.
Limping	US	Will confirm presence of effusions that can be aspirated for diagnostic and therapeutic purposes. Cannot differentiate sepsis from transient synovitis.
	XR	Proper clinical assessment needed. If pain persists or localizing signs are present, XR is indicated. If slipped epiphyses are likely, lateral XRs of both hips are needed. Gonad protection should be used routinely unless shields obscure area of clinical suspicion.
	MRI	According to local policy, expertise, and availability.
Clicking hip; suspected dislocation	US	XR may be used to supplement US examination. XR is indicated in the older infant.
Osgood–Schlatter disease		Bony radiological changes are visible in Osgood–Schlatter disease but overlap with normal appearances. Associated soft tissue swelling should be assessed clinically rather than radiographically.
Back or neck pain	XR/MRI/CT	Persistent back pain in children may have an underlying cause and justifies investigation. Choice of imaging following consultation. Scoliosis and neurological findings merit MRI/CT. MRI defines spinal malformations and excludes associated thecal abnormality.
Short stature/growth failure	XR for bone age	Only in children >1 year: Nondominant hand only.
<b>Soft tissue problems</b>		
Soft tissue mass/suspected tumor	MRI	Provides best local staging and tissue diagnosis in a proportion of patients.
	US	Can differentiate between solid and cystic tumors, is good for biopsy, and can monitor progress of benign masses such as hematoma.
	CT	Has greater sensitivity for calcification; good for biopsy.
Possible recurrence	MRI	Modality of choice.

<sup>1</sup>Modified after: RCR Working Party. *Making the best use of a Department of Clinical Radiology. Guidelines For Doctors*, 5th ed. London: The Royal College of Radiologists, 2003.

CT, computed tomography; DXA, dual-energy x-ray-absorptiometry; MRI, magnetic resonance imaging; NM, nuclear medicine; US, ultrasound; XR, radiography.

## 8.1 How Do You Analyze a Bone Image?

The analysis of a bone image should always differentiate between assessment of the bone itself, the joints, and the surrounding soft tissues.

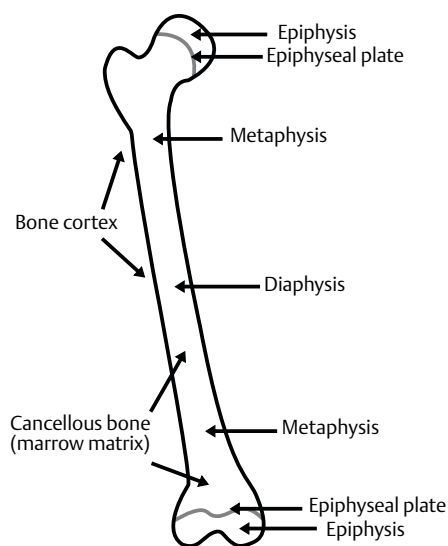
### Bone

Every bone has a typical absolute and age-dependent size as well as a configuration and an axis of orientation typical for its function. Comparison with the contralateral side may be very helpful to the radiologist in ambivalent cases, especially in children.

The bone consists of the outer solid cortical bone and the inner cancellous bone. The **bone cortex** is dense like ivory and is perforated by occasional nutrient vascular channels. Its exterior and interior margins are rather smooth. In hyperparathyroidism or if aggressive metastases infiltrate from the outside, the bone cortex becomes permeated. In metastases of the cancellous bone or multiple myeloma this occurs from the inside. The normally smooth outer contour becomes unsharp when the periosteum reacts to injuries (periosteal callus formation; periosteal reaction), inflammations, and neoplastic lesions.

The **cancellous bone** with its very location-specific architecture gives the bone stability while its weight remains low. The very well vascularized bone marrow rests in its interstices. It normally has a high fat component except if hematopoiesis is increased, such as in children and women with strong menstrual bleeds. Inflammatory and neoplastic diseases frequently occur here and destroy the

#### A Diagram of Bone



See the main terms used in bone anatomy.

typical radiological pattern of spongiosa. In thick bones or where air- and feces-filled intestines are superimposed over the bone, such as the over the iliac bone, large defects of the cancellous bone may go undetected. Other modalities can help in these cases: bone scans visualize the increased regional or focal bone turnover and MRI shows—among other things—the displacement of the fatty bone marrow. With age (*carpe diem*—seize the day: age begins at 35 here) the bone density decreases slowly. Corticosteroids accelerate this process, which typically increases the risk for vertebral body and femoral neck fractures. During extended phases of physical inactivity (after fractures and other injuries; space missions—lack of gravity) the bone density decreases, particularly in the vicinity of the joints. As physical activity is resumed, an altered, coarser trabecular pattern may remain.

### Joints

A joint consists of the articulating bones, the cartilage, any additional special fibrous cartilage (i.e., menisci), ligaments, tendons, and the joint space, which is lined by the synovial membrane and contains synovial fluid. Conventional radiographs demonstrate only a limited number of these structures. The configuration of the articulating bones is one major radiographic finding. Only magnetic resonance tomography depicts all joint components.

In osteoarthritis, the *degeneration* of a joint over time, one can observe formation of osteophytes in the periphery of the joint, an eccentric loss of joint space in the area of heaviest physical load, sclerosis, and subchondral cyst formation. In a primary *inflammation* of the joint, also termed inflammatory arthropathy, subchondral demineralization, a generalized concentric loss of joint space, bone erosions in the joint periphery close to the synovial insertion, and occasionally even ankylosis may occur. Small osseous fragments, so-called “loose bodies” can be detected in the joint. Joint effusions may become evident by the displacement of fat pads adherent to the joint capsule or located directly in the joint (such as the Hoffa fat pad in the knee). Articular recesses that are normally collapsed become visible small opacities when the joint is fluid-filled and they are surrounded by fatty tissue planes.

### Soft Tissues

The soft tissues—muscles, ligaments, tendons, fat planes, nerves, and vessels—are difficult to evaluate with plain radiographs. Of course, severely calcified vascular walls in atherosclerosis are easy to appreciate and should be commented upon. Anatomical interfaces between fat and other soft tissues can be very helpful in radiography (i.e. to diagnose lipomas or joint effusions). An optimal evaluation of the soft tissues, however, is possible only with MRI owing to its superb soft tissue contrast (see Fig. 4.4a, p. 20).

## I See an Abnormality—What Do I Do Now?

Follow the scheme described below and try to answer the following questions:

- Is it a focal process of the bone or is it there generalized osseous change?
- Is the osseous lesion lytic (bone structure is lost) or blastic (bone structure becomes denser)?
- Is the key symptom articular pain?
- Is the key symptom back pain?
- Is there an associated soft tissue mass?

The acute traumatic findings will be dealt with in the chapter on trauma (Chapter 14). Now let us have a look at the first case.

## 8.2 Diseases of the Bone

### Focal Bone Lesions

#### Checklist: Focal Bone Lesions

- How old is the patient?
- Are there clinical symptoms?
- Where in the bone is the lesion?
- What is its biological behavior (Table 8.2)?

### There Ain't No Class without Gwilym Lodwick

Boris Packer (22) has bruised his knee joint severely during one of his international tennis tournaments. Looking at the radiographs, Paul is pretty sure that there is no fracture. He has, however, searched the image with great care and has found a circumscribed lesion in the distal femur (Fig. 8.1). Boris has never had any complaints in this area before the tournament. It is undoubtedly an incidental finding. Has Paul saved Boris's life by detecting a little malignant lesion so early that it can be resected without any further harm? Or is this a benign lesion that should best be ignored to spare Boris the risks of more invasive diagnostic procedures? Paul remembers good ol' Gwilym Lodwick's time-honored classification of bone lesions (Table 8.2). He defines the lesion as a Lodwick grade IA, which indicates a benign nature.



#### Who is Gwilym Lodwick?

Gwilym Lodwick was a famous American bone radiologist. After leaving his chair at the University of Missouri at Columbia, he and his gigantic collection of skeletal cases moved into a little office at the Massachusetts General Hospital of the Harvard Medical School. There he continued to teach for a long time. He was not easy to get along with but was a full-blooded, dyed-in-the-wool radiologist.

Table 8.2 Classification of bone lesions according to Gwilym Lodwick<sup>1</sup>

Grading	IA	IB	IC	II	III
<b>Criteria of the lesion</b>					
<b>Pattern</b>	Geographic	Geographic	Mandatory geographic	Moth-eaten or geographic	Mandatory permeative <sup>2</sup>
<b>Contour</b>	Regular Lobulated Multicentric, (but sharp)	Regular Lobulated Multicentric Ragged/poorly defined	Regular Lobulated Multicentric Ragged/poorly defined Moth-eaten (<1 cm)	Edge characteristic if geographic, mandatory moth-eaten edge >1 cm	Any edge
<b>Cortex penetration</b>	None/partial	None/partial	Mandatory total	Total by definition	Total by definition
<b>Sclerotic rim</b>	Mandatory	Optional	Optional	Optional but unlikely	Optional but unlikely
<b>Cortical expansion</b>	Optional, expanded cortex ≤1 cm	If sclerotic rim present, expanded cortex >1 cm	Optional expanded cortex	Optional but unlikely	Optional but unlikely
<b>Malignancy</b>	More likely to be benign			More likely to be malignant	

<sup>1</sup> Lodwick et al. Determining growth rates of focal lesions of bone from radiographs. *Radiology* 1980; 134: 577–583.

<sup>2</sup> Infiltrating the cortex.

### The Case of Boris Packer

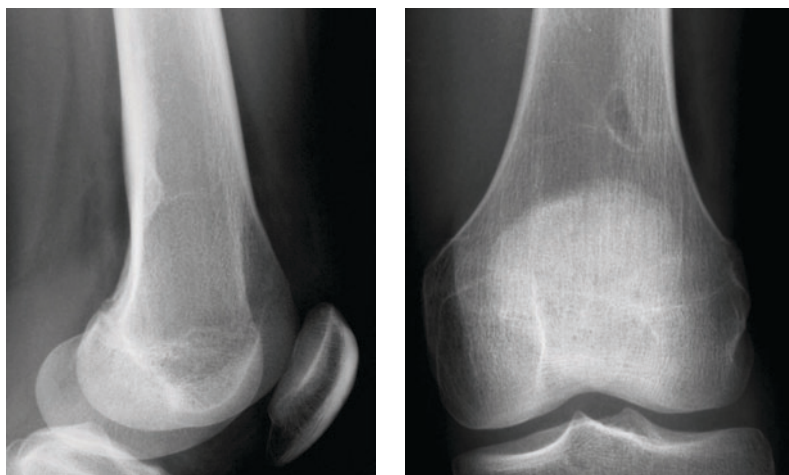


Fig. 8.1 You see a magnified view of the knee radiograph of Boris Packer. Is there anything abnormal?

→ **What is Your Diagnosis?** These are frequent benign bone tumors in childhood and adolescence:

**Enostosis:** The enostosis, also called “bone island,” is an island of cortical bone within the cancellous bone. Radiologically it appears as a focal, mostly round or oval sclerosis of the cancellous bone without any response in the surrounding bone (Fig. 8.2). The enostosis often does not show activity on bone scans and can thus be differentiated from osteoblastic metastases in ambivalent cases.

#### Enostosis

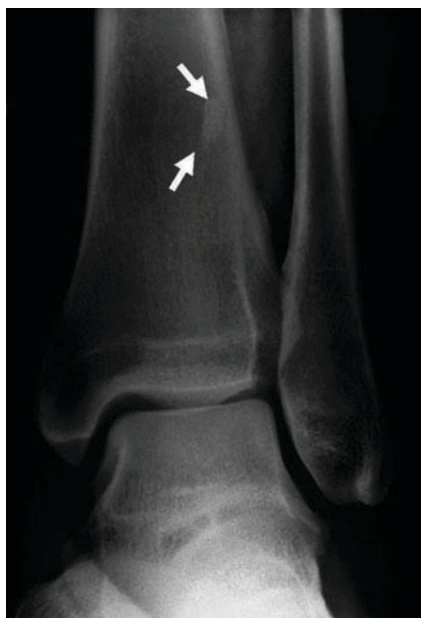

Fig. 8.2 This dense bone island (arrows) is located in the distal metaphysis of the tibia close to the cortex.

**Osteoma:** An osteoma consists of very dense bone and occurs most often in the paranasal sinuses (Fig. 8.3). It can be associated with intestinal polyposis (Gardner syndrome).

**Osteoid osteoma:** This tumor is most often located in the bony cortex of the femur and tibia but also in the axial skeleton. It consists of a severe periosteal reaction with new bone formation around an often rod-shaped nidus that contains a neurovascular bundle (Fig. 8.4). Nocturnal pain that is relieved by low-dose acetylsalicylic acid is a typical symptom. The interventional radiologist can treat this lesion by inserting a radiofrequency needle into the nidus and ablating the neurovascular bundle by electrical coagulation or by alcohol instillation.

**Enchondroma:** An enchondroma is a cartilaginous, lobulated tumor within the marrow space of cancellous bone, frequently in the hand bones (Fig. 8.5). It tends to

#### Osteoma

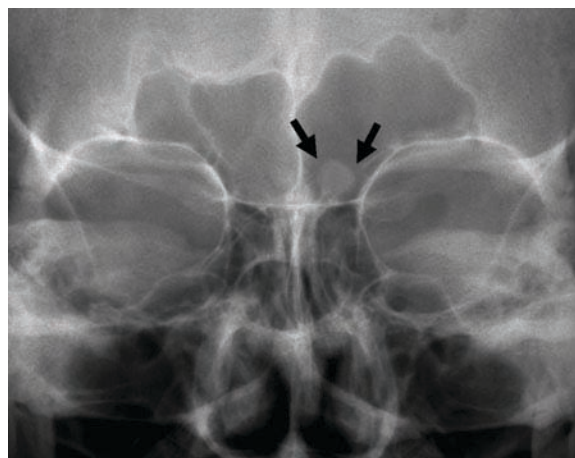


Fig. 8.3 This pea-sized dense sclerotic lesion (arrows) sits in the left frontal sinus. It is an osteoma in a typical location.



### Osteoid Osteoma

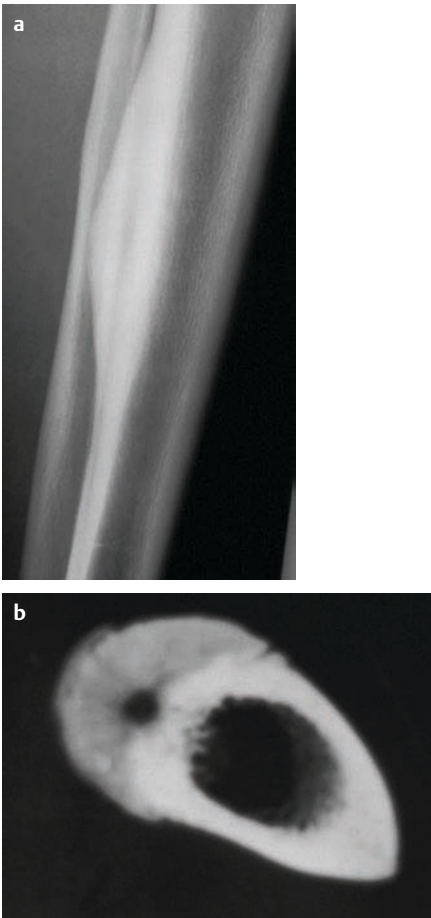


Fig. 8.4 **a** The dorsal cortex of the tibia is significantly thickened—a nidus can only be suspected. **b** CT gives more information. The reactive new bone formation around the nidus is well appreciated. This nidus must be resected/drilled out by the surgeons or ablated with alcohol or coagulated electrically by the interventional radiologist.

have a sharp margin, can erode the cortex, and occasionally contains “popcorn” shaped calcifications. If symptoms arise, especially in older patients, a malignant transformation into a *chondrosarcoma* must be excluded. If enchondromas arise at multiple locations, an *enchondromatosis*

### Enchondroma

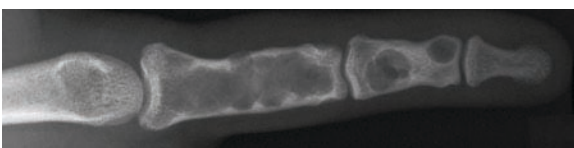


Fig. 8.5 A number of typical enchondromas are depicted in the proximal and middle phalanx of this finger. They can cause fractures.

(syn.: *Ollier disease*) may be present that may lead to fractures in affected bones during childhood and malignant transformation in adulthood (up to 30%). If soft tissue hemangiomas are also seen, *Mafucci syndrome* is present.

### Osteochondroma

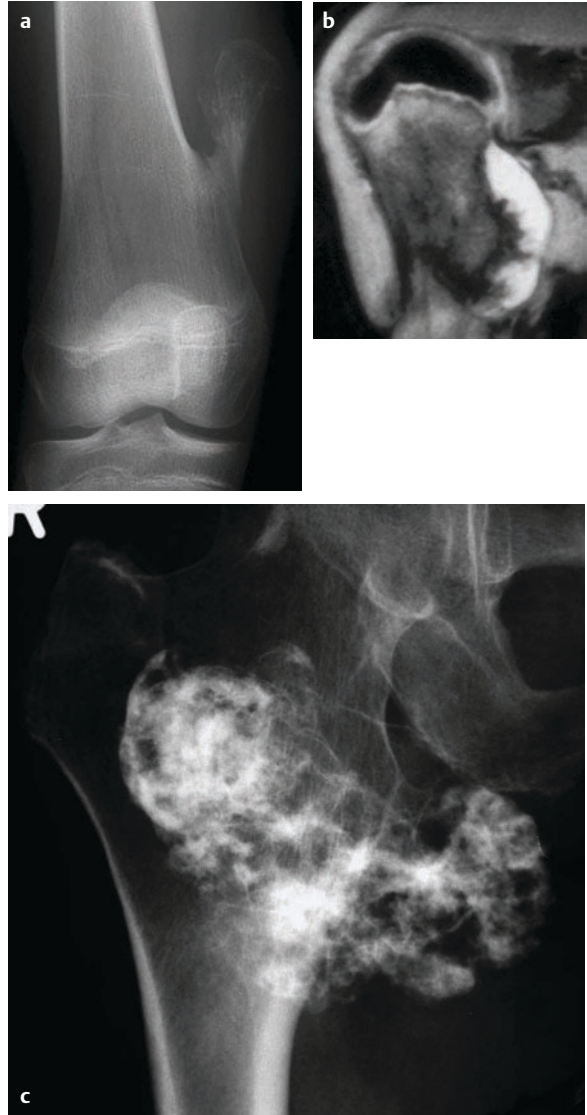


Fig. 8.6 **a** This typical cartilaginous exostosis extends medially and takes the bone cortex with it. If these lesions reside in the direct vicinity of a neurovascular bundle, mechanical impairment may develop. They may fracture, as this one has at its base. **b** This is a broad-based osteochondroma of the proximal metaphysis of the humerus in a young patient (the epiphyseal cartilage is still visible). It shows a thick cartilaginous cap. With increasing age, this chondral cap will lose its thickness. This MR sequence is a dedicated T2-weighted chondral sequence on which the cartilage demonstrates a very high signal. **c** Chondromatous tumors may turn into malignant chondrosarcomas such as this one. The popcorn-like structure of the cartilaginous calcifications is quite typical for this entity. These are tumors of the older patient.

### Nonossifying Fibroma

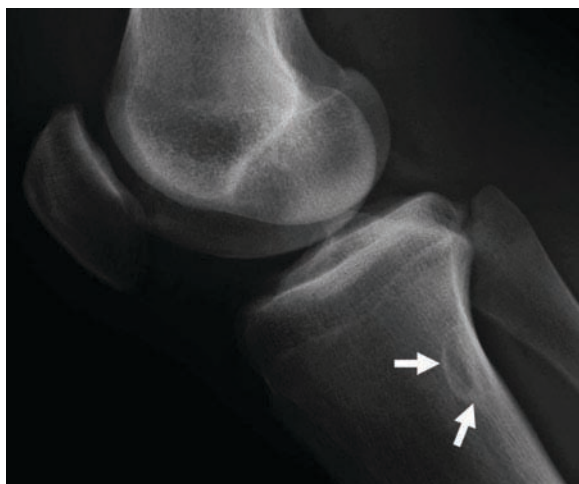

Fig. 8.7 Have a look at the bubbly bone lesion (arrows) in the dorsal proximal tibia hugging the bone cortex. It has a sclerotic margin. This is a typical nonossifying fibroma that should best be left untouched. It heals on its own come adulthood.

**Osteochondroma:** An osteochondroma or an osteocartilaginous exostosis (Fig. 8.6a) is a frequently stalked protrusion of the metaphyseal bone with a cartilaginous cap (Fig. 8.6b) that can calcify and normally decreases in thickness as the skeletal growth comes to an end. The exostoses can cause restrictions of movement as well as injuries to the vessels and nerves. If the thickness of the cap increases again, or if new symptoms arise, a malignant transformation to a *chondrosarcoma* (up to 25%) must be excluded, especially if multiple osteochondromas are present (Fig. 8.6c).

**Nonossifying fibroma:** This tumor has a bubbly, grapelike appearance with a sclerotic margin and is found immediately adjacent to the inner surface of the metaphyseal cortex of mostly long tubular bones. With increasing skeletal age it moves toward the epiphysis (Fig. 8.7). It

is a frequent incidental finding in children and adolescents.

**Giant cell tumor:** The giant cell tumor occurs in early adulthood (never during childhood) and usually lodges close to the knee joint (approx. 50%). It is often associated with an eccentric osteolysis that can erode or expand the cortex (Fig. 8.8a). Infiltration of the soft tissues is possible and emphasizes the semimalignant character of the tumor. In sectional imaging modalities, fluid–fluid interfaces are occasionally visible inside the tumor (Fig. 8.8b).

Paul must, however, also exclude some other diagnoses:

**Fibrous dysplasia:** In this bone malformation, which can occur as a single lesion or multiple lesions (associated with café-au-lait skin lesions and precocious puberty as part of the McCune–Albright syndrome), the tubular bone is expanded and often bent, and the bony cortex is often eroded but not completely perforated. The inner structure of the bone has a “ground glass” appearance (Fig. 8.9a) on CT. In the skull the irregular sclerosis and the expansion of the bone dominate the picture (Fig. 8.9b, c), which can lead to an injury of cranial nerves.

### Bone cyst:

**Simple bone cyst:** The simple bone cyst becomes symptomatic when the weakened cortical bone fractures at its site. It is a bubbly lesion located in the metaphysis of cancellous bone close to the epiphysis, often with a sclerotic margin. The lesion is fluid-filled and expands the cortex slightly. If it fractures, hemorrhage into the cyst may occur and a cortical fragment often falls inside the lesion. This is as typical a sign for a bone cyst as there is in radiology and is called the “fallen-fragment sign” (Fig. 8.10a).

**Aneurysmal bone cyst:** This lesion is an osteolytic process and consists of a blood-filled cavity. The aneurysmal bone cyst is located eccentrically in the metaphysis of tubular bones. The cortex may be expanded and perforated. For that reason differentiation from malignant lesions is not always possible. On MRI or CT fluid–fluid interfaces may be seen within the cystic fluid (Fig. 8.10b).

### Giant Cell Tumor

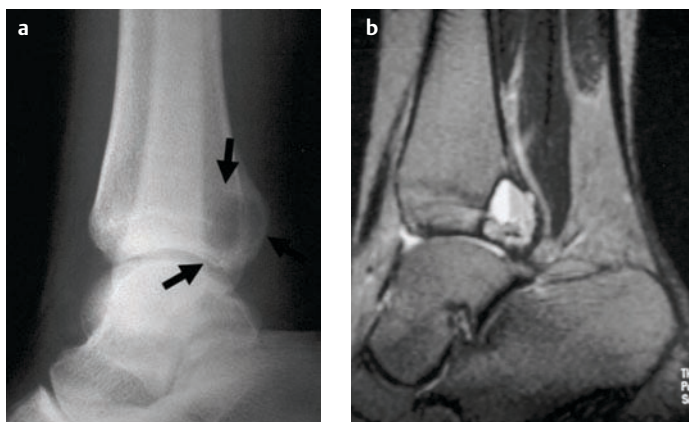
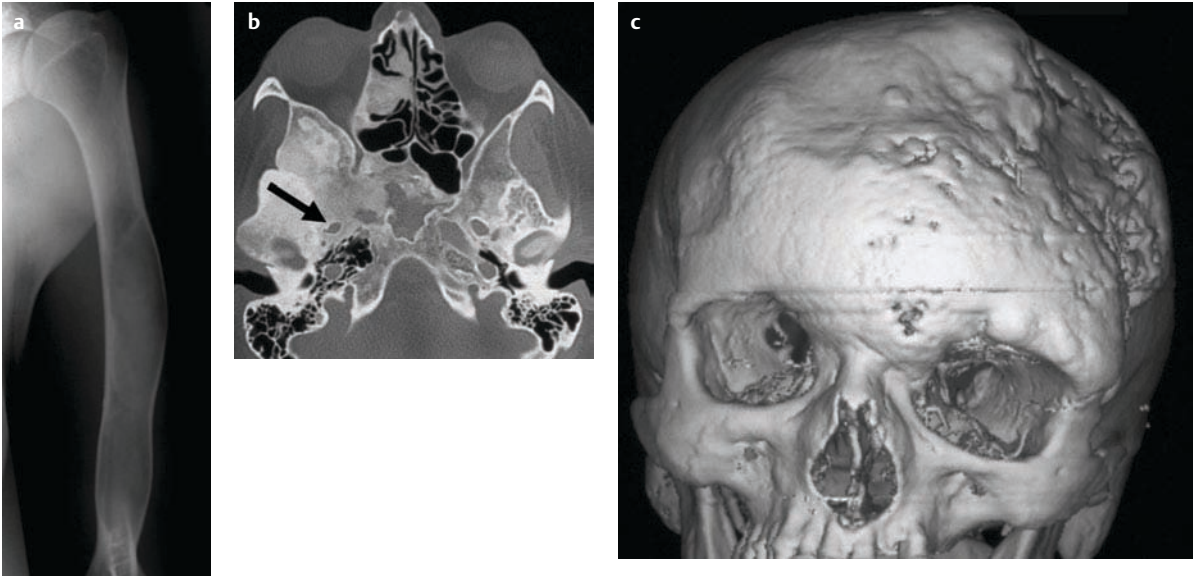


Fig. 8.8a The margins of this bone lesion (arrows) are very irregular and ill defined. The cortex has clearly been destroyed. This is a typical giant cell tumor. b On MRI the same lesion shows a fluid–fluid interface. You can also appreciate a focal defect of the cortex.

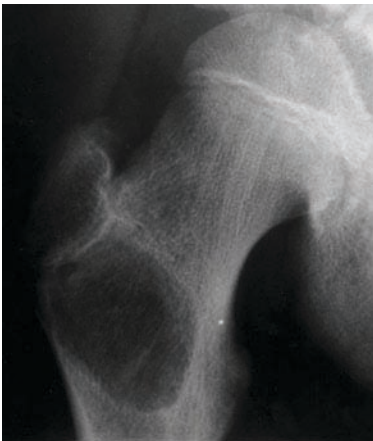
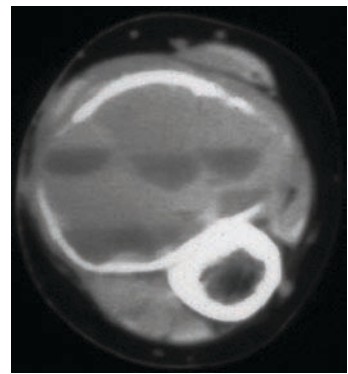
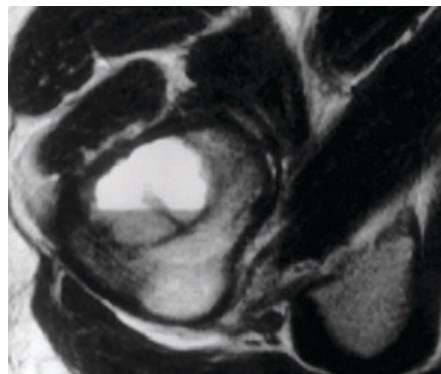
## Fibrous Dysplasia



**Fig. 8.9a** Fibrous dysplasia is characterized by an expansion of the affected bone and a ground-glass-like internal structure of the bone. In this case it is located in the diaphysis and the distal metaphysis of the humerus. It occurs with greater frequency at the skull base and in the facial bones. **b** On the right side, the bone of the skull base is expanded, the normal cancellous bone structure replaced. The right oval foramen (nicely indicated by

the smaller foramen spinosum directly posterolateral to it) is clearly smaller than the left: in fibrous dysplasia the cranial nerves passing through the skull foramina may eventually be compressed. **c** Shown is the drastic alteration of the skull in fibrous dysplasia. The famous “Elephant Man” who lived in London in the late 19th century could very well have been a case of fibrous dysplasia. Discussion continues, though.

## Bone Cyst

**a** Simple bone cyst**b** Aneurysmal bone cyst

**Fig. 8.10a** This radiograph (left) displays a large bone cyst surrounded by a fine sclerotic margin. In its inferior portion a very close look reveals a small piece of bone suspended in the cyst, the “fallen fragment.” A T2-weighted MR examination (right) documents an interface between blood and serous fluid. The bone fragments cross the horizontal interface. Blood and

bone fragment are due to the fracture, which rendered this simple bone cyst symptomatic. **b** This aneurysmal bone cyst has expanded the tibia and destroyed the cortex, and also contains a fluid–fluid interface. This is a typical finding, which nonetheless requires histological confirmation.



### Stress Fracture

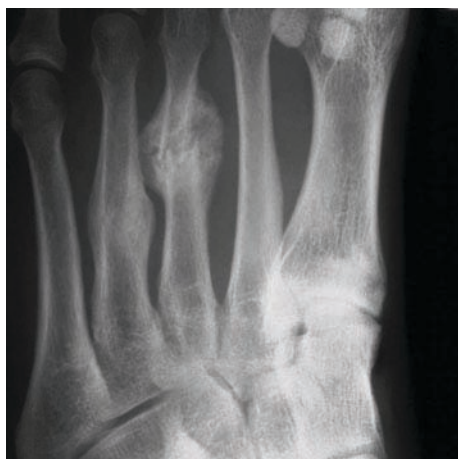

Fig. 8.11 This patient has trained for the New York marathon for four months. The pain in his foot began at the beginning of the training, which is why he blamed it on a new set of running shoes he got for the occasion. The fracture line in the metacarpal bones is frequently barely visible, quite unlike the hypertrophic formation of callus that is regularly seen.

**Stress fracture:** Stress fractures of the metatarsal bones (“insufficiency fracture,” “march fracture,” Fig. 8.11) or in the long tubular bones such as the tibia and the femur develop in the context of chronic excess physical strain. Reactive periosteal and endosteal bone formation occurs together with repetitive microfractures that can become visible as fine fracture lines. The bone scan shows a very high bone turnover.

**Bone infarct:** A bone infarction may lead to popcorn or snakelike (serpiginous) calcifications in the cancellous bone (Fig. 8.12). It occurs with greater frequency in steroid therapy, alcoholism, and diver’s disease (decompression sickness). In the large bones it can resemble a cartilaginous tumor.

→ **Diagnosis:** Paul decides that this is a nonossifying fibroma that needs no further work-up. He is right. It is a so-called “don’t touch me” lesion. Boris may return to the center court.

! *Primum nihil nocere* (First, do no harm)! If a definitely benign lesion is not recognized as such and further superfluous studies are performed, the patient suffers—psychologically and potentially even physically.

#### It’s Yet Another Case for Gwilym

Two days later Paul sees the radiograph of 12-year-old Anthony, who has been complaining about pain and swelling of his lower arm for a few weeks (Fig. 8.13). The boy cannot remember a direct trauma. His mother,

### Bone Infarction

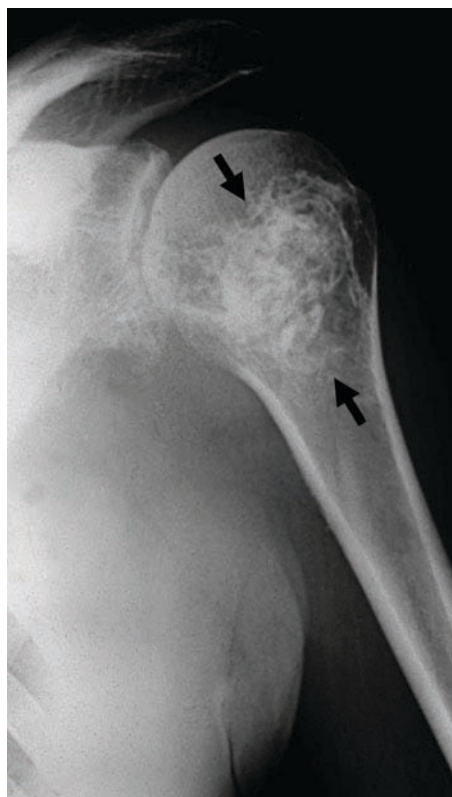


Fig. 8.12 The calcifications within the cancellous bone of this humerus (arrows) are typical of a bone infarct.

however, recalls an incident four weeks ago when her son fell against the furniture while chasing his little sister through the apartment. Paul follows the same procedure he has used in Boris’s case and classifies the lesion as a Lodwick grade III (see Table 8.2).

→ **What is Your Diagnosis?** In this age group, Paul must contemplate the following diagnoses:

**Osteosarcoma:** The osteosarcoma develops in adolescents and young adults preferentially in the proximal humerus as well as the femur and tibia close to the knee joint. It causes osteolytic and osteoblastic destruction of the bone. As it is a fast-growing tumor, the cortical and cancellous bone are eroded before the surrounding soft tissues are infiltrated. The periosteum does not succeed in capping the process: “sunburst”-like speculations emanate from the affected bone at a 90° angle to its long axis and “onion peel” or triangular (“Codman triangle,” Fig. 8.14a) periosteal bone formation is the result. The osteoblastic sarcoma type leads to sclerosis of the bone and bone formation in the surrounding soft tissues. Pulmonary metastases of this tumor type typically show ossifications (Fig. 8.14b).



### The Case of Anthony

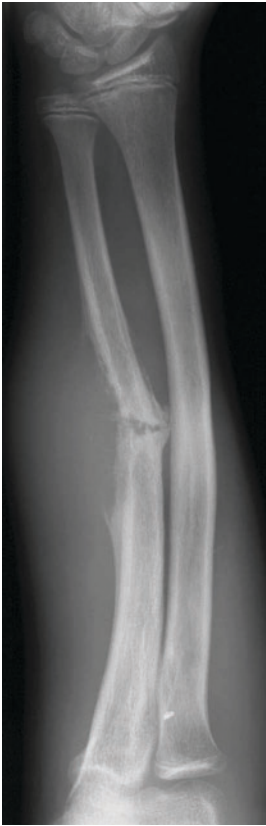

Fig. 8.13 The findings on this radiograph of 12-year-old Anthony are clear and impressive. Which diagnoses do you have to consider?

**Ewing sarcoma:** Ewing sarcoma is also a bone tumor of children and adolescents. It is a very aggressive lesion and therefore infiltrates and permeates the bone without giving it a chance to form any substantial sclerotic reaction. Ill-defined destruction of the affected bone results in a radiographic appearance that is often termed “moth-eaten.” The periosteum behaves as in the case of osteosarcoma, with unsuccessful periosteal new bone formation (Fig. 8.15). Differentiation between the two entities is not possible radiographically with sufficient certainty.

**Osteomyelitis:** An *acute hematogenous osteomyelitis*, an infection of the bone, becomes visible in the radiograph through periosteal new bone formation and defects in the cortex and cancellous bone (Fig. 8.16). These signs, however, develop only weeks after the infection. Morphological differentiation from malignant bone lesions is difficult, especially in children. If the process is successfully walled off within the bone, a “*Brodie abscess*” is the consequence—a focus of osteolysis surrounded by a thick sclerotic margin. *Chronic osteomyelitis* is frequently maintained by a sequestered bone fragment that is devascularized and therefore inaccessible to antibiotics. These sequestered fragments tend to be very dense on the radiograph and are occasionally surrounded by a cavity, called “*Totendale*” in German (meaning “ark of death”). Because they maintain the infection and are often accompanied by fistulas, they must be removed surgically.

### Osteosarcoma

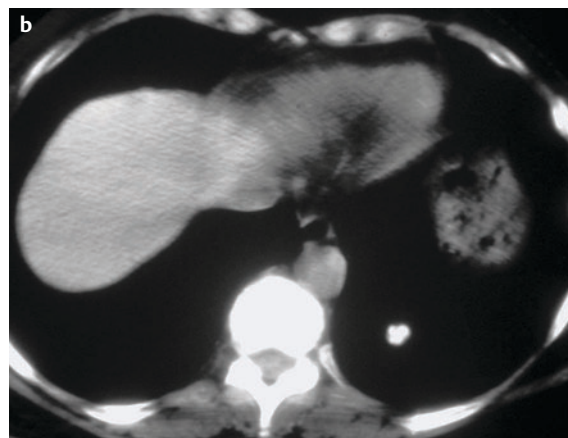
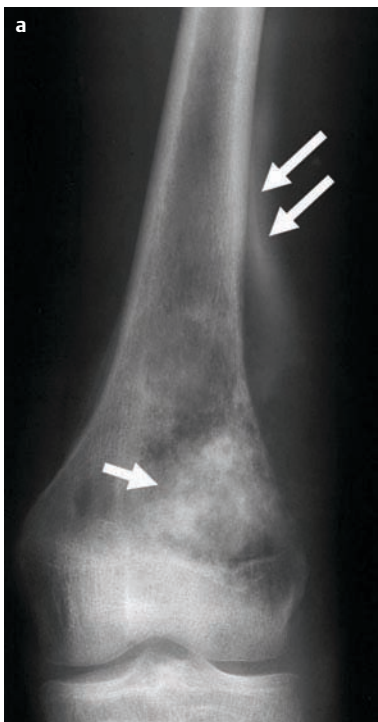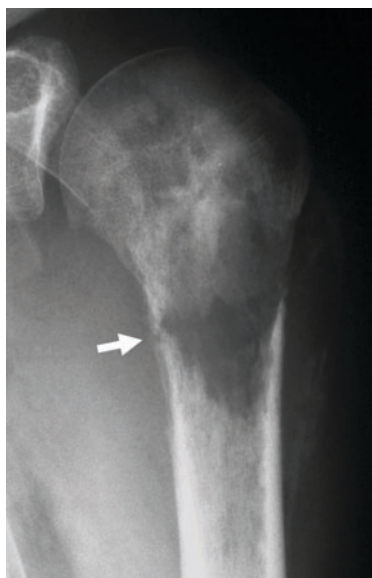


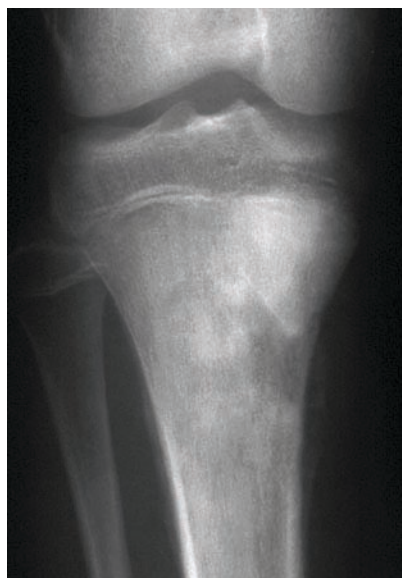Fig. 8.14 **a** This osteosarcoma in the distal femur shows all the hallmarks of malignancy. Its margin to the bone is unsharp, also referred to as a wide zone of transition. The cortex has been destroyed. The periosteum attempts to cover up the aggressive process, forming the so-called Codman triangle in the upper lateral part (thin arrows). In addition there is ossification in the distal lateral component of the tumor (thick arrow). Do you also see the periosteal reaction on the medial side of the metaphysis? **b** Pulmonary metastases of osteosarcomas are frequently ossified. This is best appreciated in the mediastinal or bone window settings when reviewing a chest CT.

## Ewing Sarcoma



**Fig. 8.15** This Ewing sarcoma has destroyed the bone almost entirely—there is a pathological fracture (arrow). The margin of the defect is extremely irregular (moth-eaten, wide zone of transition). The periosteum tries to contain the tumor but in this frustrating process it has been displaced far laterally already.

## Osteomyelitis



**Fig. 8.16** This lesion also fulfills all the morphological criteria of malignancy. However, the young patient (see the configuration of the epiphyseal cartilage, which indicates an age between 15 and 17 years) complains about pain, fever, redness, and swelling in the area. Osteomyelitis is the most likely diagnosis in this case, and was confirmed histologically.

→ **Diagnosis:** Paul has understood the importance of the clinical situation and the potential implications of his eventual diagnosis. He suggests a bone scan to prove the singularity of the lesion or to find further lesions of the same kind. In addition he recommends a leukocyte scintigraphy to exclude or verify an osteomyelitis. Deep in his heart he knows that histological proof must be achieved because Anthony has a malignant bone tumor until proven otherwise. Because any tissue biopsy will cause hemorrhages that can change the appearance of the tumor, he organizes an MR appointment right away. This examination will document the extent of the tumor within the bone marrow and the soft tissues to the surgeon and will establish the tumor volume at the outset of potential neoadjuvant, preoperative chemotherapy. Anthony now needs a good guardian angel and an experienced team of doctors.

! It is quite frequent that patients with a malignant bone tumor recall some trauma at that site. This is mainly a psychological phenomenon that should not defocus our efforts to reach a conclusive diagnosis.

### Sometimes Things Are Less Complicated (Unfortunately)

Paul's colleague Giufeng meanwhile has another problem. She looks at the pelvic radiograph of Mrs. Agatha

Kristeeze (75). Mrs. Kristeeze has been complaining about diffuse pains in the region of her left hip for quite some time now. Reading a good thriller has been much less fun than it used to be, she has lost weight, and she feels a bit feeble. Giufeng recognizes an ill-defined, sclerotic lesion in the left ischial bone as well as an irregular bone pattern in the left greater trochanter (Fig. 8.17).

### → What is Your Diagnosis?

Gwilym Lodwick is not really needed in this case—the combination of clinical symptoms and the radiograph points Giufeng the direction of malignancy, most likely metastatic disease:

**Metastases:** In elderly people metastases are the most frequent focal bone lesions. They can be osteolytic (for example, kidney, breast, thyroid cancer; Fig. 8.18a), mixed (breast), or osteoblastic (for example, prostate, breast; Fig. 8.18b). They tend to be rare in the peripheral skeleton. The lesions often have an ill-defined margin with irregular contours. They can also destroy the cortical bone. In tumor patients, a bone scan is a good test to assess for metastatic spread, although it may miss metastasis in very aggressive tumors where surrounding bone does not have sufficient time to produce a reactive osteoblastic response. Tumors that are predominantly osteolytic cause foci of decreased radiotracer activity on bone scan that are much more difficult for the radiologist to perceive than small focal areas of increased activity. There are now promising efforts

## The Case of Agatha Kristeeze

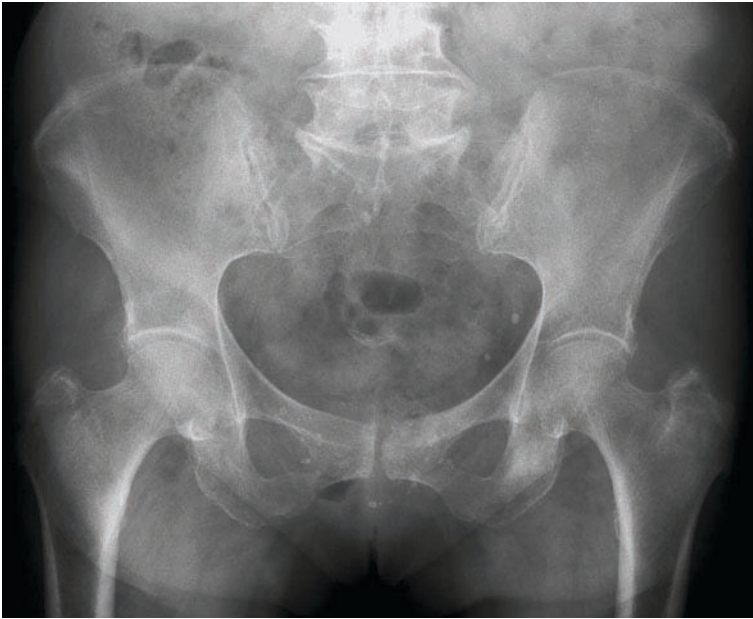
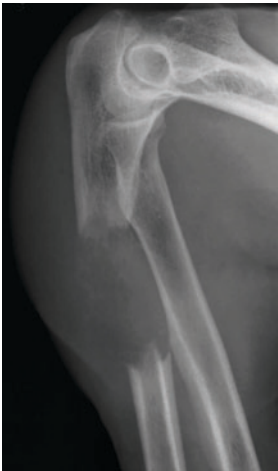
Fig. 8.17 You are looking at the pelvic radiograph of Agatha Kristeeze. Do you agree with Giufeng?

## Metastases

**a** Osteolytic metastases



**b, c** Osteoblastic metastases

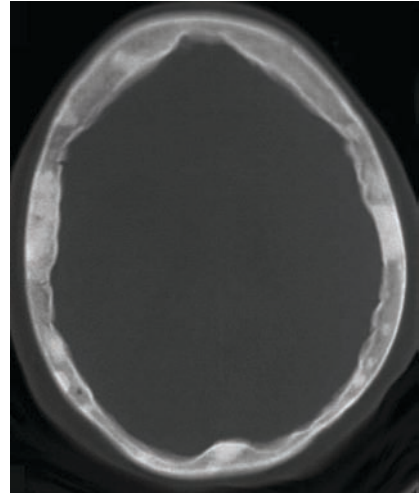
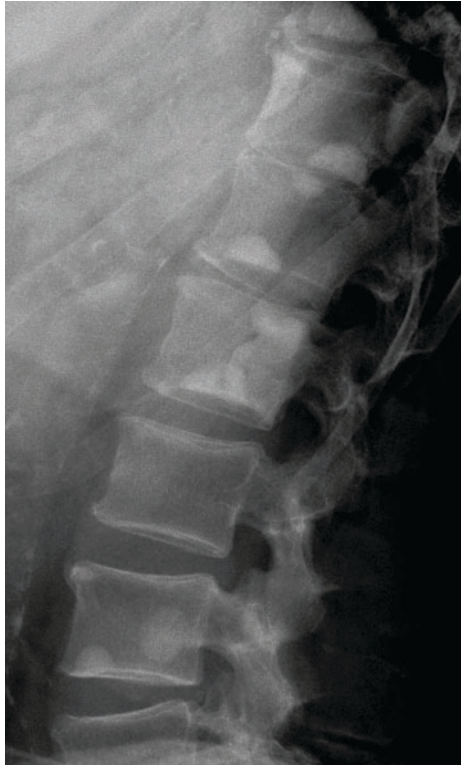

Fig. 8.18 **a** This osteolytic metastasis has led to a pathological fracture of the ulna. The defect is very irregular in its margin and a large soft tissue component seems to be present as well. The patient had a renal carcinoma of which this was a peripheral metastasis. **b** The lumbar vertebrae show multiple

very dense regions indicating osteoblastic metastases. This man had a prostate carcinoma. Had the patient been a woman, one would have had to consider primarily underlying breast cancer. **c** The bone windows of the head CT in this same patient show the osteoblastic lesions in the skull.



### Multiple Myeloma

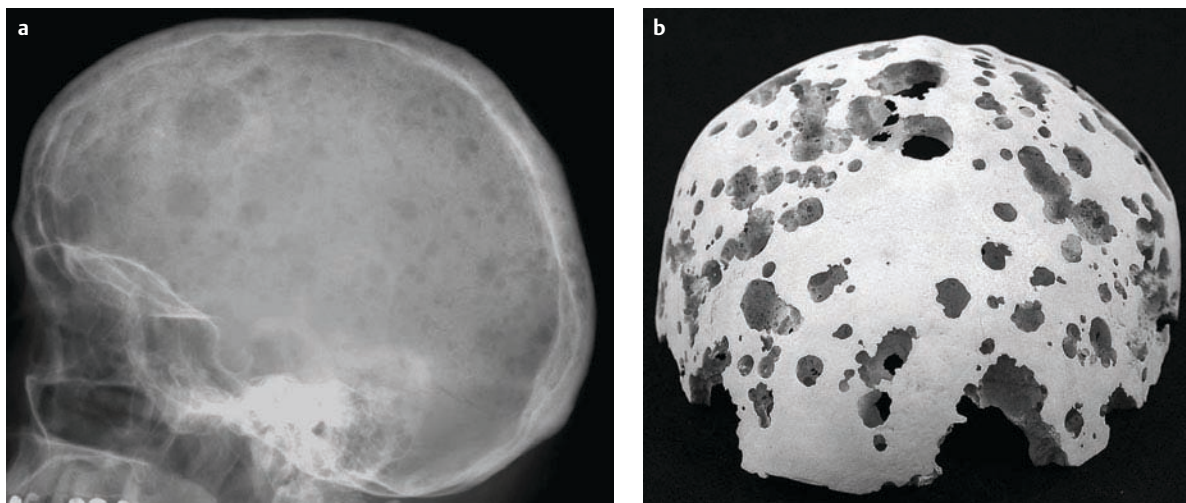


Fig. 8.19 **a, b** The radiograph of the skull (**a**) shows multiple patchy defects. An extensive infiltration of the cancellous bone with abnormal myeloid cells is likely. This historic specimen (**b**) emphasizes the degree of destruction that may be present in myeloma. (Thanks to the Berlin Museum of Medical History for permission to use this photograph.)

under way to use whole-body MRI to screen for metastases, which may be more sensitive overall. Targeted radiographs then exclude degenerative changes as a cause of the increased bone turnover and may help define the risk of fracture before radiation therapy or a surgical treatment is initiated.

**Multiple myeloma:** Multiple myeloma is a disease of the elderly. Typically, osteolytic lesions arise in the long tubular bones and the axial skeleton—osteoblastic lesions are rare. An early radiographic sign is erosion of the cortical

bone from the within the marrow space (Fig. 8.19). If the cortex is permeated by the tumor, a large soft tissue component may develop. In the axial skeleton the bone structure may turn very coarse in diffuse disease. Multiple myeloma is primarily diagnosed on the basis of laboratory parameters. Its extent and the course of the disease as well as the fracture risk are well documented in an elaborate series of radiographs of the axial skeleton and the proximal extremities. MR is more sensitive than radiography in detection of disseminated disease foci; its success is mostly based on the ability to image bone marrow displacement due to the disease and bone marrow edema. Bone scans are not indicated in myeloma because they may fail to demonstrate the sites of involvement in a large number of patients.

Some other, nonneoplastic diseases also have to be considered by Giufeng:

**Osteopoikilosis:** This is a benign, asymptomatic disease that features multiple small sclerotic bone lesions, mainly in the pelvis (Fig. 8.20) and the tubular bones. Bone scans show no abnormality in osteopoikilosis.

**Paget disease:** Paget disease (syn.: osteitis deformans) is a regional disease of the skeleton in the elderly. Its pathogenesis remains obscure. It is quite frequent in the British Isles, is seen in up to 10% of those above 80 years old in Central Europe and North America, and is almost unknown in China. The altered bone is enlarged; its texture becomes rather coarse and fibrous (“woven bone,” Fig. 8.21). Cortical thickening is a prominent feature often associated with the sclerotic phase of the disease. Despite the apparent increase of cortical thickness, the overall stability of the bone decreases because the new bone is of

### Osteopoikilosis

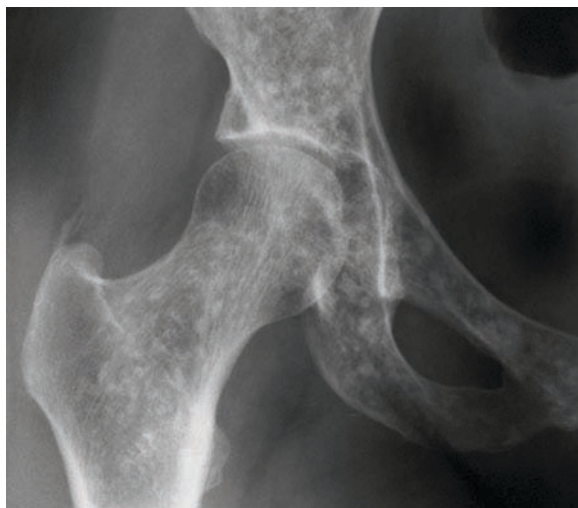


Fig. 8.20 The very rare osteopoikilosis features many small bone islands within the cancellous bone.



## Paget Disease

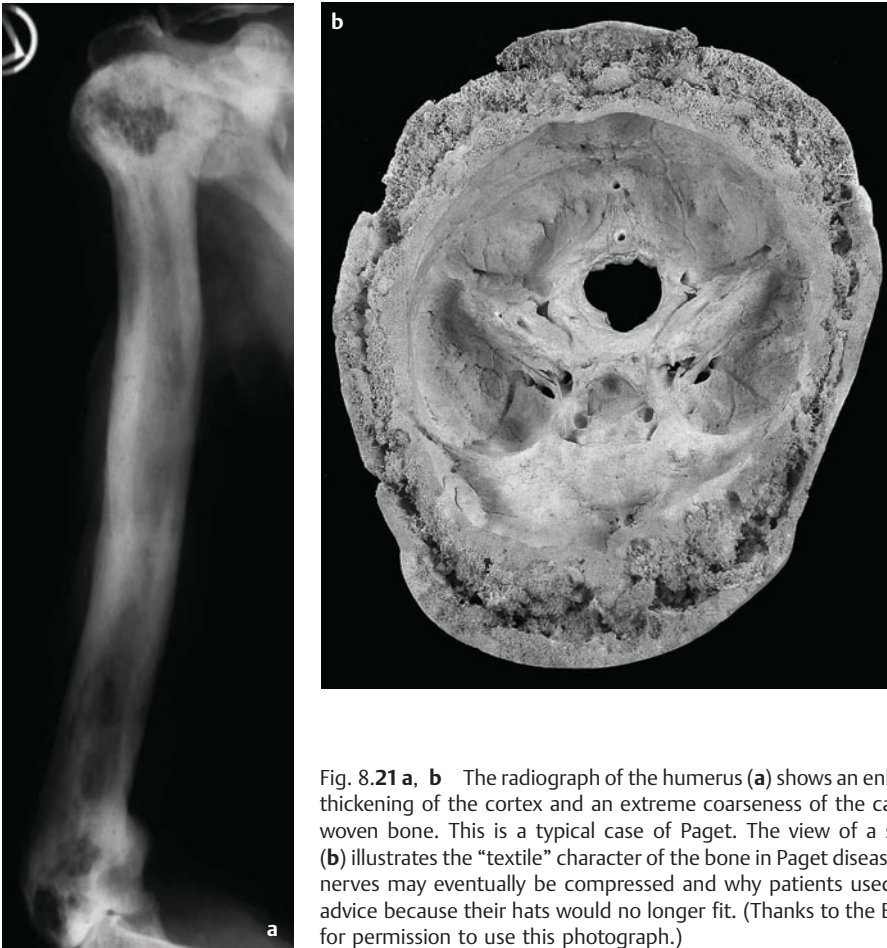


Fig. 8.21 **a, b** The radiograph of the humerus (**a**) shows an enlargement of the whole bone with thickening of the cortex and an extreme coarseness of the cancellous bone pattern—so-called woven bone. This is a typical case of Paget. The view of a skull base specimen from above (**b**) illustrates the “textile” character of the bone in Paget disease and makes clear why the cranial nerves may eventually be compressed and why patients used to come to their physicians for advice because their hats would no longer fit. (Thanks to the Berlin Museum of Medical History for permission to use this photograph.)

inferior quality. Patients therefore are often afflicted with fractures and bending of the bone. In the early phase of the disease, osteolytic foci occur and the disease may have a rather aggressive plain radiographic appearance. The risk of a malignant transformation into an osteosarcoma is around 5%; this diagnosis should be suspected if patients develop pain in the absence of evidence of a fracture. Bone scans show a very high bone turnover.



#### Do You Know about Paget?

Sir James Paget was a prominent surgeon and pathologist in London during the late 19th century. He was the personal medical attendant to Her Majesty Queen Victoria. Several disease entities have been named after him, the most frequent being the osteitis deformans. One of his most important mottos is still true today and you as a doctor should probably also follow it at least when you converse with colleagues: “To be brief is to be wise.”

**Brown tumor (osteoclastoma):** This phenomenon is associated with hyperthyroidism; it is an osteolytic lesion

(Fig. 8.22) that occasionally expands the bone. It owes its name to the hemosiderin content visible macroscopically when dissected by the pathologist. Laboratory parameters and the other radiological signs of hyperparathyroidism (see p. 36) can help in the differentiation from malignant osteolytic lesions.

→ **Diagnosis:** Giufeng is quite sure she knows what is going on. Mrs. Kristeeze suffers from osteoblastic metastases. The most probable primary tumor is a breast carcinoma. Now it is important to get a tissue sample of that primary tumor. First of all, the referring physician, who knows the patient best, is contacted and the further steps are agreed upon. Whether and how you inform the patient about a devastating condition depends on a lot of factors. If you decide to talk to your patient about such a diagnosis with far-reaching consequences, time, compassion, and a solid helping of empathy are needed. Giufeng has a look in the waiting area. Mrs. Kristeeze is completely absorbed by the latest book by Patricia Highsmith. Her personal doctor will tell her the diagnosis and guide her through the coming difficult times.

### Brown Tumor

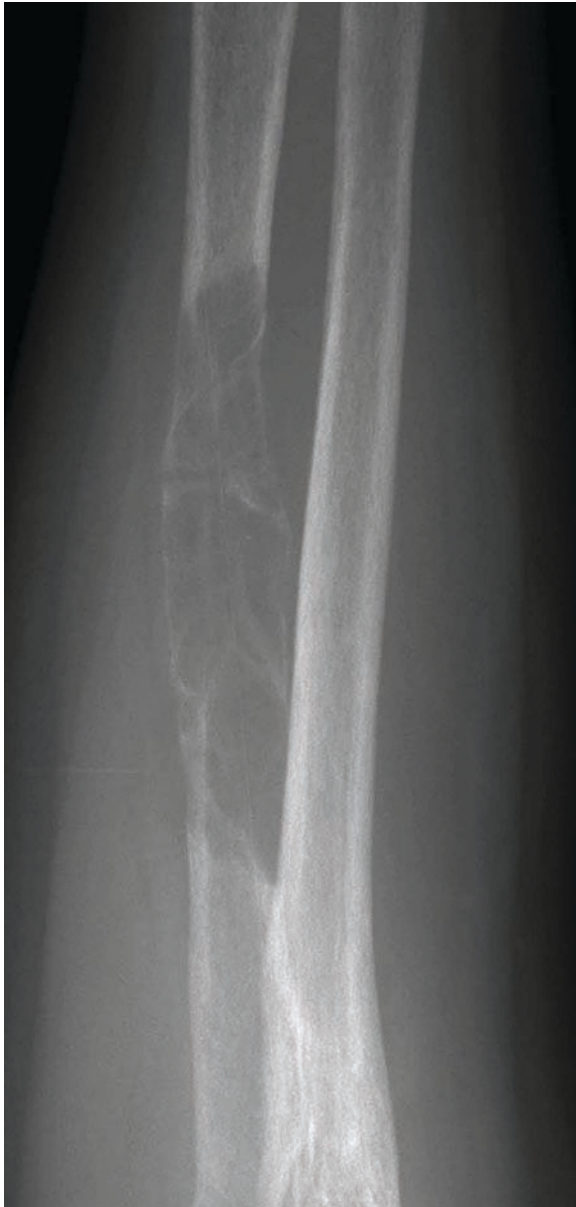

Fig. 8.22 An extensive osteolytic focus is seen in the diaphysis of the radius of this patient with hyperparathyroidism.

**!** The more consequential a diagnosis is for the patient, the more carefully must the breaking of the news to the patient be prepared. It is generally the referring physician who knows the patient best and who should cautiously inform, explain, and support. A mature and responsible patient must, however, also be treated as such by the radiologist.

### Generalized Bone Diseases

#### Checklist: Generalized Bone Diseases

- Is the bone density increased or decreased?
- Are the trabeculae of the cancellous bone unsharp, sharp, or coarsened?
- Is the bone already fractured?
- Are there osseous defects?

#### Little Old Lady

Hetty Vord's (72) golf handicap has recently deteriorated. She has noticed that her swing has changed: in order not to hit the ground she must grab the club a little lower. The pain in her back has also increased. Her 27-year-old grandson—a psychiatrist in training—has told her that she is shrinking. She told him to mind his own business and to stop growing himself. It is because of her pain that she has now come for a radiograph of the lumbar spine. Paul and Ajay look at the radiograph together (Fig. 8.23).

#### The Case of Hetty Vord

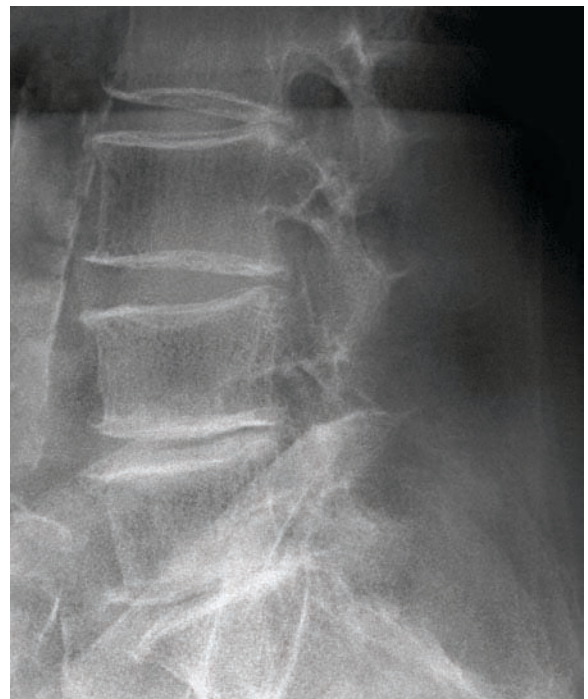

Fig. 8.23 Can you call the diagnosis on the basis of these lumbar spine films of Mrs. Vord?

### → What is Your Diagnosis?

**Osteoporosis:** If the normal continuous formation and breakdown of the bone derails in such a fashion that the cancellous bone loses its density and stability to a greater degree than normal for that age, fractures may occur spontaneously or after minor trauma. Such a degree of demineralization of bone is termed osteoporosis. Bone density is the highest around 35 years of age. After that it declines steadily; estrogen-depleted postmenopausal women are at a greater risk than men. The consequences of osteoporosis—pathological fractures and vertebral height loss due to progressive collapse—lead to the typical loss of body height and stature (the famous/infamous “little old lady”). Another major complication is, of course, the femoral neck fracture. Standard radiographs of the thoracic and lumbar spine show the osteoporosis best. The density of the vertebral bodies is decreased; the vertebral end plates therefore appear enhanced. If the vertebral end plates fracture, the typical “fish vertebra” sign of the vertebral body results (Fig. 8.24a, b). Serial measurements of the attenuation of an x-ray beam sent through the lumbar spine and femoral neck can establish the actual bone mineral density and estimate the risk of fracture (*dual-energy x-ray absorptiometry*, DXA; see Fig. 8.26). This helps stratify patients into groups of those in whom treatment may be beneficial and those who do not need any specific therapy. Bone mineral density measurement can also be used to monitor the effect of therapy. A specific interventional procedure

has been developed recently for this problem: percutaneous injection of methylmethacrylate (a kind of superglue) into the vertebral body stabilizes the affected vertebra and also treats the pain (Fig. 8.24c).

**Metastases, multiple myeloma:** Metastases and vertebral destructions due to multiple myeloma can become symptomatic with back pain, loss of vertebral body height, nerve root compression syndromes, and paraplegia. Owing to the large bone mass, destructions in the vertebral bodies are easily overlooked. It is therefore important to inspect the pedicles and the spinous processes with great care where smaller destructions are more evident (Fig. 8.25). The soft tissue component and abnormal bone marrow signal in vertebral bodies are best documented by MRI.

→ **Diagnosis:** Paul and Ajay are quite relieved that in Mrs. Vord's case osteoporosis is their final and certain diagnosis. To verify the diagnosis and monitor any medical therapy, they suggest a bone densitometry either by quantitative CT or DXA (Fig. 8.26). These methods are also used for the early diagnosis of osteoporosis. If the pain becomes too severe or does not respond to conservative treatment, they suggest a vertebroplasty. Mrs. Vord takes a deep breath when learning the results of the study. She will try to manage without vertebroplasty for now. “Should I get a completely new set of clubs?” she asks. “My grandpa has an adjustable one. That might help!” says Ajay.

## Osteoporosis

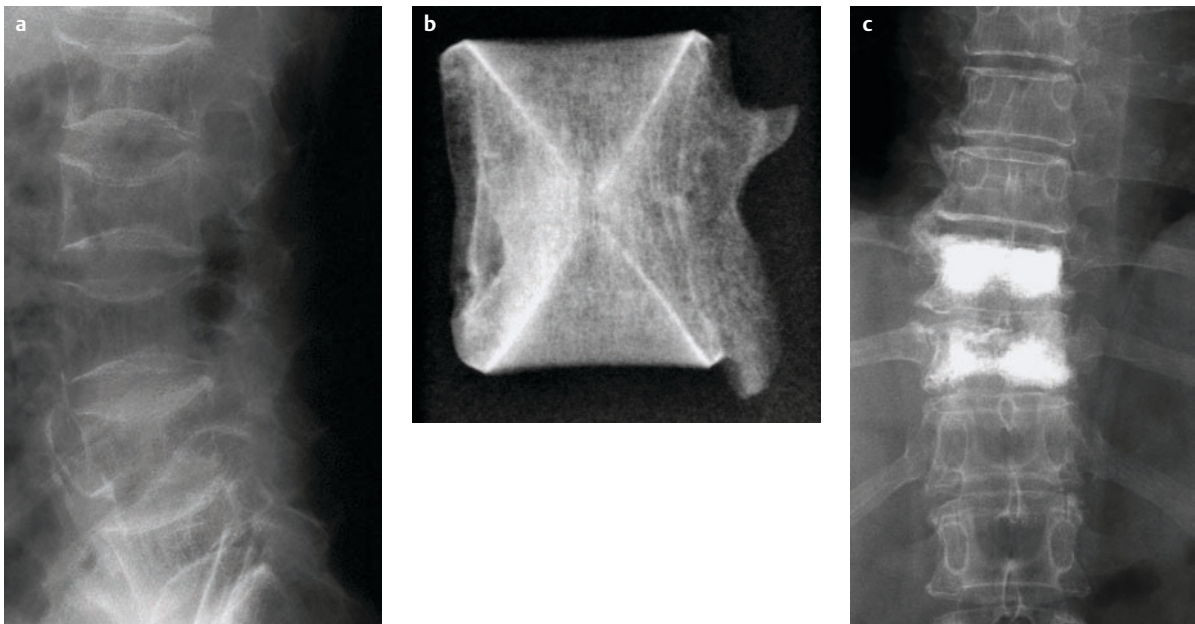
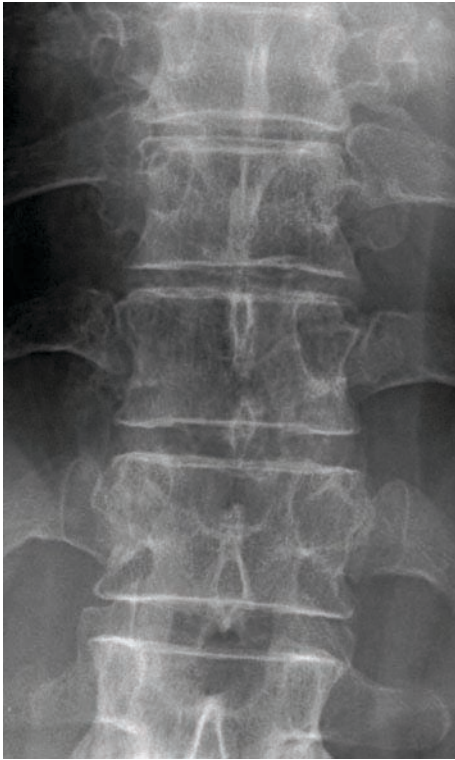

Fig. 8.24 **a** All vertebral bodies are decreased in density—their internal trabecular structure is very coarse. Lower and upper end plates are fractured, resulting in the typical fish vertebra configuration. **b** This is a real vertebral body of a fish (Whitsunday Islands, summer of 2004). **c** During a vertebroplasty, a cannula is

advanced into the vertebral body through the pedicle and a stabilizing methylmethacrylate compound is injected. Careful placement is key: high temperatures are reached as the material hardens, which is why nerve roots and of course the spinal cord should be separated from the material by intact bone.



## Metastases



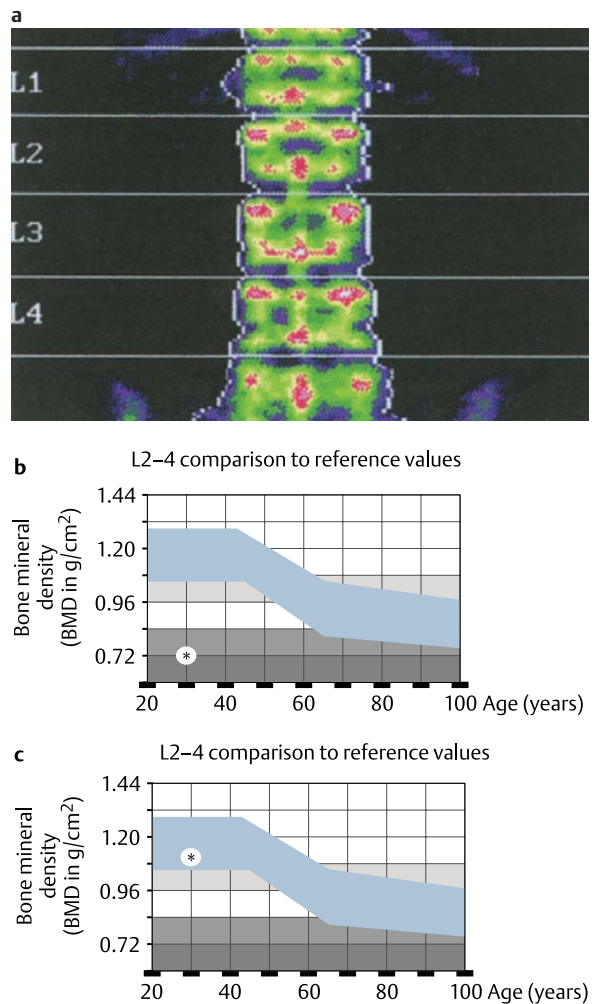
**Fig. 8.25** This is a radiograph of the thoracolumbar spine. The first lumbar vertebra is recognized by the fact that no ribs originate from it. First analyze all the dorsal spinous processes on this film. Are all of them present? Now go ahead and follow the upper and lower end plates as well as the lateral contours of all the bodies. Are they complete? Finally check out the pedicles. The T11 pedicle on the right is gone, the pedicle of T12 is denser than the others. The T11 abnormality is most likely due to an osteolytic metastasis. The T12 lesion could be an osteoblastic metastasis. The patient had a breast carcinoma.

! Try to see in your mind's eye a three-dimensional model of the vertebral body you analyse on the radiograph. Only now can you determine whether it is complete or partially destroyed. Especially with air and intestinal content overlying the bone, large osteolytic lesions may be overlooked or overstated. The correlation with the bone scan (exception: myeloma) is therefore helpful in many cases. If doubts persist and if therapy depends on the outcome, CT and MR are the next steps.

## The Complicated Case

Meanwhile, Giufeng and Hannah face another completely different patient. Hugo Blackbottom (45) knows the hospitals and the doctors "inside out" as he says. He does not want to tell his history—"You are the studied folks, ain't ya?" he grumbles. Yes, he has got pain all over and where can he go for a smoke? Both

## Bone Densitometry



**Fig. 8.26 a** This young lady was referred by a colleague from endocrinology. Bone densitometry was performed with dual-energy x-ray-absorptiometry (DXA) equipment. With this modality the lumbar spine is scanned with a narrow x-ray beam twice, first with a higher and subsequently with a lower energy spectrum. The difference after subtraction of the collected attenuation values correlates with the absorption of the osseous substance. **b** The blue band running from left to right documents the variance and the change over time of the normal bone density in the different sex-matched age groups. The asterisk indicates the age and the bone density of this patient. The density in this case is clearly below normal. **c** After one year of therapy, the bone density has reached normal levels.

women retreat to their light box and examine Blackbottom's radiographs closely (Fig. 8.27). They want to have an unbiased first look before they call up the referring colleague for more background information. The bone structure seems to be altered. A long-standing chronic process seems to be the problem.



### The Case of Hugo Blackbottom

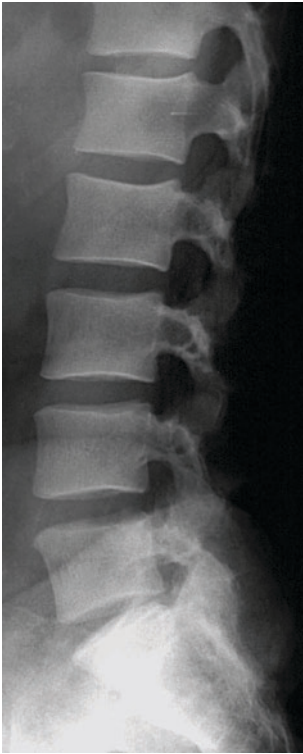

Fig. 8.27 This is the lumbar spine radiograph of Mr. Blackbottom. Can you help Giufeng and Hannah?

#### → What is Your Diagnosis?

**Osteomalacia:** In osteomalacia the bone matrix is preserved but is mineralized to a lesser degree. This occurs particularly in disturbances of the vitamin D, calcium, and phosphate metabolism, such as in secondary hyperparathyroidism due to chronic renal insufficiency (renal osteopathy). Radiologically, the cancellous texture appears washed out (Fig. 8.28a). Frequent microfractures are stabilized by ongoing periosteal new bone formation (so called “Looser zones,” Fig. 8.28b). The earliest and specific radiological signs of *hyperparathyroidism* are the coarse lamellation of the phalangeal cortex (Fig. 8.29a) and subperiosteal bone resorption. Acro-osteolyses of the finger tips may develop. In later phases a “rugger-jersey” spine may result (Fig. 8.29b) with sclerosed bone seen along the superior and inferior end plates of the affected vertebral bodies.

**Congenital diseases of the bone** often present with typical radiological signs. In osteogenesis imperfecta—a genetic disease that is due to a defect in collagen production—the bones are extremely fragile and poorly mineralized (Fig. 8.30a, b). Deformations and fractures are frequent. Osteosclerosis is a very rare entity in which the mineral content of the bone is greatly increased. It can be due to increased osteoblastic activity, subnormal osteoclastic

### Osteomalacia

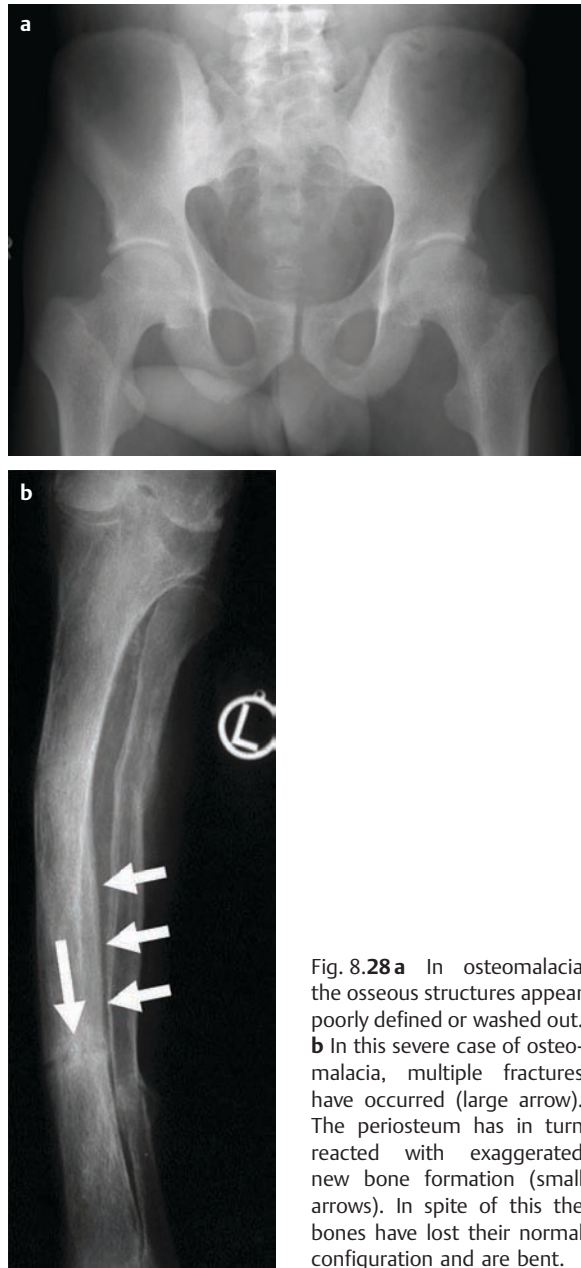


Fig. 8.28 a In osteomalacia the osseous structures appear poorly defined or washed out. b In this severe case of osteomalacia, multiple fractures have occurred (large arrow). The periosteum has in turn reacted with exaggerated new bone formation (small arrows). In spite of this the bones have lost their normal configuration and are bent.

activity, or enhanced mineralization of the bone matrix. In *osteopetrosis* or “marble bone disease” (Fig. 8.30c), a congenital form of osteosclerosis, the complete marrow space of the skeleton may obliterate (with corresponding devastating consequences for erythropoiesis). *Camurati-Engelmann disease* is also a congenital form of osteosclerosis that is detected early owing to the waddling gait of the children. The sclerotic but weakened bone bends and the central nerve foramina at the skull base taper with time (Fig. 8.30d), with subsequent blindness and deafness.

## Hyperparathyroidism

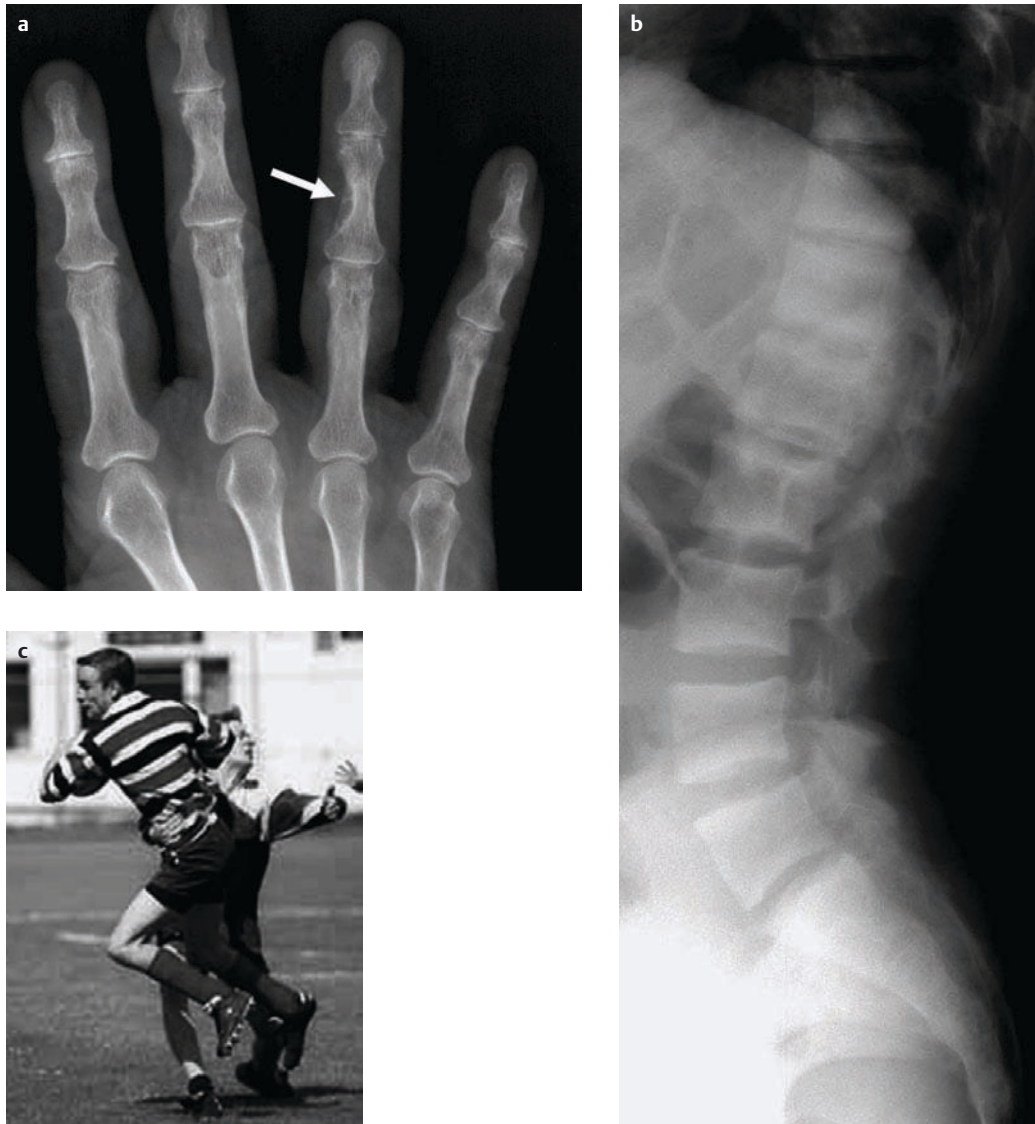

Fig. 8.29 **a** Bone resorption along the phalanges and the delamination of the cortex point in the direction of a hyperparathyroidism. This is particularly well seen in the mid-phalanx of the fourth finger (arrow). **b** This spine shows the characteristic “rugger-jersey” pattern—harking back to the times when

rugby players and football players wore horizontally striped shirts instead of walking round as living billboards. The vertebrae show sclerotic bands along the upper and lower end plates. **c** See a typical rugger player doing his thing.

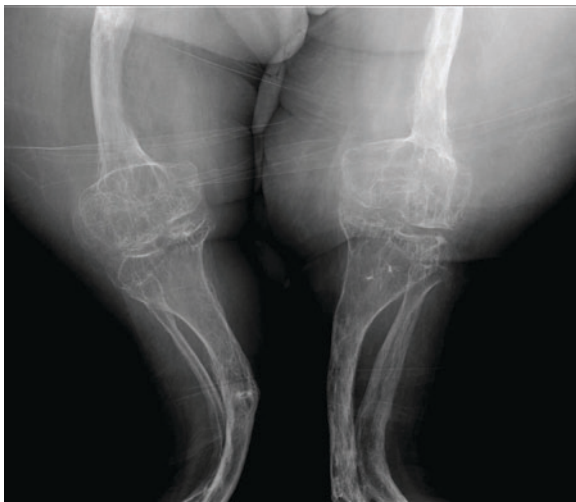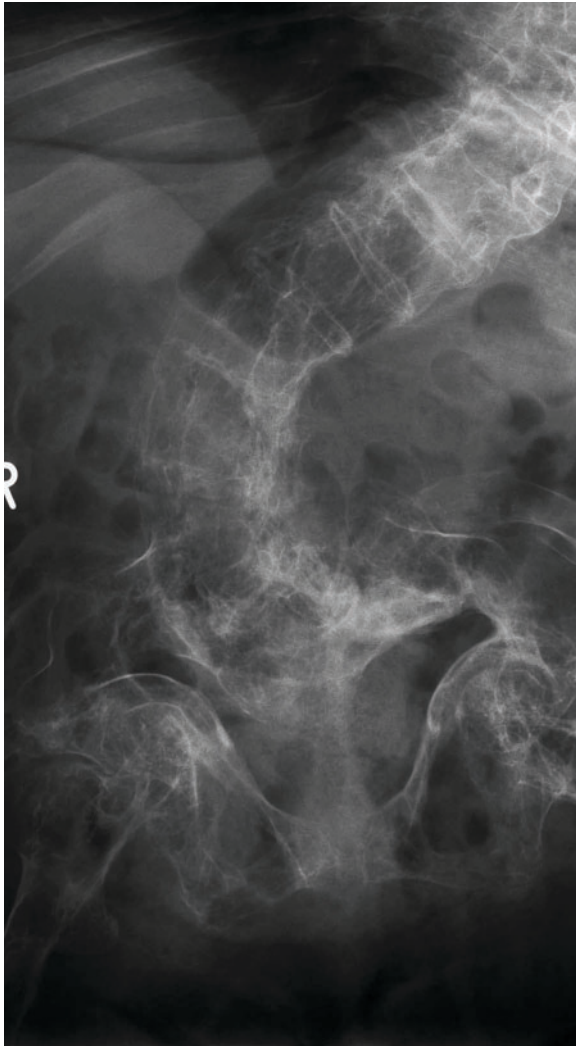
**Hypertrophic osteoarthropathy:** This entity (syn.: Pierre-Marie–Bamberger disease) manifests itself as a periosteal new bone formation, particularly of the lower extremities (Fig. 8.31). It is frequently associated with a pulmonary disease (fibrosis, tumor). For that reason, a glance at the fingers (drumstick or clubbed fingers) and the chest radiograph is helpful in most cases.

→ **Diagnosis:** Hannah and Giufeng find the bone structure a little diffuse and washed out. Their suspicion is

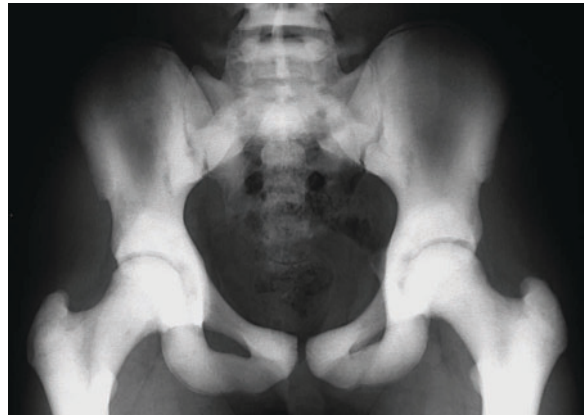supported by the information they get when talking to the referring colleague. Mr. Blackbottom has been on dialysis for renal insufficiency for years. His renal osteopathy has long been known. After having puffed his cigarette he is a little more pleasant than before, even friendly, and tells the two students a story or two out of his long and exhausting career as a renal patient. “You gals are alright,” he mumbles finally, grabs the plastic supermarket bag containing his very own roentgen archive, and shuffles away.

### Congenital Bone Diseases

a, b Osteogenesis imperfecta



c Osteopetrosis



d Camurati-Engelmann-disease

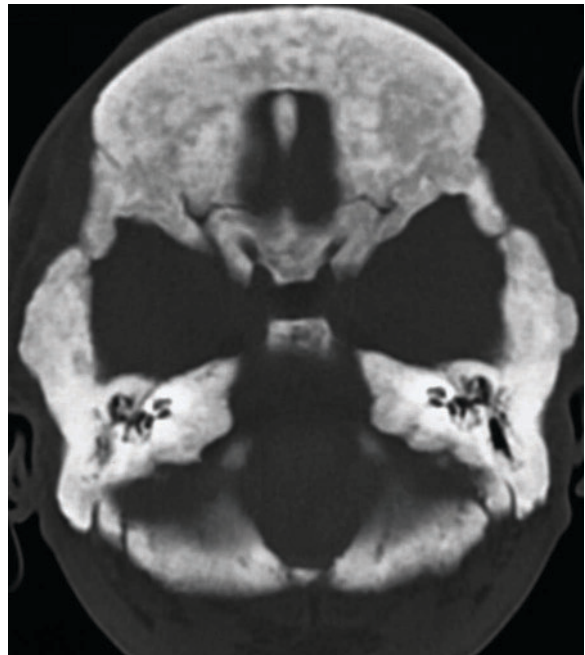
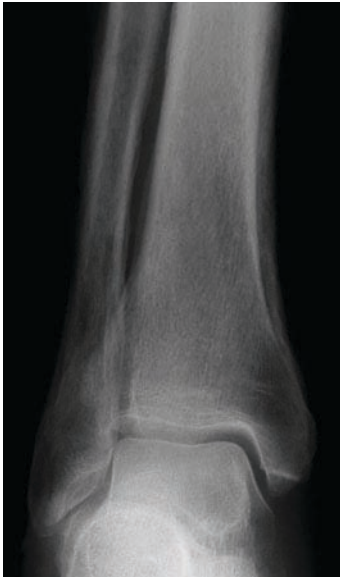

Fig. 8.30 **a, b** Observe the severely decreased bone density and the deformation of the bones in osteogenesis imperfecta. Scoliosis and short stature result. **c** In osteopetrosis the whole bone is increased in density. **d** Camurati-Engelmann disease is characterized by an obliteration of the cancellous bone and an expansion of the bone. This sectional CT of the skull base at the level of the sella shows the stenosis of both optical canals (arrows). The patient was already blind on one side.

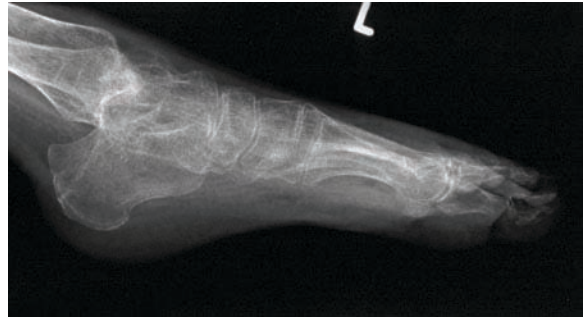

### Hypertrophic Osteoarthropathy



**Fig. 8.31** A thick stripe of periosteal new bone formation is visible along the cortex of the tibia and also the fibula. This is reason enough for a smart radiologist to start a diagnostic work-up for pulmonary disease, which would prove that the initial finding in the tibia was indeed hypertrophic osteoarthropathy. Severe venous insufficiency and burn injury of a limb can also set off this kind of periosteal reaction.

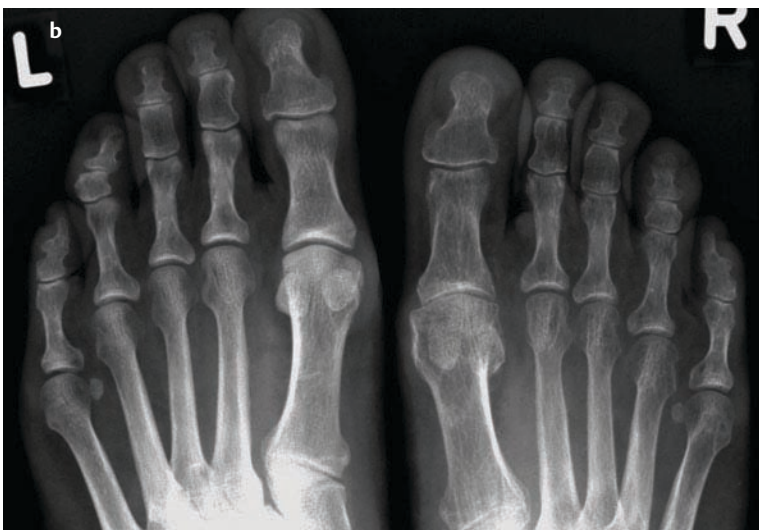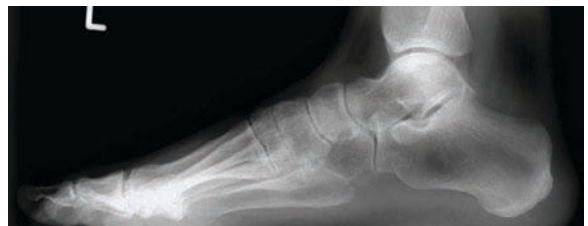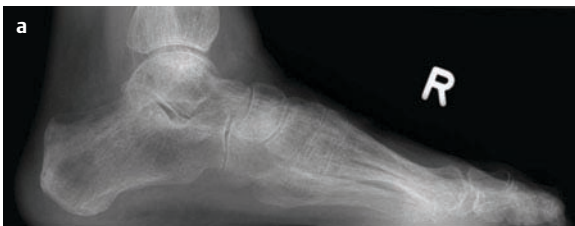
### The Case of Hikka Meckinen



**Fig. 8.32** This radiograph shows the foot of Mr. Meckinen. Which disease entities do you have to consider?

**!** If we are finished with the image analysis and the clinical information of the referring colleagues is not sufficient, we go ahead and do what no one has dared to do before: We talk to the patient!

### Disuse Atrophy



**Fig. 8.33 a** This patient was immobilized for quite a while because of a fracture of the femoral shaft. The inactivity led to an atrophy of the immobilized bone. Radiographically, significantly decreased density and severely coarsened trabecular structure of the bone are seen (left). A view of the contralateral leg shows the normal appearance for comparison (right).

**b** Compare the osseous structure of the right and left feet. The bone density on the left is markedly decreased and the spongiosal structure is coarsened. There is no soft tissue swelling. This patient was immobilized for a very long time because of a complicated lower leg fracture.



## Sudeck Disease

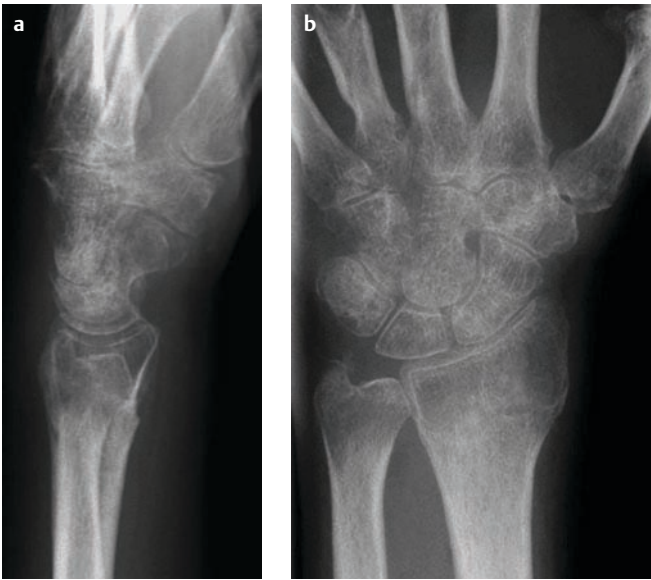


Fig. 8.34 This hand is severely demineralized owing to Sudeck disease. The swelling of the hand can be appreciated on the lateral view (a). In the anteroposterior radiograph (b) there is sharp demarcation of the demineralized bone from the more normal forearm at the level of the radiocarpal joint.

### Consequences of an Accident

Hikka Meckinen (35) found himself in the middle of a heap of tires after a pretty exciting and problem-riddled trial with a new race car a few months ago. He suffered a femoral shaft fracture that is all but completely healed now. His left foot, however, continues to worry him. It is swollen, warmer than his right foot, and painful. Joey and Paul analyze the radiograph of the foot (Fig. 8.32). They notice the diffuse demineralization of the foot skeleton. The soft tissues are not well enough appreciated on the radiograph.

#### → What is Your Diagnosis?

**Disuse atrophy:** Skeletal disuse atrophy, caused by the immobilization of an extremity after trauma or during space flight, is an often patchy periarticular loss of bone mineralization (Fig. 8.33a). It begins subchondrally. As the extremity is put to use again, the bone recovers its density. If the atrophy was so severe that the bone matrix was reduced, the ensuing remineralization appears coarser than normal (Fig. 8.33b) because the remaining trabeculae of the cancellous bone become thicker and denser.

**Sudeck disease:** Sudeck disease is caused by a malfunction of the autonomous nervous system after a trauma, or may be idiopathic. The diagnosis is made on the grounds of symptoms and clinical findings such as swelling and hyperthermia of the limb in question. It is verified radiologically by the demineralization of the bone (Fig. 8.34).

→ **Diagnosis:** Joey is quite sure of his diagnosis after having talked to the patient and having examined his foot: This is real Sudeck disease.

## 8.3 Diseases of the Spine

### Checklist: Diffuse Back Pain

- Is the general configuration of the spine intact?
- Is the alignment of the vertebral bodies normal?
- Are the intervertebral disk spaces normal?
- Are the vertebrae complete and symmetrical?
- Are there transitional vertebrae?
- Are the sacroiliac joints normal?

### It's the Backbone Over and Over Again

For years Will Walton (45) has been suffering from severe back pain that, off and on, has tied him to his bed for days in a row. As a self-employed truck driver, father of three, and builder of a new family home, he is looking for rapid relief. For the last three days now he has not been able to walk owing to the pain. Ajay and Paul review the radiographs of his lumbar spine (Fig. 8.35). Are there any visible signs of degeneration?

#### → What is Your Diagnosis?

**Osteochondrosis:** Osteochondrosis is the degenerative loss of height of the intervertebral disk, which ends in the destruction of the central disk and the formation of a central “gas” pocket (also called “vacuum phenomenon”). In addition, osseous protuberances—spondylophytes—are formed at the rims of the vertebral end plates; these may become very large and eventually bridge the intervertebral gap (Fig. 8.36). Degenerative osteophytes may also develop around the posterior facet joints. The

### The Case of Will Walton

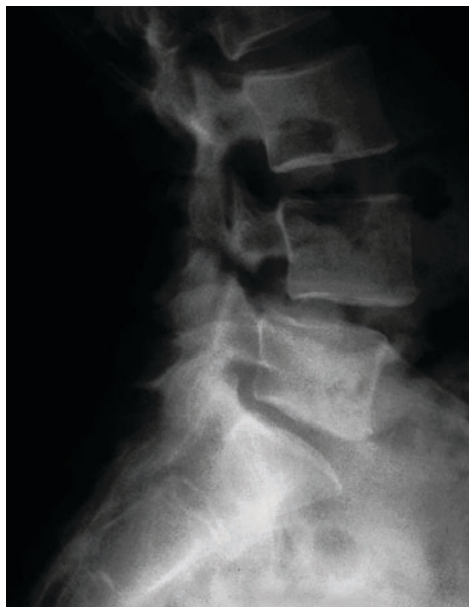

Fig. 8.35 Is there anything abnormal on this radiograph of Will Walton's lumbar spine?

combination of spondylophytes, osteophytes, and the loss of disk height may narrow the neuroforamina and eventually cause nerve compression syndromes.



#### Vacuum in the Body?

The vacuum phenomenon is quite reliable when degenerative changes of the disk space need to be differentiated from infectious ones.

But is it really a vacuum? Some researchers have sampled diskal “vacuums” with needles and reported a high content of nitrogen. See Figure 8.36b and c for proof that some sort of biomechanical phenomenon is at work: In **b** the spine is flexed forward—no pocket is seen. As the spine is flexed backward in **c**, the pocket appears out of nowhere.

**Intervertebral joint osteoarthritis:** Intervertebral or facet joint osteoarthritis can cause a narrowing of the spinal canal and the neuroforamina. As the integrity of the joints decreases, intervertebral misalignment may ensue that further encroaches on the spinal canal and the foramina—the so called pseudospondylolisthesis or degenerative spondylolisthesis (Fig. 8.37).

### Osteochondrosis

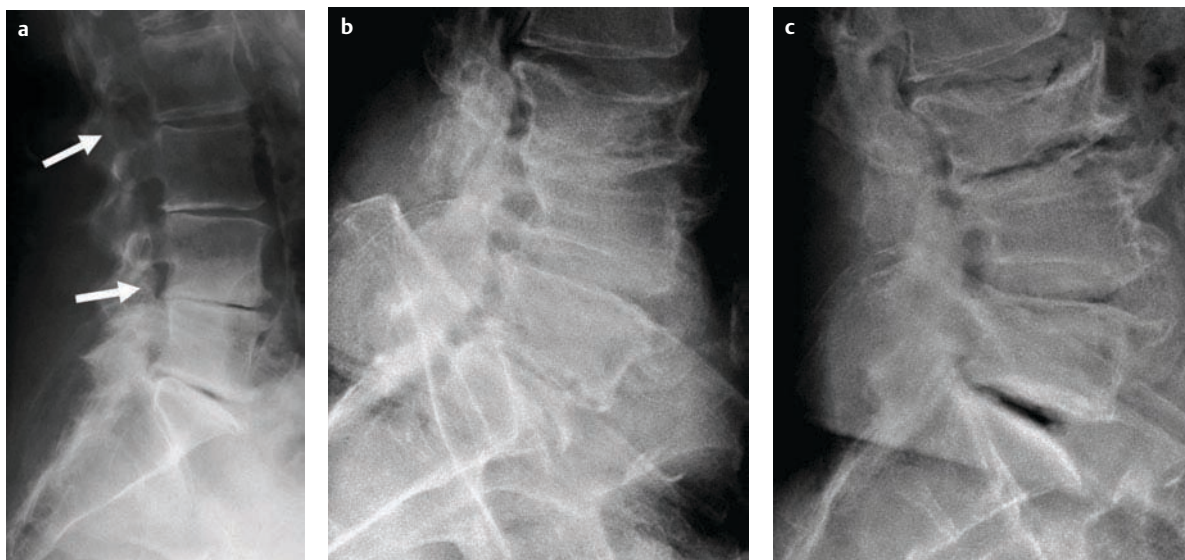
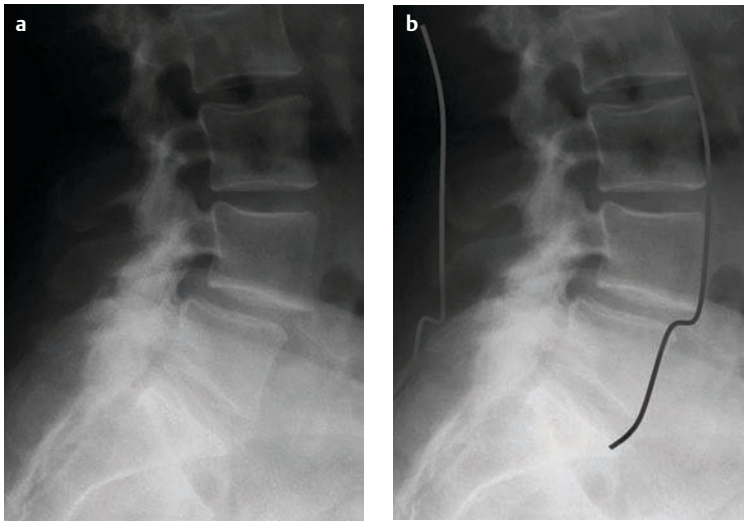


Fig. 8.36 a–c The lower lumbar spine (a) is affected by extensive degenerative disk disease and associated typical osseous changes. The uppermost visible intervertebral disk has normal height—all others are reduced in height. The disks are all but destroyed. Dark stripes are seen within the residual disk. This “vacuum phenomenon” is a sure indication of a degenerative process. The vertebral end plates are sclerotic. Their margins show osseous protuberances—spondylophytes. The deterioration of the disk decreases the strength of the spinal architecture,

leading to malalignments such as seen at the L5/S1 level on this radiograph. Note how the loss of disk height also diminishes the size of the neuroforamina (arrows). The foramen has a normal diameter at the L2/L3 level but at the L5/S1 level it is much smaller. A nerve root must squeeze through there! Functional radiographs of the lumbar spine bent forward (b) and backward (c) performed within seconds of each other prove that the phenomenon is indeed due to vacuum: the stripes develop out of nothing in (c).

### Intervertebral Joint Osteoarthritis



**Fig. 8.37 a** This misalignment at the L4/L5 level is caused by degenerative disk disease and degenerative changes in the posterior elements of the spine, the intervertebral joints. Because it is not due to a defect of the pars interarticularis of the vertebral body, it is also called pseudospondylolisthesis or degenerative spondylolisthesis by some. The whole L4 vertebral body including the spinous process and the body itself has moved ventrally relative to L5. **b** If you draw one line along the anterior margins of the vertebral bodies and another one along the spinous processes, it becomes clear that the displacement concerns the whole vertebral body—quite the opposite to what one can see in true spondylolisthesis associated with spondylolysis (see Fig. 8.43a).

**Spinal canal stenosis:** A stenosis of the spinal canal (Fig. 8.38) can cause diffuse back pain. It is verified by CT or MR.

**Scoliosis:** In scoliosis—a curvature of the spine in the form of an S that may also include a rotational component (Fig. 8.39)—altered biomechanics of the spine lead to accelerated degeneration of the intervertebral disks. (By the way, which other relevant finding is present on this radiograph?)

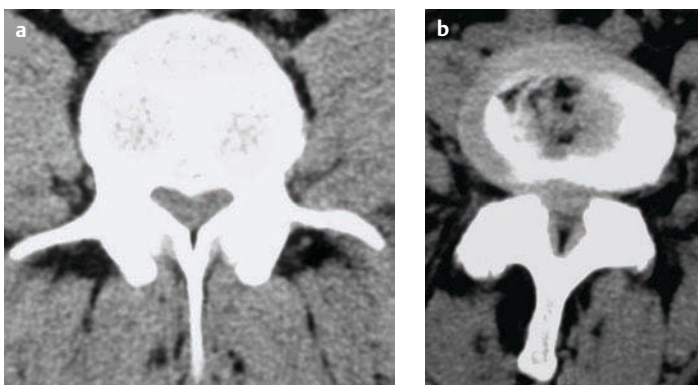
**Intervertebral disk prolapse:** A circumscribed disk prolapse can cause diffuse back pain. The standard lumbar radiograph may, however, be entirely normal in these cases (Fig. 8.40a). A CT (Fig. 8.40b) or MRI is indispensable to substantiate the diagnosis, the latter representing the current gold-standard for spinal imaging.

**Spondylodiskitis:** This entity is an acute inflammation of the disk space that was frequently caused by mycobac-

terial infection (tuberculosis) in the past but that may be due to a large number of different bacteria nowadays, with *Staphylococcus aureus* taking the lead. The disk literally melts away in this condition and the neighboring vertebral end plates are also destroyed (Fig. 8.41). Sometimes the differentiation from degenerative disease is not trivial, but a vacuum phenomenon excludes an inflammatory nature for all practical purposes.

To verify diskitis and to establish the extent and spread of the disease preoperatively, MRI is obligatory because it also shows the frequent perivertebral abscesses, especially in the spinal canal (Fig. 8.42a, b). Imaging should include MR sequences without and with intravenous contrast administration and fat suppression. If abscesses form outside the spinal canal, they can descend along the rim of the psoas muscle and reach down into the inguinal region. If percutaneous drainage is necessary, it is often performed under CT guidance (Fig. 8.42c).

### Spinal Canal Stenosis



**Fig. 8.38 a** You are looking at an axial CT image through a lower lumbar vertebral body. The spinal canal is severely stenosed by the bone itself—there is no sign of degeneration. This spinal canal stenosis is congenital in nature. Back problems are unavoidable and preprogrammed in these patients. **b** The vacuum phenomenon in this disk is well seen as well as the hypertrophic degenerative change in the intervertebral joints and the thickening of the posterior longitudinal ligament (the ligament that forms the posterior border of the spinal canal). This spinal canal stenosis is acquired and is due to chronic degenerative change.



## Scoliosis

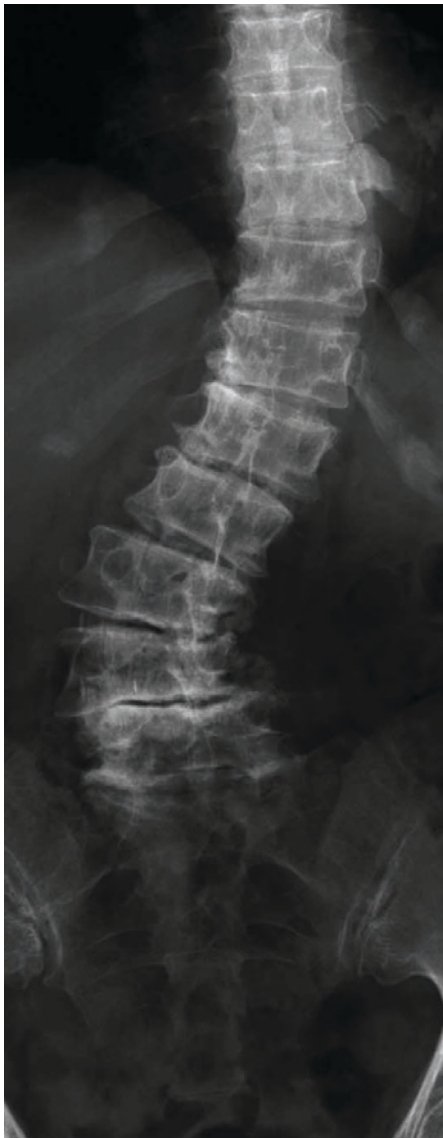

Fig. 8.39 Scoliosis results in uneven distribution of axial loading forces to the spine. Eccentric biomechanical stress of the intervertebral disks leads to accelerated degeneration, further increasing the deformity over time. Note the dislocation of L4 relative to L5! Now take a little time for the second relevant finding on this radiograph, which is independent of the scoliosis. Remember the “satisfaction of search” we talked about in Chapter 4.

Correct—some of the ribs shows osteoblastic lesions. These are metastases of a prostate carcinoma.

## Disk Prolapse

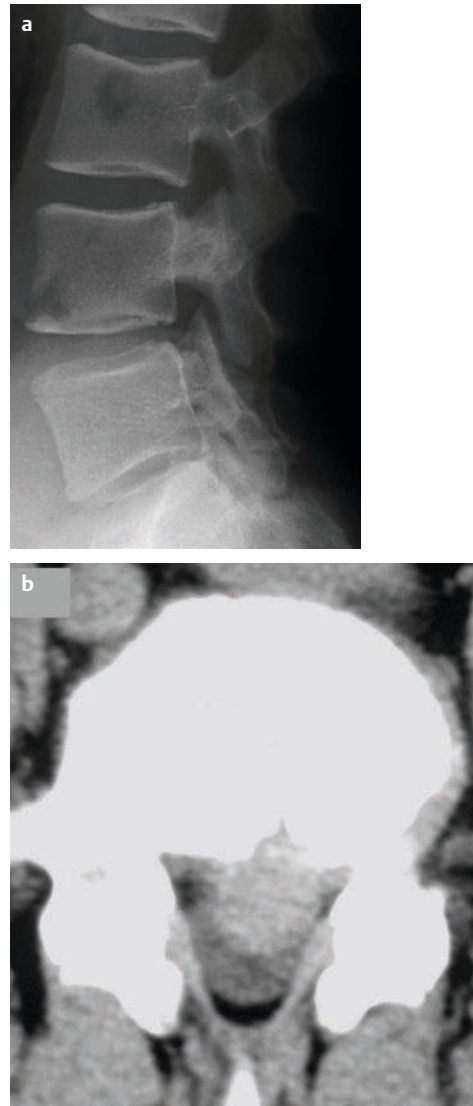


Fig. 8.40 **a** The lumbar spine film of this patient shows no abnormality. A disk herniation is evident on MRI. The increases in transparency in projection over the upper and middle vertebral body are due to intestinal gas. **b** This axial CT image demonstrates the massive posterior prolapse of disk material into the spinal canal. The thecal sac is compressed and along with it the cauda equina.



## Spondylodiskitis

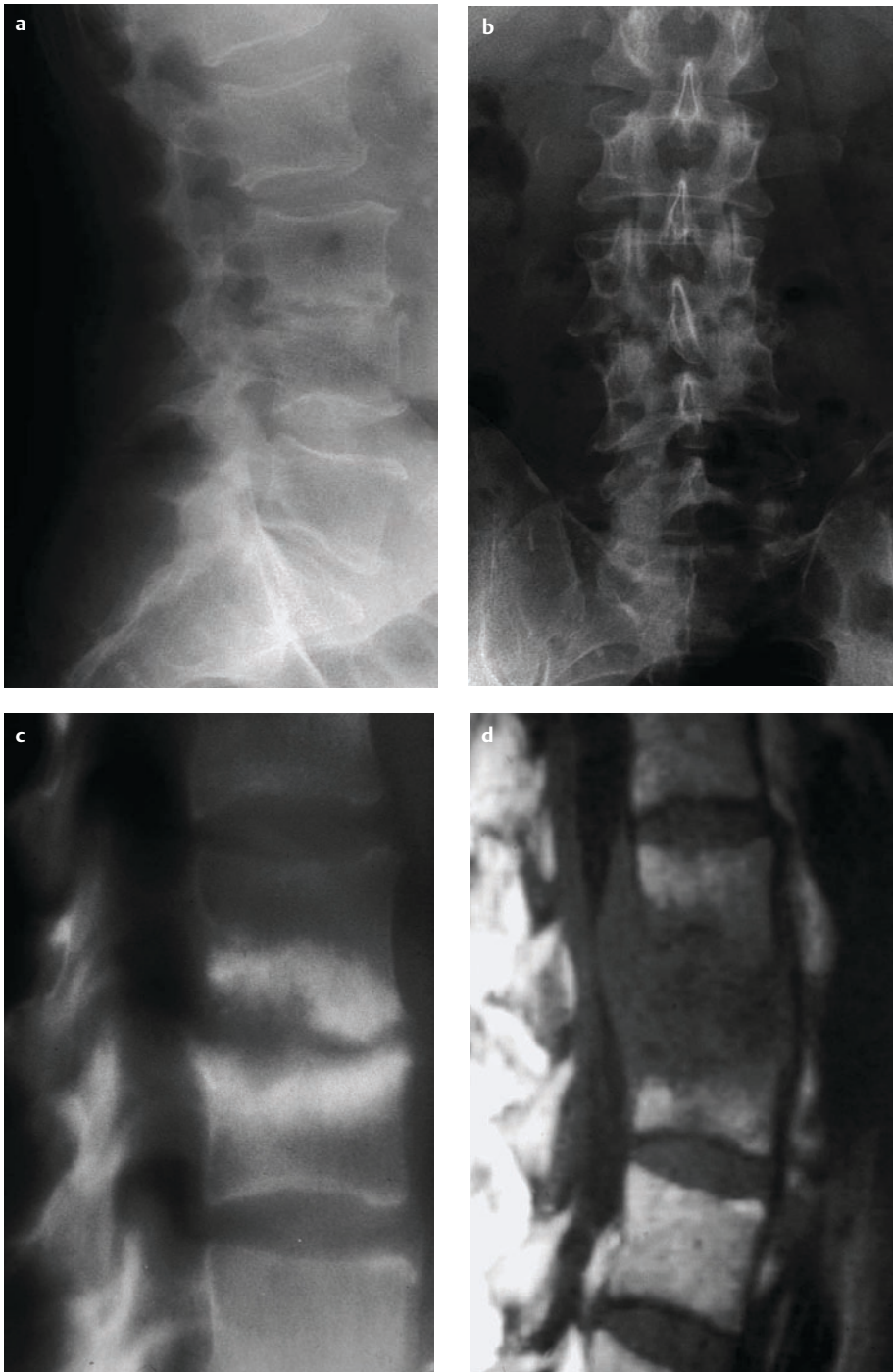
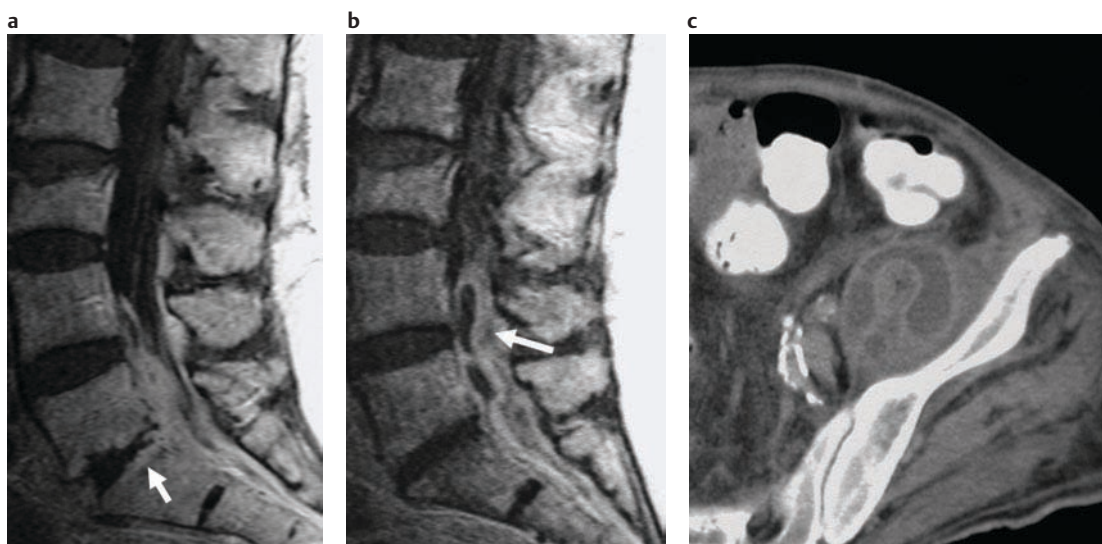


Fig. 8.41 **a** This radiograph shows the loss of definition of the vertebral body end plates adjacent to the intervertebral disk space L3/L4. This is a strong hint in the direction of infectious spondylodiskitis. **b** The process has also caused a misalignment of L3 relative to L4. The ligaments have become flaccid or are destroyed; the spinal architecture is disturbed. **c** This

conventional tomogram illustrates even better the destruction of the end plates. Conventional tomography has ceased to be a diagnostic tool in spondylodiskitis but, boy, does this one look good. **d** The MR image shows the extent of the infection into the spinal canal and into the bordering vertebral bodies. It is the modality of choice for this entity.

## Abscess Locations in Spondylodiskitis



**Fig. 8.42 a** This scan of the lower lumbar spine shows a sagittal image including vertebral bodies, disks, and the spinal canal. The signal of the spinal fluid tells you whether it is a T1-weighted or T2-weighted sequence (see Fig. 4.4a in Chapter 4). For better soft tissue delineation, intravenous contrast has been given. With the exception of the lowest level, all intervertebral disk spaces seem to be normal. At the L5/S1 level, contrast accumulates in the periphery of the disk space (arrow). **b** Spondylodiskitis may also be complicated by an epidural abscess. The fluid

content of the abscess appears dark on T1-weighted images and is surrounded by an enhancing abscess wall (arrow). **c** This CT image of the lateral pelvis shows a pocket of fluid along the iliopsoas muscle. The space was filled with pus from a spondylodiskitis at the L3/L4 level that had descended along the muscle in a typical fashion. The abscess was drained under CT guidance by the interventional radiologist and material for a microbiological analysis was sent to the microbiology laboratory.

**!** A suspected spondylodiskitis is one of the most important emergency indications of magnetic resonance imaging.

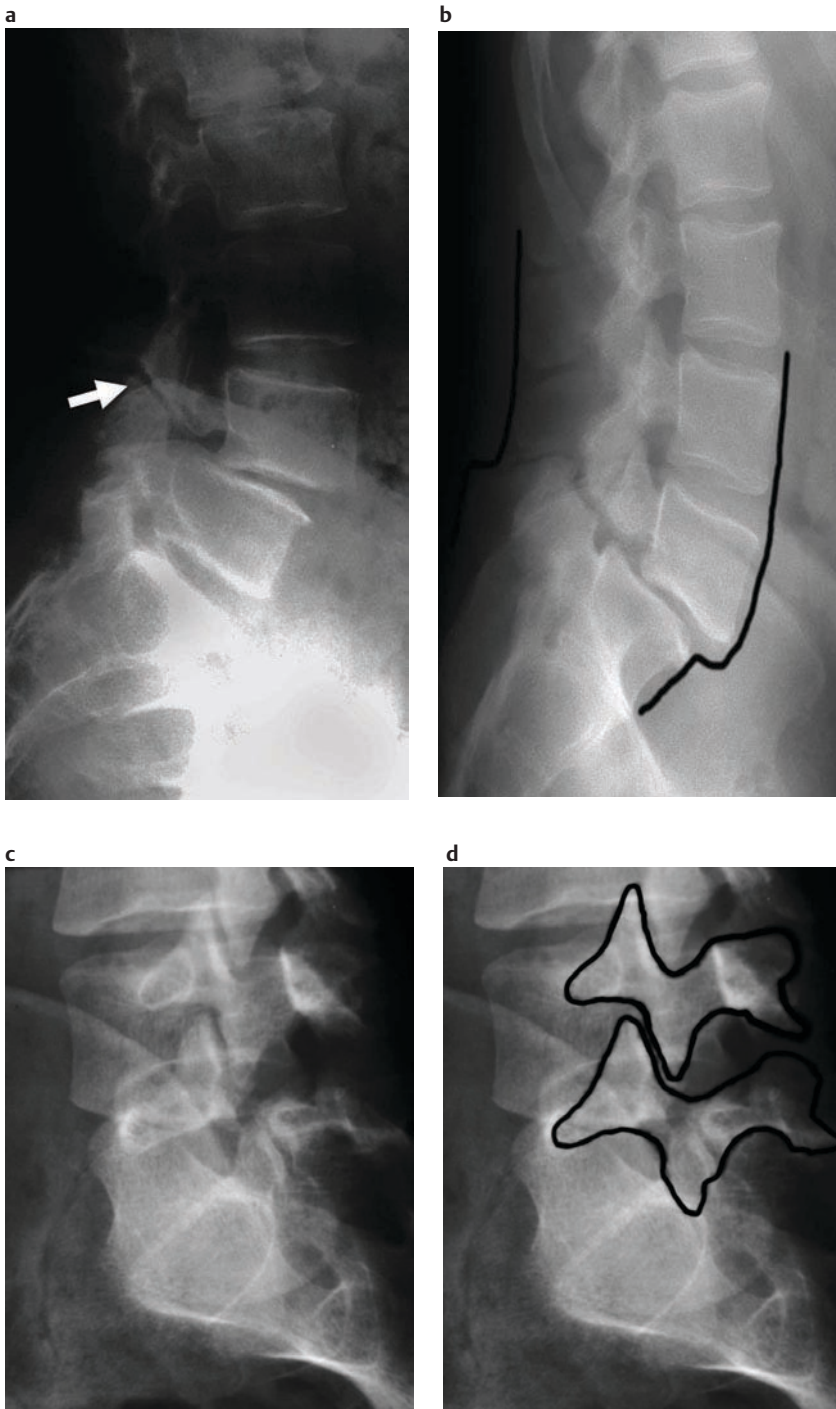
**Spondylolisthesis with spondylolysis (true spondylolisthesis) and without spondylolysis (pseudospondylolisthesis):** Spondylolisthesis is defined as the ventral slippage of a complete or partial vertebral body on the stationary vertebra underneath it. The so-called *true spondylolisthesis* is so frequent it could be called a natural variant (Fig. 8.43a, b). It is a complication of bilateral spondylolysis, which is a defect in the pars interarticularis of the vertebra, the osseous bridge between the upper and lower intervertebral facet. This pars may be dysplastic to start with and/or may fracture as a consequence of physical stress. It results in a division of the vertebra into an anterior part including the body and a dorsal part consisting of the lower intervertebral joint and the posterior arch. As the disk gives way under the increased strain, the vertebral body slips forward (just like a new ship slides into the water), leaving the separated arch and spinous process behind. Radiologically, spondylolysis is particularly well appreciated on oblique lumbar radiographs where the shape of a “Scottie dog” can be perceived (the head and ear of the dog is the upper intervertebral process, its body the lower intervertebral process). The defect in the pars interarticularis looks quite like the Scottie dog’s collar (Fig. 8.43c, d).

In *pseudospondylolisthesis* the slippage is due to degenerative changes of the intervertebral joints (see above) as the whole vertebra moves forward. The resulting misalignment certainly may stenose the lateral neuroforamina and the spinal canal. Neurological symptoms may develop as a consequence.

On lateral views of the spine, the extent of the vertebral slippage in both types of spondylolisthesis can be determined and classified according to Meyerding: The lower body’s end plate is divided into quarters—from I through IV starting dorsally. A Meyerding I through IV is assigned depending on the amount of slippage relative to the lower body. Flexion and extension views of the spine are useful to detect potential instabilities.

**Ankylosing spondylitis:** Ankylosing spondylitis or Bechterew disease is a seronegative spondylarthropathy, a member of the group of inflammatory arthropathies. The disease often occurs in conjunction with sacroiliitis (Fig. 8.44a). The ligaments—particularly those of the spine—may ossify, resulting in the famous “bamboo spine” appearance on plain radiography (Fig. 8.44b). The affected joints—such as the sacroiliac articulation—tend to fuse. The patients end up with a rigid axial skeleton, which can lead to dramatic spinal injuries after trivial trauma.

## True Spondylolisthesis (Spondylolysis)



**Fig. 8.43 a** This radiograph shows the slippage of L4 relative to L5 to good advantage. The listhesis is classified as a Meyerding grade I–II. The defect in the pars interarticularis is also well seen in this patient (arrow). **b** That is not always the case. Draw one line along the anterior margin of the vertebral bodies and another along the posterior edge of the spinous processes (compare degenerative spondylolisthesis, Fig. 8.37b). The lines prove

that the malalignment is one vertebral level higher posteriorly compared to ventrally—the spinous process and its vertebral body are disconnected. **c** On the oblique view, the silhouette of two “Scottie dogs” is visible. **d** In this case the upper dog runs around unrestrained while the lower dog wears a “leash”—the radiographic lucency that corresponds to the defect in the pars interarticularis of the affected vertebral body.



## Ankylosing Spondylitis

**a Sacroiliitis**

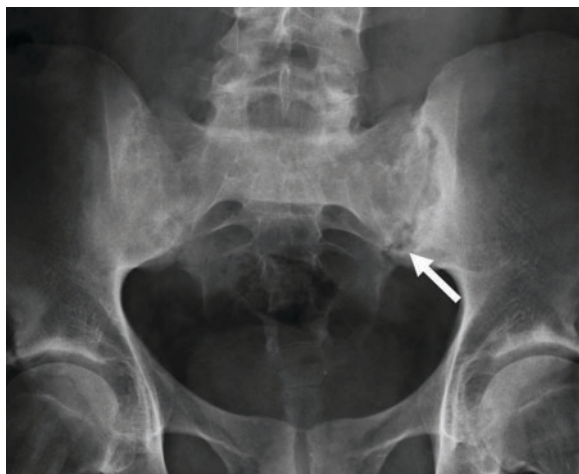
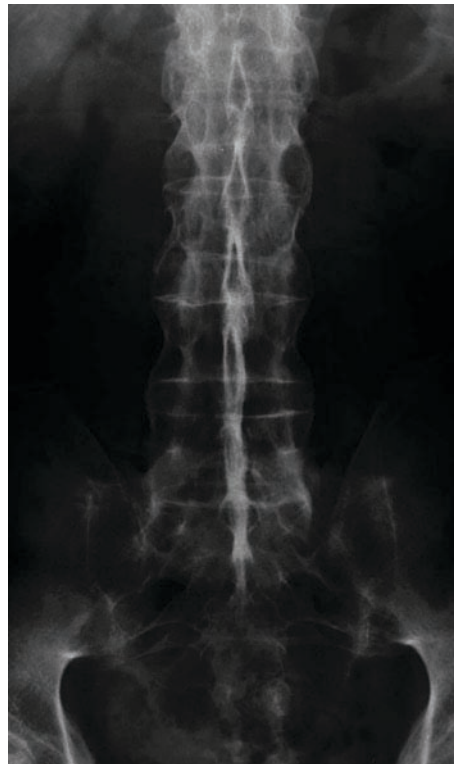
Fig. 8.44 **a** The right iliosacral joint is already fused in its lower part. The left iliosacral joint shows pronounced periarticular sclerosis along erosions of the bone (arrow). This is a rather typical pattern of ankylosing spondylitis. **b** In the final phase and with maximal expression of Bechterew disease (as ankylosing spondylitis is also called), the paraspinous ligaments become ossified, giving rise to the so-called “bamboo spine.” The intervertebral spaces are completely bridged by ossified tissue, which reduces the flexibility of the spine to nil. Any deceleration trauma may have dire consequences in this setting.

**b “Bamboo spine”**



### Did You Know That . . . ?

Wladimir von Bechterew was a neurologist and psychiatrist in St. Petersburg around 1900. His psychiatric ideas and models were highly speculative, but his neuroanatomical scientific work is relevant to this day. He was one of the first to comprehensively describe ankylosing spondylitis. One of his colleagues and major rivals in St. Petersburg was Ivan Pavlov, whose experiments we all know. In 1927 the leader of the Soviet Union, a certain Comrade Stalin, sought his medical advice. The 70-year-old Bechterew diagnosed a grave paranoia and did not hesitate to tell the dictator. Bechterew survived the diagnosis by a whole day.

→ **Diagnosis:** After analyzing the malalignment of Mr. Walton’s lumbar spine, both Paul and Ajay come to the same conclusion: there is an osseous defect in the pars interarticularis of L4. This is a true spondylolysis with associated spondylolisthesis and is the most likely explanation for the patient’s complaints.

Could an additional disk herniation have aggravated the situation? Of course. If there are nerve root symptoms and surgery is considered as an option, an additional MRI is indicated and could verify the disk herniation.

! The radiograph of the lumbar spine can allow diagnosis of osteochondrosis, malalignment, instability, spondylolysis and ankylosing spondylitis. It should always be the first imaging modality to be used in back pain.

## 8.4 Diseases of the Joints

### Checklist: Articular Pain

- Are the symptoms monoarticular or polyarticular?
- Are the joints in question weight-bearing and prone to degeneration?
- Is the configuration of the joint normal?
- Is the joint space narrowed? If so, only in the weight-bearing zone (eccentrically) or everywhere (concentrically)?
- Is the periarticular and subchondral bone increased or decreased in density?
- Are there any periarticular cysts?
- Is the soft tissue of normal appearance?
- Are there clinical signs of inflammation?



## Joints of the Upper Extremity

### When the Shoulder Goes on Strike

André Aklassi (32) has been troubled lately by shoulder pain that slowly ruins his serve. He needs a diagnosis and therapy rapidly because the season is in full thrust and the Australian Open is approaching. His wife accompanies him. Hannah is rather excited, while Joey, a baseball fanatic, could not care less. A standard radiograph of the shoulder has already been performed elsewhere and apparently showed no abnormal finding. The students go ahead and analyze the MR image of the shoulder (Fig. 8.45).

#### → What is Your Diagnosis?

**Degeneration of the shoulder joint:** The rotator cuff is a group of fused flat tendons that arcs over the humeral head and inserts into the greater tuberosity of the humerus. It thus forms the roof of the shoulder joint. Forward elevation of the arm and overhead motion pinches the cuff and the subacromial bursa against the overlying acromion and the acromioclavicular (AC) joint. This can lead to a chronic injury—also called impingement—which is most pronounced when there is coexisting *osteoarthritis of*

*the AC joint* (Fig. 8.46c), which can form subacromial spurs. Extensive calcification of the bursa (Fig. 8.46a) or even a rupture of the rotator cuff (Fig. 8.46b) may ensue. Eventually a full-blown *osteoarthritis of the shoulder joint* (Fig. 8.46d) develops with the typical signs of degeneration such as eccentric loss of joint space, periarticular osteophytes, and subarticular sclerosis of the articulating bones.

**Shoulder dislocation:** A shoulder dislocation is often accompanied by ligamentous or osseous injuries. Not only can the cartilaginous glenoid labrum be torn but small focal compression fractures of the humeral head (Hill–Sachs defect, Fig. 8.47) and avulsions of the inferior osseous glenoid labrum (Bankart lesion) are also possible and may need to be treated.

→ **Diagnosis:** Hannah diagnoses a rupture of the rotator cuff. Joey has found calcifications in the subacromial bursa. Mr. Aklassi discusses the findings with his wife and they decide to seek the service of a good shoulder surgeon.

### Dolor, Tumor, Rubor

Barbara Noosh's (78) hands have been hurting for quite a while, especially in the morning. She has had to quit knitting. Calling her son on her old red rotary dial phone has also been a pain. The finger joints are swollen. Paul has a short conversation with her and then turns his attention to the radiographs (Fig. 8.48).

#### → What is Your Diagnosis?

**Rheumatoid arthritis (RA):** This entity is a rheumatic disease that is seropositive for the rheumatoid factor antibody in 70–80% of cases and runs a chronic relapsing clinical course. Regions most often affected are the radiocarpal joints, the styloid process of the ulna as well as the metacarpophalangeal and proximal interphalangeal joints (Fig. 8.49). In the first place the bone is demineralized close to the joint and there is periarticular soft tissue swelling. In a later phase there is a generalized loss of joint space in the absence of new bone formation (as you would see in osteoarthritis). Erosions of the bone develop in the articular periphery where cortical bone is not protected by overlying cartilage and is therefore exposed to the synovial inflammatory response. Eventually typical subluxations with ulnar deviation in the finger joints occur. Severe joint mutilations and fusions indicate end-stage disease.

**Psoriatic arthritis:** Seronegative psoriatic arthritis is a complication of psoriasis. It prefers the distal interphalangeal joints, but the iliosacral joints and the spine can also be involved. The skin manifestations, thick, pitted fingernails, and the impressive swelling of single fingers, which is also visible on radiographs ("sausage digit," Fig. 8.50), are pathognomonic.

### The Case of André Aklassi

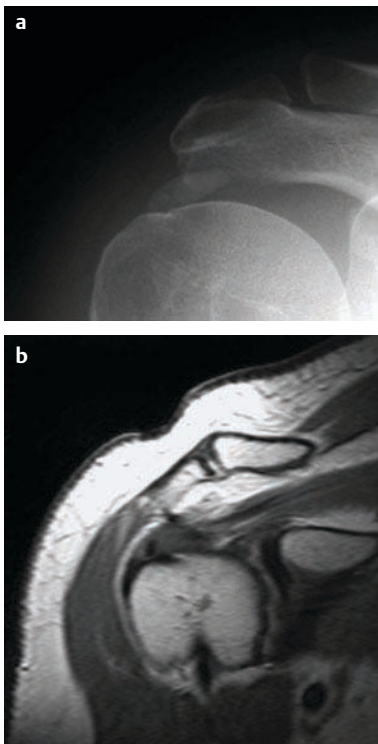
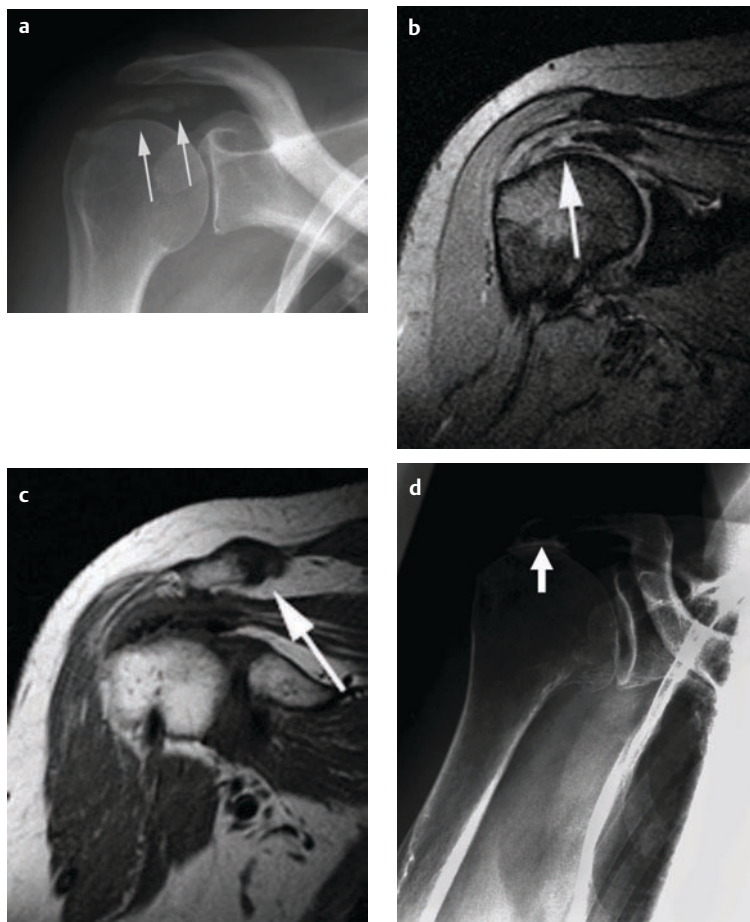


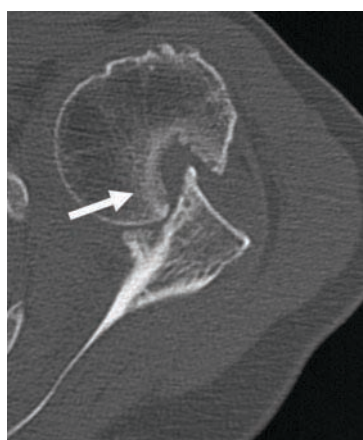Fig. 8.45 The radiograph (a) and the diagnostic MR image (b) of Mr. Aklassi's shoulder joint. Can you call the diagnosis already?

### Consequences of Degenerative Diseases of the Shoulder Joints



**Fig. 8.46** **a** Calcifications in the subacromial bursa (arrows) indicate problems of the rotator cuff, which in turn can be due to osteoarthritis of the acromioclavicular joint, often when associated with a subacromial spur. **b** The rotator cuff, an arc of tendons of shoulder muscles, is low in water content and shows consistently low in signal in MRI for that very reason. On this image of a T2-weighted sequence, a fluid-filled defect (arrow) is visible in the cuff. This is a rupture of the rotator cuff. **c** The osteoarthritis of the acromioclavicular joint shown here (arrows) causes impingement that over time may contribute to rupture of the rotator cuff. **d** The advanced degenerative disease of the shoulder joint in this patient has completely used up the subacromial space (arrow)—bone rubs on bone. The osteophytes along the lower contour of the humeral head confirm the diagnosis.

### Shoulder Dislocation



**Fig. 8.47** This CT section through the shoulder joint shows an anterior shoulder dislocation after trauma. During dislocation, the humerus banged against the anterior bony glenoid labrum, which caused an impression fracture of the humeral head—the so-called Hill-Sachs defect (arrow). The homogeneous bone sclerosis along the base of the groove and the osseous support rim at the neck of the scapula indicate that this dislocation has been present or has recurred regularly for quite some time.

## The Case of Barbara Noosh

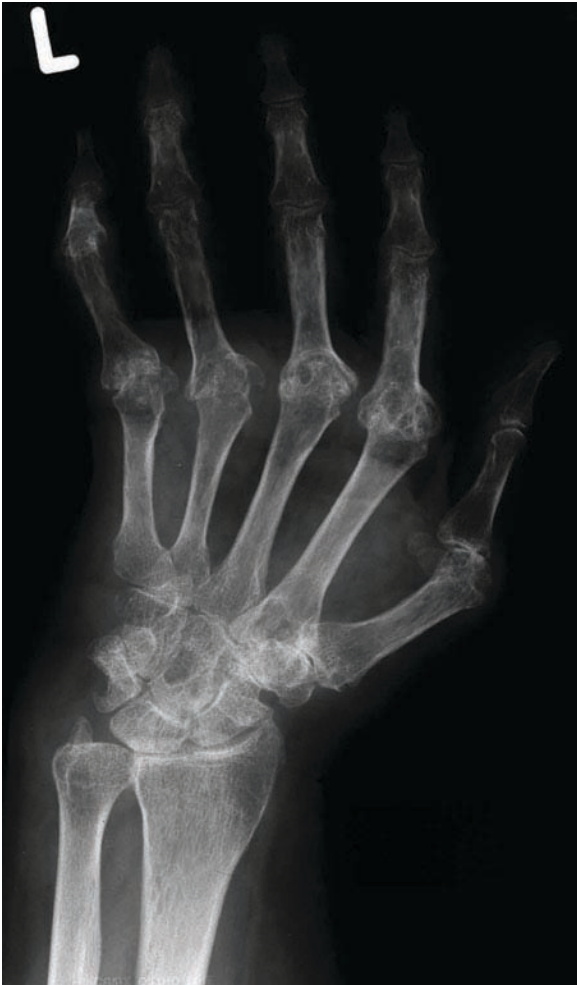

Fig. 8.48 This radiograph of Mrs. Noosh's hand shows changes characteristic of a specific disease. Can you tell which one?

## Rheumatoid Arthritis

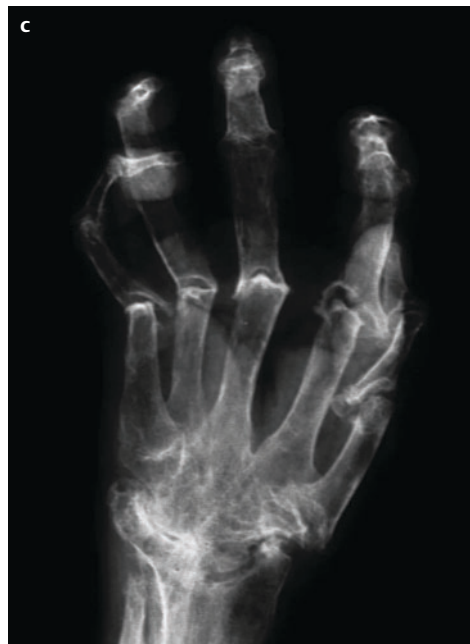
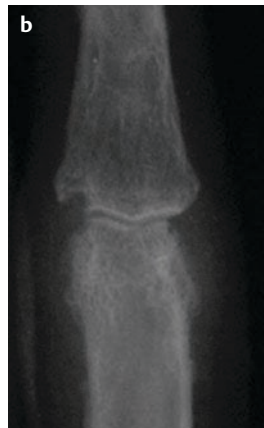
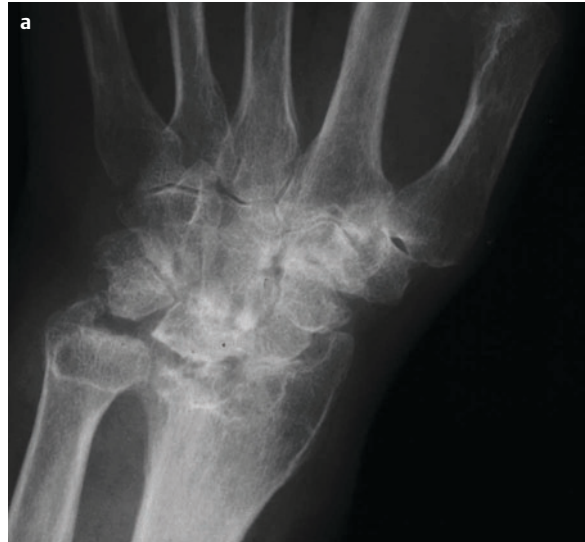Fig. 8.49 a–c Rheumatoid arthritis tends to start around the radiocarpal joint. Observe the loss of the joint space and the lytic defects in (a). Lytic defects also develop in the periphery of the finger joints (b). Advanced rheumatoid arthritis (c) is characterized by the almost complete joint destruction and ulnar deviation of the fingers. There are erosions of the periarticular cortex.



### Psoriatic Arthritis

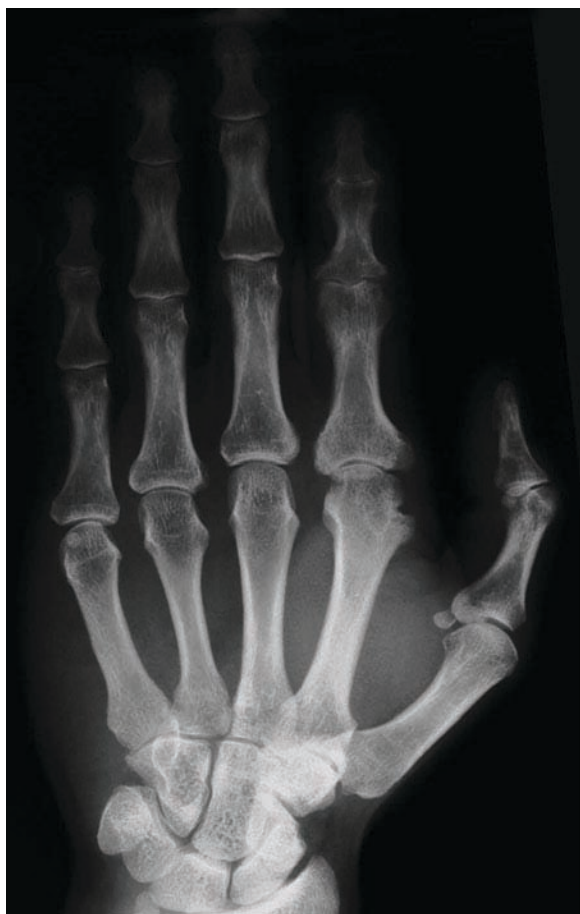

Fig. 8.50 The “sausage finger” (second digit) is a characteristic finding in psoriatic arthritis. The phalanges are plump, the joint spaces are diminished.

**Osteoarthritis of the hand and finger joints:** This condition preferentially affects the distal (*Heberden type*) and proximal interphalangeal joints (*Bouchard type*), the metacarpophalangeal joints, and the trapeziometacarpal joint of the thumb. In the example radiograph provided, the bases of the distal and middle phalanges show lateral and dorsal osteophytes, which give the joint something of a “bird in the sky” or “seagull wing” configuration (Fig. 8.51). Joint space loss is also seen.

→ **Diagnosis:** Paul has no doubt that Mrs. Noosh suffers from a textbook case of rheumatoid arthritis and he is right, of course.

### Heberden Type and Bouchard Type Osteoarthritis

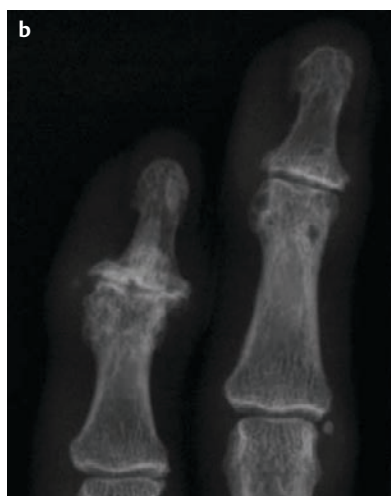
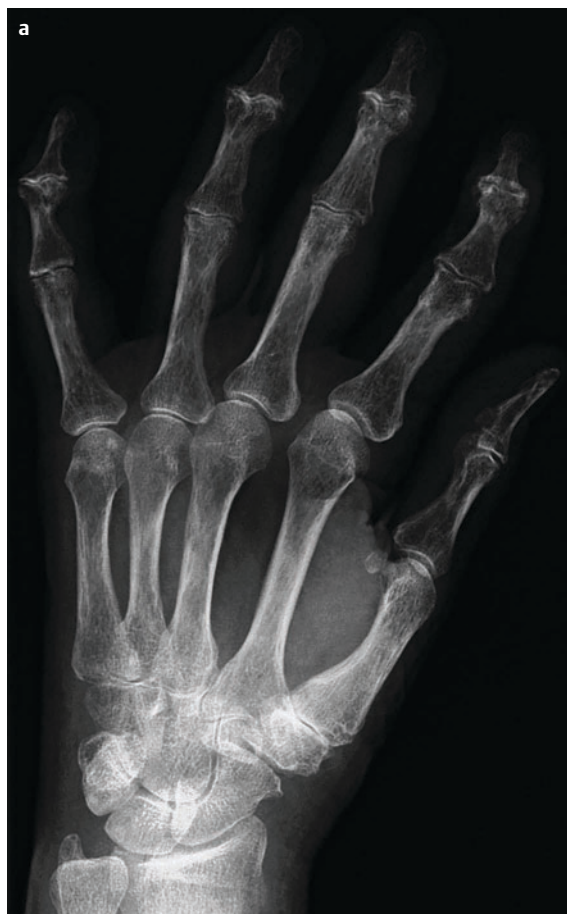
Fig. 8.51 **a, b** Changes in degenerative osteoarthritis dominate in the distal carpal joints and the distal finger joints (Heberden) (**a**). The degenerative changes are less pronounced at the level of the proximal interphalangeal joints (Bouchard). In addition there is degenerative change in the carpometacarpal joint of the thumb. The finger joint space (**b**) has the typical “bird in the sky” or “gullwing” configuration. Joint space loss is also seen. There is periarticular bone sclerosis and soft tissue swelling, resulting in the typical Heberden nodes.



### The Case of Odi Hatburn

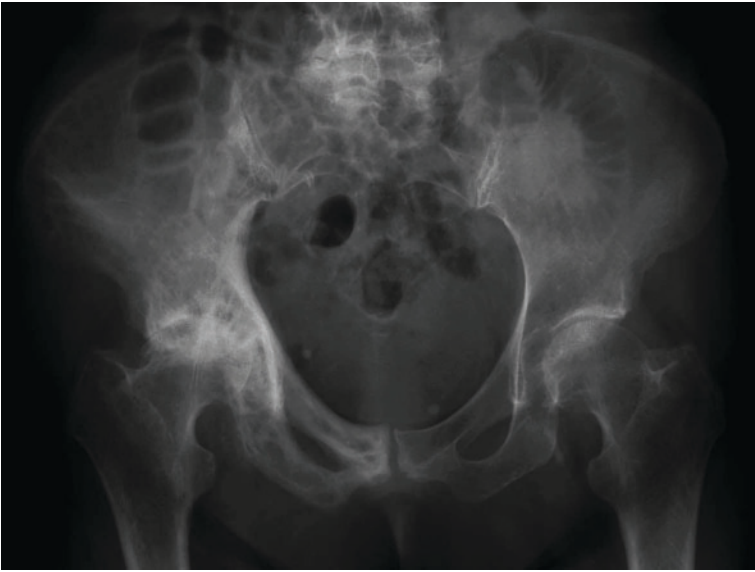

Fig. 8.52 Review this pelvic radiograph of Mrs. Hatburn. Which differential diagnoses can you think of?

## Joints of the Lower Extremity

### When Walking Becomes a Pain

For months Odi Hatburn (65) has been complaining about a radiating pain in her right hip that has kept her from her regular breakfast at Tiffany's in Chifley Square. Giufeng and Paul take a close look at her radiograph of the pelvis, concentrating on her right hip (Fig. 8.52).

### → What is Your Diagnosis?

**Osteoarthritis of the hip:** Naturally, osteoarthritis of the hip is the most probable diagnosis in this case. The degeneration of the joint is accompanied by a loss of cartilage and joint space in the weight-bearing zone, that is, in the cranial superior circumference of the hip and eccentrically. The subchondral bone becomes sclerotic as a reaction to the destruction of the cartilage. Synovial fluid is pressed into the denuded bone and generates subchondral cysts that also have sclerotic margins. Other major characteristics of osteoarthritis include osseous protuberances (osteophytes) that develop at the bony insertion of the articular capsule and are most pronounced in the region of the acetabular convexity (Fig. 8.53).

**Intraosseous ganglion cyst:** Cyst formation within the bone in the direct vicinity of a joint without concurrent signs of osteoarthritis points to an intraosseous ganglion cyst (Fig. 8.54). Its etiology remains unclear. Symptoms tend to be minimal.

**Inflammation of the hip joint:** Inflammation of the hip joint can be bacterial or sterile or rheumatic. Initially a synovial effusion is seen associated with a demineralization of subchondral bone. The periarticular soft tissues are swollen. Eventually the cartilage is destroyed in the total circumference of the joint (concentrically, Fig. 8.55a). Reactive synovial proliferation undermines the cartilage in the periphery of the joint and the typical erosions result. Toward the final stage of the disease, the joint is ankylosed or fused, making any movement impossible (Fig. 8.55b).

**Avascular necrosis (AVN) of the femoral head:** This entity is the consequence of a vascular insufficiency in an anatomical region that normally loses its embryological second arterial system because the vessels in the acetabular

### Osteoarthritis of the Hip (Coxarthrosis)

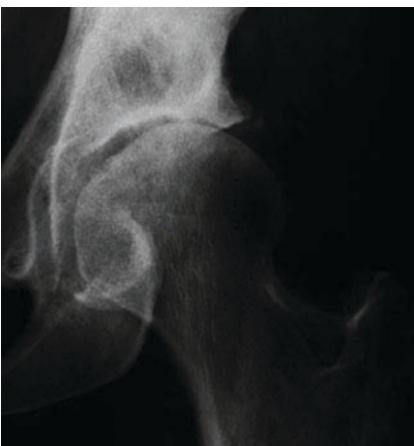

Fig. 8.53 Osseous protuberances (osteophytes) are seen extending from the acetabular convexity in osteoarthritis of the hip joint. The joint space width is diminished in the zone of weight bearing; the neighboring bone is sclerosed. The acetabulum harbors a large synovial cyst.

### Intraosseous Ganglion Cyst

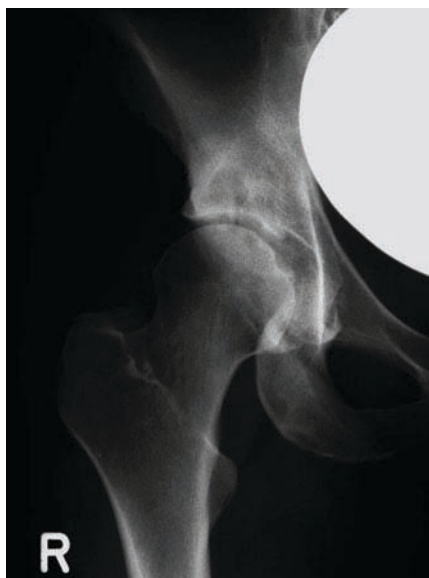

Fig. 8.54 The large cyst in the acetabulum is well appreciated. As the joint seems to be absolutely normal otherwise, the cyst most likely represents an intraosseous ganglion cyst.

ligament obliterate. AVN may be idiopathic but it is frequently associated with steroid therapy, chemotherapy, liver cirrhosis, and alcoholism. The contour of the femoral head collapses (Fig. 8.56a) and an accelerated osteoarthritis of the hip ensues. MRI detects bone marrow edema associated with femoral head necrosis much earlier than any other method and during a stage when treatment can still be of benefit (Fig. 8.56b), which is why it is indicated in hip pain with no other detectable reason.

### Inflammation of the Hip Joint

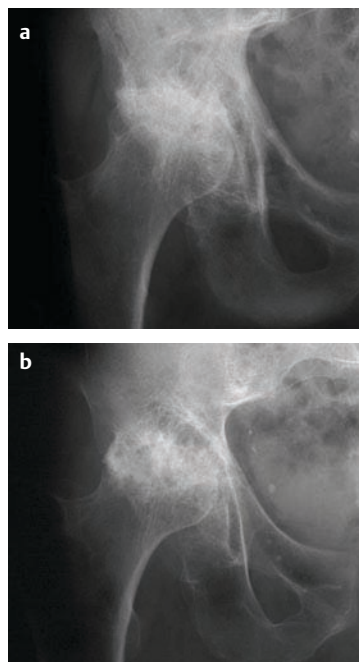


Fig. 8.55 **a** An inflammatory process, either rheumatic or infectious, is the cause for this acute joint condition. The cartilage in the hip joint has been destroyed completely and everywhere. There are no osteophytes at all. The acute phase of the arthritis has passed—the bone is already remodeling with reactive sclerosis. **b** On this radiograph of the hip, the trabeculae of the femoral head are seen to run through into the acetabulum with no joint space discernible except in the medial periphery of the joint. This hip joint has become fused/ankylosed in a late and final phase of the arthritis.

### Avascular Necrosis (AVN) of the Femoral Head

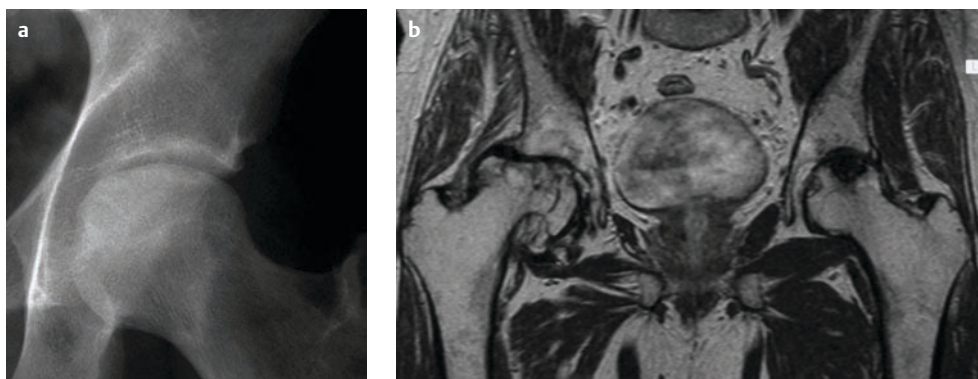


Fig. 8.56 **a** If you look closely at this femoral head you will notice the flattening of the head in the weight-bearing zone. A narrow subchondral stripe of decreased density is also seen in this area. There are no signs of joint degeneration: the joint space width is normal. This configuration is characteristic of an osteonecrosis of the femoral head due to a vascular insufficiency. All weight bearing must be avoided at once.

**b** The entity is detected with much more ease and much earlier with MRI. On the left the osteonecrosis is visible as a region of signal loss within the normal fatty marrow of the femoral head. On the right any help comes too late: the head has collapsed and is severely deformed. The ultimate therapy in this inevitable outcome of untreated AVN is a total hip replacement.

### Transient Osteoporosis

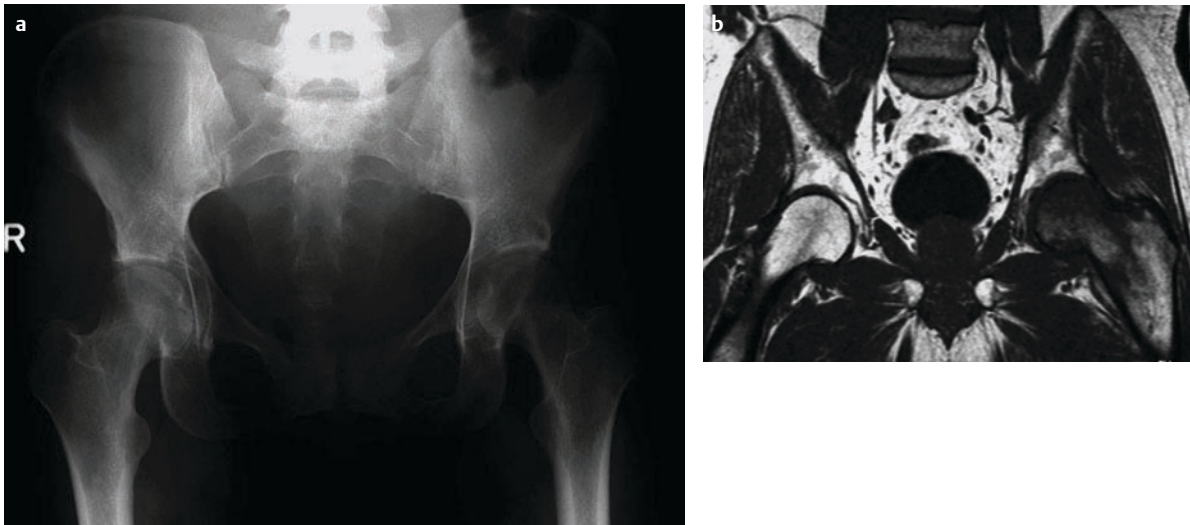


Fig. 8.57 **a** Educate your eye! On this pelvic radiograph you see the typical loss of bone density seen in transient osteoporosis. Just where exactly? In the left femoral head and neck, of course. **b** The alteration in the fatty marrow of the left femoral head and neck is much more obvious on MRI. On the right the fatty marrow shows a normal signal pattern.

**Transient osteoporosis:** This entity is supposed to be the little brother of femoral head necrosis (Fig. 8.57). It has been suggested to be a similar vascular problem that, however, encompasses the whole femoral neck. If treated with a sufficient period of rest it is supposed to resolve completely.

### Synovial Chondromatosis

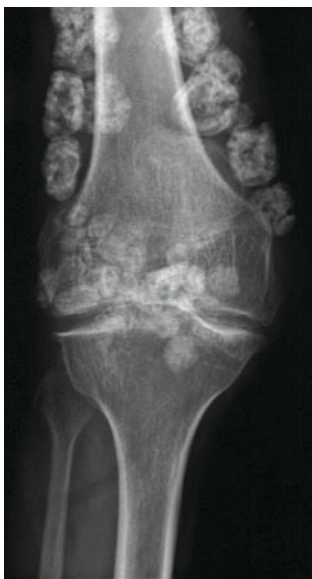

Fig. 8.58 These popcorn-like structures are typical of synovial chondromatosis. The loose bodies are suspended within the joint space and would, if left untouched and inside, destroy the joint over time. Some early osteophytes are already present along the tibial plateaus.

**Synovial osteochondromatosis:** In this basically benign disease, the articular synovial lining forms little cartilaginous loose bodies that are then released into the joint space, where they continue to grow, nourished by the synovial fluid. Osteoarthritis is the end result. It is a disease of (mainly middle aged) men rather than women. Radiologically, the cartilaginous intra-articular bodies become visible because of impressive popcorn-like calcifications (Fig. 8.58). Therapy is surgical articular lavage and synovectomy.

→ **Diagnosis:** Mrs. Hatburn's hip joint is destroyed—that is pretty obvious. There are degenerative osteophytes along the femoral neck, which point to osteoarthritis. However, the acetabular convexity shows no osteophytes at all—that is puzzling. Overweight and physical stress due to other causes are risk factors for the degeneration of the hip joint. Mrs. Hatburn denies any particular physical stress of this joint. She has never dared to leave her ideal weight for professional reasons. What could have been the cause of this kind of degeneration? Giufeng and Hannah discuss and think for a while, then put the radiograph on the side for the moment. Their next patient seems to have a similar problem and might bring them closer to the correct diagnosis.

! Not every case can be solved right away and on the spot. A little time to think and to research in the literature, a discussion with colleagues, and a call for help to one of those gray-haired, odd-looking senior radiologists are nothing to be ashamed of. The opposite is true. The final diagnosis can also be communicated to the referring physicians in a second step after a preliminary report. They will appreciate the extra attention and care.



### The Case of Dynamite Rumsfeld

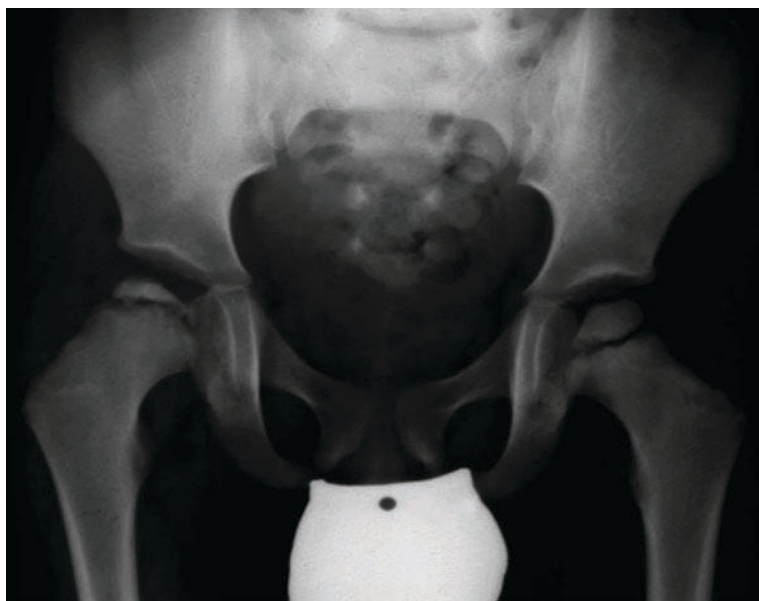

Fig. 8.59 This is the pelvic film of little Rumsfeld. Why doesn't he want to walk?

#### A Walker on Strike

Dynamite Rumsfeld (3) has refused to walk for about three weeks now. The usual educational and motivational methods have been unsuccessful. His hip joint seems to hurt. An ultrasound of both hip joints showed no abnormality. A pelvic radiograph is performed. Giufeng and Hannah have a very close look (Fig. 8.59).

#### → What is Your Diagnosis?

**Transient synovitis (syn.: toxic synovitis, irritable hip):** This entity of young children is characterized by a symptom complex of pain, limp, and spasm, generally of acute onset. An effusion in the hip joint evolves that is well

visualized by ultrasound and MRI (Fig. 8.60) but rarely appreciated on radiographs. The pathogenesis remains unclear but the prognosis is generally good; symptoms usually subside with rest.

**Legg–Calvé–Perthes disease:** Idiopathic femoral head necrosis that preferentially affects boys from 3 to 12 years of age is called Legg–Calvé–Perthes disease. It is due to a vascular problem like the adulthood femoral head necrosis. In the early stages, radiography of the pelvis shows a widening of the articular space of the affected joint due to swelling of the cartilage and the synovial lining, resulting in lateral subluxation of the head. Later, irregular demineralization and sclerosis, a flattening of the head contour, subcortical collapse of cancellous bone, and finally fragmentation of the femoral head are found. MR imaging is

### Transient Synovitis

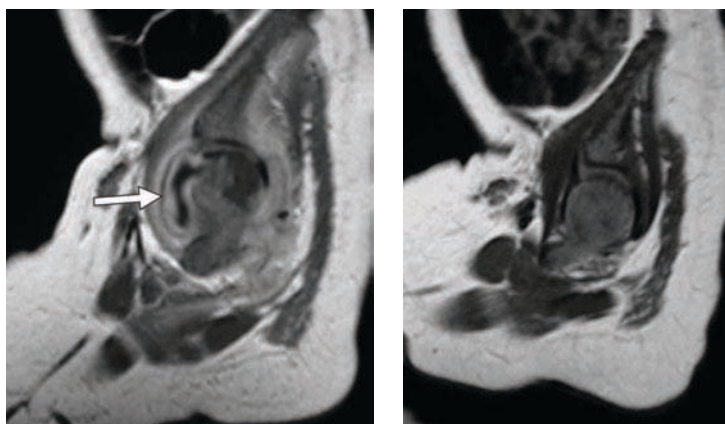


Fig. 8.60 The sagittal MR section of the hip joint (left) after the intravenous administration of contrast demonstrates an effusion in the joint surrounded by contrast-enhancing synovium (arrow). Compare the normal contralateral side (right).



### Legg–Calvé–Perthes Disease

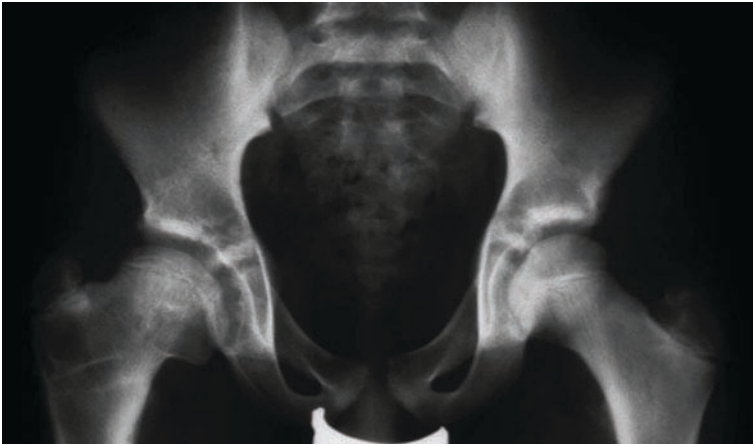


Fig. 8.61 This is an image of the deformed femoral head of a child with Legg–Calvé–Perthes disease on the right. A corrective osteotomy has already been performed (do you see the traces of an osteosynthetic stabilization in the femoral metaphysis?) to halt or slow down the degenerative process.

much more effective in proving and excluding Legg–Calvé–Perthes disease, showing a signal loss along the femoral head margin. The entity frequently heals with a deformed femoral head (Fig. 8.61), which in turn causes osteoarthritis of the hip joint in the middle-aged adult.



#### A Truly International Group

Legg–Calvé–Perthes disease is a good example of an international scientific competition in the early 20th century—and how nicely it was solved. Arthur Thornton Legg was a pediatric orthopedic surgeon in Boston; Jaques Calvé worked as an orthopedic surgeon on the northern coast of France; and Georg Clemens Perthes was surgeon and radiologist in Leipzig and Tübingen. When naming this disease, do not forget to check your listeners' nationality, then put their countryman first.

**Epiphysiolysis:** Epiphysiolysis or slipped capital femoral epiphysis is the posterior and inferior subluxation of the

femoral epiphysis due to an injury of the epiphyseal cartilage (Fig. 8.62). It tends to occur in late childhood, between ages 10 and 14, and is bilateral in 20% of cases. Pain in the groin, potentially extending into the knee joint, is typical. A short-term complication of epiphysiolysis is femoral head necrosis; a long-term complication is the deformation of the femoral head and subsequent osteoarthritis of the hip in early adulthood.

**Hip dysplasia:** Hip dysplasia is a congenital deformity of the acetabular bone and the femoral head. Less than two-thirds of the femoral head is covered by the acetabulum and the acetabular angle is too steep (Fig. 8.63). For that reason the femoral head has a tendency to recurrent dislocation. The diagnosis should be made in the first week of life, clinically or by ultrasound. If doubts remain, radiographs of the pelvis can prove the diagnosis. Therapy carries its own risks because it increases the risk of avascular necrosis of the femoral head and subsequent early-onset secondary osteoarthritis of the hip joint.

### Epiphysiolysis

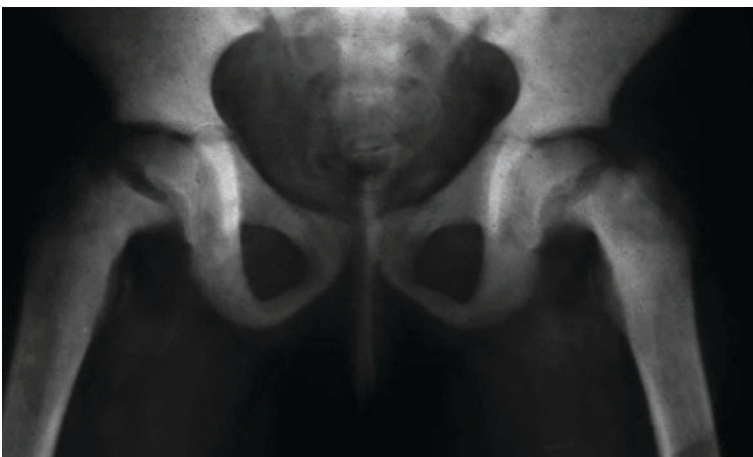


Fig. 8.62 The medial slippage of the femoral epiphysis is obvious on both sides. In the early phase the surgeons try to halt the movement by inserting metal pins that traverse the epiphyseal cartilage.

### Hip Dysplasia

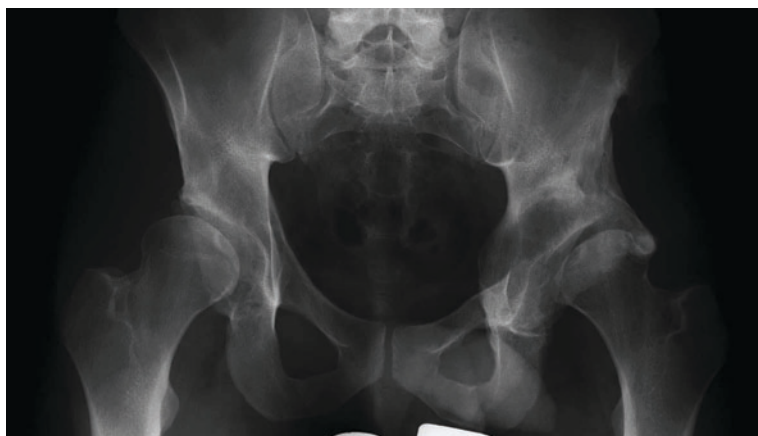

Fig. 8.63 On the right a full-blown hip dysplasia is present. The acetabular angle is too steep, the femoral head is only partially covered. On the left a correction osteotomy of the acetabular bone has been performed. Now the head is covered to a greater extent but it is also flattened. Premature degeneration of this joint is very probable.

→ **Diagnosis:** The two students are quite sure that l'il Rumsfeld has a case of Legg–Calvé–Perthes disease on the right. If any doubt remained, MRI would bring certainty. But what on earth is the reason for Mrs. Hatburn's problem? None of the described infantile precursor diseases seems to have been present. Giufeng and Hannah are still staring at Mrs. Hatburn's radiograph and scratching their heads as Gregory turns the corner: "Hey, got any problems, the two of you?" he grins and plunges into a chair beside Giufeng. "Well, we have just been waiting for you, Greg Darling!" snorts Giufeng. "This doesn't look like a normal osteoarthritis to you, does it?" Gregory straightens up, collimates the radiograph

on the viewbox with painstaking care, and contemplates the findings for a while. "Oh, Giu, you've learned so much from me in such a short time," he hums and leans back again. "You're quite right. This is indeed not a normal osteo of the hip. The joint is degenerated before its time because the bone is structurally weakened. Compare it to the other side and you see the typical textile or woven bone pattern of Paget disease on the abnormal side. Nice case, girls!" Giufeng does not know whether she should be thankful or close her eyes in disgust. Hannah makes an obscene gesture behind Greg's back. Let us leave the scene before Gregory gets into any more trouble. Had you thought of that diagnosis already?

### The Case of George Tush

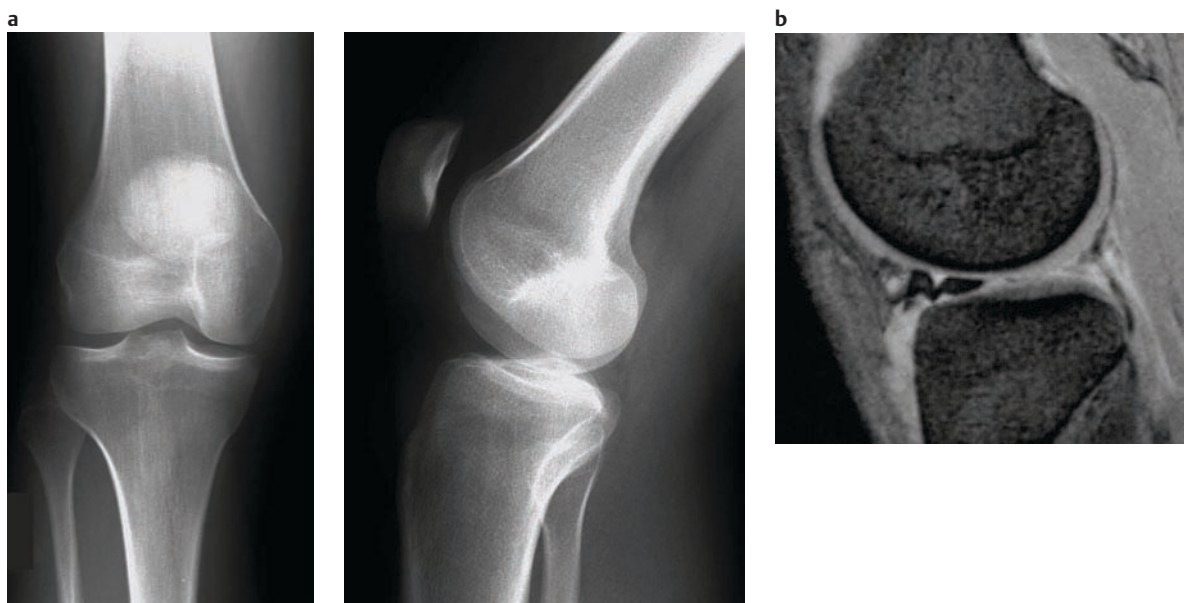


Fig. 8.64 **a** This knee joint is completely normal radiologically. An effusion is not seen. **b** The finding is obvious on MRI, isn't it?

### Osteoarthritis of the Knee

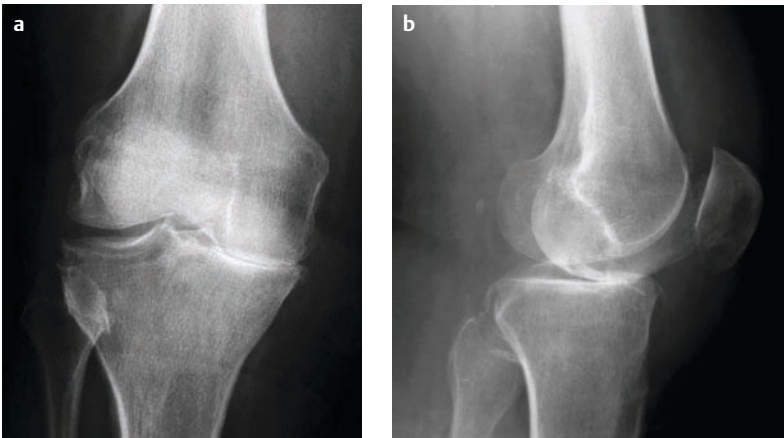


Fig. 8.65 **a** Loss of joint space width in the medial tibiofemoral joint compartment associated with osteophytes along the edge of the tibial plateau is pathognomonic for osteoarthritis (OA) due to a varus alignment of the lower extremity. The meniscal cartilage and hyaline cartilage covering the articulating bones is destroyed in the respective main weight-bearing zone. **b** A little osseous protuberance at the upper margin of the patella indicates patellofemoral osteoarthritis, which is often associated with OA of the tibiofemoral joint.

! Remember the “satisfaction of search” phenomenon: If you have your first diagnosis don’t stop right there. Keep it in mind and then take another turn and look for other findings in the imaging study.

#### → What is Your Diagnosis?

**Osteoarthritis of the knee:** Most of the time, advanced degenerative change of the knee joints can be diagnosed with standard radiographs (Fig. 8.65). Further imaging is usually not necessary.

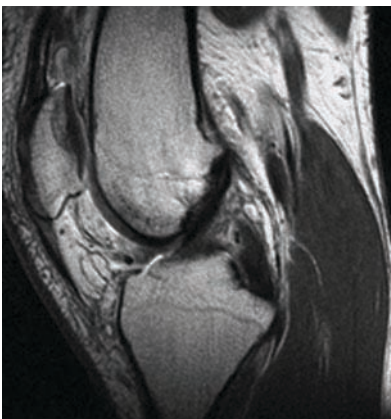
#### One Turn Too Many

While running the Sydney Marathon yesterday, George Tush (45) strained his knee on the Harbor Bridge, tripping over one of its security guards. Now it is swollen and painful and he is very worried. Paul looks at the radiograph of the knee in two projections first (Fig. 8.64a). It looks rather normal to him. The MRI examination of the knee shows the whole extent of the injury (Fig. 8.64b).

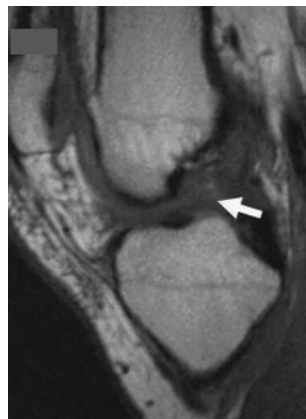**Cruciate and collateral ligament sprain or tear:** A full-thickness tear of the *anterior cruciate ligament* is best appreciated on T1-weighted MR images angled along the long axis of the ligament (Fig. 8.66b). The intact tendinous fibers seen in the normal knee (Fig. 8.66a) are no longer discernible. A *lesion of the posterior cruciate ligament* is well seen on straightforward sagittal images of the knee (Fig. 8.66c). The *collateral ligaments* are evaluated by looking at the coronal T1-weighted images.

### Cruciate Ligament Injuries

**a Normal anterior cruciate**



**b Rupture of the anterior cruciate**



**c Rupture of the posterior cruciate**

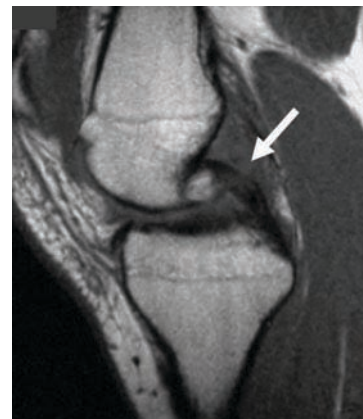

Fig. 8.66 **a** Observe this healthy knee joint with an intact anterior cruciate ligament. **b** The T1-weighted MR section along the axis of the anterior cruciate ligament should display the low-signal fibers of the ligament running from superior–posterior to inferior–anterior. Instead we see only a homogeneous

gray mass because the anterior cruciate ligament is completely torn and edematous (arrow). **c** This T1-weighted sagittal MR section shows a defect in the course of the posterior cruciate ligament. This is also a full-thickness tear (arrow).



## Meniscal Tear

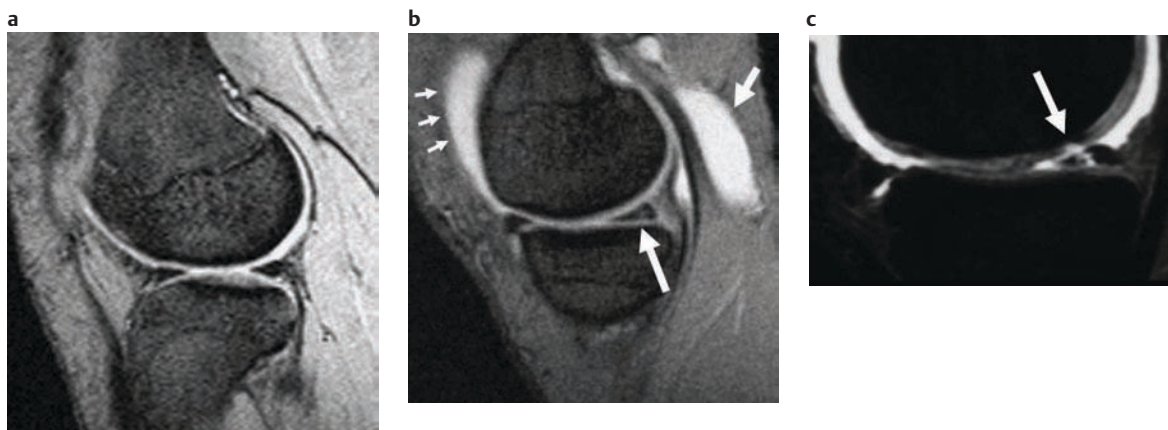


Fig. 8.67 **a** These menisci are normal. **b** The posterior horn of the medial meniscus is torn. The tear reaches the undersurface of the meniscus (long arrow). There is an effusion in the suprapatellar bursa (small arrows), most likely hemorrhagic in nature. Arising from the posterior joint space, a synovial outpouching can develop filled with joint fluid—the rather frequent Baker

cyst (short arrow), which is characteristically located between the tendons of the medial head of the gastrocnemius and the semimembranosus muscle. **c** Here you see a complete tear of the posterior horn of the meniscus. It is accompanied by a defect of the hyaline cartilage covering the femoral condyle (arrow).

**Meniscal tear:** This injury is best observed on T2-weighted coronal and sagittal images (Fig. 8.67). The cartilage is best visualized with dedicated cartilage sequences.

**Baker cyst:** The Baker cyst (Fig. 8.67b) is located posteromedially in the popliteal fossa, between the tendons of the medial head of the gastrocnemius and the semimembranosus muscle. It communicates with the joint via a slitlike connection and may cause compression syndromes or rupture. It is best detected on T2-weighted sequences. It may resolve on its own or is treated surgically.

→ **Diagnosis:** Paul diagnoses a tear in the posterior horn of the medial meniscus in Tush's knee. The posterior me-

niscus is dislodged ventrally and compresses the ventral meniscus—"kissing menisci" is the nice term for the phenomenon. This is an indication for surgery.

## Occupational Disease?

Doris Goldberg (19) is an energetic young lady who has done a lot of footwork during her career: she is a ballet dancer. Now she has had pain in her ankle for a little while. The standard radiographs of her ankle show a region of increased density in her medial talus that needs further analysis. MRI of the ankle has been performed (Fig. 8.68). Giufeng and Joey analyze the image with care.

## The Case of Doris Goldberg

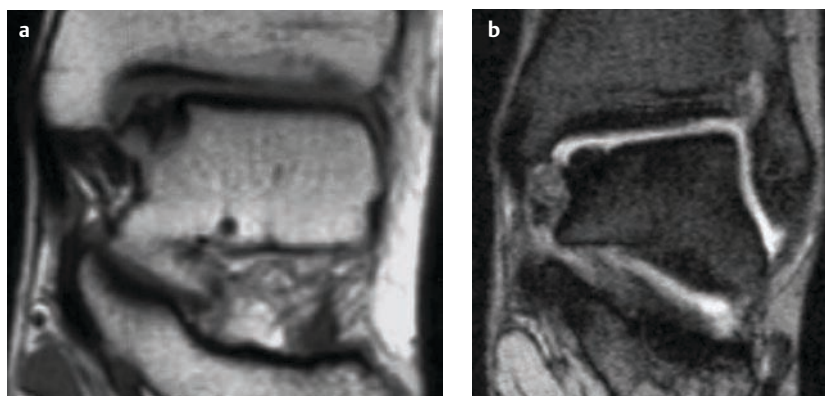


Fig. 8.68 Representative T1-weighted (**a**) and T2-weighted (**b**) MR sections of Mrs. Goldberg's upper ankle joint show an abnormality. Which entities do you have to consider?



## Osteochondritis Dissecans

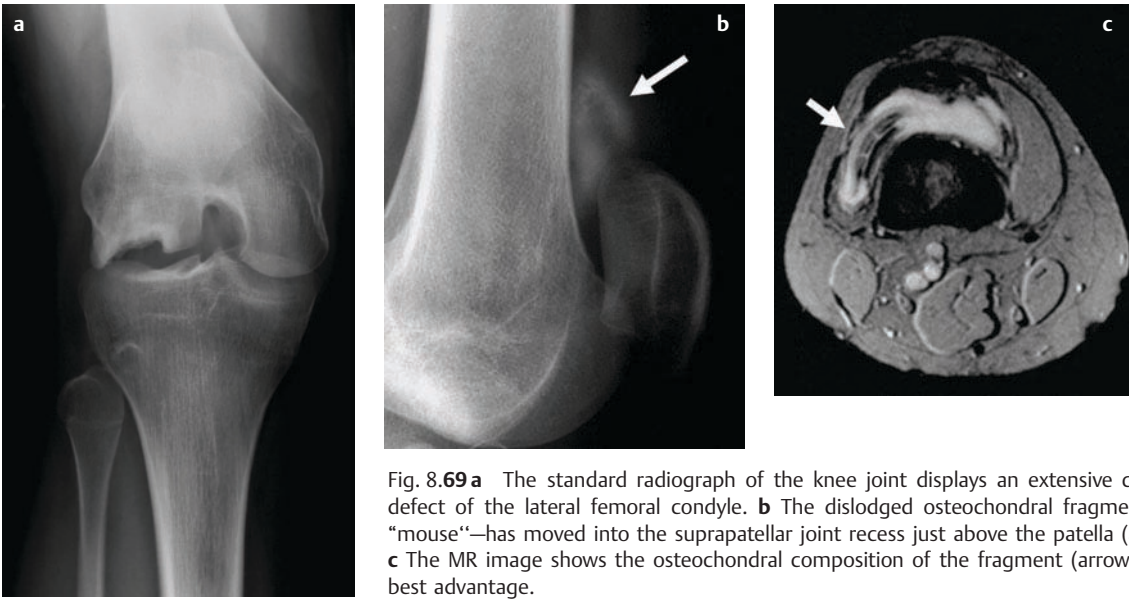


Fig. 8.69 **a** The standard radiograph of the knee joint displays an extensive contour defect of the lateral femoral condyle. **b** The dislodged osteochondral fragment—the “mouse”—has moved into the suprapatellar joint recess just above the patella (arrow). **c** The MR image shows the osteochondral composition of the fragment (arrow) to its best advantage.

## → What is Your Diagnosis?

**Osteochondritis dissecans (OD):** This disease is caused by vascular insufficiency and/or traumatic injury of the junction between bone and cartilage (Fig. 8.69a). A typical OD in the upper ankle joint is located along the medial and posterior contour of the talar dome. Radiologically a subchondral zone of decreased density (called a “mouse bed” by some) houses a rounded sclerotic osteochondral fragment (called a “mouse” by some) that may later be dislodged and become an intra-articular loose body (“The mouse leaves its bed,” Fig. 8.69b, c). How well the fragment is anchored in its bed can best be evaluated by MRI. When the fragment gets dislodged, synovial fluid is seen at the base of the defect. Without treatment, osteoarthritis of the affected joint may ensue.

**Osteonecrosis of the talus:** As in femoral head necrosis, subchondral demineralization and then a collapse of the articular surface develops (Fig. 8.70a), which in turn leads to a degeneration of the joint. It is easily and very early appreciated by MRI (Fig. 8.70b).

**Osteoarthritis of the ankle joints:** Of course one has to consider classical osteoarthritis. The general signs are already familiar to us—remember the hip joint (see p. 151).

→ **Diagnosis:** Giufeng and Joey agree that this is a typical case of osteochondritis dissecans where, fortunately, “the mouse has not left the bed” yet and still seems to be well anchored. To document the status of an OD and to decide about conservative or surgical therapy, MRI is the modality of choice.

## Osteonecrosis of the Talus

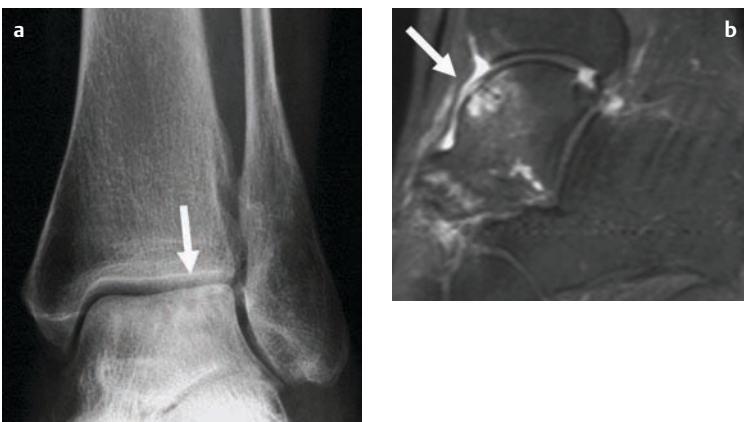


Fig. 8.70 **a** The lateral talar dome appears more radiolucent, in analogy to the femoral head in AVN (see Fig. 8.55). **b** This fat-saturated sagittal T2-weighted MR image demonstrates a signal increase in the corresponding location. The normal fatty marrow signal was also absent on a T1-weighted image: The diagnosis of osteonecrosis of the talus is established.

### Wine, Women and . . . Oh, Goodness, My Big Toe

Luciano Pavarocki (62) loves the good life. He spent his last weekend under the reign of Bacchus, dancing, singing, drinking, and trying other things. Now his foot hurts badly. It is not really the first time this has happened. His big toe base joint is swollen. His wife—a well known opera singer herself with a special love for Wagner—knows the problem and has told him her diagnosis already. Mr. Pavarocki cannot remember it, however—he leaves all the business stuff to his wife. Joey and Ajay grab the radiographs and study them closely (Fig. 8.71). Ajay pulls all the drawers searching for that big red skeletal radiology book that Gregory hides there somewhere.

### The Case of Luciano Pavarocki

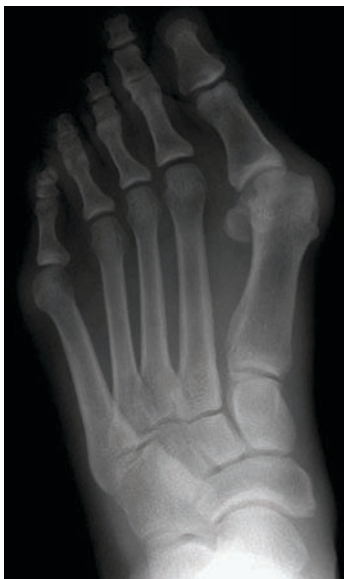

Fig. 8.71 Have a good look at the radiograph of Luciano Pavarocki's forefoot. Do you see the cause of his pain?

#### → What is Your Diagnosis?

**Osteoarthritis of the hallux base joint:** The base joint of the big toe frequently suffers from degeneration because it is exposed to a lot of physical strain (Fig. 8.72). Osteophytes and sclerosis of the periarticular bone point in this direction. Osteoarthritis may, however, become more aggressive (erosive osteoarthritis) and present with clinical signs of inflammation as well.

**Rheumatoid arthritis (RA, see p. 147):** Radiographic findings in RA of the foot resemble those in the hand (Fig. 8.73).

### Osteoarthritis (OA) of the Hallux Base Joint

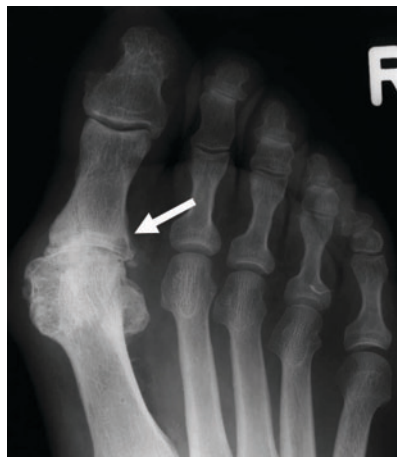

Fig. 8.72 Osteophytes, synovial cysts (arrow), and sclerosis indicate degeneration (OA) of the first metatarsophalangeal joint.

**Gout:** Gout or gouty arthritis typically manifests itself in the first metatarsophalangeal joint. In this location it is also called podagra in fashionable Latin. In addition to the usual signs of arthritis, large defects develop in the vicinity of the joint (Fig. 8.74), the so-called gout tophi in which urates are deposited. The gout attack can simulate an otherwise unremarkable osteoarthritis, which is why in degenerative disease of the first metatarsophalangeal joint a disturbance of the uric acid metabolism should always be excluded with the appropriate laboratory tests.

**Hallux valgus:** A hallux valgus is a pronounced lateral deviation of the great toe at its base joint. The angulation

### Rheumatoid arthritis (RA)

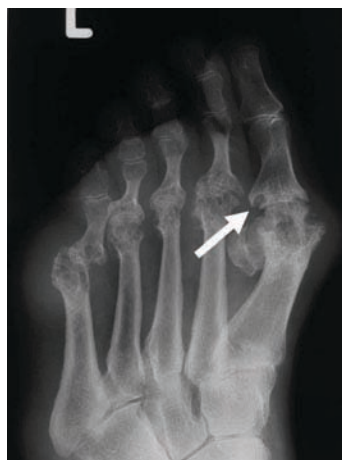

Fig. 8.73 Subluxation, concentric loss of joint space, erosions (arrow), and the destruction of the articular surfaces are hallmarks of RA. The soft tissue swelling is anticipated.

### Gout

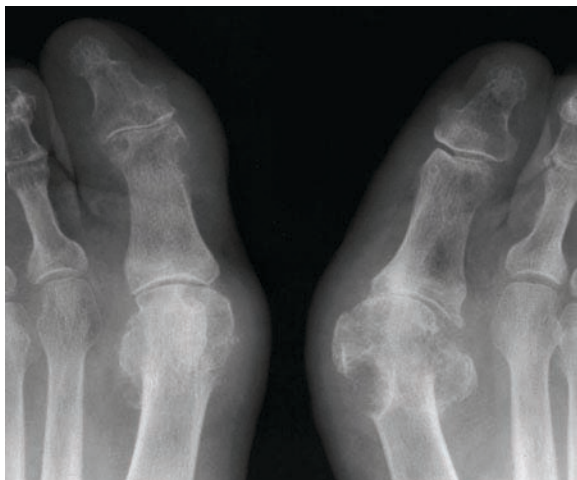


Fig. 8.74 Loss of joint space and sclerosis are present—predominantly in the left base joint of the big toe. The large defects of the head of the metatarsal bone of the first toe are caused by gout tophi.

imitates an exostosis or a bunion. Pain and inflammation are frequent findings due to the unphysiological biomechanical stress on the joint (Fig. 8.75).

If this patient had a neuropathy (for example, as a consequence of severe diabetes), one would have to consider another diagnosis:

### Hallux Valgus (Bunion)

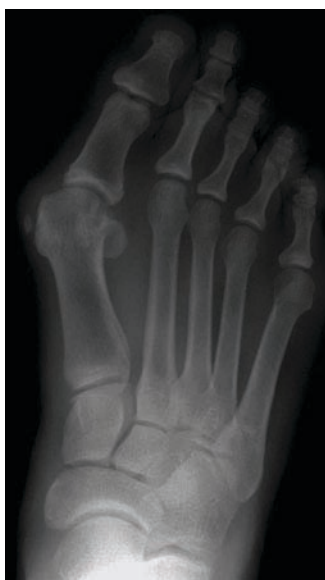

Fig. 8.75 Hallux valgus is characterized by a lateral subluxation of the proximal phalanx in relationship to the first metatarsal with a resulting palpable bony protuberance lateral to this joint.

### Neuropathic Arthropathy

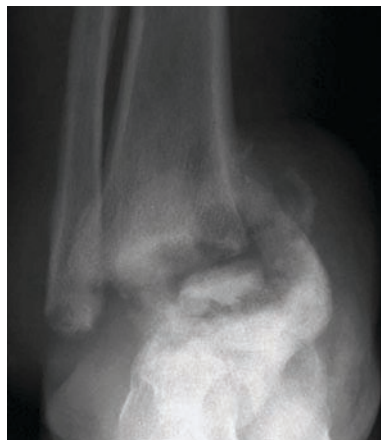

Fig. 8.76 Diabetes is one of the most frequent causes of a neuropathic arthropathy. In this case the whole upper ankle joint and the talus are destroyed. The bones stand misaligned. This may also occur in the first metatarsophalangeal joint.

**Neuropathic arthropathy:** A neuropathic arthropathy causes destruction and complete mutilation (Fig. 8.76), particularly of the large and heavily stressed affected joints. The cause of the damage is thought to be a combination of the sensory loss and vascular insufficiency. The joints suffer from a chronic biomechanical overload; associated pain that would normally prevent further use of the joint beyond its physical limits is not adequately perceived by the patient. Neuropathic arthropathy, particularly of the lower extremities, was also often seen in patients with neurosyphilis and was initially called “Charcot joint.” Today the term applies to any neuropathic arthropathy.

→ **Diagnosis:** While Ajay still ponders gout as the diagnosis—he has seen his grandfather suffer from it—Joey has made up his mind that this is a typical hallux valgus. Pavarocki’s dancing must have aggravated the situation. However, this sort of weekend would also go along beautifully with a gout attack—the famous podagra.

! If the patient history always pointed us in the right diagnostic direction, imaging would be a useless exercise. For a radiologists this means: First analyze the image and get your thoughts organized, then check the clinical history, and at the end review the study again with both biased and unbiased information in your mind.

## 8.5 Fracture and Dislocation

For frequent and relevant fractures and dislocations of the different skeletal regions, refer to Chapter 14.

## 8.6 Soft Tissue Tumors

### Checklist: Soft Tissue Tumors

- Is a predisposing disease known?
- Is it a solitary lesion or are multiple masses present?
- Does the MR signal of the lesion suggest a specific diagnosis?
- Is the location of the lesion typical?

### Criteria of malignancy<sup>1</sup>

- Does the mass invade the neurovascular bundle?
- Is the mass inhomogeneous in MR on T1- and T2-weighted sequences and after contrast administration?
- Does the mass show septations?
- Does its diameter exceed 4 cm?
- Does the mass grow rapidly?

<sup>1</sup>If you can answer these questions with a “yes,” a malignant lesion is probable and must be excluded.

### The Protrusion of Unknown Origin

Arnold Schwortenbakker (29) has a lump on his right upper arm that is not really explainable by his regular bodybuilding or any gubernatorial activities. He is not absolutely sure how long it has been present. It was actually his secretarial intern who detected the lesion. The lump is very soft and mobile. Joey decides that because of the lump's location, and the age and apparently good physical health of the patient, a lymphoma or metastasis is unlikely, but that an isolated soft tissue tumor is a good possibility. He studies the MR images with great care (Fig. 8.77) and searches for typical aspects that make a histological diagnosis possible (see Checklist). If a histological diagnosis is not possible on the grounds of a typical imaging appearance, Joey must at least try to determine whether the tumor is benign or possibly malignant in nature.

→ **What is Your Diagnosis?** Joey goes through a mental list of soft tissue tumors that are associated with other disease entities:

**Neurofibromatosis type I (syn.: NF1, von Recklinghausen disease):** This autosomal-dominant congenital disease manifests with numerous nodular, soft neurofibromas of the central, peripheral, and autonomic nerve system (Fig. 8.78). The famous café-au-lait colored skin spots are characteristic. In addition, gliomas of the optic nerve and dysplasias of the sphenoid bone may be present. The neurofibromas can transform into malignant *neurofibrosarcomas* in up to 10% of patients. Rapidly growing lesions are highly suspicious for that reason.

**Amyloid:** Amyloidosis can infrequently cause soft tissue tumors that have nonspecific MR signal intensity between muscle and cartilage on both T1- and T2-weighted images. As with lymphoma today and syphilis in the past, one should be prepared for the unusual. The question “Could this be amyloid?” has a resounding effect in utterly complicated cases and—if used sparingly and with caution—provides the radiologist with a minute to catch his or her breath in discussions with suddenly hesitant clinical colleagues.

**Mafucci syndrome (see p. 123):** In this entity hemangiomas are seen parallel to the already described multiple enchondromas. They typically contain phleboliths, which is why this diagnosis can be diagnosed on plain radiographs.

Now Joey thinks about all tumors with a typical signal behavior in MRI:

**Lipoma, liposarcoma:** A pure lipoma demonstrates a typical high, fat-equivalent signal on T1-weighted and fast spin echo T2-weighted images just like subcutaneous fat tissue. With the so-called “out of phase technique,” the fat content of the tumor can be proved. If the interior of the lesion appears homogeneous, a benign process is more likely. If a tumor is inhomogeneous, has irregular

### The Case of Arnold Schwortenbakker

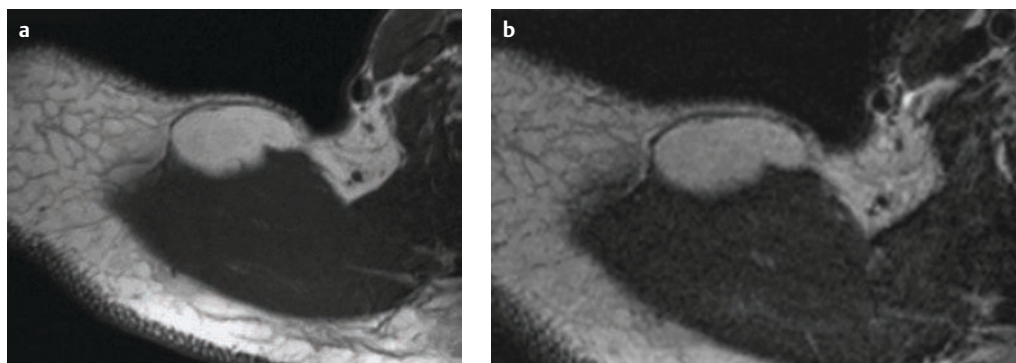


Fig. 8.77 This axial MR image of Mr. Schwortenbakker's arm above the right shoulder joint in T1-weighting (a) and T2-weighting (b) should be more than sufficient for your diagnosis! What soft tissue tumors do you have to contemplate?



### von Recklinghausen Neurofibromatosis (NF1)

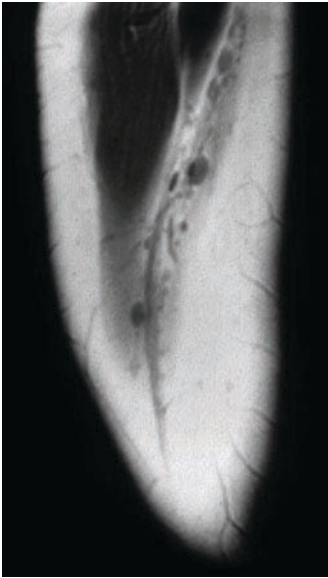


Fig. 8.78 Multiple neurofibromas are located along the course of the neurovascular bundle.

margins, invades the neighborhood, and also contains fat (Fig. 8.79), a liposarcoma is probable and has to be ruled out through biopsy or excision. Lack of fat, however, does not exclude a liposarcoma.

**Fibrosarcoma, malignant fibrous histiocytoma:** Tumors with a high proportion of fibrous tissue such as fibrosarcoma (Fig. 8.80) or malignant fibrous histiocytoma (MFH) may show a relatively low signal on both T1-weighted and T2-weighted MR images. The reason is the paucity of protons in this tissue, which are needed for imaging in conventional magnetic resonance tomography. A low signal both in T1-weighted and T2-weighted

### Liposarcoma

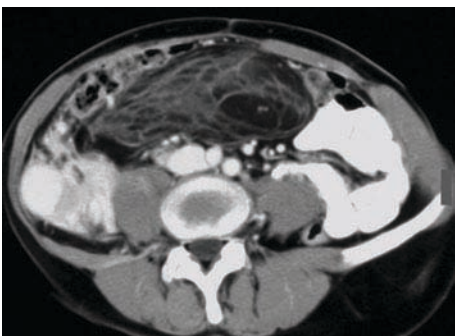


Fig. 8.79 This CT image through the upper pelvis shows a large fatty tumor within the mesentery that is septated by fibrous strands of differing caliber. Histology confirmed the radiological suspicion of a liposarcoma.

### Fibrosarcoma

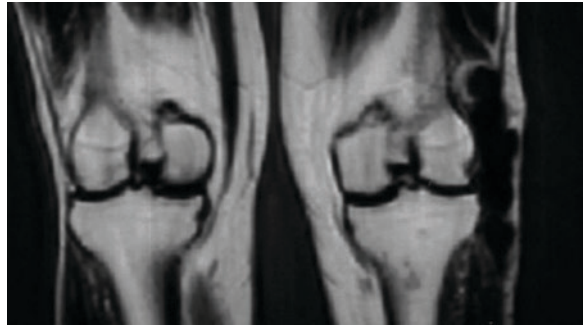


Fig. 8.80 The coronal MR sections through both knee joints document a large signal-free structure along the left joint. This signal type is typical for fibrous, water-deprived tissue. Size, configuration, and signal suggest a malignant fibrous tumor here—a fibrosarcoma.

images can, however, also be caused by fast blood flow or calcifications in a tumor.

**Myositis ossificans:** The main characteristic of a myositis ossificans is the overshooting ossification of the soft tissues—frequently after a soft tissue trauma and resulting intramuscular hematoma. It is particularly pronounced if the patient has been in coma. The diagnosis is usually made from the plain radiograph (Fig. 8.81).

### Myositis Ossificans (Heterotopic Bone Formation)

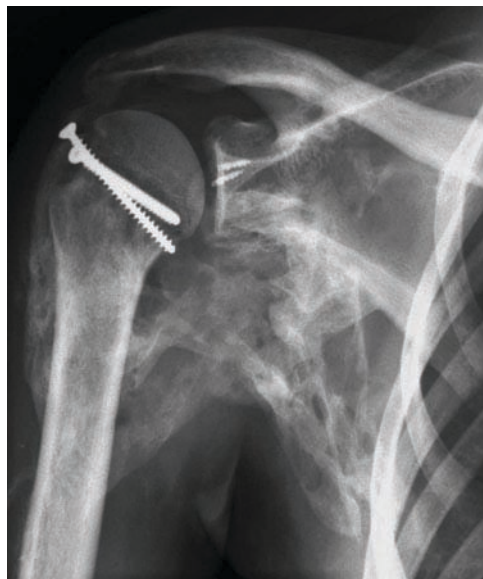


Fig. 8.81 There is overshooting calcification or ossification of the soft tissues after a severe shoulder injury, often transforming a hematoma—myositis ossificans. The range of motion in this joint is naturally very limited. The patient also suffered a heavy brain injury and stayed in coma for three weeks. Comatose patients tend to develop particularly large areas of heterotopic bone formation.

### Synovial Hemangioma

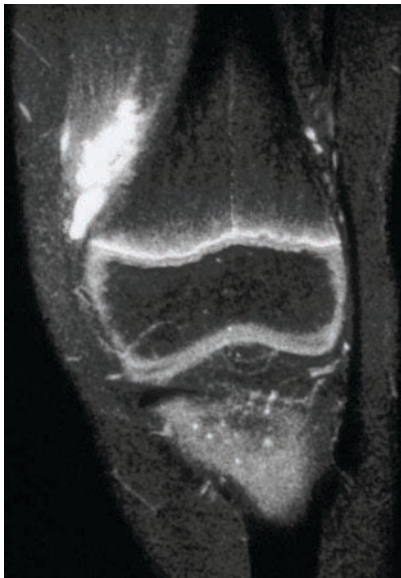


Fig. 8.82 This coronal MR section with fat saturation and after intravenous contrast administration displays a significantly enhancing structure lateral to the femoral metaphysis. Location and structure are typical for a synovial hemangioma.

Finally Joey considers lesions in typical locations:

**Synovial hemangioma:** This is a vascular lesion in the direct vicinity of the knee joint (Fig. 8.82).

**Plantar/palmar fibromatosis:** The plantar or palmar fibromatosis (better remembered as Ledderhose disease and Dupuytren disease, respectively) are nodular lesions of the fascia of foot and hand.

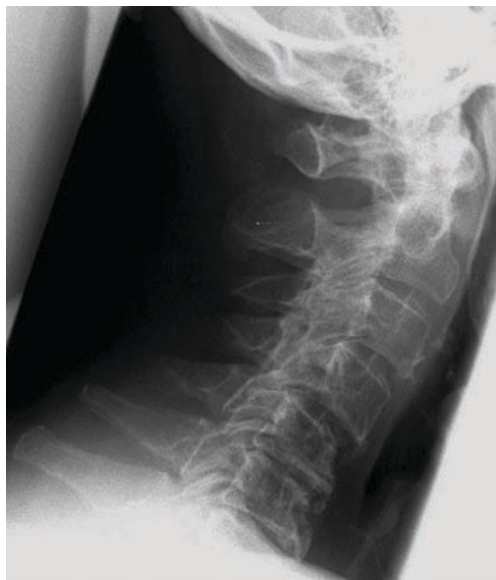→ **Diagnosis:** Joey could not really get much more information out of the images. But he has got good news for Mr. Schwortenbakker. His tumor is definitely a lipoma, which can easily be resected by his plastic surgeon. Had the lesion fulfilled the above criteria of malignancy, Joey could have determined the most likely histological diagnosis by taking into account the age of the patient and the localization of the tumor. It would have earned him the special respect of the clinical colleagues.

## 8.7 Gregory's Test

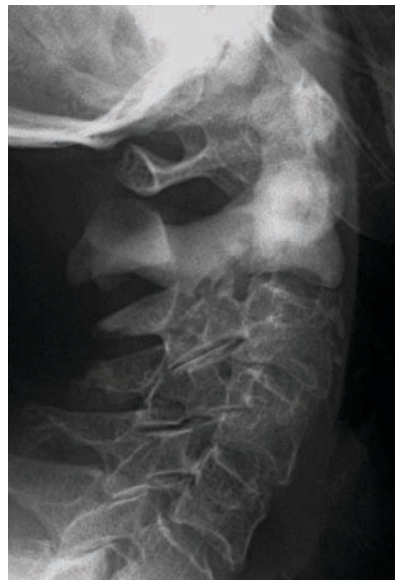Giufeng, Hannah, Paul, Ajay, and Joey sit in the skeletal imaging unit at the end of the day and are having a good time. As they dig into their quiche to order, Gregory opens the door. His face lights up as he notices the little crowd: "Apparently I came right on time," he roars and grabs the last piece of the quiche. "OK, who's ready for dessert? Come on, Joey, let's hear it!" He munches and whips a few films onto the lightbox (Fig. 8.83). Who can help Joey? Jot down your diagnoses. You'll find the answers at the end of the book (see p. 342).

### Test Cases

Fig. 8.83 a–l

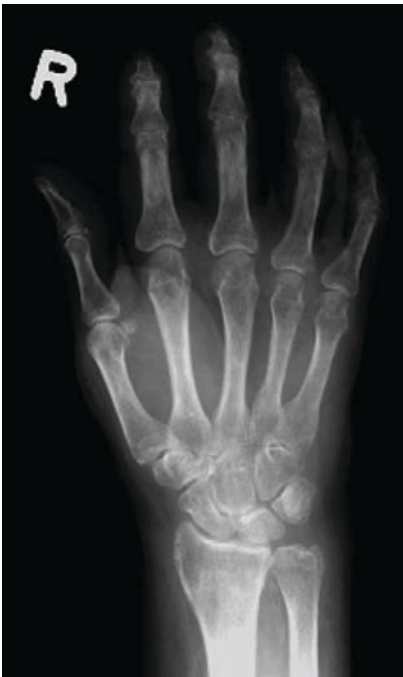

a This elderly man complained of cervical pain.

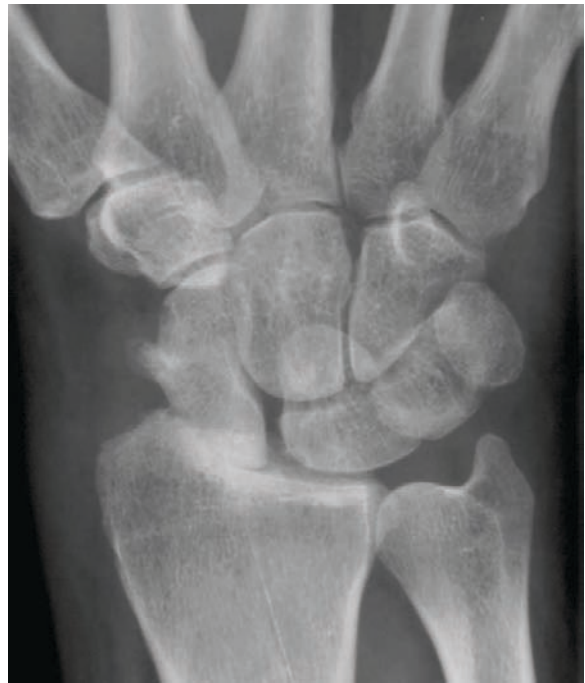

b This patient had the same problem.

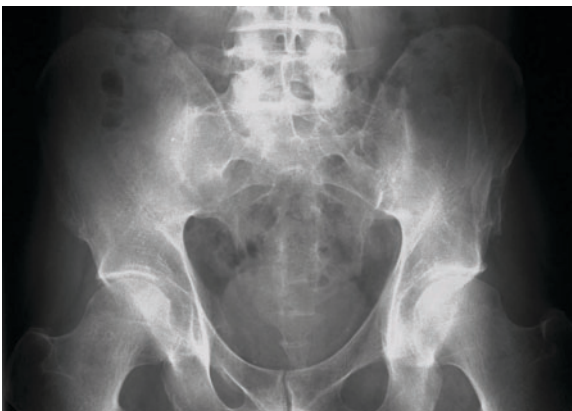## Test Cases



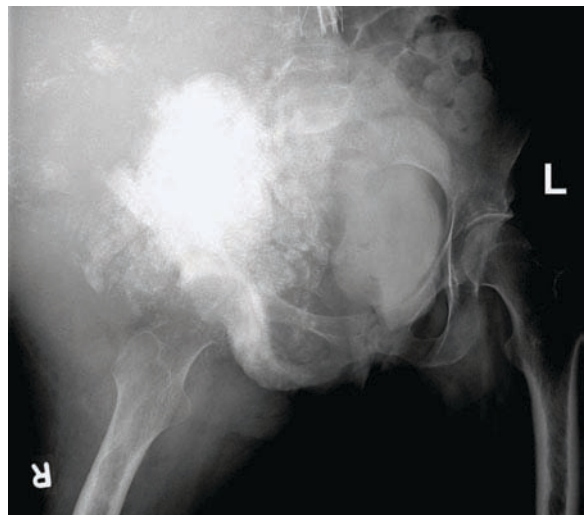
c This hand of a young woman was warm, swollen, and painful.



d This joint was painful.



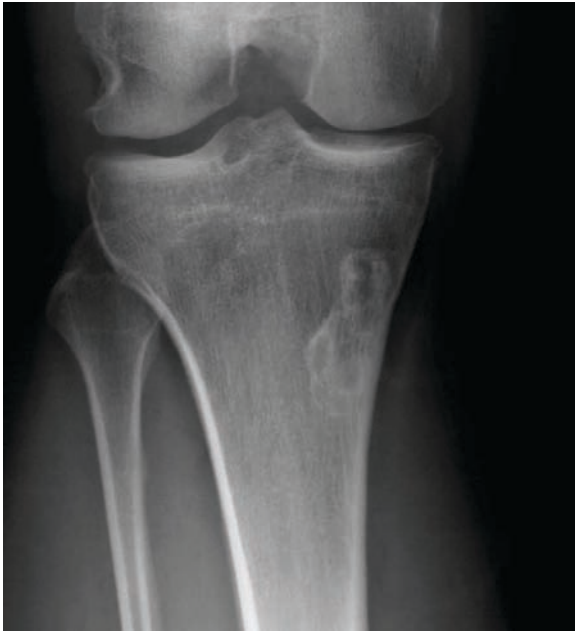e This patient felt a little stiff and had unspecific back pain.



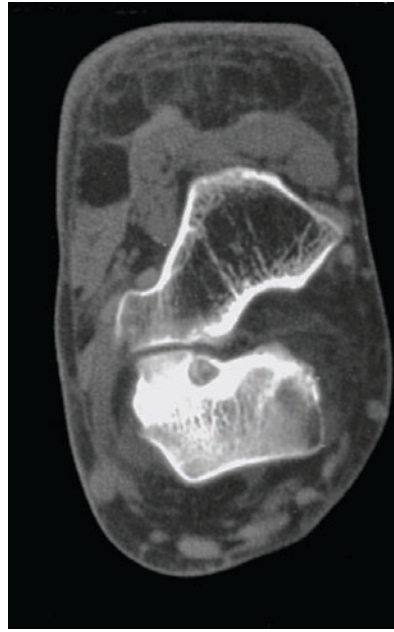f A large swelling and pain in the right lower abdomen and pelvis was the problem here. Tell us the histology!



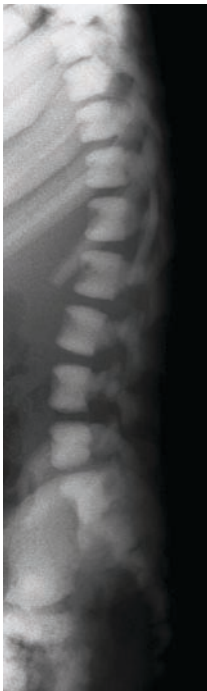## Test Cases



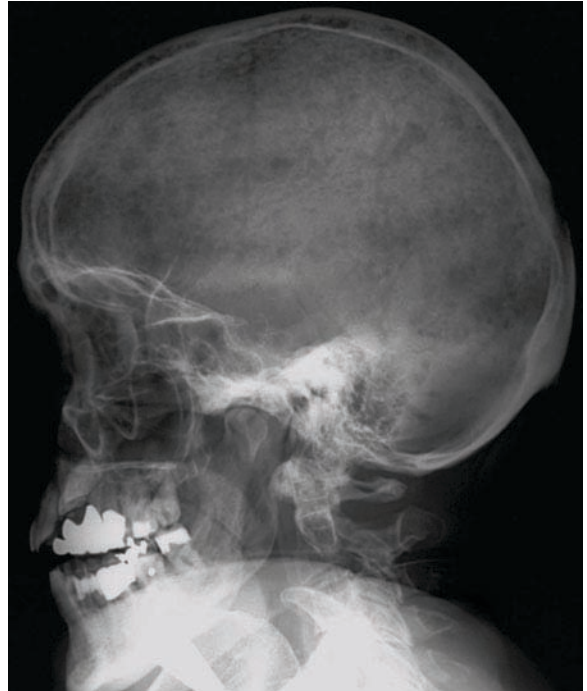g This lad came straight off the soccer field.



h The foot has been painful, especially at night.



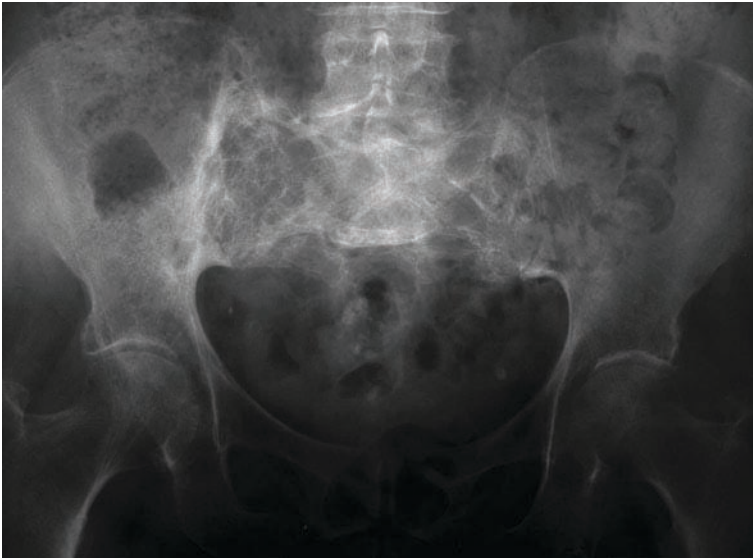i This kid has a problem.



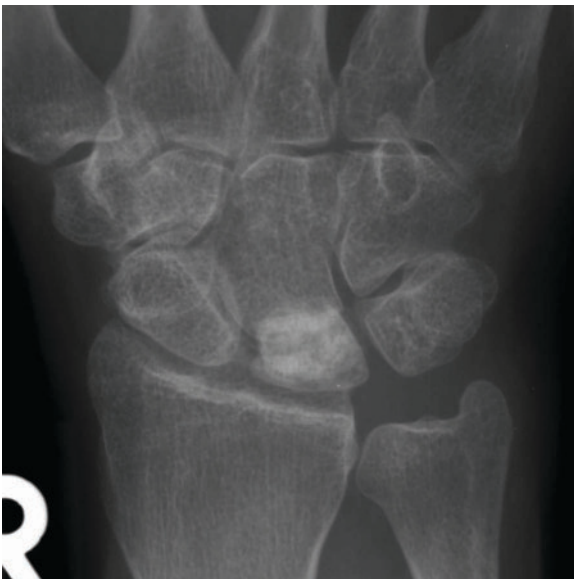j This elderly patient has been sent by the internists.



## Test Cases



k This is an incidental finding in a patient who is being checked for skeletal metastases of a prostate cancer.



l This hand has been painful for some time. The radiograph shows a disease with a name. Go search your sources and let us hear it!

## 9 Gastrointestinal Radiology

The evolution of fiberoptic endoscopy has brought about a profound change in the frequency and spectrum of examinations performed by abdominal radiologists today. No other subspecialty in radiology has undergone a comparable shift in recent decades. Direct visualization of the gastrointestinal tract has largely replaced classical radiology, especially in the evaluation of the stomach, duodenum, and colon. While our forefathers (look for some gray-haired survivors in the dark corners of the department) performed dozens of upper GI examinations per day, today's students and residents have little chance to witness a significant number of these skillful examinations during their rotations in GI radiology. On the other hand, their odds of seeing a double contrast barium enema are much higher. While the resulting images are quite appealing visually when obtained by a real master of this dying art, their diagnostic yield is typically inferior to that of endoscopy.

! The endoscopic studies of the stomach, the duodenum, and the colon are unsurpassed because they permit direct visualization of the mucosal surface and allow for immediate tissue sampling of suspicious findings or even interventions such as stent placement during the same session.

One thing applies to both endoscopy and barium studies: quality and efficiency rely heavily on the operator. As always, radiologists are somewhat more exposed than other specialists: a rotten barium study can haunt a radiologist for ages.

The **classical radiological imaging methods** such as upper GI examination still play an important role whenever physiological motion plays a role (swallowing, peristalsis of the esophagus, gastric motility, etc.) and in post-operative patients, e.g., when the evaluation of an anastomosis has been requested. The oral administration of contrast is obligatory in these cases. For intestinal segments that are inaccessible for the normal endoscope—in particular the mid to distal small bowel—radiological procedures remain a diagnostic mainstay. Capsule endoscopy is an emerging direct, nonionizing modality that uses a small radiofrequency transducer that is swallowed and acts as a camera imaging the small bowel; this might turn the tide in the near future.

**Sectional imaging** techniques such as ultrasound, CT, and MRI are increasingly gaining ground in the radiological evaluation of the hollow viscera: virtual colonoscopy is just one example (Fig. 9.1a, b). On the other hand, contrast-enhanced sectional imaging undoubtedly is the gold standard of the radiological evaluation of the solid organs in the abdomen.

### Virtual Colonoscopy

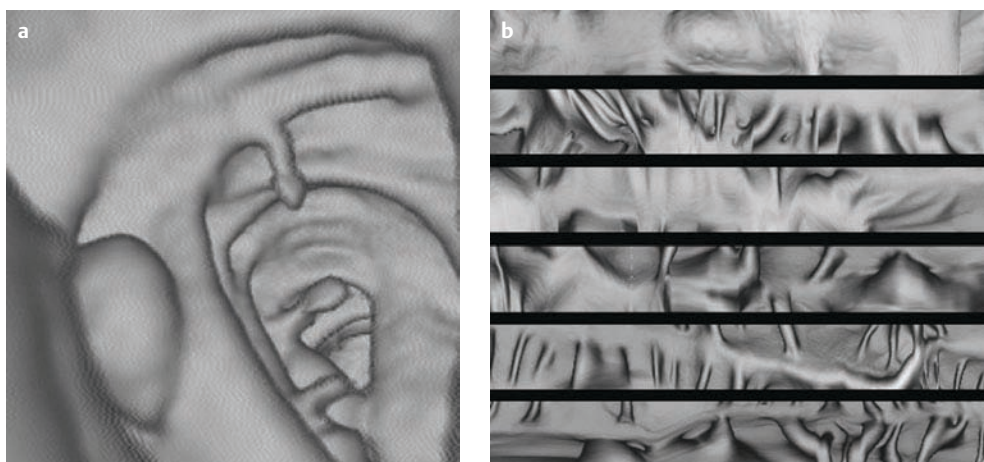


Fig. 9.1a What you see here is an endoscopy-type image reconstructed from spiral CT sections. A small polyp on a long stalk is clearly seen hanging from the roof of this colonic segment. b Modern imaging can do what pathologists do when they

examine an intestine macroscopically: The intestine is cut open along its longitudinal axis and unfolded to check the interior for abnormalities. There is a drawback, though: The bowel must be absolutely clean and that depends wholly on patient compliance.

Table 9.1 Suggestions for diagnostic modalities in gastrointestinal imaging<sup>1</sup>

Clinical problem	Investigation	Comment
<b>Acute abdomen</b>		
Acute abdominal pain (warranting hospital admission and surgical consideration); perforation; obstruction	AXR erect and CXR erect, US	Erect or left-side-down AXR with horizontal beam indicated routinely for gas pattern and free air. US for free fluid.
	CT	To further classify findings.
Palpable mass	US	Often solves the problem.
	CT	Where US is inconclusive.
Acute GI bleeding: hematemesis	Endoscopy	Provides diagnosis of upper GI lesions; allows injection of varices, etc.
	US	Only useful to look for signs of chronic liver disease.
	Angiography	In uncontrollable bleeding. Can accurately direct surgery and transcatheter embolization; may be used as primary treatment
	NM (red cell study)	After endoscopy. Can detect bleeding rates as low as 0.1 mL/min; more sensitive than angiography. Red cell study is most useful in intermittent bleeding.
<b>Diseases of the esophagus and stomach</b>		
Difficulty in swallowing	Barium swallow	Barium studies are still recommended before possible endoscopy; will accurately localize lesions and show the degree of obstruction caused by a stricture and its length. Webs and pouches are well demonstrated. Subtle strictures may be demonstrated by a marshmallow (or other bolus) study. Detailed fluoroscopy or NM needed for motility disorders.
	Video fluoroscopy	For suspected pharyngeal dysfunction in conjunction with speech therapists.
Chest pain ?Hiatus hernia or reflux	Endoscopy	Best for metaplasia and esophagitis because it also allows biopsy.
	pH monitoring	Generally regarded as the "gold standard" to diagnose acid reflux but gives no anatomical information.
	Barium swallow/meal	Although useful to demonstrate hernia, reflux, and their complications, not all such patients need a work-up. Reflux is common and not necessarily the cause of pain. NM may be oversensitive. Increasing use of barium studies before antireflux surgery.
Esophageal perforation	CXR	Will be abnormal in 80%; pneumomediastinum will show in 60%. May be sufficient, unless localization for surgical repair is planned.
	Contrast swallow	Two schools of thought exist: (A) Study should be performed with water-soluble nonionic contrast agents. If no leak is seen, proceed immediately to CT. (B) Study should initially be performed with nonionic contrast agents. If no leak is seen, one should switch to barium for better detail.
	CT	Sensitive for presence of perforation and mediastinal and pleural complications.

AXR, abdominal radiograph; CT, computed tomography; CXR, chest radiograph; ERCP, endoscopic retrograde cholangiopancreatography; GI, gastrointestinal; HIDA, hepatobiliary imino-diacetic acid; MRCP, magnetic resonance cholangiopancreatography; MRI, magnetic resonance imaging; NM, nuclear medicine; US, ultrasound; WBC, white blood cell.

Table 9.1 Suggestions for diagnostic modalities in gastrointestinal imaging<sup>1</sup> (Continued)

Clinical problem	Investigation	Comment
Dyspepsia in the younger patient (e.g., under 45 years)	Imaging (endoscopy/barium meal)	Most patients under 45 years can be treated without complex investigations and will undergo a trial of therapy to lower gastric acidity. Endoscopy, or alternatively barium meal, for those who fail to respond. Other alarming features pointing to early investigation include unintentional weight loss, anemia, anorexia, GI bleeding, pain requiring hospitalization, nonsteroidal anti-inflammatory drugs, vomiting, no improvement following treatment in those positive for <i>Helicobacter pylori</i> .
Dyspepsia in the older patient (e.g., over 45 years)	Imaging (barium meal/endoscopy)	Endoscopy is the modality of choice. The main concern is the detection of early cancer, especially submucosal tumors. If endoscopy is negative and symptoms persist, then barium meal should be considered.
Ulcer follow-up	Endoscopy	Preferred to confirm complete healing and to obtain biopsies (e.g., <i>Helicobacter pylori</i> ) where necessary.
	Barium studies	Not indicated. Scarring precludes accurate assessment.
	Carbon-14 breath test	To assess effect of treatment of <i>Helicobacter pylori</i> .
<b>Diseases of the small bowel</b>		
Small-bowel obstruction	AXR	Indicated for primary diagnosis.
	Contrast studies	With nonionic agents can determine both the site and completeness of obstruction.
	CT	Some centers use CT in this situation, which can determine level and likely cause.
Small-bowel obstruction: chronic or recurrent	Small-bowel barium enema	Examination of choice; will reveal presence and level of obstruction in most cases; may suggest cause.
Small-bowel disease suspected (e.g., Crohn disease)	Small-bowel barium enema or follow-through	Investigation of choice to establish extent of disease prior to surgery, any fistula, cause of obstruction. Some centers use US to assess bowel wall.
	NM (white cell study)	Labeled white cell scintigraphy may reveal activity and extent of disease. Complementary to barium studies.
	MR	Increasing use as modality for extramural extent and to keep radiation dose low.
	CT	Reserved for complications.
Malabsorption	Barium small-bowel follow-through	Imaging is not required for the diagnosis of celiac disease but may be indicated for jejunal diverticulosis or when biopsy is normal/equivocal.
<b>Diseases of the large bowel</b>		
Large-bowel tumor or inflammatory bowel disease: pain, bleeding, change in bowel habit, etc.	Barium enema	Colonoscopy is often first-line investigation. Air-contrast enema is useful if the bowel is properly prepared. Furthermore, all patients should undergo rectal examination to assess suitability for barium enema and to exclude a low rectal tumor. Good practice requires a sigmoidoscopy before barium enema. Defer barium enema for 7 days after full-thickness biopsy via a rigid sigmoidoscope. Biopsies taken during flexible sigmoidoscopy are usually superficial and require no delay of enema.

AXR, abdominal radiograph; CT, computed tomography; CXR, chest radiograph; ERCP, endoscopic retrograde cholangiopancreatography; GI, gastrointestinal; HIDA, hepatobiliary imino-diacetic acid; MRCP, magnetic resonance cholangiopancreatography; MRI, magnetic resonance imaging; NM, nuclear medicine; US, ultrasound; WBC, white blood cell.



Table 9.1 Suggestions for diagnostic modalities in gastrointestinal imaging <sup>1</sup> (Continued)		
Clinical problem	Investigation	Comment
	CT	Some centers use CT for the frail elderly patient. Increasing role of CT colonoscopy, also called virtual colonoscopy, in large centers.
Large-bowel obstruction: acute	AXR	May suggest diagnosis and likely level.
	Contrast enema	Single contrast (ideally water-soluble contrast medium) study can confirm diagnosis and level of obstruction and may indicate likely cause. May exclude “pseudo-obstruction.” Can be therapeutic in sigmoid or cecal volvulus.
	CT	Some centers use CT for the frail elderly patient. Increasing role of CT colonoscopy in large centers.
Inflammatory bowel disease of colon: acute exacerbation	AXR	Often sufficient to determine disease severity and extent.
	NM (white cell study)	Will reveal activity and extent of disease.
	Barium enema	Dangerous when toxic megacolon is present; unprepared enema in selected cases after discussion with radiologist.
Inflammatory bowel disease of the colon: follow-up	Colonoscopy	Preferred to identify developing dysplasia, stricture, carcinoma in those at high risk.
	Barium enema	In complex postoperative situations and when fistulae are present.
Palpable abdominal mass	US	Usually solves the problem and is very reliable in thin patients, right upper quadrant, and pelvis.
	CT	Alternative to US and useful to exclude a lesion; particularly good in large patients.
<b>Diseases of the liver and biliary system</b>		
Hepatic metastases	US	Should be the initial investigation but metastases may show the same reflectivity as the hepatic parenchyma and thus be missed. Use of newer ultrasound contrast agents may help distinguish lesions but these are not available in all countries. Also allows biopsy. Newer therapies require more sensitive test.
	CT	Significantly more sensitive than US, particularly in smaller lesions. Essential for accurate staging in preoperative assessment before hepatic resection.
	MRI	With liver-specific contrast agents even more sensitive than CT. Accurate characterization of small lesions. Widely used in preoperative assessment before hepatic resection.
Liver hemangioma (e.g., on US)	US	Frequent incidental finding.
	CT/MRI	Both reliably show further characteristic features of hemangioma and many other solitary hepatic lesions.
Jaundice	US	Sensitive for bile duct dilatation but dilatation may be subtle in early obstruction and sclerosing cholangitis. Shows gallstones and most forms of hepatic disease. US also shows the level and cause of any obstruction to common bile duct. Discuss subsequent investigations (CT, ERCP, MRCP, etc.) with radiologist.
	ERCP	Will confirm and remove ductal stones. Gold standard for intrahepatic duct change in sclerosing cholangitis.

AXR, abdominal radiograph; CT, computed tomography; CXR, chest radiograph; ERCP, endoscopic retrograde cholangiopancreatography; GI, gastrointestinal; HIDA, hepatobiliary imino-diacetic acid; MRCP, magnetic resonance cholangiopancreatography; MRI, magnetic resonance imaging; NM, nuclear medicine; US, ultrasound; WBC, white blood cell.

Table 9.1 Suggestions for diagnostic modalities in gastrointestinal imaging<sup>1</sup> (Continued)

Clinical problem	Investigation	Comment
	CT	To further assess US-proven obstructive jaundice, especially below the hilar level. Crucial in staging malignant hilar level obstruction. May predict unresectability in pancreatic cancer.
	MRI, MRCP	In hilar level obstruction MR cholangiopancreatography is the investigation of choice. Depicts pattern and extent of duct involvement for pretherapy staging. If US shows no definite duct stones, MRCP should precede ERCP.
	Endoscopic US	Most accurate method for detection of small duct stones and small papillary and peripapillary tumors. Permits biopsy of pancreas without risk of seeding.
Biliary disease (e.g., gallstones, post-cholecystectomy pain)	US	Investigation of choice for exclusion or demonstration of gallstones and acute cholecystitis. Initial study in biliary pain. Cannot exclude common duct stones. I.v. cholangiography is obsolete.
	CT	Useful in evaluation of gallbladder wall and masses.
	MRCP	Where ductal calculi are suspected but not confirmed by US; and in post-cholecystectomy pain.
Postoperative biliary leak	US	Initial method in suspected leak, will show size and location of collections.
	CT	CT is an important modality to assess for leaks, especially after complex biliary/liver surgery and/or immediately postoperatively when there is no good sonic window in the upper abdomen.
	ERCP	Definitive method to detect site of leakage and for stent placement.
	NM	HIDA will show activity at site of leak.
<b>Diseases of the pancreas</b>		
Acute pancreatitis	AXR	Only if diagnosis is in doubt; then needed to exclude other causes acute abdominal pain. Some patients presenting with acute pancreatitis have underlying chronic pancreatitis, which may cause visible calcification.
	US	To show gallstones and to diagnose and follow pseudocyst development, especially good in thin patients.
	CT, MR	Reserved for clinically severe cases (to assess extent of necrosis), in patients who do not improve on treatment, or if there is uncertainty about the diagnosis. Some centers use MR, especially if repeated follow-up is likely.
Chronic pancreatitis	AXR	To show calcification.
	US	May be the definitive method in thin patients.
	CT	Will show calcification to good effect.
	ERCP, MRCP	ERCP shows duct morphology, but considerable risk of acute pancreatitis. MRCP (particularly with secretin) shows ductal changes and may indicate exocrine function.
Pancreatic tumor	US	Especially in thin patients and for lesions in the head and body.
	CT	CT or MR are good in the larger patient and where US is equivocal or where precise staging is needed.

AXR, abdominal radiograph; CT, computed tomography; CXR, chest radiograph; ERCP, endoscopic retrograde cholangiopancreatography; GI, gastrointestinal; HIDA, hepatobiliary imino-diacetic acid; MRCP, magnetic resonance cholangiopancreatography; MRI, magnetic resonance imaging; NM, nuclear medicine; US, ultrasound; WBC, white blood cell.

Table 9.1 Suggestions for diagnostic modalities in gastrointestinal imaging<sup>1</sup> (Continued)

Clinical problem	Investigation	Comment
	Endoscopic US	May provide detailed presurgical staging information and permits biopsy.
	ERCP	Demonstrates strictures, permits biopsy and stent placement.
Insulinoma	MRI, CT, angiography	When biochemical tests are convincing. MRI is emerging as the best examination, although arterial phase spiral CT is promising, especially in combination with radiotracers in hybrid imaging systems. Most centers seek two positive investigations before surgery (out of CT/MRI/angiography).
	US	Endoscopic and intraoperative US are also useful.
<b>Other problems</b>		
Previous upper GI surgery (recent)	Water soluble contrast medium study	To assess anastomosis. If leak is not detected and clinical concern remains, immediate subsequent CT is more sensitive.
Previous upper GI surgery (old; symptoms of acid reflux)	Endoscopy	Best for assessment of gastric remnant (gastritis, ulceration, recurrent tumor, etc.). Barium studies not normally indicated.
Previous upper GI surgery (old; dysmotility, obstructive symptoms)	Barium studies	Shows surgical anatomy and may demonstrate dilated afferent loop, narrowed anastomoses, internal hernias, closed loops, etc.
	CT	May be needed to assess extraluminal disease.
Intestinal blood loss, chronic or recurrent	Barium small-bowel enema	Only after negative upper and lower tract endoscopy.
	NM (red cell or Meckel study) and/or angiography	When all other investigations are negative.
Constipation	AXR, intestinal transit studies	AXR may be useful in geriatric and psychiatric specialties to show extent of fecal impaction. Intestinal transit studies using radiopaque markers can confirm normal transit.
	Evacuation proctography	In some patients constipation is secondary to an evacuation disorder
Abdominal sepsis; pyrexia of unknown origin (PUO)	US	May be the first and definitive examination, especially when there are localizing signs, for the subphrenic and subhepatic spaces and the pelvis. Not as good for surveillance of the retroperitoneal spaces and organs.
	CT	CT is probably the best test overall: infection and tumor are usually identified and excluded. Also allows biopsy of nodes or tumor and drainage of collections (especially recent postoperative).
	Labeled WBC, gallium	NM is particularly good when there are no localizing features: good for chronic postoperative sepsis; gallium-labeled radiotracer will accumulate at sites of tumor (e.g., lymphoma) and infection.

<sup>1</sup>Modified after: RCR Working Party. *Making the best use of a Department of Clinical Radiology. Guidelines For Doctors*, 5th ed. London: The Royal College of Radiologists, 2003.

AXR, abdominal radiograph; CT; computed tomography; CXR, chest radiograph; ERCP, endoscopic retrograde cholangiopancreatography; GI, gastrointestinal; HIDA, hepatobiliary imino-diacetic acid; MRCP, magnetic resonance cholangiopancreatography; MRI, magnetic resonance imaging; NM, nuclear medicine; US, ultrasound; WBC, white blood cell.

One “ancient” study has withstood the test of time very well owing to its high diagnostic value, its speed, and its availability: the **plain radiograph of the abdomen**. It remains the essential first-step modality besides ultrasound and CT in the diagnostic assessment of patients with abdominal pain. The abdominal radiograph is one of the studies young doctors on call or in the emergency room may have to face on their own without the support of an expert radiologist. Substantial observations can be made that may have important therapeutic consequences. Nobody will expect you to interpret an abdominal CT or MRI, or even a barium swallow, but you should be able to do basic interpretation of an abdominal radiograph. You will learn the essentials for this task—besides a lot of other things—in this chapter. The numerous very specific procedures will be explained to the extent that is necessary as we go along. The key to a good diagnostic work-up is, as always, to choose the appropriate procedure for the right reason (Table 9.1).

## 9.1 How Do We Analyze an Abdominal Radiograph?

The abdominal radiograph is almost always evaluated in combination with a chest radiograph—for two good reasons:

- On the chest radiograph the directly subdiaphragmatic regions of the abdomen may be better appreciated because exposure parameters optimized for the lung are also well suited to imaging this area.
- Free intra-abdominal air rises to the nondependent portion of the abdomen and is therefore easily detected under the diaphragm on an upright radiograph. Other conditions that can present with abdominal pain as the cardinal symptom may be diagnosed, such as a basilar pneumonia.

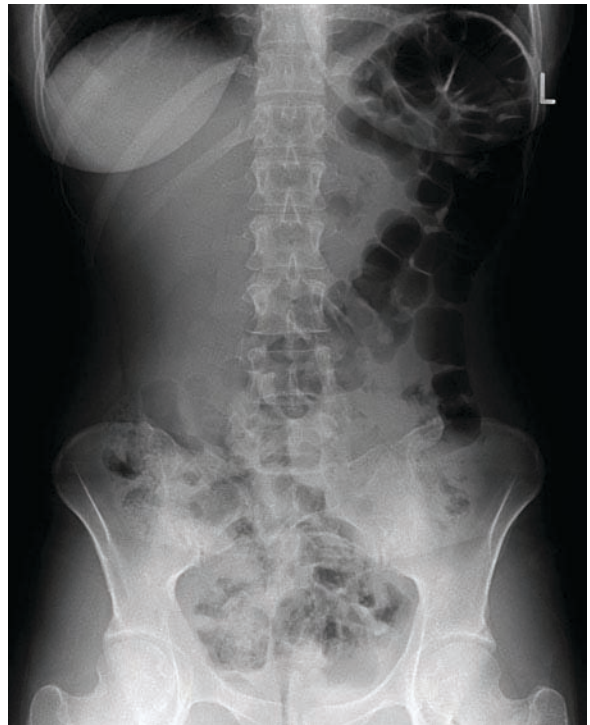
If possible at all the chest radiograph should be performed with the patient standing up. The same is true for the abdominal radiograph. If the patient cannot stand, the examination should combine the supine radiograph with an additional exposure suited to demonstrate potential air–fluid levels and free air, e.g., in left lateral decubitus position with the beam directed through the patient in a horizontal fashion (parallel to the table).

### What Can You Evaluate on an Abdominal Radiograph?

The **liver** can be differentiated from the rest of the abdominal contents and its size can be roughly estimated. While frequently there are intestinal loops projecting over the spleen, this is an uncommon finding in the right upper quadrant of the abdomen (Fig. 9.2a). An exception to this rule is the interposition of colon between the right diaphragm and the liver, also termed Chilaiditi syndrome (Fig. 9.2c).

## Abdominal Film

### a Normal radiograph



### b Retroperitoneum

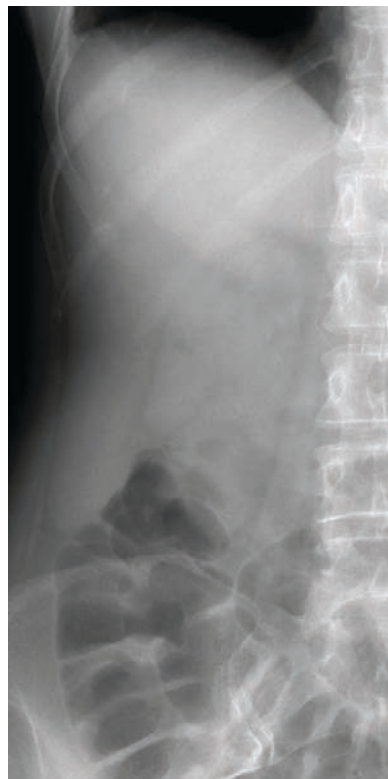


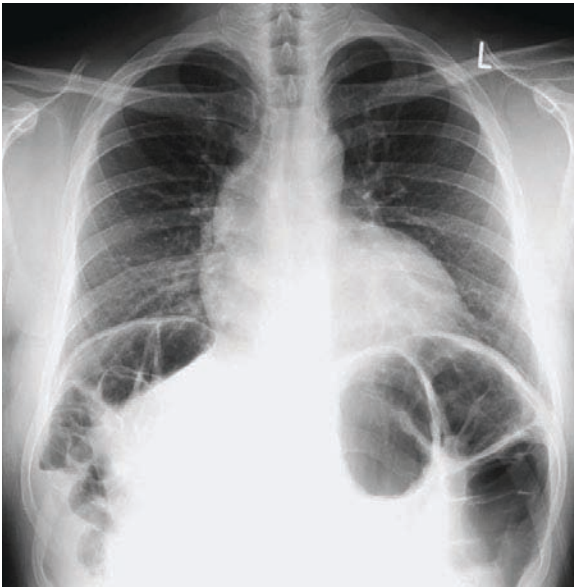Fig. 9.2 a–e



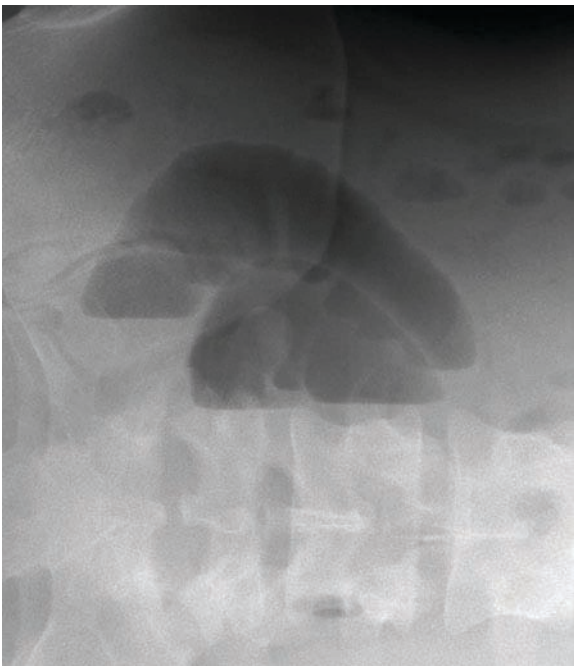


## Abdominal Film

## c Chilaiditi syndrome



## e “Sentinel loops”



## d Chronic pancreatitis

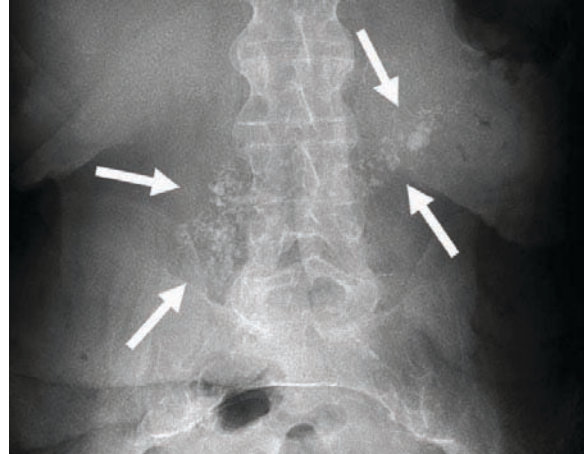


Fig. 9.2a This is a normal abdominal film. The liver shadow occupies the right upper abdomen. Its inferior margin can only be guessed on this film. The peritoneal fat stripe along the right lateral abdominal wall is visible, however. The spleen in the left upper abdomen is completely disguised by the splenic flexure of the colon. Almost the whole colon is filled with air. Stool is seen in the cecum, the descending colon, and the sigmoid colon. The small bowel is not visible at all. The gastric bubble is barely appreciated medial to the splenic flexure. In this slim patient the retroperitoneal fat is not abundant enough to clearly outline the contours of the kidneys and the iliopsoas muscle. **b** The lower margin of the liver, the contour of the kidney, and the border of the iliopsoas muscle are beautifully depicted in this patient. **c** In this patient, air-filled large-bowel loops are projecting over the liver. This entity is called Chilaiditi syndrome and tends to be an incidental finding without symptoms. **d** In chronic pancreatitis typical calcifications occur in the parenchyma (arrows) and have to be differentiated from atherosclerosis of the splenic artery. **e** This cut-out of an abdominal radiograph of a patient positioned on the left side and taken with a horizontal beam shows air-filled small-bowel loops with air-fluid interfaces—so-called “sentinel loops.” They indicate disturbances of the intestinal peristalsis. The difference in fluid level in the larger loop hints at peristalsis working to overcome an obstacle: this is a sign of a mechanical (dynamic) bowel obstruction or early obstructive ileus. The colon is devoid of air: the obstruction must be somewhere in the distal small bowel.

The structures of the retroperitoneum are easily distinguished as long as they have interfaces with the retroperitoneal fat: the contours of the **kidneys** and the **iliopsoas muscle** are regularly appreciated; the **pancreas** tends to be discernible only if its parenchyma contains punctate calcifications, for instance due to chronic pancreatitis (Fig. 9.2d).

The **urinary bladder** can be delimited in the lower pelvis if it is filled well. When fully expanded it tends to lift the intestines out of the pelvis.

**Calcifications** are frequently found in the following locations:

- **Vascular walls:** Particularly frequent in the aorta, the celiac artery and its branches, in particular the splenic artery and in the iliac arteries. Oval calcifications in the pelvis are often due to phleboliths in pelvic veins, particularly common in the veins next to the uterus and in the venous plexus around the bladder.
- **Parenchymal organs:** Kidneys (kidney stones), uterus (fibroids), liver and spleen (after granulomatous infec-

tions such as histoplasmosis), pancreas (chronic pancreatitis).

- Hollow organs: Particularly frequent in the gallbladder lumen (gallstones) or wall (porcelain gallbladder).
- Lymph nodes: Particularly frequent in the mesentery.

The **distribution of the intestinal air** and the thickness of the intestinal walls is of special importance. Air in the small bowel is rare in the healthy adult. It is an obligatory (regular) finding in neonates and frequent in small children. The stomach and the colon routinely contain varying amounts of air. The differences in caliber and wall structure (valvulae conniventes—or Kerckring folds—in the small bowel and haustral folds in the large bowel) make it easy to differentiate small and large bowel in most cases. Any air outside the intestinal lumen is abnormal and should prompt careful correlation with the patient's history: if surgery has recently been performed, free air may be related to the procedure. Careful comparison with prior radiographs is warranted if these are available, to ensure that this finding is not new or increasing.

The **thickness of the bowel wall** is evaluated by observing the distance between two neighboring loops. In inflammatory and ischemic processes of the bowel, the thickness of the wall increases. If intramural gas (mostly in the form of small bubbles like a “string of pearls” or as streaks in the bowel wall, particularly in dependent parts of the bowel wall) is found, further diagnostic measures need to be taken. Although there is a benign condition termed “pneumatosis intestinalis,” characterized by air in the bowel wall, this finding may also be associated with life-threatening conditions such as intestinal infarction or severe inflammation of the intestine that need to be excluded.

The **amount and distribution of stool** throughout the colon should also be noted. Patients with severe constipation may present with acute abdominal pain.

### Why Are You Interested in the Standard Chest Radiograph in a Patient with Abdominal Pain?

The areas under the diaphragm are of particular interest when confronted with abdominal symptoms: Air seen underneath the right hemidiaphragm (above and surrounding the liver) is intraperitoneal by definition. Free air in the peritoneum, of course, also reaches the underside of the left hemidiaphragm, but there the air in the stomach and in the splenic flexure of the colon may obscure it and can often not be distinguished from true free air, which leaves too much room for mistakes. For that reason, in patients unable to stand, the abdominal radiograph is performed with the patient turned all the way up on their left side: potential free air then rises to the right into the nondependent space between the diaphragm and the liver. Patients should remain in that position for at least 5 minutes before the radiograph is taken because it takes time for the air to rise into the right upper quadrant of the abdomen.

### I See an Abnormality—What Do I Do Now?

First reflect on whether the perceived abnormality may be clinically relevant in that particular patient; put the observation into context with history and findings on clinical examination.

Most **calcifications** in the abdomen are of no clinical significance for the health of the patient. Exceptions are the calcifications seen in the expected location of the pancreas (chronic pancreatitis) and the ureter (renal colic). The combination of clinical findings and history in a given patient will often guide the diagnostic process toward the dominant clinical problem.

**Free intraperitoneal air** is very relevant finding and indicates the perforation of a hollow viscus. (Just a few milliliters of air is detectable!) But be aware: It may also be seen in patients who have undergone recent abdominal surgery, a common situation in a hospital setting. As mentioned above, careful comparison with prior postoperative radiographs is warranted, if these are available, to ensure that this finding is not new or increasing. In case of doubt, a phonecall to the clinician taking care of the patient is good practice and will often clarify the significance of the finding as well as help determine the need for further imaging or even surgical intervention. So do not ring the grand alarm bell right away.

**Air in the retroperitoneum** is always pathological. The contours of the kidneys, the pararenals, and the iliopsoas muscle become very distinct. Reasons may be the perforation of a retroperitoneal bowel segment (duodenum, parts of the colon and rectum) or the transit of air from the mediastinum into the retroperitoneal space in mediastinal emphysema.

The analysis of the **distribution of bowel gas** can help in the diagnosis of a number of entities:

An air-distended stomach is frequently found after *resuscitation* and may point to an earlier false intubation. It doesn't hurt to mention the distended stomach to the referring physician, because placement of a nasogastric tube can often provide relief to the patient.

Wide, air-filled small-bowel loops indicate a disturbance of the bowel peristalsis and are due to either a partial or complete ileus or small-bowel obstruction.

! Differentiation between an ileus and a small-bowel obstruction is most readily afforded by auscultation: the absence of bowel sounds suggests an ileus (or extremely advanced obstruction), while high-pitched active bowel sounds suggest a mechanical bowel obstruction. Remember that even (!) radiologists may consider using the stethoscope every now and then to help make the right diagnosis.

The actual image appearance of the air- and fluid-filled small-bowel loops—also called “sentinel loops”—(Fig. 9.2e) hints at the character of the disturbance: If a mechanical obstruction is present, the intestinal peristalsis continues and tries to force the bowel content across the point of obstruction. A characteristic sentinel loop shows air–fluid interfaces at significantly different levels.

The air-filled bowel segments are naturally located proximal to the point of obstruction because the air distal to it is absorbed in time.

If the peristaltic problem is due to a paralysis or if the obstructed bowel is eventually exhausted, the air–fluid interfaces in the sentinel loops tend to remain at the same level: an adynamic ileus is present. (To observe the potential difference in fluid levels, the patient must remain motionless in the above-described positions for a few minutes.) Bowel sounds are typically absent in this situation. Extremely dilated air-filled large-bowel segments may be seen in **toxic megacolon**, in **large-bowel obstruction due to tumor**, or in **volvulus** (torsion of the bowel around its mesenteric root). The more chronic the problem, the larger the intestines can appear.

Now let us try this out on the first patient.

## 9.2 Patient with Acute Abdominal Pain

### Checklist: Acute Abdomen

- Is the patient standing up or positioned on the left side, and is the x-ray beam horizontal?
- Do you see air outside of the gastrointestinal tract?
- Is the air within the gastrointestinal tract normally distributed?
- Are “sentinel loops” with air–fluid levels of differing height present?
- Are there characteristic calcifications present?

### Mutiny in the Belly

The paramedics found Melissa Stonegrave (51) helpless on a park bench. Passersby had noticed her as she was lying on her side wincing and calling for help. The paramedics noted that she complained of severe abdominal pain. In the emergency room she was carefully examined. A nasogastric tube was inserted because the patient had vomited. Giufeng is looking through some rather boring cases of the teaching file when x-ray technician Thomas brings Mrs. Stonegrave's radiographs over from the emergency room for her to review. Giufeng puts the chest radiograph on the view-box first, but sees nothing abnormal and puts it to the side. Pulmonary problems such as a basal pneumonia as a cause of her symptoms do not seem to be present. She grabs the abdominal radiograph and begins a careful analysis (Fig. 9.3).

### → What is your diagnosis?

**Free intraperitoneal air:** In case of free intraperitoneal air, the perforation of a hollow organ such as the stomach, the duodenum (in ulcer disease), or the large bowel (for example in diverticulitis), or a traumatic perforation must

### The Case of Melissa Stonegrave

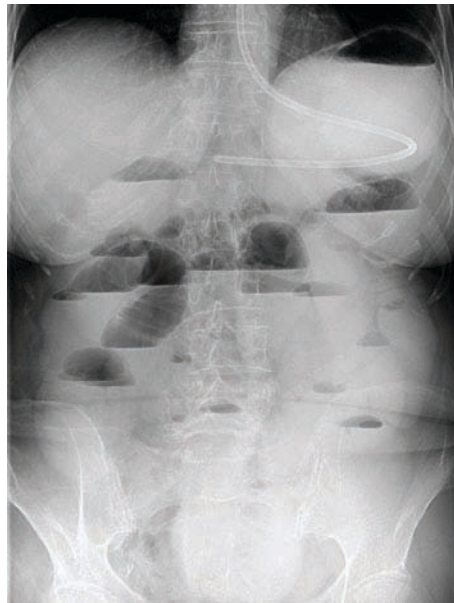

Fig. 9.3 Have a look at the abdominal radiograph of Melissa Stonegrave. Which finding grabs your attention right away?

be considered (Fig. 9.4). It may, however, also be residual air after a surgical intervention in the abdomen, which may persist for days and weeks.

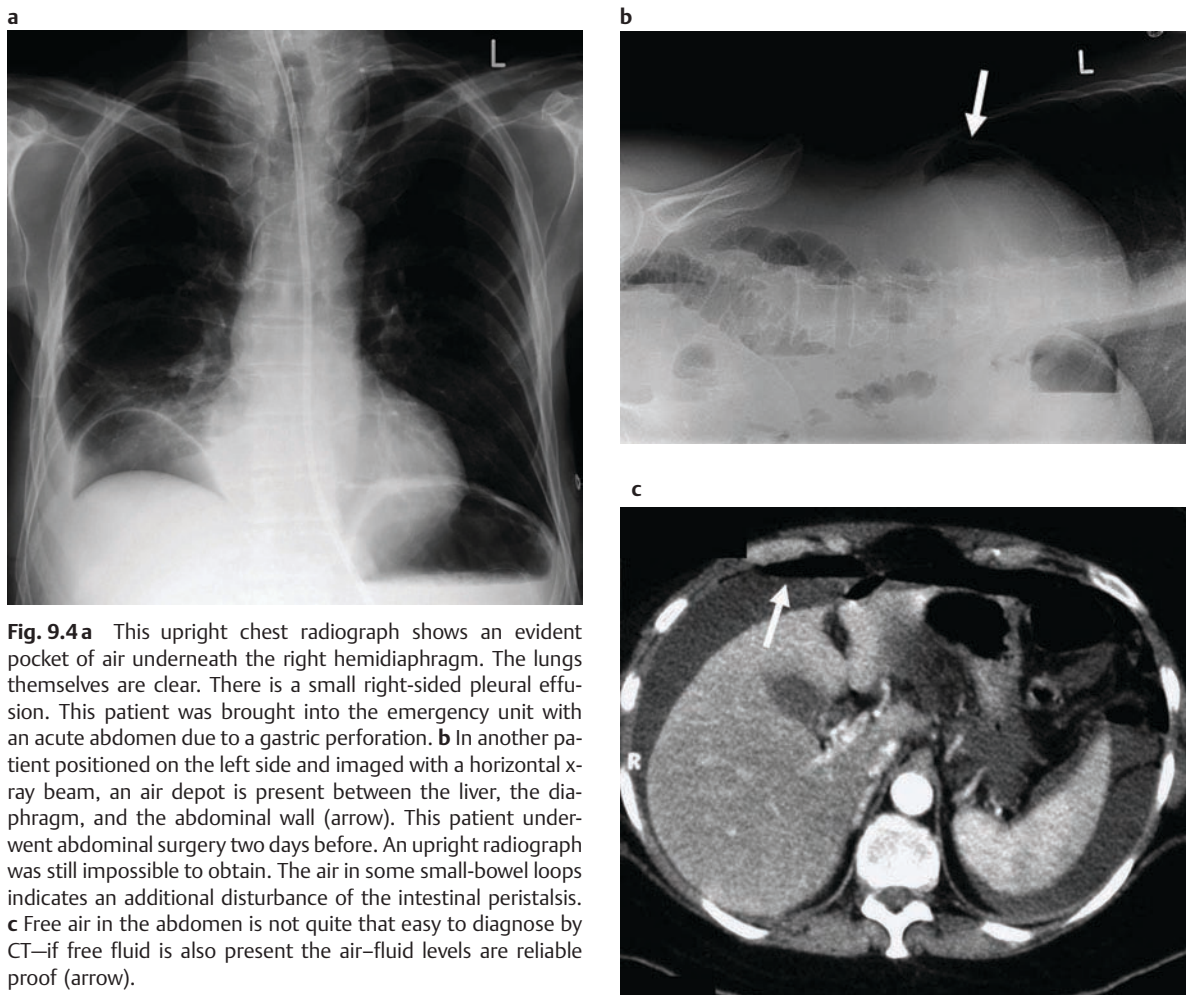
**Air in the retroperitoneum:** Retroperitoneal air is much less frequent and occurs, for example, in perforations of retroperitoneal bowel segments such as the duodenum, colon, or rectum (Fig. 9.5). It can also occur in severe infections with gas-forming bacteria, e.g., emphysematous pyelonephritis in diabetic patients.

**Air in the bowel wall:** Air in the bowel wall can be observed in pneumatosis intestinalis (Fig. 9.6a, b), a benign asymptomatic condition, or in the late phase of bowel ischemia (Fig. 9.6c) that goes along with severe abdominal pain. In extreme cases the air reaches the portal venous system of the liver via the mesenteric veins (Fig. 9.6d). In the olden days this used to be a “signum mali ominis,” an ominous sign indicating a deleterious course of the disease. In times of ubiquitous CT, the sign is much more often seen and is fortunately less prognostic.

**Bowel obstruction (mechanical ileus):** Also termed mechanical or dynamic ileus, this condition is characterized by a mechanical obstruction of the intestinal lumen (Fig. 9.7a). In the small bowel, postoperative fibrous bands, so-called adhesions, are the most frequent cause of obstruction followed by incarcerated hernias (inguinal, femoral, umbilical, and incisional). In children an intussusception may be the culprit. Gallstones that have perforated into the bowel lumen (Fig. 9.7b) may be a cause of obstruction that can be directly visualized on the radiograph. In the large bowel, colorectal carcinomas, volvulus of the

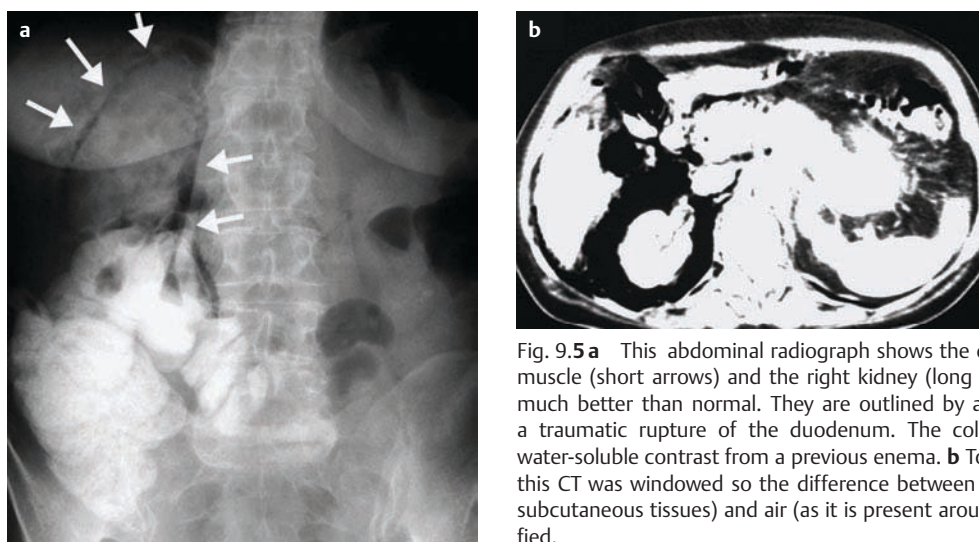


## Free Intraoperative Air



**Fig. 9.4a** This upright chest radiograph shows an evident pocket of air underneath the right hemidiaphragm. The lungs themselves are clear. There is a small right-sided pleural effusion. This patient was brought into the emergency unit with an acute abdomen due to a gastric perforation. **b** In another patient positioned on the left side and imaged with a horizontal x-ray beam, an air depot is present between the liver, the diaphragm, and the abdominal wall (arrow). This patient underwent abdominal surgery two days before. An upright radiograph was still impossible to obtain. The air in some small-bowel loops indicates an additional disturbance of the intestinal peristalsis. **c** Free air in the abdomen is not quite that easy to diagnose by CT—if free fluid is also present the air–fluid levels are reliable proof (arrow).

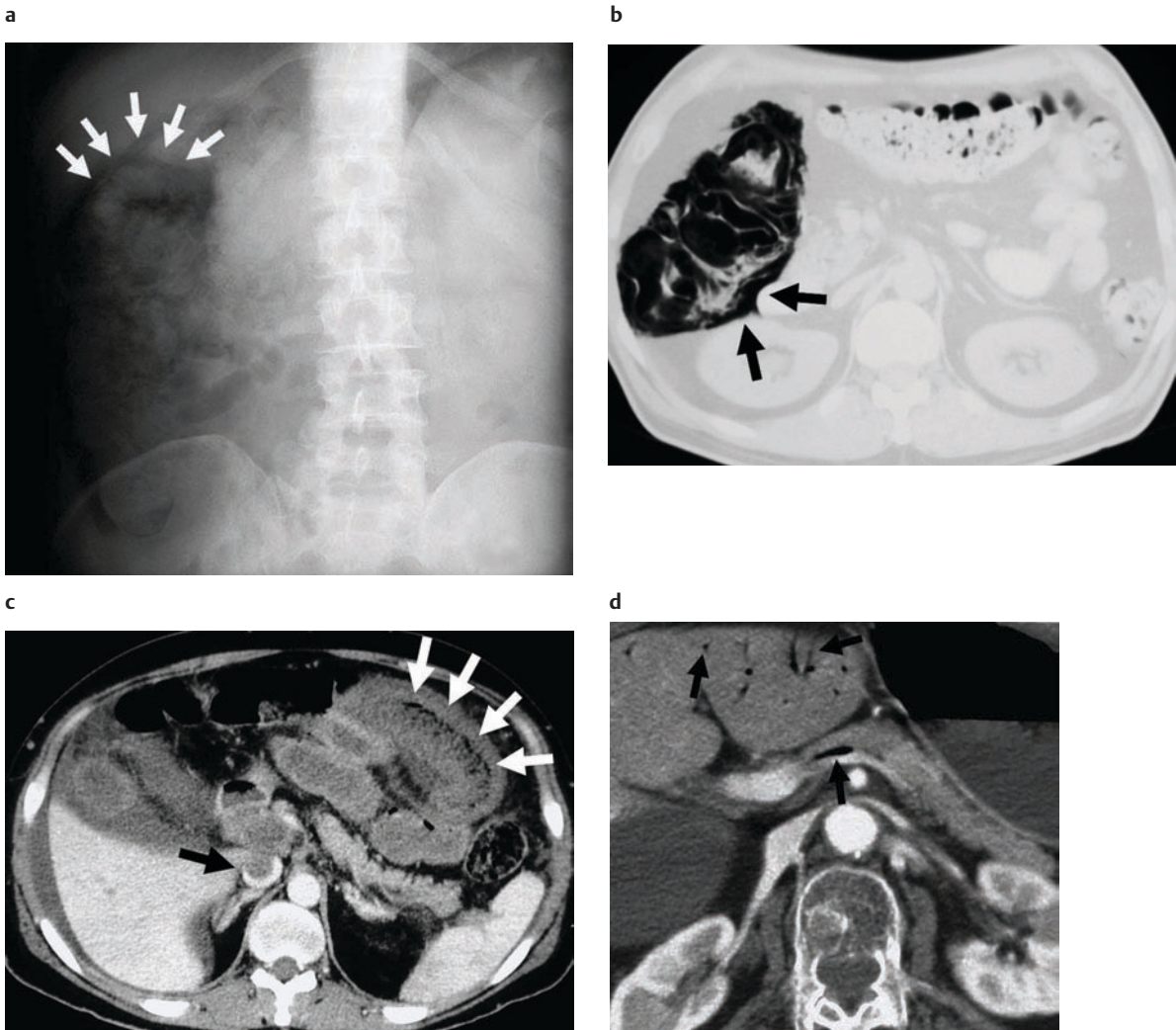
## Air in the Retroperitoneum



**Fig. 9.5a** This abdominal radiograph shows the contour of the iliopsoas muscle (short arrows) and the right kidney (long arrows) extremely well, much better than normal. They are outlined by air that originated from a traumatic rupture of the duodenum. The colon is filled with some water-soluble contrast from a previous enema. **b** To confirm the diagnosis, this CT was windowed so the difference between fat (as it is seen in the subcutaneous tissues) and air (as it is present around the kidney) is amplified.



## Air in Bowel Wall



**Fig. 9.6a** In the right upper abdomen several layers of air (arrows) are present around the intestinal lumen. **b** The CT confirms the presence of air in the bowel wall (arrows). This patient had an acute myelogenous leukemia (AML) but no intestinal symptoms whatsoever at that time and later. This turned out to be pneumatosis intestinalis. **c** The CT section in another patient with severe abdominal pain displays a marked thickening of the bowel wall with small air deposits in it—much like a “string of beads” (white arrows): This bowel segment is gangrenous.

In addition, thin rims of ascites are seen around the liver and also around the spleen. By the way: The contrast defect in the vena cava (black arrow) is not a thrombus but is a result of laminar flow! Blood rich with contrast medium from the kidneys flows along uncontrasted blood from the lower extremities. **d** Once there is air in the necrotic bowel wall, it can also enter the mesenteric veins and eventually the hepatoportal system (arrows).

sigma (Fig. 9.7c) or cecum and diverticulitis must be excluded as the cause of the ileus. Enemas with water-soluble contrast media are essential in the radiographic differentiation of these entities in the large bowel. CT of the abdomen with multiplanar 3D image reconstructions on a workstation can help determine the point of obstruction as well as provide clues to the underlying cause.

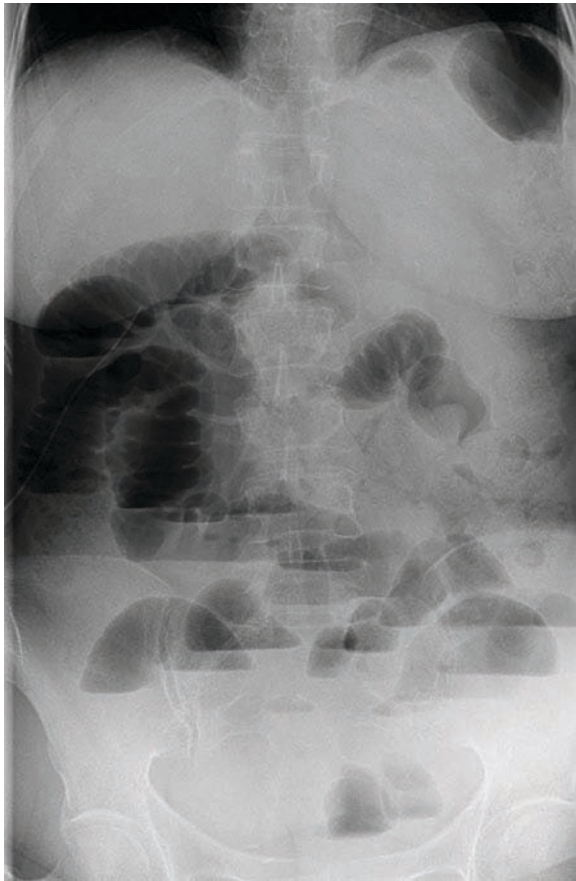
**Paralytic ileus:** The paralytic ileus may be due to a number of different conditions (Fig. 9.8). It is also the pathophysiological end point of a persisting untreated bowel obstruction.

It may be seen after surgical interventions in the abdomen, after abdominal trauma, and in electrolyte imbalances, sepsis, peritonitis, or infiltration of the mesentery by tumor.

**Acute pancreatitis:** An acute pancreatitis is not normally diagnosed on the abdominal radiograph. The signs of recurring or chronic pancreatitis may, however, be visible and point the diagnostic work-up in the right direction (see Fig. 9.2d).

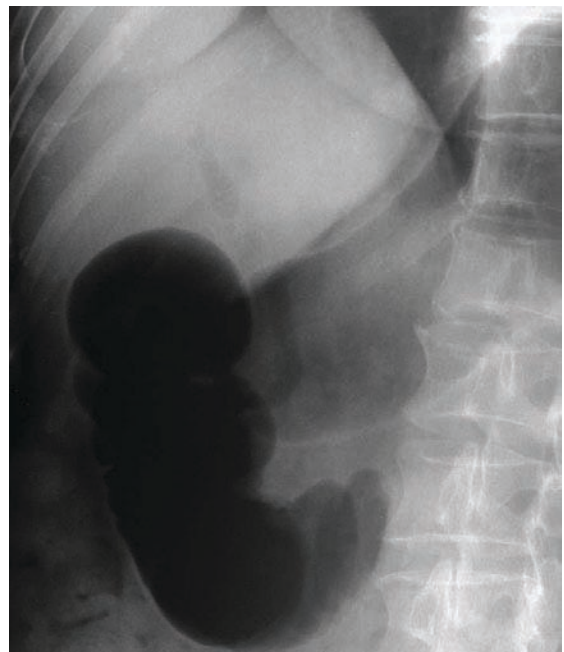
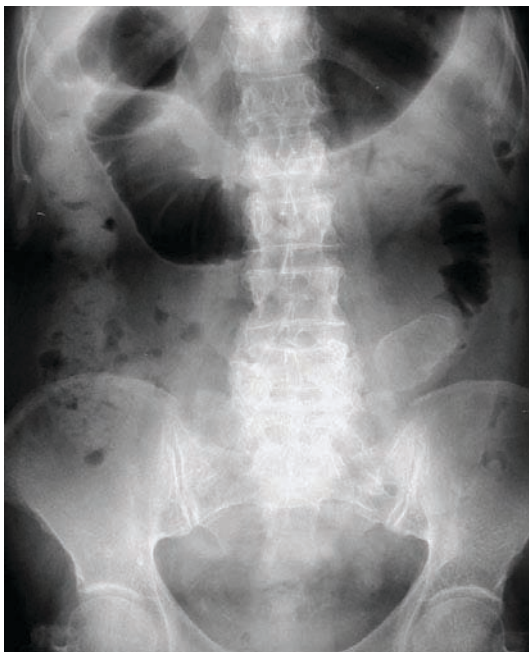## Mechanical Ileus

### a Colon carcinoma



**Fig. 9.7 a** Numerous sentinel loops with air-fluid levels of varying heights indicate a mechanical (dynamic) ileus. The colon is essentially free of air. This was an obstruction due to a colon carcinoma. **b** Air is seen in the duodenum and proximal jejunum, almost none in the colon (left). This looks like a jejunal obstruction. The reason is a giant gallstone that has found its way into the jejunum. Can you see it above the left iliac crest? On its way into the jejunum the gallstone has created a communication (right) through which air seeps into the biliary system. Note the air-filled common bile duct coursing toward the distended duodenum! Air may also be seen in the biliary tract after the rather frequent therapeutic dilation of the papilla of Vater and must be differentiated from air in the portal system as an ominous sign of bowel ischemia. **c** In another patient an extremely dilated and air-filled bowel loop (left) is identified as sigmoid colon owing to its location and the obvious haustration. The colon is nicely outlined by air; the rectum shows no air at all. This is a sigmoid volvulus, a torsion of the sigma around its mesenteric root. The result is, of course, mechanical bowel obstruction. The configuration of the bowel in this entity is reminiscent of the underside of the “bean” that helps us through many a day: It is called the “coffee-bean sign.” The volvulus is confirmed with the help of an enema with water-soluble contrast. We see a “bird’s-beak” like configuration of the contrast column at the rectosigmoidal transition (right). ▶

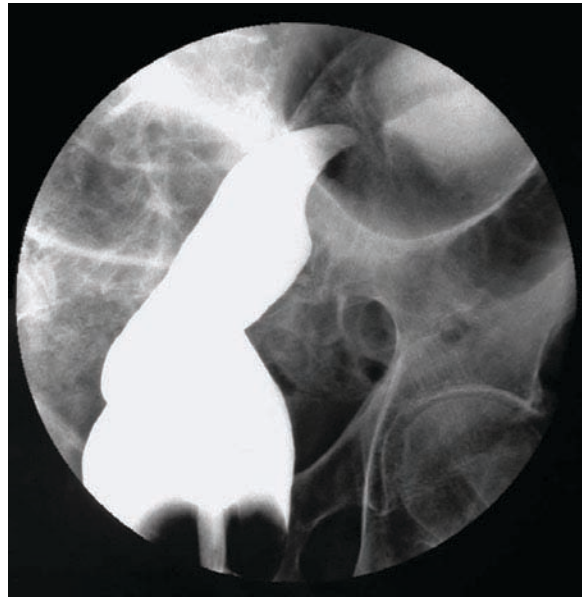
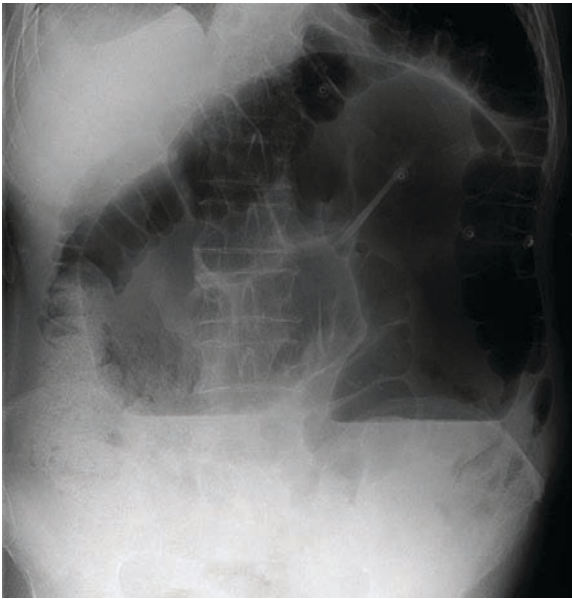
### b Gallstone



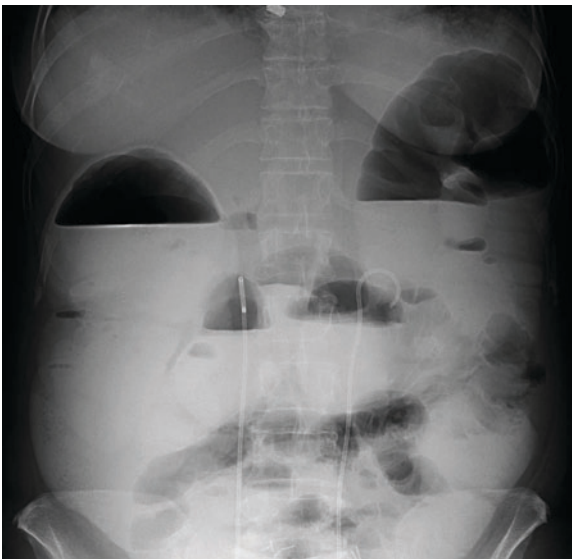

## Mechanical Ileus

### c Volvulus



## Paralytic Ileus



**Fig. 9.8** In this cancer patient the diffuse spread of cancer in the retroperitoneum has necessitated stenting of both ureters to keep urine flowing from kidneys to the bladder. Now a paralytic ileus has developed on top of that: distended bowel loops with air–fluid interfaces that tend to have the same levels in one loop and that seem to be present everywhere. Note: Paralytic ileus is usually diagnosed with a stethoscope! Imaging is not really needed here.

→ **Diagnosis:** Giufeng has not found any free air in the peritoneum or retroperitoneum of Mrs. Stonegrave. However, she thinks that the distribution of air in the intestines is grossly abnormal. The colon is completely free of air, while the small bowel shows many sentinel loops with air–fluid levels of differing heights. It is quite clear to her that a mechanical bowel obstruction is present; air in the colon has been absorbed or passed. Giufeng diagnoses a dynamic, mechanical ileus on the basis of an obstruction of the small bowel or the proximal colon. As it turns out, Melissa Stonegrave had undergone a complicated cholecystectomy a few years earlier. During surgery, adhesions were found to be the cause of the small-bowel obstruction.

! Most bowel obstructions are actually treated conservatively with a nasogastric tube and observation. In fact, CT allows us to stratify patients into a surgical versus a non-surgical group by detecting the presence or absence of ischemia, portal venous gas, extraluminal disease, etc., which clearly represents an advance over the olden times when the clinical picture (signs of sepsis, shock, acidosis, etc.) was all we had in addition to the radiograph.

! Free intraperitoneal air and an ileus are best diagnosed on an abdominal radiograph with the patient standing or positioned on the left side and a horizontal x-ray beam. The infrequent retroperitoneal air and the cause of a mechanical bowel obstruction are often better appreciated on CT. Free fluid is detected most rapidly by ultrasound. Make a note of that: It is not always the most expensive modality that gives you the crucial information!

### 9.3 Diseases of the Esophagus

#### Checklist: Diseases of the Esophagus

- Does the patient choke or cough while eating or drinking?
- Does food get stuck when the patient is eating?
- Has a foreign body been swallowed?
- Does the patient complain about a lump in the throat, regurgitation of undigested food, or bad breath?
- Is swallowing painful for the patient?
- Has the patient had heartburn for extended periods?

#### The Steak Won't Go Down Easy

Jack Wiggle (86) comes to the radiology department for an examination because he has problems swallowing. He chokes quite often and feels a lump in the throat,

and his grandchildren have been complaining about grandpa's bad breath. He has brought one of them with him to help out with the test. Paul is just getting his first instructions on the art of fluoroscopy, the real-time x-ray examination of the intestinal tract. Dr. Llewellyn, a dyed-in-the-wool, old-school specialist in gastrointestinal imaging, watches him carefully while he sets out to do the examination. The clinical information given by Wiggle's general practitioner and the conversation with Mr. Wiggle as well as the young man who accompanies him have not provided any definite clues as to what is going on.

! If a functional swallowing disorder were suspected, dedicated videofluoroscopy of the swallowing act would be the examination of choice. Videofluoroscopy documents the different phases of the highly complex swallowing act in multiple video frames (Fig. 9.9). If, for example, the disturbance is due to the nonrelaxation of

#### Normal Swallowing

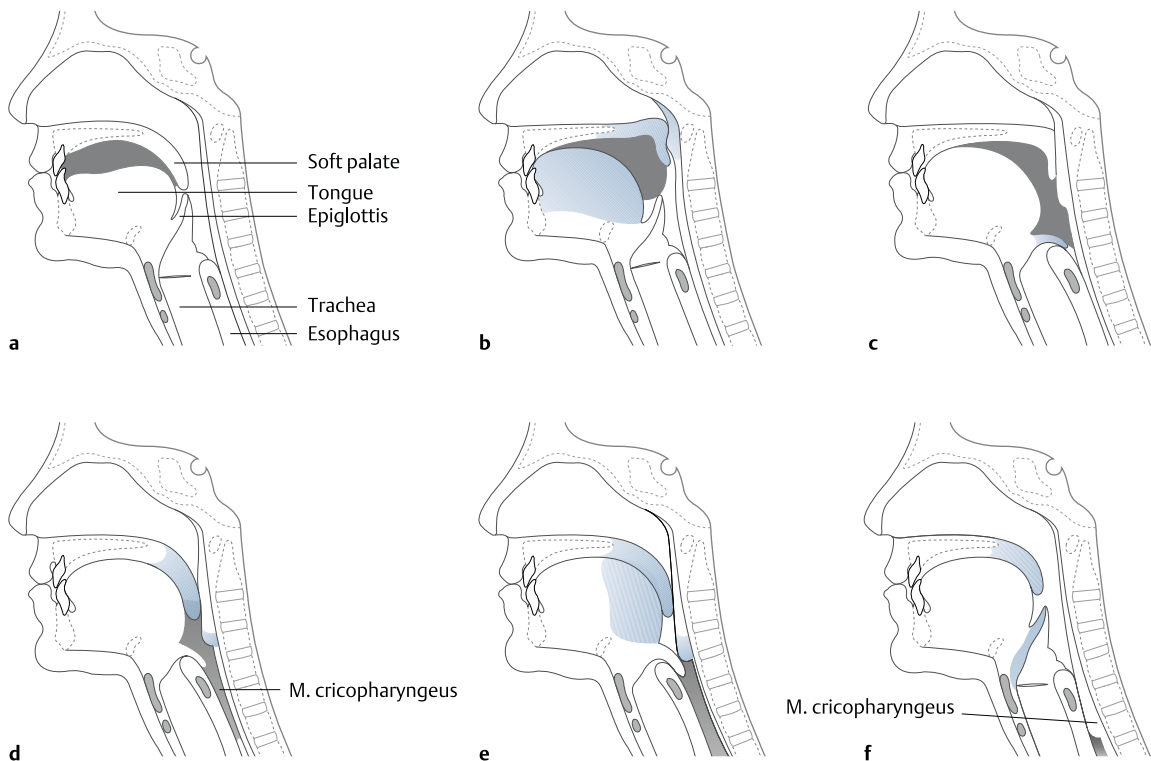


Fig. 9.9 This is what normal swallowing looks like. **a** The contrast bolus is held and formed between the tongue and the soft palate. **b** The tongue and the soft palate elevate to present the bolus to the oropharynx. In the process the soft palate seals the communication to the nasopharynx to prevent regurgitation. **c** The bolus moves dorsally and downward while the epiglottis seals the laryngeal introitus. **d** The soft palate descends even further and the cricopharyngeus muscle relaxes,

permitting the passage of the bolus. **e** As the bolus has passed the cricopharyngeus muscle, the tongue base and the soft palate rise again. **f** As the bolus reaches the thoracic esophagus, the tongue base moves forward, the epiglottis flips up, and the larynx returns to its resting position. (From Richard M. Gore, Marc S. Levine, Igor Laufer, eds. *Textbook of Gastrointestinal Radiology*. Philadelphia: WB Saunders, 1994.)



the cricopharyngeal muscle, an injection of botulinum toxin may be considered. Specific other findings, such as weak stripping motion of the tongue, weakness of the soft palate, or food getting stuck in the valleculae or piriform sinus, can aid the speech pathologist in figuring out a new swallowing technique for the patient affected by these abnormalities.

Paul studies a frontal radiograph of the chest and upper abdomen that was obtained prior to the examination on Mr. Wiggle, which demonstrates no obvious abnormality. To get oriented a bit, he has Mr. Wiggle take a little sip of a barium suspension and watches the barium pass through his esophagus under fluoroscopy. Subsequently he asks the patient to drink some more and obtains radiographs of the whole esophagus in two projections, both fully distended with the barium column and in double contrast technique to assess the mucosal lining of the esophagus. When he sees a narrow segment of esophagus, he hesitates and obtains some enlarged collimated views of this suspicious segment (Fig. 9.10).

#### → What is your diagnosis?

**Esophageal diverticula:** These are circumscribed mucosal and submucosal outpouchings of the esophagus with little or absent muscular coverage. They are divided into traction and pulsion diverticula. Pulsion diverticula tend to

### The Case of Jack Wiggle

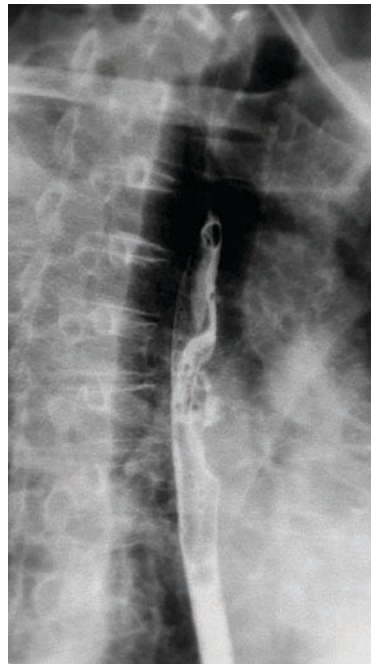


Fig. 9.10 Here you see the diagnostic film of the barium swallow of Jack Wiggle. Is there anything abnormal?

### Diverticulum

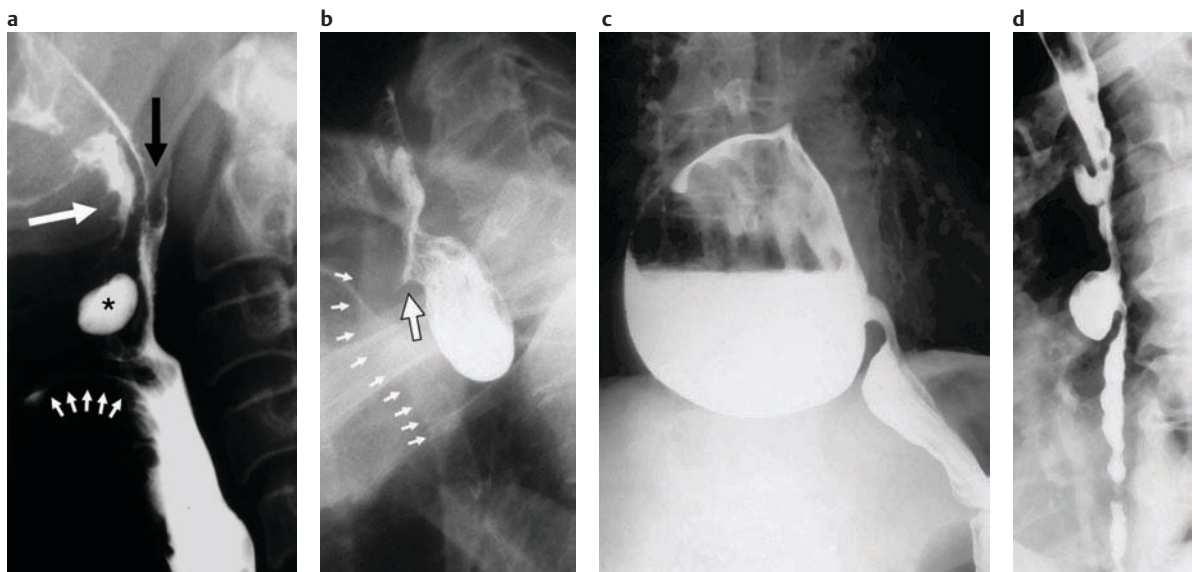


Fig. 9.11 **a** This lateral view of the swallowing act shows the appearance after passage of the barium bolus into the esophagus. The soft palate is pressed against the dorsal pharyngeal wall (black arrow), thus preventing the regurgitation of food into the nasal cavity. The tongue base (large white arrow) has moved upward and backward; the epiglottis (small white arrows) seals off the laryngeal entrance. The bolus has entered the proximal esophagus. There is a diverticulum in the area of the epiglottic

fold (star). It extends laterally from the tongue base. **b** In a Zenker diverticulum the depiction of the width of the diverticular neck (large arrow) is of particular importance to the surgeon. The esophagus and the trachea (small arrows) are displaced ventrally. **c** Another typical location of a pulsion diverticulum is the distal esophagus. **d** Traction diverticula tend to occur at the level of the pulmonary hila and are usually the consequence of inflammatory lymphadenitis in the mediastinum.

## Achalasia

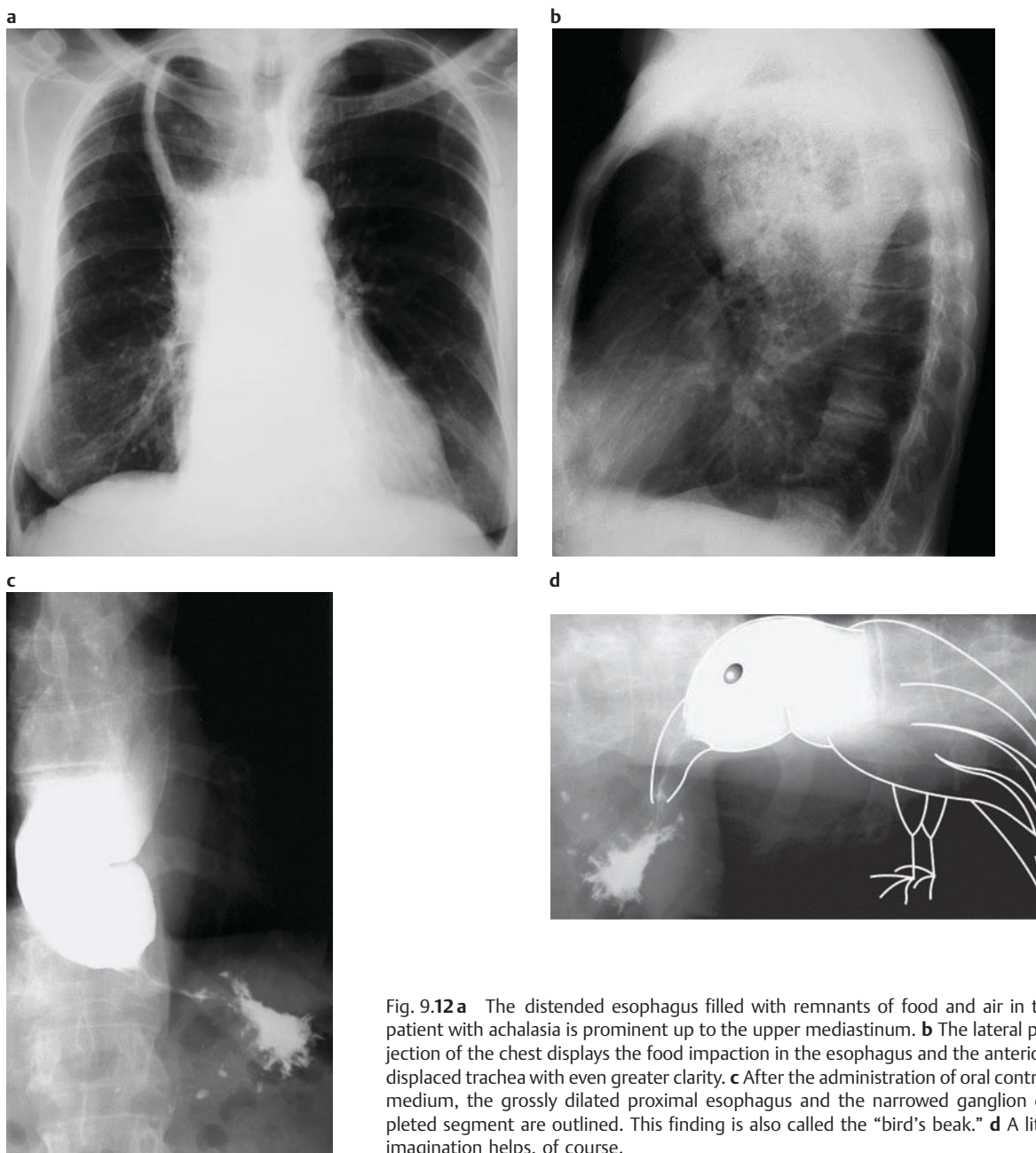


Fig. 9.12 **a** The distended esophagus filled with remnants of food and air in this patient with achalasia is prominent up to the upper mediastinum. **b** The lateral projection of the chest displays the food impaction in the esophagus and the anteriorly displaced trachea with even greater clarity. **c** After the administration of oral contrast medium, the grossly dilated proximal esophagus and the narrowed ganglion depleted segment are outlined. This finding is also called the “bird’s beak.” **d** A little imagination helps, of course.

be cervical (Fig. 9.11a) and epiphrenic (Fig. 9.11c) and usually occur proximal to a relative point of obstruction such as the upper or lower esophageal sphincter or when a weak spot in the muscular wall of the esophagus gives way to the pressure. Traction diverticula due to pulling inflammatory processes (often in the mediastinum) occur almost exclusively at the level of the tracheal bifurcation (Fig. 9.11d).

The *Zenker diverticulum* is a pulsion diverticulum always located left of the pharyngoesophageal transition zone

(Fig. 9.11b). It may become extremely large and it can retain undigested food and can compress the esophagus. The food remnants give rise to the frequent symptom of halitosis (synonym for bad breath).

! Esophageal diverticula can be overlooked during endoscopy, especially if they have a narrow neck, while wide-necked diverticula may be mistaken for the esophageal lumen and be perforated when the endoscopist tries to advance the scope during the procedure.

**Disturbances of the esophageal peristalsis:**

**Achalasia:** In this neurogenic disorder those ganglion cells of the muscle layers of the distal esophagus that normally inhibit the contraction of the lower esophageal sphincter are decreased. It is rare in children and can occur throughout adult life. The disorder is characterized by a combination of absent peristalsis and a hypertensive lower esophageal sphincter, resulting in a functional obstruction at or close to the esophagogastric junction. Over time this can lead to a dilated esophagus, often filled with secretions and undigested food. The chronic irritation of the mucous membranes induces a chronic inflammation of the esophagus and is associated with a 10-fold higher risk of developing esophageal carcinoma. The diagnosis of achalasia may be suggested on a simple chest radiograph (Fig. 9.12a, b). The final confirmation is achieved by performing a barium swallow (Fig. 9.12c, d).

**Diffuse esophageal spasm (DES):** DES is due to a local neurodegenerative process and it shows a completely different appearance: so-called “tertiary” (uncoordinated) contractions occur that may give the esophagus a “corkscrew” configuration; this kind of uncoordinated peristalsis is more frequent in the elderly (Fig. 9.13).

**Scleroderma:** Peristalsis of the esophagus is weakened or completely absent in scleroderma (Fig. 9.14). Delayed radiographs after a barium swallow may show residual contrast in the esophagus.

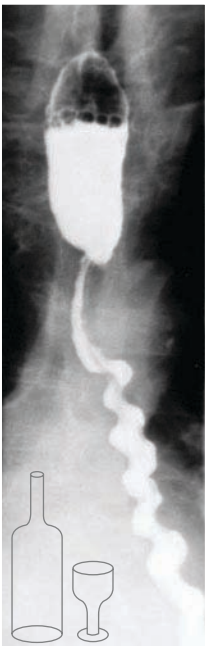**Diffuse Esophageal Spasm (DES)**

Fig. 9.13 In elderly patients the peristalsis of the esophagus may become disorganized, losing its propulsive force. After barium has been given, the esophagus may look like a corkscrew in DES. This entity is not associated with alcohol abuse, however.

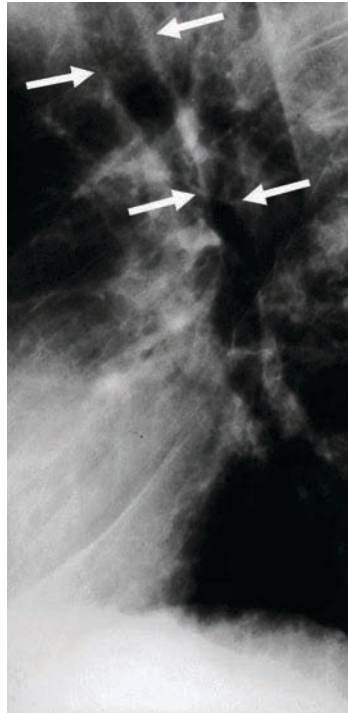
**Scleroderma**

Fig. 9.14 In extreme cases of scleroderma the rigid and dilated esophagus (thick arrows) may appear as a second air column behind the trachea (thin arrows)—the “double-barrel sign.”

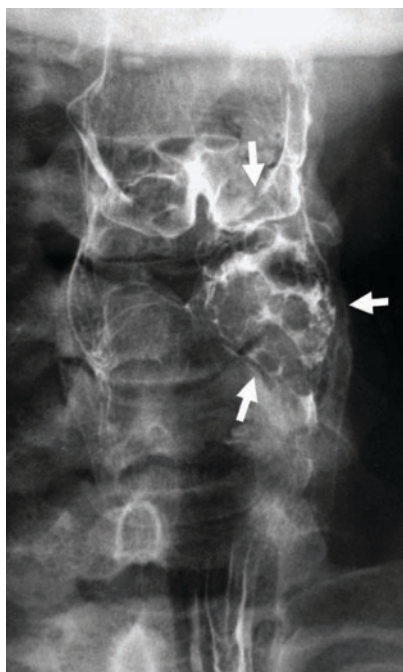
**!** Peristaltic disturbances are best diagnosed by a barium swallow examination.

**Esophageal tumors:** If the appearance on barium swallow suggests the possibility of an esophageal tumor, it must be considered to be malignant until proven otherwise. If the lesion is located in the very proximal esophagus, it is most likely a squamous cell carcinoma of the hypopharynx (Fig. 9.15) or of the esophagus (Fig. 9.16a); further distal the frequency of adenocarcinomas increases (Fig. 9.16b). These are particularly frequent if precursor diseases of the esophagogastric transition zone such as reflux esophagitis (Fig. 9.17a) or a Barrett esophagus (Fig. 9.17b) have been present.

**Esophageal varices:** Venous varices of the esophageal wall may develop as a consequence of portal hypertension due to liver cirrhosis (Fig. 9.18) or portal vein occlusion. The veins around the esophagus have connections to the portal system in the upper abdomen around the esophagogastric junction and drain into the azygos and hemiazygos venous systems in the posterior mediastinum, which are part of the systemic circulation. This pathway may be used by the body to decompress the portal venous system in the aforementioned conditions. Severe acute hemorrhage is the greatest risk associated with this condition.

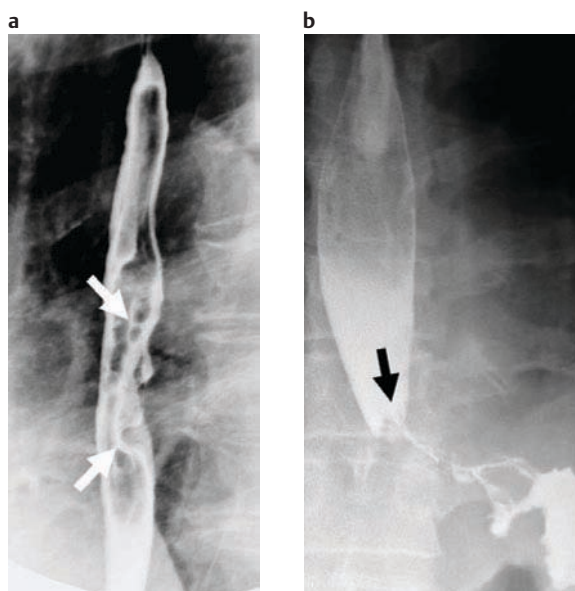


### Hypopharyngeal Carcinoma



**Fig. 9.15** This polypoid growing hypopharyngeal carcinoma (arrows) is located in the left piriform recess, directly proximal to the entrance into the esophagus and directly distal to the epiglottis, which is nicely outlined by contrast medium. (Where was your anatomy book again?)

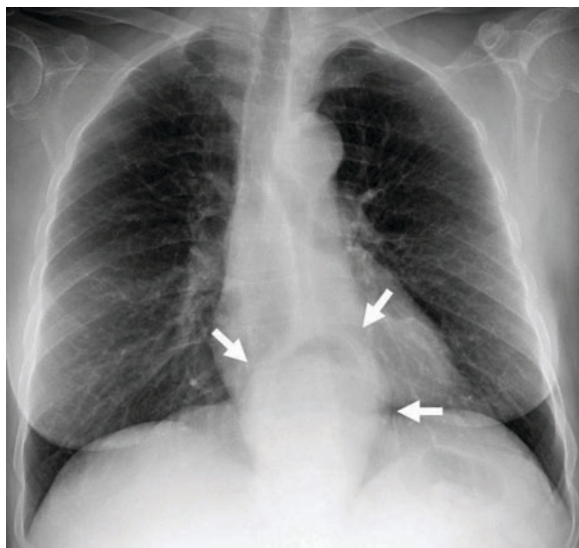
### Esophageal Carcinoma



**Fig. 9.16 a** This esophageal carcinoma presents as an abnormal appearance of the esophageal wall contour (arrows), frequently with ulcerations. Submucosal lesions are also detectable in a barium swallow because they change the peristalsis of the esophageal wall; that is a real advantage in comparison to fiberoptic endoscopy. **b** A carcinoma of the distal esophagus like this one tends to involve the gastric cardia as well. Note the irregular proximal contour (arrow) and the distal margin of the stenosis.

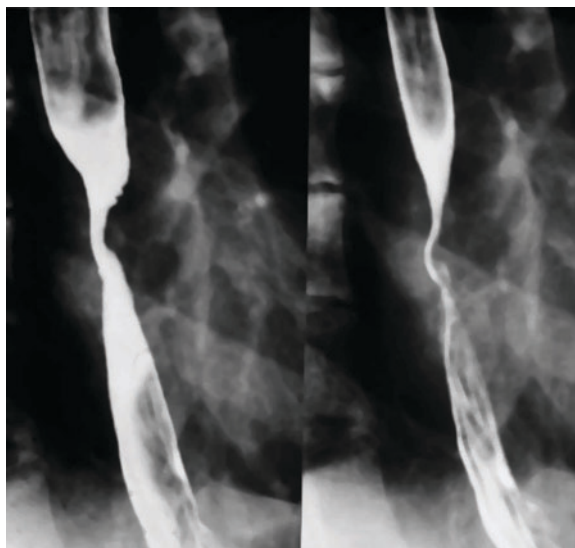
### Esophageal Carcinoma: Precursor Diseases

#### a Hiatal hernia



**Fig. 9.17 a** Hiatal hernias are recognized by their ringlike structure (arrows), frequently with air-fluid interfaces, in the mediastinum. To confirm the diagnosis, a small cup of barium is sufficient. **b** The leading characteristic of a Barrett esophagus is the stenosis or mucosal irregularity in the distal third of

#### b Barrett esophagus



the esophagus, but often this precancerous abnormality is invisible to the radiologist. Distal to the stenosis, columnar epithelium replaces the normal stratified squamous epithelium in the esophagus as a result of chronic acid reflux into the distal esophagus.



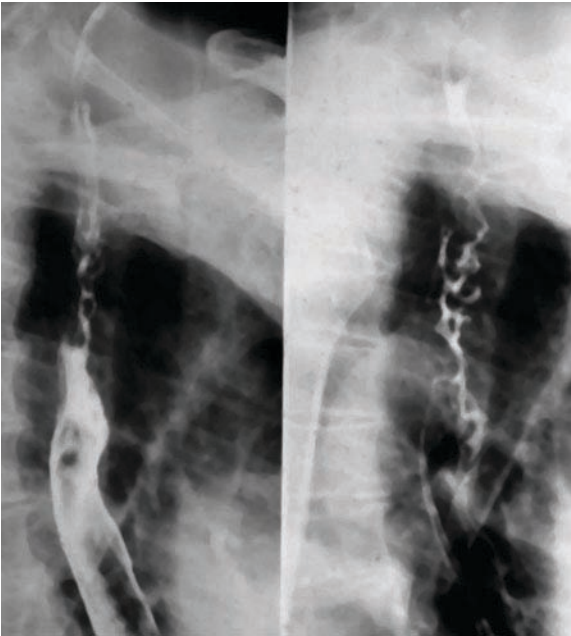
**Esophageal Varices**

Fig. 9.18 The wormlike contrast defects in the esophageal lumen in this barium swallow are due to dilated veins in the wall. This patient suffered from severe portal hypertension with recurrent variceal bleeds.

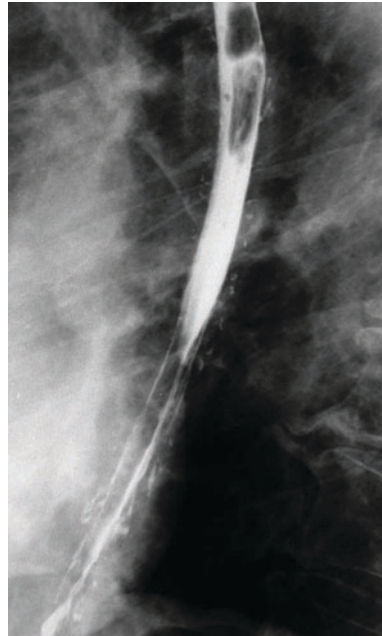
**Esophagitis in Crohn Disease**

Fig. 9.19 Small contrast tracks and depots are visible in the wall of the esophagus. These correspond to ulcerations and fistula formations such as are also found in the bowel wall in Crohn disease.

**Esophagitis:** Inflammatory changes of the esophageal mucosa may be due to gastroesophageal reflux, caustic injury, candidiasis, or viral infection in immunocompromised patients. Sometimes Crohn disease can affect the esophagus in the child and adolescent (Fig. 9.19).

**Foreign body:** This is of particular importance in psychiatric patients (Fig. 9.20b). Potential foreign bodies in the

esophagus include dental fixtures, toothbrushes, coins, etc. If a fine and delicate structure like a fishbone is suspected, the patient should be asked to swallow cotton pads soaked in iodinated water-soluble contrast medium that will get stuck to the fishbone. However, the examination should be performed only if endoscopy is either not available or ambiguous.

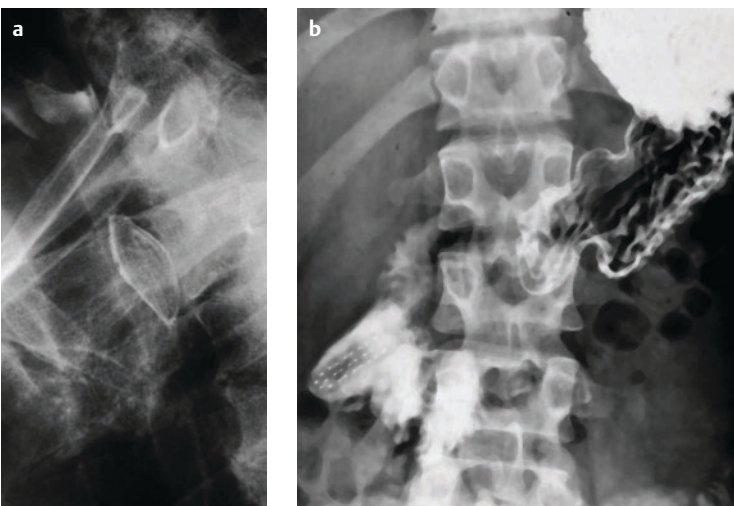
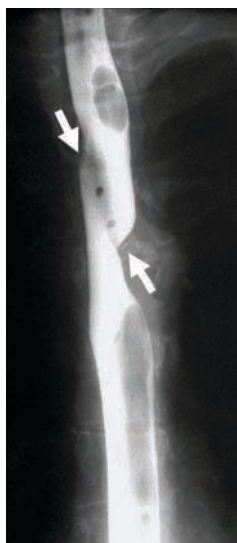**Foreign Body in the Esophagus**

Fig. 9.20 **a** While baking that delicious plum cake with its mother, this child suddenly developed swallowing problems. The contrast medium marks the margins and the surface structure of the plum pit impacted in the proximal esophagus. **b** This patient from a psychiatric institution was sent for the examination because the danger of self-inflicted injury was known and the toothbrush—here nicely outlined in the stomach—was missing.

## Compression of the Esophagus

**a Arteria lusoria**



**b Osteochondrosis of the cervical spine**

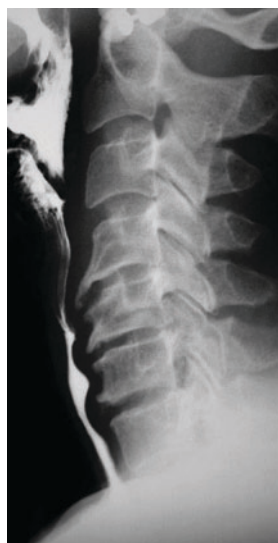

Fig. 9.21 **a** When the right subclavian artery runs posterior to the esophagus toward the right it may impinge on the esophageal lumen, which is termed arteria lusoria. On this anteroposterior view it is characterized by a smooth oblique defect of the luminal contrast filling just above the aortic knob (arrows). **b** Degenerative disk disease of the cervical spine with formation of anterior osteophytes may encroach on the esophagus and cause swallowing problems.

**!** If there is a risk of esophageal perforation, only water-soluble iodinated contrast medium should be used initially. Barium formulations are contraindicated if a perforation is present. If there is none, one may switch to barium for a much more accurate diagnosis. The postoperative patient should always receive thin barium suspension because of the better diagnostic yield and the high chance of aspiration.

### Compression of the esophagus:

**Arteria lusoria:** The esophagus can also be compressed from the outside (Fig. 9.21a). A relatively frequent—and congenital—cause is an aberrant right subclavian artery in “dysphagia lusoria”.

**Osteochondrosis of the cervical spine:** Ventral degenerative spondylophytes of the cervical spine may impinge on the esophagus from dorsally and lead to dysphagia as well (Fig. 9.21b).

In older patients there frequently is an extrinsic impression of the esophagus by an ectatic aortic arch, sometimes also compression of the distal esophagus by an ectatic and tortuous thoracic aorta, which may cause swallowing problems (dysphagia aortica).

→ **Diagnosis:** Paul decides that this eccentric stenosis of the middle segment of the esophagus must be due to a process that extends through the mucosa. Until proven otherwise, this is a carcinoma, most likely a squamous cell carcinoma. The biopsy taken during a fiberoendoscopy on the next day confirms that diagnosis.

**!** Any space-occupying lesion and any stenosis of the esophagus requires histological work-up.

## 9.4 Diseases of the Small Bowel

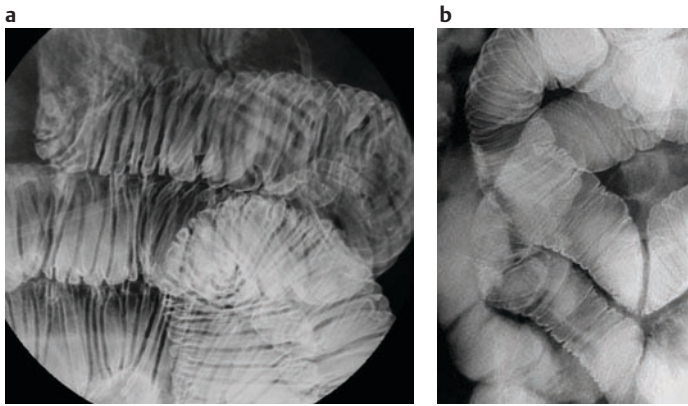
### Checklist: Diseases of the Small Bowel

- How old is the patient?
- Are symptoms related to ingestion of any specific food items?
- Is there diarrhea or weight loss?
- Is an abdominal tumor palpable?
- Has there been abdominal surgery?

### Intestine on Strike

Josephine Slimline (16) has been a puzzle to her family and her general practitioner. She complains about diarrhea and abdominal cramps. Her weight has remained constant for the last two years. Her primary care physician has now asked for a double contrast examination of the small bowel, also called enteroclysis, to get to the root of the problem. Dr. Llewellyn has made a deal with Paul: Paul may introduce the tube into the jejunum under close supervision, but the remainder of the examination will be done by Llewellyn himself. After all—Josephine is only 16 years old and the exposure dose of this study to the radiosensitive female gonads and the bone marrow is relatively high. Especially in patients of reproductive age, the procedure should be done by an experienced radiologist rapidly and efficiently. Paul even succeeds in getting Ms. Slimline to laugh on the examination table. She has closely followed the instructions for the preparation for examination (see below).

### Double Contrast Enema of the Small Bowel: Normal Findings



**Fig. 9.22** This is a normal small-bowel pattern in a double contrast examination. In the jejunum (**a**) you find less than one mucosal fold per centimeter; in the ileum (**b**) there are more than two mucosal folds per centimeter. Note that the distance between the bowel loops is of major diagnostic significance because it indicates the thickness of the bowel wall.

**!** A correct preparation by the patient is crucial for a small-bowel examination.



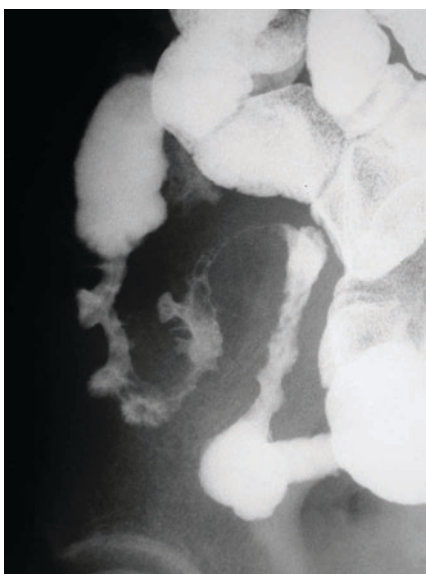
#### What Is a Perfect Patient Preparation for Enteroclysis of the Small Bowel?

On the day before the examination the patient should consume nothing but clear liquid foods (clear soups, coffee, tea, clear juices).

High-fiber foods, vegetables, fruits, rice, meat, or milk should be avoided in particular. A laxative may also be taken on the day before the examination.

On the eve of the examination (after 10 p.m.) and on the day of the examination nothing may enter the mouth: no smoking, no tooth brushing, no oral medication, no drinking, no eating.

### The Case of Josephine Slimline



**Fig. 9.23** Analyze the relevant radiograph from Ms. Slimline's small-bowel examination.

The experienced x-ray tech Mrs. Fairweather lends Paul a hand as he introduces the cooled tube via a nostril after having lubricated it with a lidocaine gel (also called xylocaine or lignocaine). Paul has also sprayed lidocaine solution into the patient's nose and throat. Josephine turns out to be a brave and calm patient and breathes regularly in a controlled way. As the tube is far enough in to reach the tongue base, Paul asks Josephine to swallow a few times and he is in luck: during this maneuver the tube can easily be advanced. A short fluoroscopy confirms the position of the tube tip inside the stomach. He pushes the tube into the region of the pylorus and withdraws the guide-wire just a little. He asks Josephine to position herself on her right side. After a little while the soft tip of the tube slides through the pylorus into the duodenum. Paul advances the tube some more until the tip is positioned just distal to the ligament of Treitz in the jejunum. After withdrawing the guide-wire, he injects a little thin barium solution through the tube to confirm the position of the tip: it is right where it is supposed to be. Mrs. Fairweather gives him a big smile. Dr. Llewellyn seems to be satisfied as well: "We have seen worse than that!" he nods to Paul before he walks over to Ms. Slimline to start the examination itself. Rapidly a special barium suspension and then a preparation of methylcellulose are infused via the tube. All small-bowel loops are expanded and evaluated (Fig. 9.22). While watching the examination and during the subsequent review of the exposed radiographs, one segment grabs Paul's attention (Fig. 9.23).

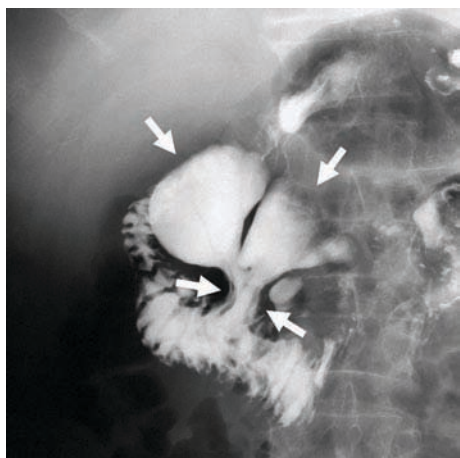
#### → What is Your Diagnosis?

**Duodenal diverticulum:** A duodenal diverticulum is a relatively frequent outpouching of the duodenum, mostly to the left (Fig. 9.24a). It is asymptomatic in most cases. Rarely diverticula are found in other segments of the small bowel (Fig. 9.24b).



### Small-bowel Diverticulum

**a Duodenal diverticulum**



**b Jejunal diverticulum**

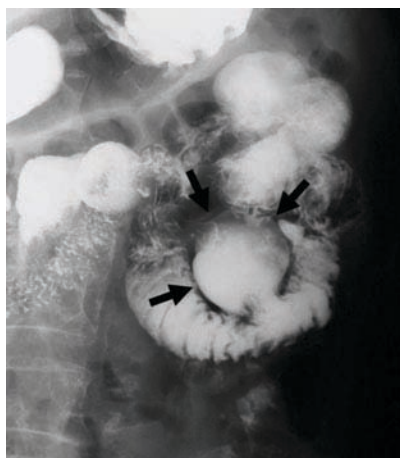

Fig. 9.24 **a** Observe the duodenal “C” configuration and the air-distended stomach cranially. Diverticula that originate from the inner curvature of the C (arrow) can cause problems, particularly if they reach the size depicted in this image and

if they also involve the papilla of Vater. In that situation it becomes very difficult for the endoscopist to find and, if necessary, enter the papilla. **b** This diverticulum is located immediately distal to the ligament of Treitz (arrows).



#### Do You Know about the Meckel Diverticulum?

Meckel diverticulum has been encountered in up to 3% of patients in a series of autopsies performed for unrelated reasons. It is a remnant of the vitelline duct, located in the ileum within 100 cm or so of the ileocecal valve and often connected to the umbilicus by a fibrous ligament. Frequently, ectopic gastric or pancreatic tissue is found within the diverticulum.

**Crohn disease:** Crohn disease is a granulomatous inflammatory condition that can manifest itself in any segment of the gastrointestinal tract between the lips and the anus but that most commonly affects the terminal ileum (Fig. 9.25a). Alternating relatively normal areas of mucosa surrounded by mucosal ulcerations and scarring result in a “cobblestone” appearance of the mucosa on contrast examination. The entire bowel wall is affected and involvement of intestinal segments is often discontinuous

### Crohn Disease

**a, b Terminal ileitis**

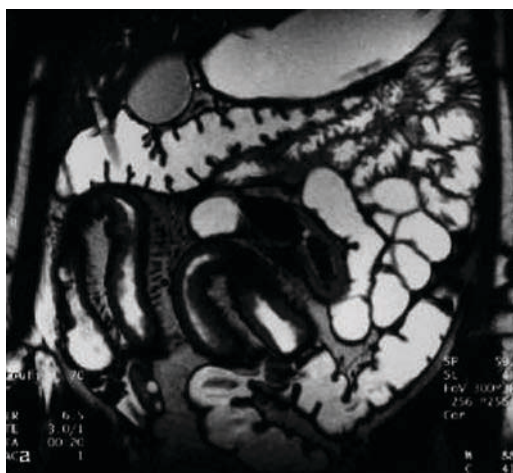
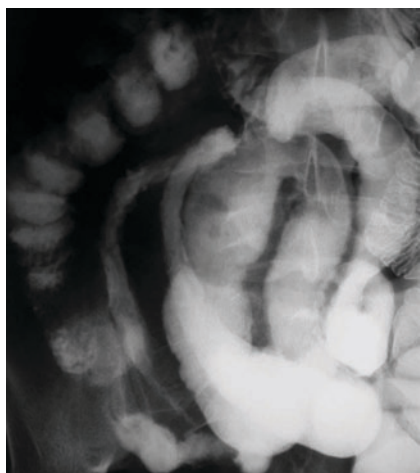


Fig. 9.25 **a–c**



## Crohn Disease

## c Fistula formation

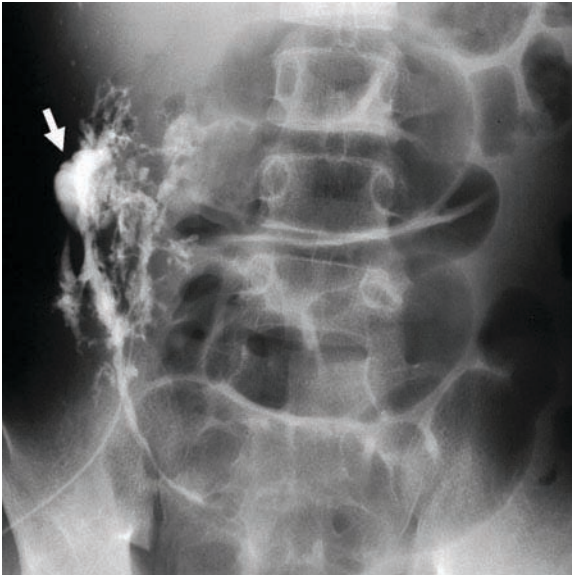


Fig. 9.25 **a** The terminal loop of the ileum has a significantly smaller caliber than the proximal loops. The lumina lie wide apart as a sign of bowel wall swelling and hypertrophy of intervening mesenteric fat. Fluoroscopy of the terminal ileum loop shows minimal mobility of this segment. **b** MRI is increasing its role in imaging for inflammatory bowel disease—a welcome development because affected patients are often young and radiation exposure must be kept to a minimum. The thickened wall of the terminal ileum is well appreciated. **c** In this case contrast was injected via a small catheter that was introduced into a cutaneous fistula. A complex fistula system becomes apparent that communicates with the bowel (arrow). Some call these systems the “fox hole.”

## Intussusception

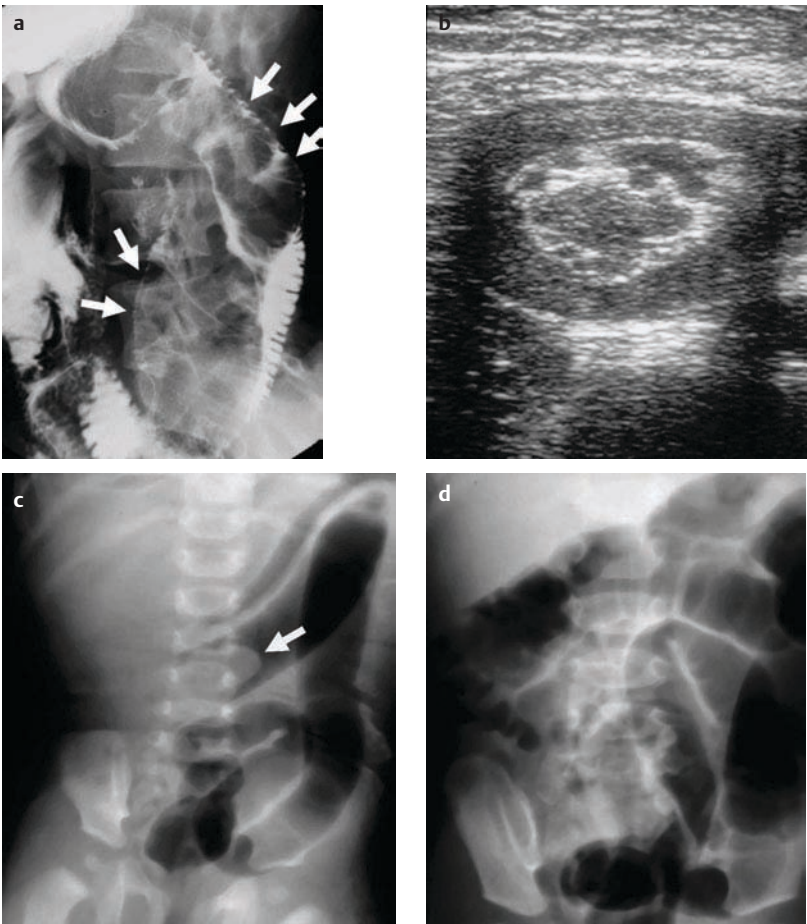


Fig. 9.26 **a** The invaginated segment of bowel appears as a contrast-engulfed “sausage” (arrows) within the outer bowel lumen. In this case a polyp was the lead point of the intussusception. **b** On ultrasound the characteristic “double-doughnut sign” is appreciated. The reduction with air takes place under fluoroscopy to monitor the success of the procedure. **c** The invaginated bowel segment is visible in the middle abdomen (arrow). The small bowel is free of air. **d** The final radiograph shows the resolution of the intussusception. The air column has reached the small bowel, proving successful reduction.

("skip lesions"). Long segmental strictures and intramural and intestinocutaneous fistulas may be another complication (Fig. 9.25c). After multiple resections of the small bowel, a short bowel syndrome can ensue: the residual ileal segment grows wider and shows thicker folds.

**Celiac disease:** In this malabsorption entity due to gluten intolerance, the number of folds visible in enteroclysis changes to less than 1 per cm in the jejunum and to more than 2 per cm in the ileum.

**Intussusception:** An intussusception develops when one segment of the intestine is pulled into the contiguous distal segment of bowel (Fig. 9.26a). It tends to occur most commonly in children; about 90% of intussusceptions in children are ileocolic. The cause is often a so-called "lead-point" (a polyp or a mucosal hyperplasia) that is picked up by the intestinal peristalsis like a food particle and thus pulls the attached segment of bowel with it. The two main resulting problems are intestinal obstruction and vascular compromise because the mesentery follows the bowel and blood vessels can twist and become blocked. An intussusception must be treated quickly to prevent a bowel infarction. Today this is done primarily under ultrasound control (Fig. 9.26b). Water or air is administered through a rectal tube. The water column or air pressure then pushes the invaginated intestinal segment back and thus reduces the intussusception. When air insufflation is used, the procedure is usually performed under fluoroscopic control (Fig. 9.26c, d). While an intussusception is often idiopathic or due to temporary reactive mucosal hyperplasia in children, a symptomatic intussusception in an older patient should always prompt a careful work-up to determine the underlying etiology as it is commonly caused by small-bowel tumors in the adult. On modern multidetector-row CT of the abdomen we often see asymptomatic transient small-bowel intussusceptions that are of no clinical significance.

**Small-bowel tumors:** Tumors of the small bowel are extremely rare and the benign ones (for example, leiomyomas; lipomas, Fig. 9.27) make up the majority. Chances are that you will not see a patient with a small-bowel tumor in your professional lifetime.

→ **Diagnosis:** Paul has already jotted down a short report as Llewellyn puts his lead apron neatly back on the hanger. "Crohn disease of the terminal ileum, no fistulas detectable so far" is his diagnosis. Llewellyn has not told him a thing during the procedure, not a single hint, but has taken the necessary radiographs under fluoroscopy rapidly and carefully. Now he takes a look at Paul's report on the table. "Bingo," says Llewellyn. He pleurably takes a noisy sip of coffee. "I just hope the gastroenterologists get a handle on this one. The patients are so awfully young. Well, Paul, the next barium enema is yours. I hope you have done your reading. I'll talk you through it if you get stuck."

### Small-bowel Lipoma

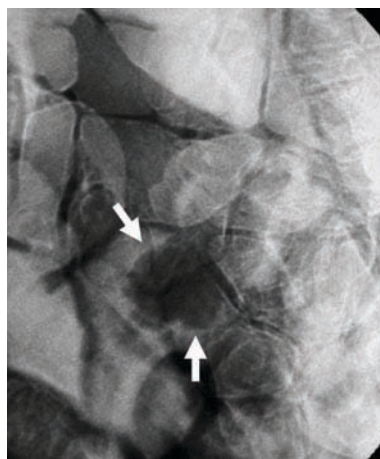


Fig. 9.27 This small-bowel enema shows a tumor in the intestinal lumen (arrows). The histological analysis of the resected segment confirmed a lipoma, which can also sometimes be diagnosed with confidence in CT thanks to the characteristic negative density.

## 9.5 Diseases of the Large Bowel

### Checklist: Diseases of the Large Bowel

- Is the patient sufficiently prepared? Check the radiograph of the abdomen before you even think about putting in a rectal tube!
- Is there an ileus, a fistula, or an obstruction of the intestinal lumen, or is the examination scheduled only a few days prior to abdominal surgery? If yes, only water-soluble iodinated contrast medium may be used.

### Oh, Bloody Stool

Trudy Herbgarden (55) complains about a change of bowel habits for the last few months. Her primary care physician has done a test of the stool for occult blood, which was positive. Now Mrs. Herbgarden sits in the waiting room and waits for her barium enema. Paul explains the procedure to her once again and makes sure she has understood and followed the rules for the preparation of this particular examination.



### What Is a Perfect Patient Preparation for the Air Contrast Enema of the Large Bowel?

Two days before the examination the patient should consume nothing but clear liquid foods

(clear soups, coffee, tea, clear juices). Salads, wholemeal products, vegetables, fruits, rice, meat, or milk should be avoided in particular. A laxative may also be taken on the day before the examination.

On the eve of the examination (after 10 p.m.) and on the day of the examination nothing may enter the mouth: no smoking, no tooth brushing, no drinking, no eating. Oral medication should be postponed until after the examination if at all possible.

Paul is so fussy in his own interest: if he encounters residual feces in Mrs. Herbgarden's colon, the examination may have to be terminated or it will last much longer because every single fecal particle (sometimes also called fecaloma) must be differentiated from true tumors (Fig. 9.28b) by moving them around with the barium (true tumors are obviously stuck to one place in the wall). After the patient has been positioned comfortably on her side by Mrs. Fairweather, Paul cautiously introduces the rectal tube after having done a careful digital rectal examination. He then inflates a small balloon that sits around the tip of the tube to prevent it from falling out. Paul has the barium suspension flow inside slowly until it reaches the cecum. To facilitate this, he turns Mrs.

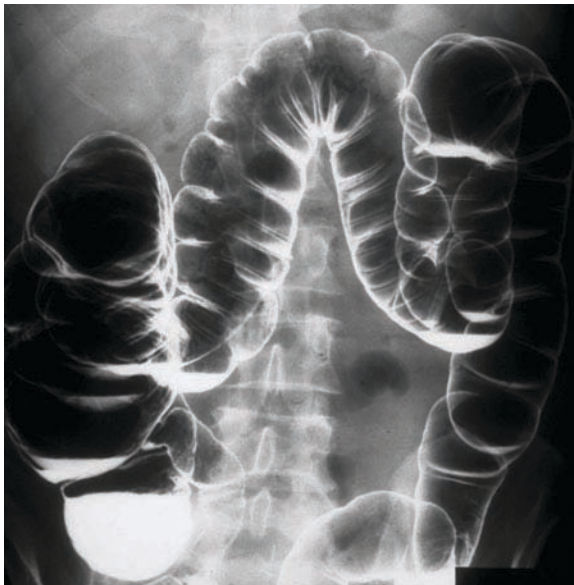Herbgarden slowly around her long axis. The suspension is then partially evacuated again; Paul injects a spasmolytic drug (such as glucagon) into her vein and insufflates air cautiously with a balloon pump. The large bowel is expanded in the process.

! Never forget the rectal examination. In glaucoma and hypertrophy of the prostate, scopolamine derivatives as spasmolytics are contraindicated and glucagon should be used.

The homogeneous and thin barium coating of the bowel wall permits a first-rate evaluation of the mucosa (Fig. 9.28a). Paul unfolds the rectum and sigma by turning the patient under fluoroscopy and shoots radiographs of these colon segments. Subsequently he tilts up the fluoroscopy table and with it the patient. Air rises and unfolds the splenic and hepatic flexure of the colon in the upper abdomen, Paul has to turn the patient slightly to the left and right to get the best views of these tortuous areas. Standard erect radiographs of the whole colon follow. Now the table is tilted head down to get a good expansion of the cecum, which is also documented on dedicated radiographs. He finishes the examination by producing two large radiographs of the colon with a horizontal x-ray beam—one with the patient positioned on the right, the second with the patient positioned on the left side. These are called left and right decubitus radiographs. It is Paul's ultimate goal to get a double contrast radiograph

## Double Contrast Enema of the Large Bowel

### a Normal findings



### b Residual stool

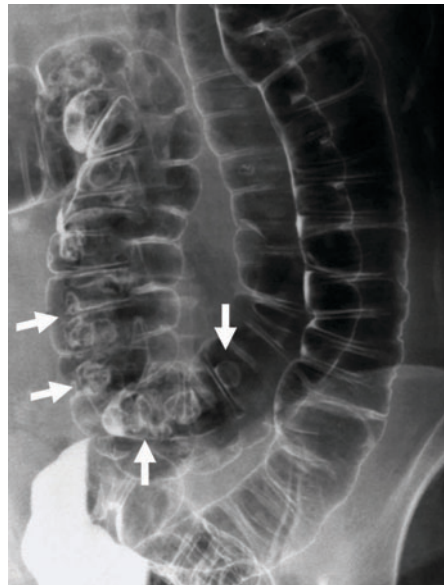


Fig. 9.28a This is what a normal double contrast enema of the colon looks like. The bowel is clean and completely distended with air, the mucosa well coated with a barium suspension. A small part of the terminal ileum is also visualized.

b The numerous space-occupying lesions (arrows) in this bowel

segment were very irritating for the examining physician. It required several radiographs in different patient positions to confirm that they represented retained stool particles. Polyps and also larger malignant lesions can easily be overlooked if the patient preparation is suboptimal.



### The Case of Trudy Herb garden

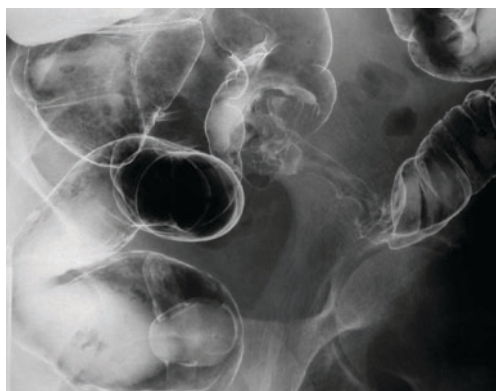

Fig. 9.29 Analyze this key radiograph of Mrs. Herb garden's barium enema. What diseases come to your mind?

of every colon segment in two projections—that is the only way to get a complete examination of the colon without missing a small polyp or cancer. One segment looks a little odd to him (Fig. 9.29).

#### → What is Your Diagnosis?

**Diverticulosis:** Diverticulosis is a disease primarily of the sigma and the distal colon, where outpouchings (diverticula) of the bowel wall occur (Fig. 9.30). Inside the diverticula inflammations can develop, termed “diverticulitis” (Fig. 9.31a); patients typically present with fever and left lower abdominal pain. CT can be used to make sure

that no abscess formation or perforation of the bowel has occurred if the patients do not readily get better with antibiotic treatment or if there are signs of generalized peritonitis. Recurrent diverticulitis may eventually give rise to stenoses, fistulas, most commonly to the bladder (Fig. 9.31b), and pseudotumors. Imaging cannot not always differentiate them from true malignant processes. It is good practice to obtain a dedicated study of the colon after the acute diverticulitis has resolved to exclude any other serious underlying process. This is also true for patients who get recurrent diverticulitis.

**Large-bowel polyps:** Polyps are quite frequent in the large bowel (Fig. 9.32a). If they exceed 5 mm in diameter, their chance of malignant transition increases significantly. Their removal is strongly recommended once they reach a size of 10 mm for that reason. Larger tumors may encompass the whole bowel lumen, which eventually leads to a characteristic appearance on a barium enema reminiscent of an “apple core” because of the transition from soft distended colon to rigid narrow cancer back to soft distended colon. Eventually the bowel lumen is obstructed completely and a bowel obstruction develops (see p. 177).

**Crohn disease:** Crohn disease is an inflammatory bowel disease that causes ulcerations of the bowel wall and eventually results in an image appearance called “cobblestone relief” for obvious reasons (Fig. 9.33). It tends to show a segmental involvement of the gastrointestinal tract (“skip lesions,” sparing segments of intestine in between diseased segments) and spares the rectum. The terminal ileum is frequently involved and fistulas and abscesses occur (see also p. 191).

### Diverticulosis

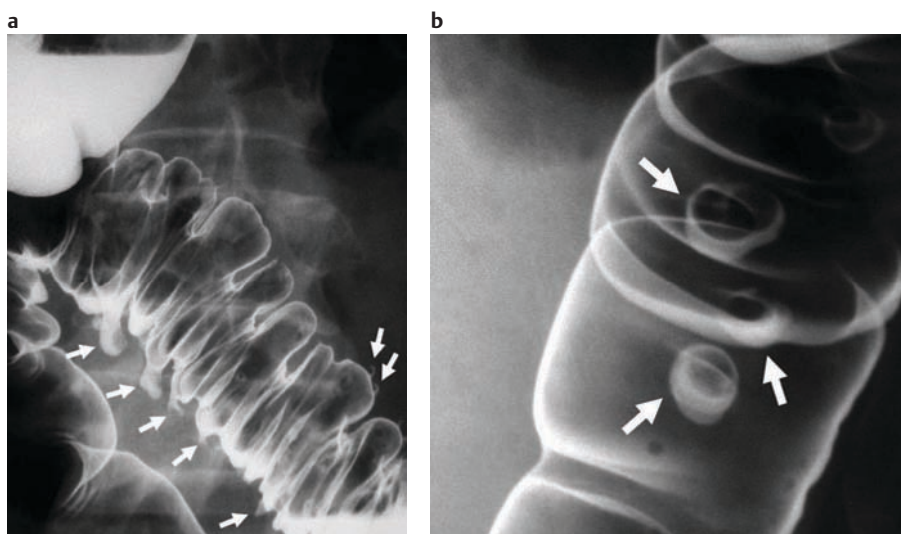


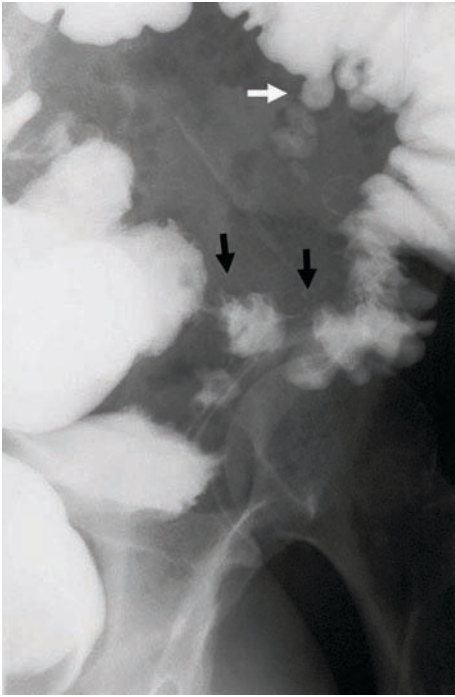
Fig. 9.30 a Diverticula of the colon are frequent in elderly patients. Often they come in larger numbers as part of a diverticulosis. When imaged sideways they are easily perceived as outpouchings of the bowel wall (arrows). b If imaged head-on, things become a little bit more difficult (arrows) unless

a small contrast-air meniscus is visible, which only occurs in diverticula: every diverticulum needs to be differentiated from a polyp. That is one very good reason for getting two perfect views of every large-bowel segment in a barium enema.

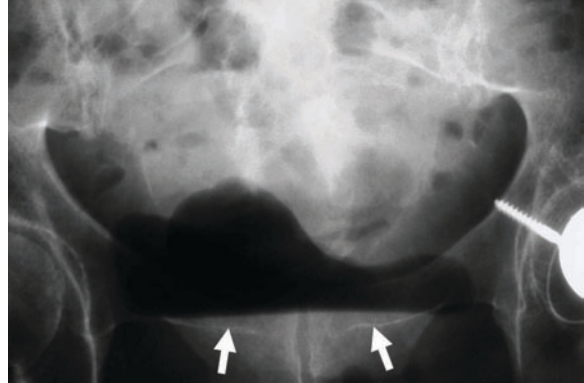


## Complications of Diverticulosis

a Diverticulitis



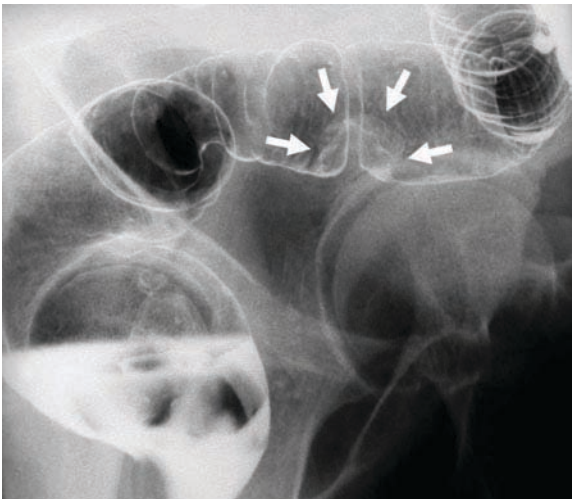
b Fistula formation



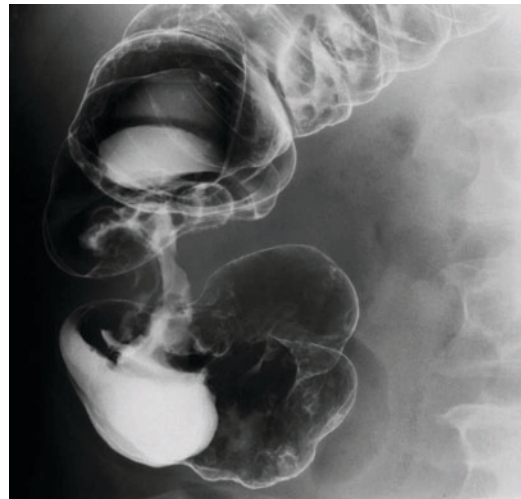
**Fig. 9.31 a** The inflammation of a diverticulum may cause regional inflammation of fat around the affected segment of bowel and can even extend into adjacent organs. A stenosis of the bowel lumen results (black arrows) that must be differentiated from a malignant process on the basis of the symptomatology. An intact mucosal appearance may hint at benign underlying etiology. The existence of other diverticula (white arrow) may point the diagnostician in the right direction, but does not entirely exclude a cancer. **b** In this patient a fistula originating from a diverticulitis has reached the urinary bladder: The air–fluid level (arrows) confirms the finding.

## Polyp of the Colon

a



b

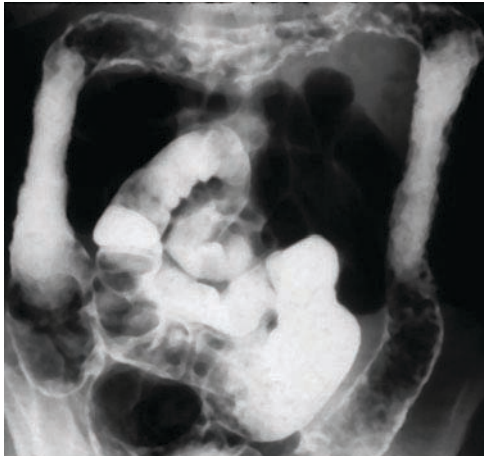


**Fig. 9.32 a** This broad-based sessile polyp (arrows) had already turned malignant. **b** Here you see a carcinoma of the cecum that has caused an incomplete obstruction. Distal to it there

are residual stool particles located in the haustrations—or are these additional polyps?

### Crohn Disease

**a Manifestations in the colon**



**b Anal fistula**

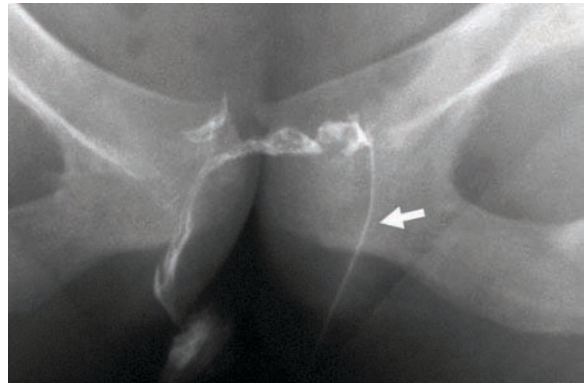
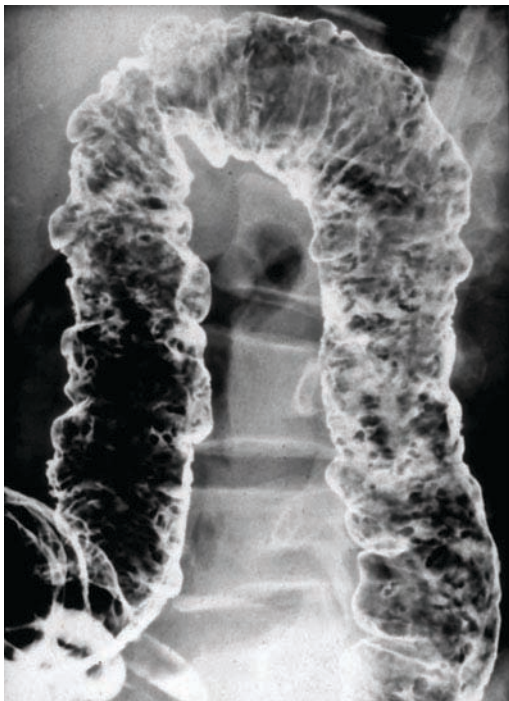


Fig. 9.33 **a** The manifestation of Crohn disease in the colon goes along with the formation of the so-called “cobblestone” pattern of the mucosal surface and a stricture of the involved segments. The sigmoid colon is not involved in this case and

shows a normal width and mucosal pattern. **b** Crohn disease has led to a characteristic anal fistula in this patient. A fine catheter (arrow) was introduced into the perianal opening of the fistula.

### Ulcerative Colitis

**a**



**b**

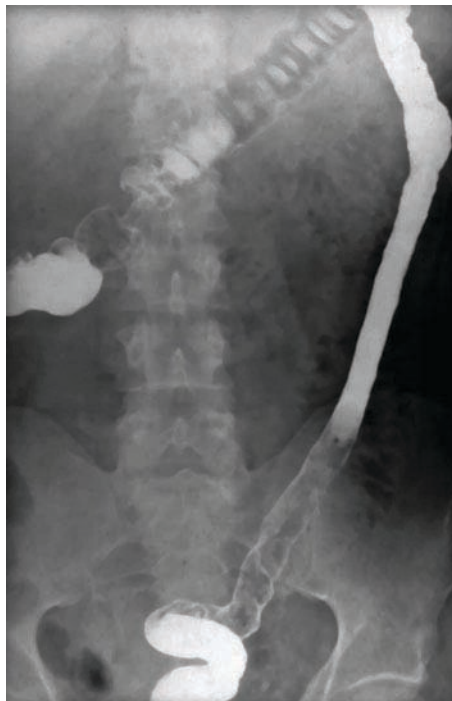

Fig. 9.34 **a** In an early phase of ulcerative colitis the residual islands of relatively normal mucosa appear as pseudopolyps. **b** This advanced ulcerative colitis reaches from the rectum to the splenic flexure of the colon, producing the typical aspect of a “rigid tube.”

## Radiation Stenosis of the Rectum

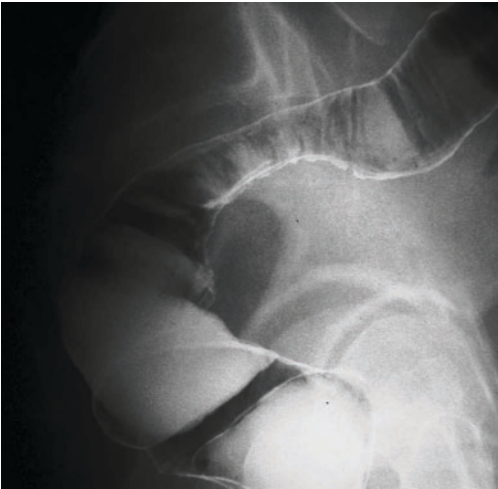


Fig. 9.35 This woman had a pelvic malignant tumor and underwent radiation therapy. Now the rectum in the presacral region is fibrotic and stenosed.

## Tapeworm in the Colon

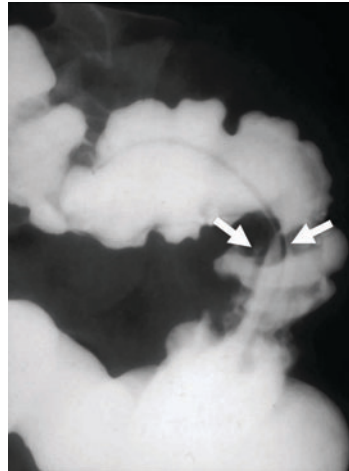


Fig. 9.36 The two parallel lines within the bowel lumen (arrows) indicate the outer wall of the worm. The contrast medium between them is in the bowel of the tapeworm: bowel in bowel, so to say.

**Ulcerative colitis:** Ulcerative colitis is different from Crohn disease in that it has a different pattern of intestinal involvement. It begins in the rectum and progresses proximally in a continuous fashion (Fig. 9.34). Fistulas are hardly ever seen. Up to 10% of all patients per year develop colon cancer, typically after several years of disease, which is why a total colectomy is often performed. Nowadays colorectal surgeons can preserve the patient's anal sphincter and build a new rectal pouch from small bowel, so that the

patients can have a fairly normal life even without their colon and without the need for any external appliances.

**Radiation colitis:** Radiation colitis may develop after radiation therapy has been given to the abdomen and pelvis, for example, in pelvic tumors. Ulcerations and a bowel wall swelling arise that may ultimately result in a segmental bowel stenosis (Fig. 9.35).

## The Ultimate Bleed

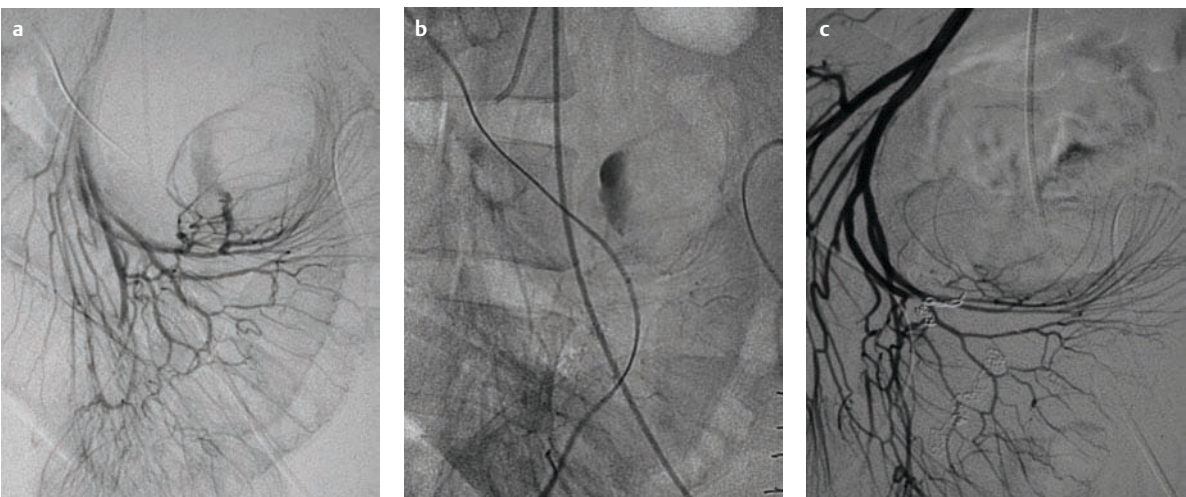


Fig. 9.37 **a-c** Arteriography of the mesenteric vessels is the modality of choice if the hemorrhage necessitates the infusion of packed red cells. The arterial phase (**a**) shows contrast extravasation into a jejunal loop (arrow). A later image after the clearance of vascular contrast demonstrates a persistent con-

trast depot in this location (**b**), which illustrates the force of the bleed. After several embolization coils have been deployed into the major feeding vessels, the bleeding is stopped (**c**). ▶



**Parasitosis of the colon:** Parasites, for example, tapeworms (Fig. 9.36), may set up shop in the bowel as well and need to be considered in the differential diagnosis, especially if the patient has recently traveled to an endemic area or enjoys raw food.

→ **Diagnosis:** Paul has checked the whole list of differential diagnoses, but the appearance, the patient's age, and sheer probability have led him to come to a straightforward conclusion: This is a sigmoid cancer that has led to a partial obstruction of the sigmoid colon. Diverticulitis could certainly produce a similar appearance, but the symptoms do not fit and other diverticula cannot be found. Llewellyn calls Mrs. Herbgarden's primary care physician. He arranges an urgent appointment for her in the surgical clinic during this conversation. Mrs. Herbgarden will visit her physician the next morning to find out about the result of the study and the treatment options.

Dr. Llewellyn takes a little time to tell Paul about the diagnostic handling of more intense and acute bleeds into the gastrointestinal lumen. "If endoscopy is impossible or does not yield any results, radiology comes into the picture. Basically it is the small and large bowel that need to be looked at in that setting. Angiography is the modality for really strong bleeds [Fig. 9.37a–c]. But if the patient does not require infusions of blood at the time of the intervention, chances are low of detecting the source of bleeding with a catheter-based contrast injection into a blood vessel: in that case don't even try an angiogram! On the other hand, if you find it you can embolize it right away! In lower intensity bleeds, nuclear medicine is your only chance: a blood pool scan will show bleeds of as little as 0.1 ml per minute. And you can image the patient over and over again in the first 24 hours after injection without giving more drug, so you can wait until they bleed again and then hunt for the source [Fig. 9.37d, e]."

## 9.6 Problems with Defecation

### Checklist: Disturbances of Defecation

- Is the patient constipated?
- Is the patient incontinent of stool?
- Did the rectal digital examination reveal bleeding or a rectal prolapse?

### An Embarrassing Problem

Samantha Pamper (68) has come to the department with a problem she does not really want to brag about: She has been stool incontinent for a few years and needs diapers when she leaves her home. She has given birth to three children and is grossly overweight. Her social life has suffered quite a bit. Finally she has found a female surgeon she trusts who specializes in incontinence and other rectoanal problems. For proper preoperative planning the surgeon needs to have functional information about the defecation process: she has ordered a defecography for Mrs. Pamper. Llewellyn is the specialist for this type of problem in the radiology department—he has all the utensils for it stowed away in a little cabinet: a camping toilet made of plastic and a large ruler with lead markings. He fixes the toilet to the footstand of the fluoroscopy unit and elevates it to a comfortable sitting position. After the rectal examination he cautiously introduces a large-lumen tube into Mrs. Pamper's rectum and injects a rather thick barium paste. The vagina is also lined with just a little contrast using a smaller tube. Mrs. Pamper is asked to squat on the toilet, ready to be fluoroscoped in a lateral projection with the lead ruler held tight between her thighs.

### The Ultimate Bleed

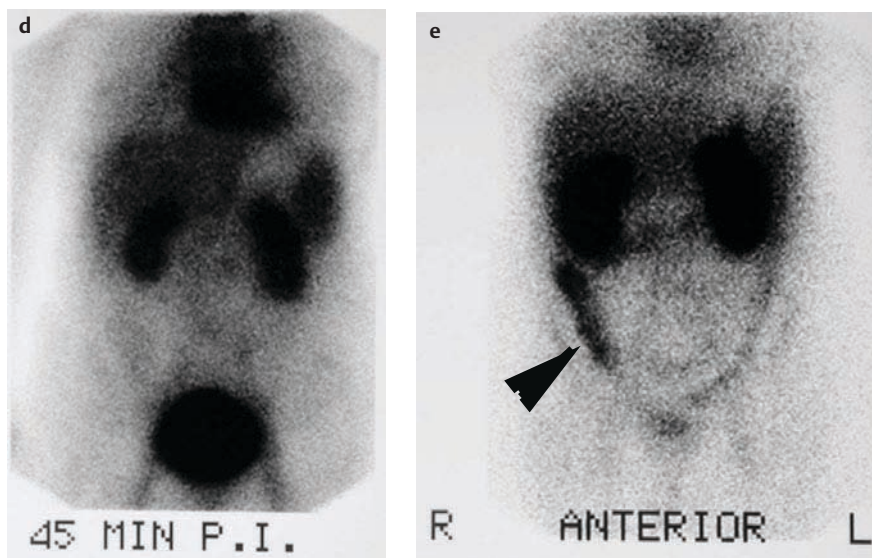


Fig. 9.37 **d** A blood pool scan after administration of technetium-99-labeled red cell in another patient with a less intense bleed shows no abnormality in the first 45 minutes. Kidneys, bladder, liver, spleen, and heart show a homogeneously high radiotracer uptake, as expected. Another scan 20 hours later (**e**) not only indicates the location of the primary bleeding source (arrow) in the cecum but also proves its intrainestinal location because the radiotracer activity is spread out over the colon by the ongoing peristalsis.



**Problems of Defecation**

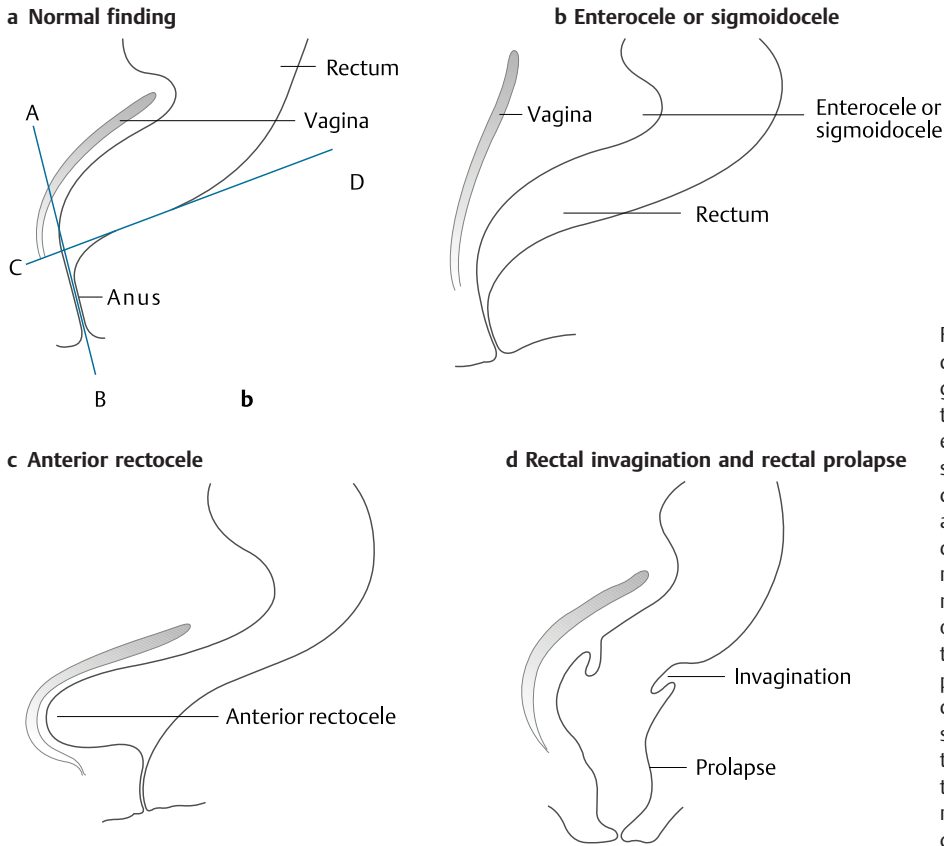


Fig. 9.38 These are the typical findings during defecography. **a** This is a normal situation. **b** In the case of an enterocele, a more proximal segment of bowel prolapses down between the rectum and the vagina during defecation. **c** A rectocele is a significant outpouching of the rectal wall either posteriorly or anteriorly during defecation. The content of this outpouching is not emptied, causing a constant and unsuccessful urge. **d** If the rectum has lost its mooring in the pelvic floor, it invaginates or prolapses during defecation.

“With no other procedure,” Llewellyn says to Hannah, “can we evaluate the defecation so well. It may not be as complex as the swallowing act but quite a few things can definitely go wrong. We make a video during the rest, the push, and the emptying phases; we measure the length of the anal canal and the change of its angle during pushing and expulsion.” After the procedure is finished, Hannah and he review the video together. Mrs. Pamper’s anterior rectal wall bulges toward the vagina quite a bit while she is straining—there is a definite anterior rectocele (Fig. 9.38c, Fig. 9.39), which makes a regular evacuation impossible. The surgeon can now go ahead and plan her therapy.

**Anterior Rectocele**

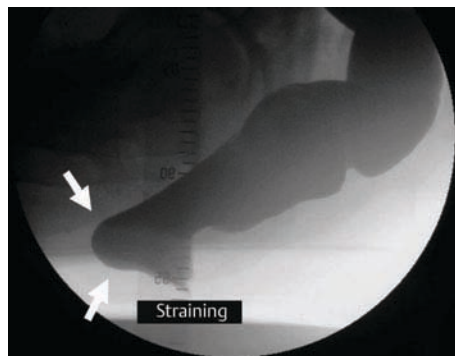


Fig. 9.39 This radiograph done during the straining phase of the defecogram demonstrates an obvious outpouching of the anterior rectal wall that can only be evacuated with great difficulty: This is an anterior rectocele.

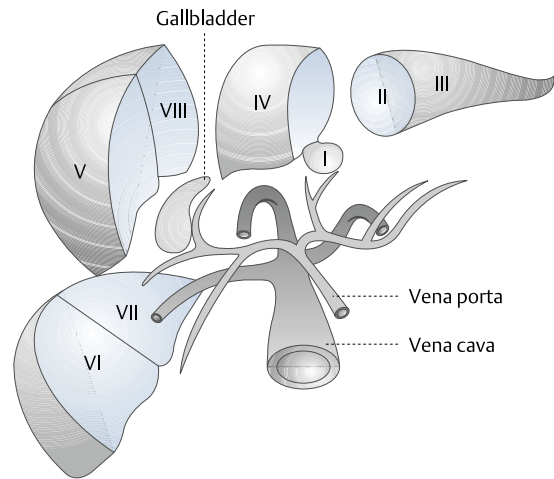
**!** Defecography is a significant intrusion into the privacy of the patient. The setting and the ambiance during the examination must take this into account.

## 9.7 Diseases of the Liver and the Intrahepatic Biliary System

### Focal Liver Lesion

#### Checklist: Focal Lesion(s)

- One or many? Homogeneous or inhomogeneous texture on imaging?
- Does the density or signal of the lesion resemble that of fat or water or is it different?
- Does the lesion enhance after contrast administration (peripherally, centrally, centripetally)?
- Is it calcified? Is it septated?
- Are the lymph nodes around the liver hilum enlarged?



#### This Thing in the Liver

Georgina Goodlooks (35) is still in shock. During an ultrasound examination of her abdomen a suspicious lesion was found in the liver, the precise nature of which remained unclear. Ajay reviews the MR images of Mrs. Goodlooks' liver together with friendly Dr. Longbreak (Fig. 9.40). Ajay finds the lesion and assigns it to segment V/VI of the liver.



#### How Can You Remember Liver Segments According to Couinaud?

This is a surgical classification of liver segments based on the veins of the liver, the major landmarks for surgeons during a liver operation.

The portal vein marks the division between the caudal and cranial segments. Imagine you are a surgeon and view the liver through the opened abdomen of the reclining patient. You are looking at the liver hilum from underneath. The caudate lobe extends downward like a finger—that is segment I.

From there you move counterclockwise around the hilum. First grab the dorsal (segment II) and the ventral (segment III) segments of the lateral left lobe of the liver. Now cross over the ligamentum teres to the medial part of the left liver lobe (cranially: segment IVa, caudally: segment IVb). Jump over the gallbladder further to the right lobe of the liver—segments V and VI. Finally feel (deep underneath the diaphragm) the cranial segments of the right liver—laterally segment VII and medially segment VIII.

Ajay first checks whether the lesion is really singular. Then he studies the internal structure with care. He works through the differential diagnoses one after the other—first the cystic and then the solid liver lesions.

#### → What is Your Diagnosis?

**Congenital liver cysts:** Congenital liver cysts are a frequent incidental finding. They can be diagnosed with great certainty by ultrasound (Fig. 9.41a) and by computed

#### The Case of Georgina Goodlooks

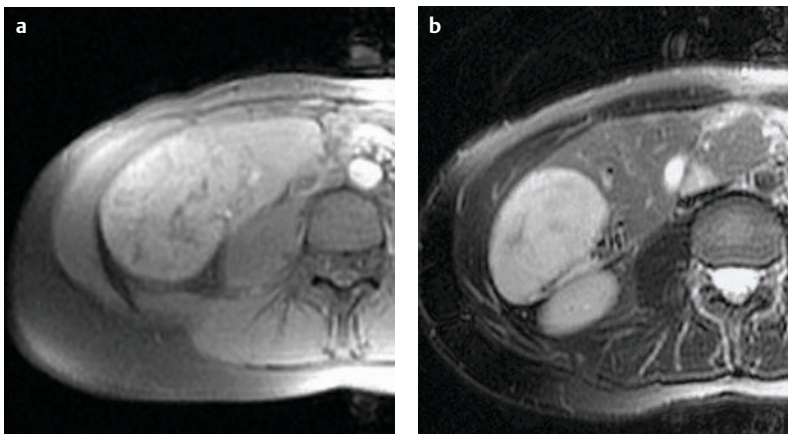


Fig. 9.40 Look at these crucial MR sections of Georgina Goodlooks: in axial T1-weighting with contrast (a); in axial T2-weighting (b).

### Congenital Liver Cyst

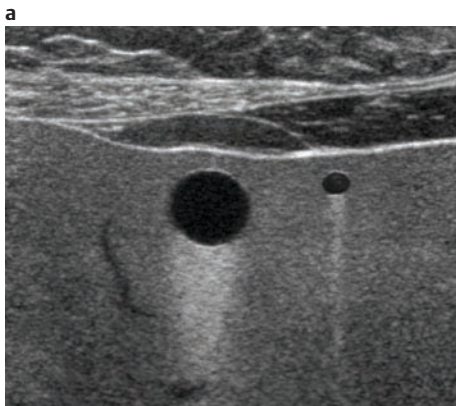
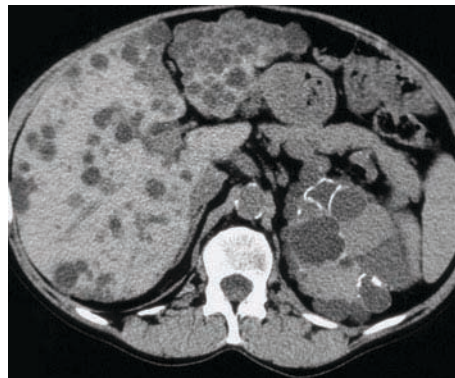
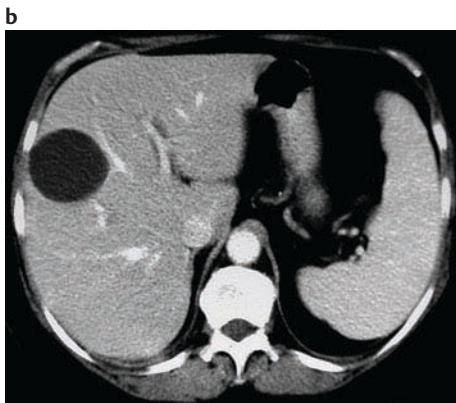
Fig. 9.41 **a** A developmental liver cyst displays a sharp margin, echo free contents, and a distal amplification of the echo. **b** This cyst, located in liver segment VIII after Couinaud, has the density of water and a sharp margin and does not enhance after contrast administration (left). Frequently one finds associated renal cysts, particularly in polycystic liver and kidney disease (right).



### Echinococcal Cyst

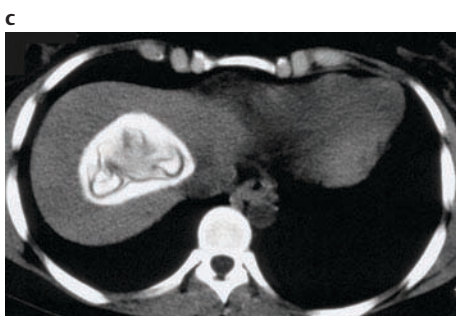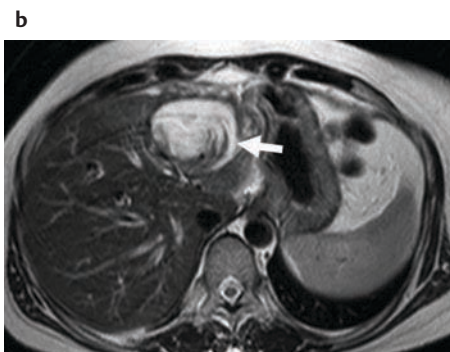
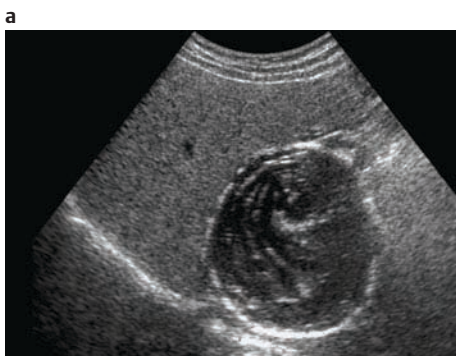


Fig. 9.42 **a** The ultrasound examination finds the cyst at the underside of the liver. It contains numerous internal layers and structures. **b** In another patient a T2-weighted MRI shows the daughter cysts as defects within the cyst fluid (arrow). **c** After the interventional ablation of an echinococcal cyst with a mixture of alcohol and contrast, the remnants of the parasites are seen suspended in the cyst.



tomography (Fig. 9.41b). Often kidney cysts are also found, particularly in *polycystic liver disease*. Approximately 70% of patients with polycystic liver disease (Fig. 9.41b) also have polycystic kidney disease. Very rarely a necrotizing metastasis presents as a cystic mass in the liver.

**Hydatid cyst:** When the parasite *Echinococcus granulosus* (dog tapeworm) sets up shop in a human liver, it creates one or several cysts the walls of which typically have three layers and several appearances on imaging: They can look like normal cysts; they can contain so-called “hydatid sand”; they may show septations and their walls can calcify (Fig. 9.42). Patients tend to come from rural areas where dogs—the definitive hosts of the worm—are kept to herd livestock. The verification of the diagnosis is done serologically or by demonstrating scolices, the larval stage, in the cyst fluid during aspiration. Therapy today is often performed by the interventional radiologist. The lesion is punctured percutaneously and alcohol or hypertonic saline solution mixed with contrast medium is injected (Fig. 9.42c) under CT guidance.

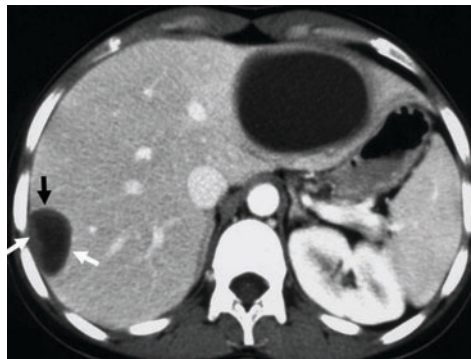
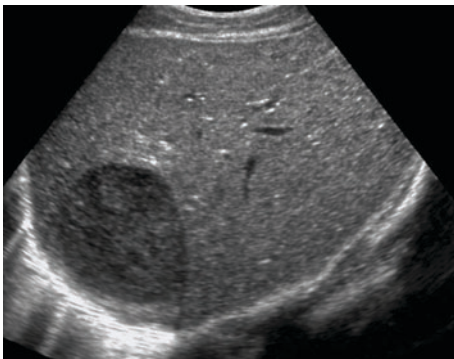
#### Liver abscess:

**Amebic abscess:** Amebic abscesses in the liver are typically caused by *Entamoeba*, which is endemic in developing countries. However, certain groups in developed countries are at high risk, such as recent immigrants and institutionalized patients, and it is found in the stool of up to 30% of sexually active homosexual men. Amebic abscesses can be single or multiple; they develop in up to 7% of all patients with acute or recurring intestinal amebiasis, that is, 10% of the world population. In the industrialized world the abscesses are rare because *Entamoeba histolytica* is transmitted by contaminated water. Their appearance in ultrasound and CT (Fig. 9.43a) is not very specific. It is the patient history and the serology that confirm the diagnosis.

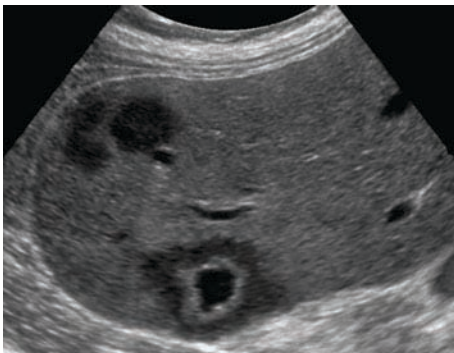**Bacterial (pyogenic) abscess:** A bacterial abscess in the liver can develop via five major routes: ascending cholangitis often associated with biliary obstruction; through the portal circulation (appendicitis, diverticulitis); through the hepatic artery (septicemia, bacterial endocarditis); through direct extension from adjacent organs (perforated

### Liver Abscess

#### a Amebic abscess



#### b Bacterial abscess



#### c Mycotic abscess

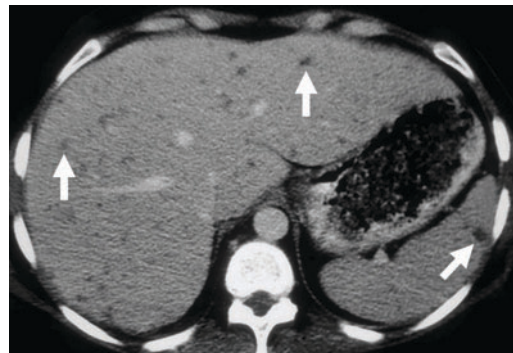

Fig. 9.43 **a** An amebic abscess appears sonographically as a hypoechoic lesion with a few internal echoes (left). In the CT of another patient (right) the wall of the amebic abscess (arrows) is thicker than that of a normal developmental cyst (see also Fig. 9.41b). **b** The transverse ultrasound image of the liver demonstrates several hypoechoic lesions anteriorly and a better-demarcated lesion dorsally with significant wall

thickening. This is a typical bacterial abscess. **c** In another patient with an acute myelogenous leukemia (AML) in neutropenia, multiple small abscesses are dispersed over the liver and spleen (arrows) that do not show any peripheral enhancement after contrast administration (check the vessels for the contrast!). This is the pathognomonic pattern of hepatosplenic candidiasis.



## Caroli Disease

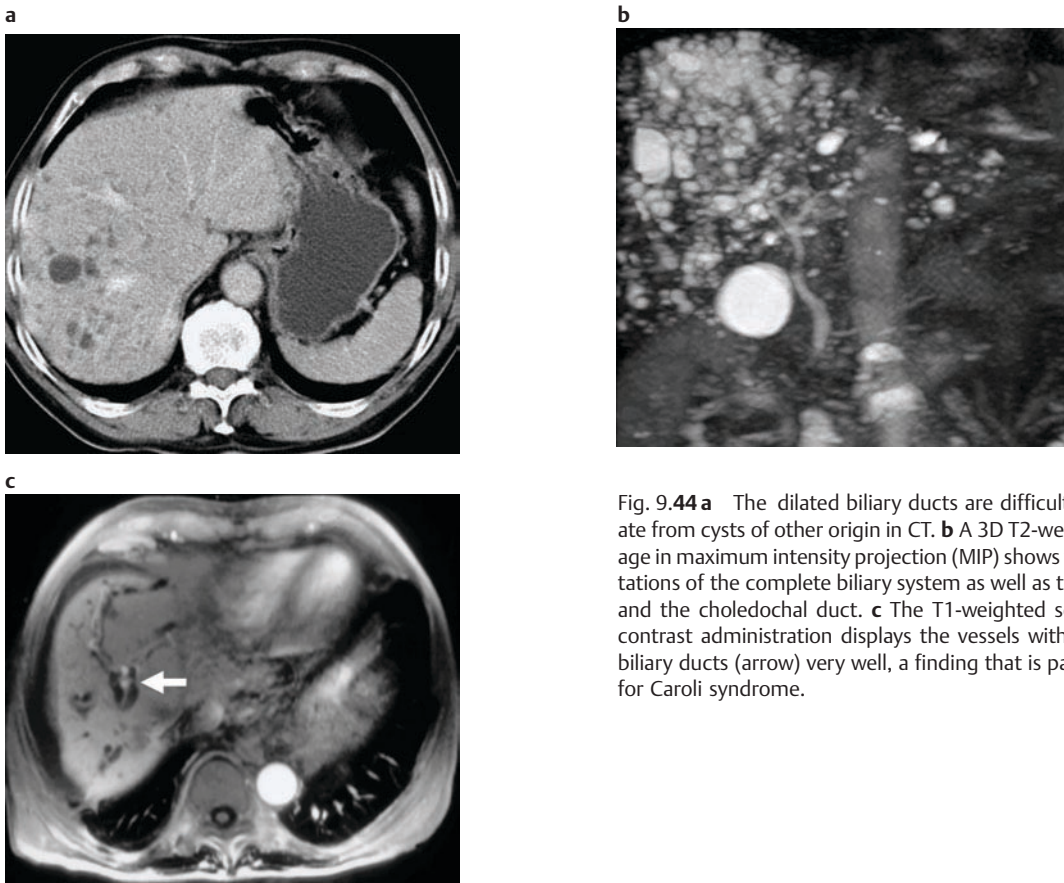


Fig. 9.44 **a** The dilated biliary ducts are difficult to differentiate from cysts of other origin in CT. **b** A 3D T2-weighted MR image in maximum intensity projection (MIP) shows the cystic dilations of the complete biliary system as well as the gallbladder and the choledochal duct. **c** The T1-weighted sequence after contrast administration displays the vessels within the dilated biliary ducts (arrow) very well, a finding that is pathognomonic for Caroli syndrome.

duodenal ulcer, perinephric or subphrenic abscess); and as a complication of trauma (penetrating injuries). Depending on the content and the age of the abscess it can have no, little, or a strong internal echo on ultrasound. The type of margin also varies widely. In the final stage the abscess has a thick wall that enhances strongly after contrast administration (Fig. 9.43b). The patients are severely ill.

**Mycotic abscess:** Mycotic abscesses are often disseminated and tend to occur in immunocompromised patients (candidiasis). They may be small, and can be difficult to detect on CT as contrast enhancement is typically absent (Fig. 9.43c).

**Caroli syndrome:** The congenital and very rare Caroli syndrome goes along with segmental cavernous ectasia of bile ducts in the liver (Fig. 9.44a). Morphologically it must be differentiated from other cystic processes. The proof of a communication of the cysts with the biliary system is reached by endoscopic retrograde cholangiopancreatography (ERCP) or by magnetic resonance cholangiopancreatography (MRCP), for example in MIP (maximum intensity projection) (Fig. 9.44b). In this sequence the T2 weighting is so extreme that only fluids are visualized. The individual images are then added up to form a three-dimensional model.

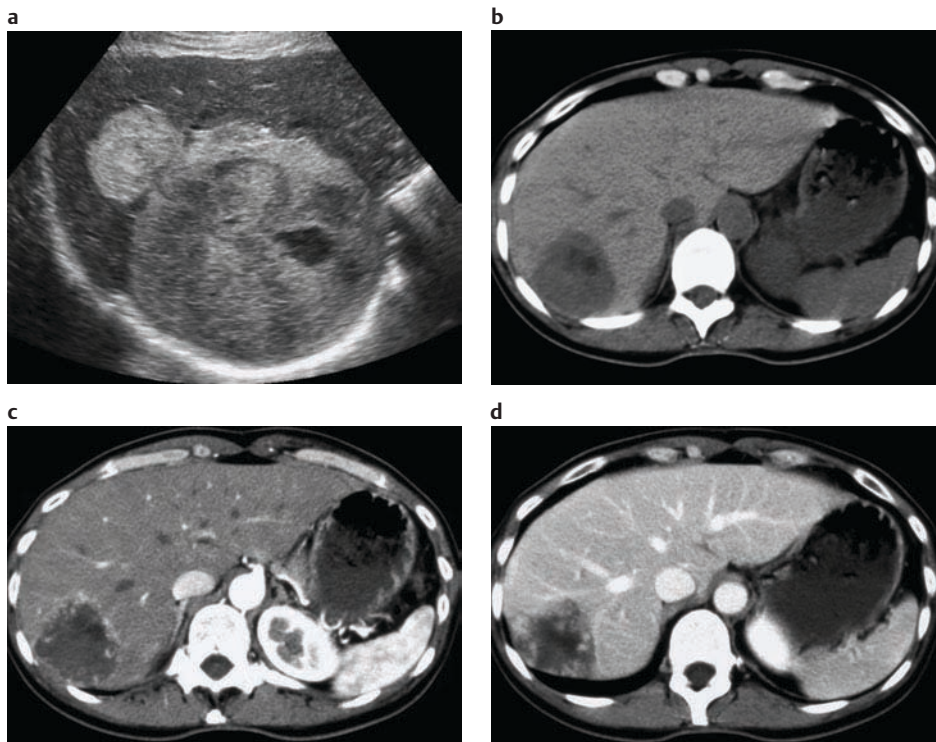
Patients are predisposed to developing biliary stones and may present with recurrent attacks of cholangitis. Vessels typically run centrally through the cysts (Fig. 9.44c). Patients suffer from a 100-fold increased risk of developing bile duct carcinoma.

#### Benign liver tumors:

**Liver hemangioma:** A hemangioma is present in approx. 5% of all patients and is the most common benign tumor of the liver. On ultrasound it displays a typical high echogenicity (Fig. 9.45a). In multiphasic contrast-enhanced CT it typically demonstrates nodular peripheral contrast enhancement on early contrast phase, which gradually progresses to the center and is difficult to differentiate from the normal liver parenchyma in late-phase scans (Fig. 9.45b–d).

**Liver adenoma:** Adenomas of the liver occur particularly in females after the regular intake of oral contraceptives. On ultrasound they tend to be echogenic, on CT and MRI they enhance markedly after contrast administration (Fig. 9.46). Imaging is not specific enough to permit omission of histological proof. Adenomas can reach a significant size and occasionally hemorrhage and rupture, resulting in a surgical emergency.

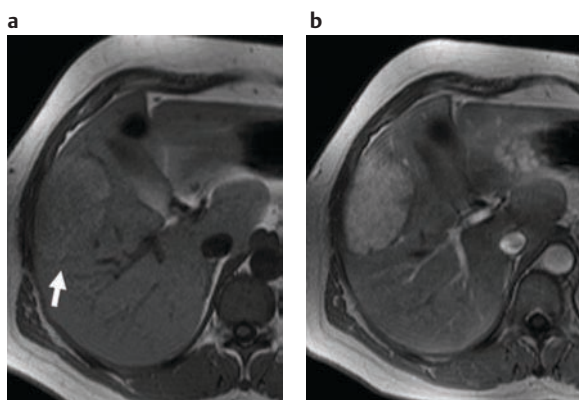
### Liver Hemangioma



**Fig. 9.45 a** This giant hemangioma shows some hypoechoic and cystic areas within a tumor that otherwise exhibits the typical hyperechoic signal. **b** The CT of another patient displays the hemangioma as a hypodense lesion with ill-defined margins before contrast administration. **c** In the arterial contrast phase the peripheral vessels fill rapidly, giving the lesion an appearance

that reminds some of cotton blossoms (“cotton-wooling”). **d** In the later phases, the cavernous spaces of the hemangioma fill up completely with contrast and eventually the tumor becomes isodense to surrounding liver. This may, however, take several minutes.

### Liver Adenoma



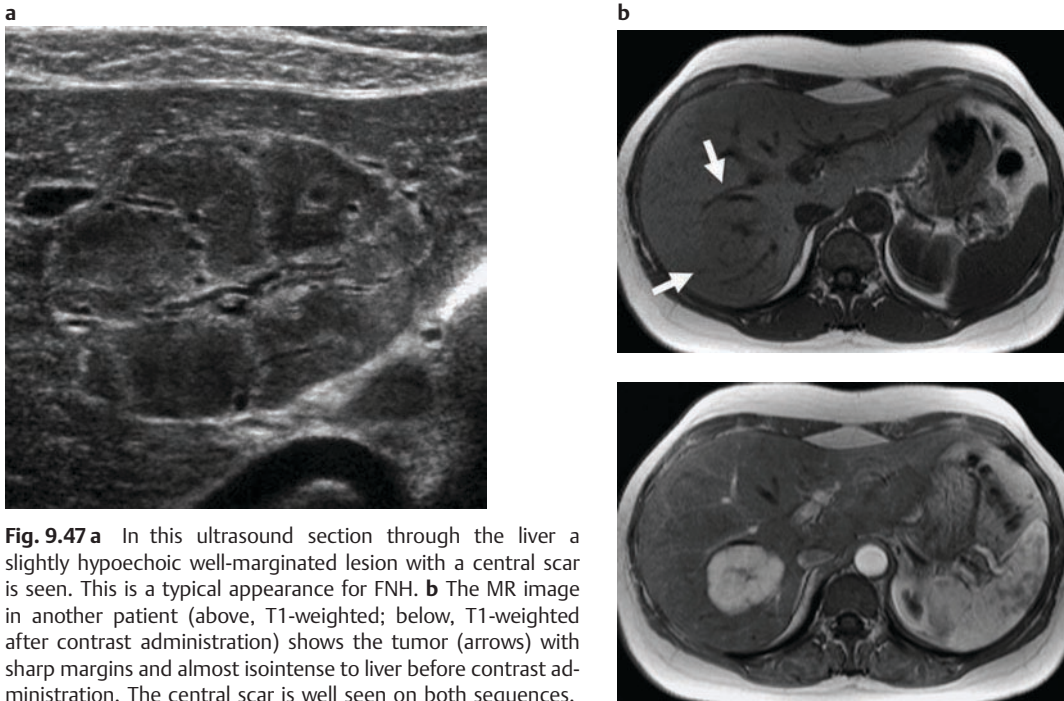
**Fig. 9.46 a** The T1 sequence without contrast shows a rather well demarcated lesion. **b** After gadolinium administration it enhances significantly.

**Focal nodular hyperplasia (FNH):** FNH is the second most common benign liver tumor, seen predominantly in women taking contraceptives. On ultrasound the tumor has clear margins, little echo, and a central scar (Fig. 9.47a). On CT the lesion appears hypodense on noncontrast images and enhances rapidly with contrast on arterial phase CT, when it is hyperdense compared to surrounding liver parenchyma. At that time the relatively hypodense central scar may be most discernible. The lesions may become isodense to liver parenchyma on venous phase imaging and may be difficult to detect if only a monophasic contrast CT is performed. On MRI in T1 weighting, the tumor is isointense to liver and enhances markedly after gadolinium is given intravenously (Fig. 9.47b).

#### Malignant liver tumors:

**Metastases:** Metastases are the most frequent malignant lesions in the liver—18 times more frequent than a primary liver cell carcinoma. The liver is also one of the most common localizations of metastases, second only to the lymph nodes. Liver metastases originate primarily from carcinomas of the large bowel, stomach, pancreas, breast, and lung. They are supplied with blood mainly via the hepatic

## Focal Nodular Hyperplasia (FNH)



**Fig. 9.47 a** In this ultrasound section through the liver a slightly hypoechoic well-margined lesion with a central scar is seen. This is a typical appearance for FNH. **b** The MR image in another patient (above, T1-weighted; below, T1-weighted after contrast administration) shows the tumor (arrows) with sharp margins and almost isointense to liver before contrast administration. The central scar is well seen on both sequences.

arteries, while the liver parenchyma is mainly dependent on the portal venous system. For that reason their differential contrast compared to the normal surrounding liver parenchyma is most pronounced and their detectability is best during the portal venous contrast phase. Their appearance on ultrasound (Fig. 9.48a) and in CT (Fig. 9.48b) is highly variable. Essential observations are number and pattern of involvement of hepatic segments (which may determine treatment options). Findings need to be correlated with the age and history of the patients.

**Hepatocellular carcinoma (HCC):** Hepatocellular carcinoma is the most frequent malignant liver tumor. Up to 5% of the Japanese population will eventually develop HCC, particularly in the third to fifth decades of life. In Europe and North America, HCC is associated with liver cirrhosis and hemochromatosis. The patients are also older. Alpha-fetoprotein is almost always increased in patients with HCC. The ultrasound appearance of HCC is nonspecific (Fig. 9.49a). On contrast-enhanced CT or MRI the tumor enhances strikingly in the arterial phase of contrast administration (Fig. 9.49b). The therapy can be—as for metastases, by the way—percutaneous and can be done by the interventional radiologist: chemoembolization or image-guided instillation of alcohol, laser-induced thermotherapy (LITT), and radiofrequency ablation can be the sole or supportive therapy in the right setting.

**Cholangiocellular carcinoma (CCC):** Cholangiocellular carcinoma originates from the biliary epithelium. It is the second most frequent malignant liver tumor and it may be located intrahepatically or in the hilum of the liver. The intrahepatic type often displays mixed echogenicity

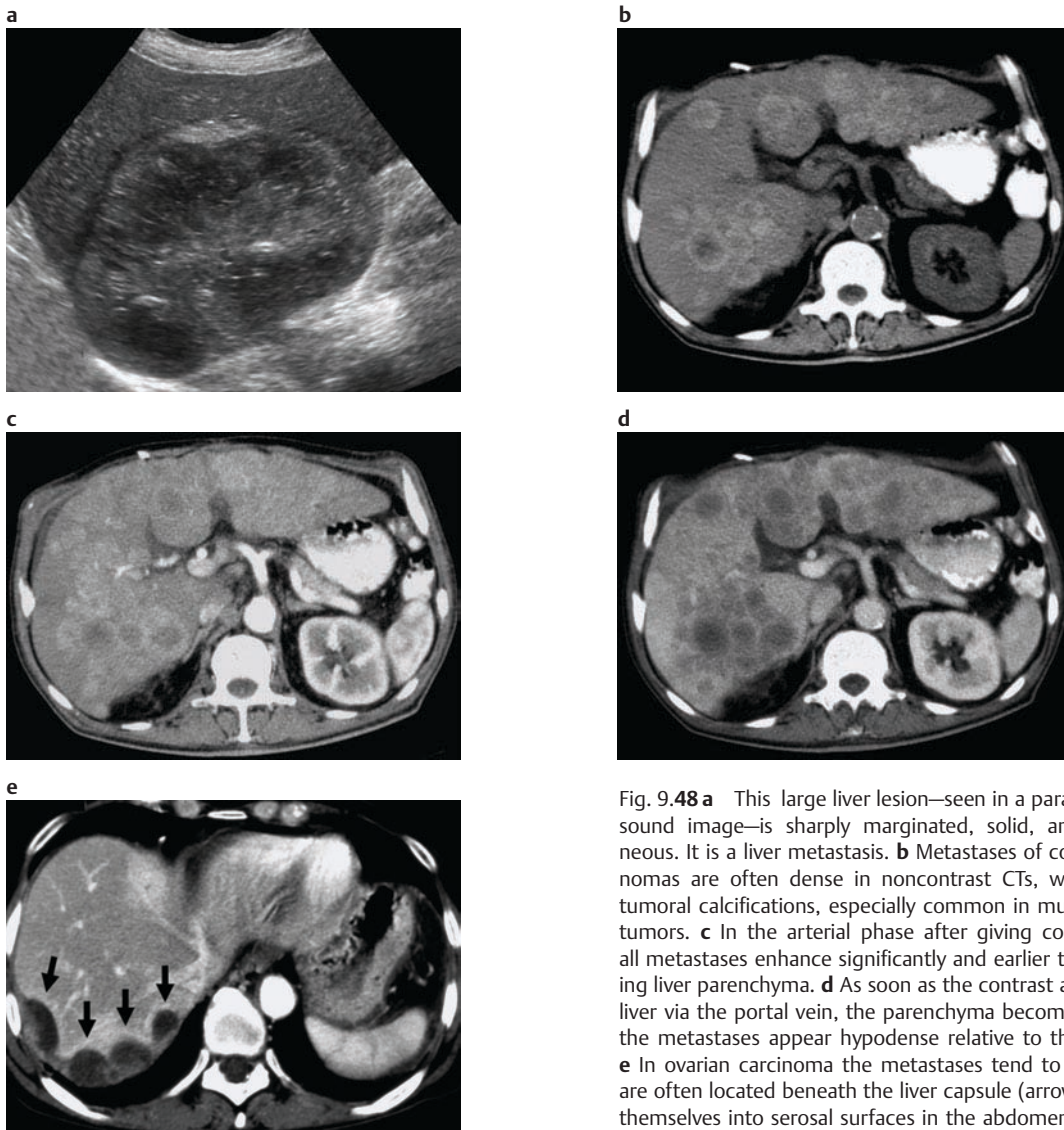
on ultrasound without biliary stasis in the vicinity (Fig. 9.50a). On CT the tumor is partially hypodense, with an irregular serpiginous enhancement of the tumoral periphery after contrast administration (Fig. 9.50b, c). On delayed images, the tumor may retain more contrast than surrounding hepatic parenchyma and thus become conspicuous.

**Fibrolamellar carcinoma:** This carcinoma is very rare. It occurs in the young and without any preexisting liver cirrhosis. It may be impossible to differentiate from focal nodular hyperplasia.

→ **Diagnosis:** Ajay's head buzzes with all the information and different possibilities. So many different appearances, so many modalities to choose from! And—has this examination made any difference at all or is he as smart as he was before? Longbreak takes the time to set the poor fellow straight again. “Generations of academic radiologists have made their career on the imaging of liver tumors—so it can't be that simple, can it?” he chuckles. He gives Ajay a hand with the image analysis. They decide together that they are dealing with a solitary liver lesion. Mrs. Goodlooks has no history of malignancy. A singular metastasis seems less likely but is not impossible. The lesion is definitely not cystic. Liver cysts and most parasitic lesions fall out of the differential list right there. Liver cirrhosis (see p. 209) is not present, which makes HCC unlikely. They cannot find enlarged lymph nodes elsewhere in her abdomen on this study. Mrs. Goodlooks is on oral contraceptives—that would go along well with an adenoma or FNH. Ajay knows that both are fortunately benign



## Liver Metastases



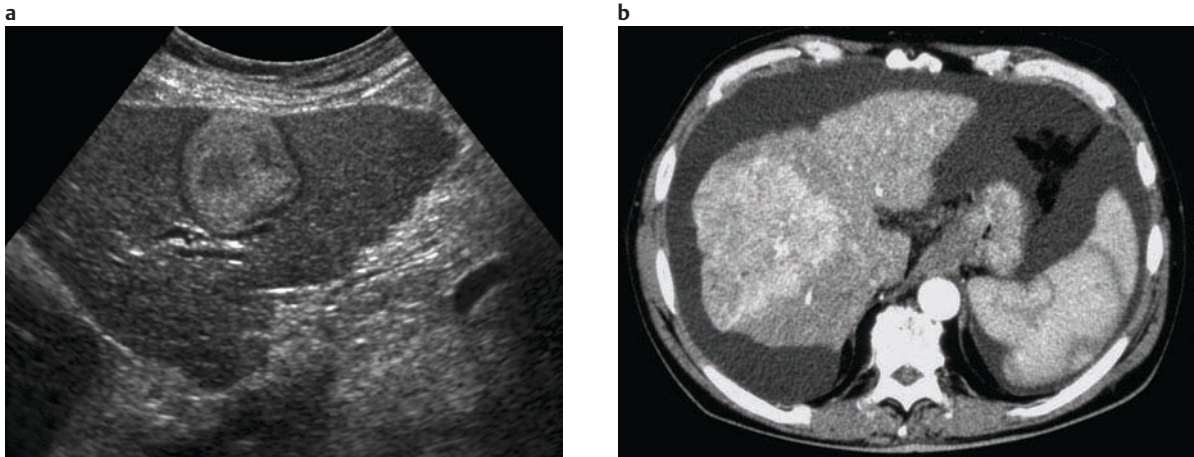
**Fig. 9.48** **a** This large liver lesion—seen in a paramedian ultrasound image—is sharply margined, solid, and inhomogeneous. It is a liver metastasis. **b** Metastases of colorectal carcinomas are often dense in noncontrast CTs, which indicates tumoral calcifications, especially common in mucin-producing tumors. **c** In the arterial phase after giving contrast, almost all metastases enhance significantly and earlier than surrounding liver parenchyma. **d** As soon as the contrast also enters the liver via the portal vein, the parenchyma becomes denser and the metastases appear hypodense relative to the liver tissue. **e** In ovarian carcinoma the metastases tend to be cystic and are often located beneath the liver capsule (arrows) or implant themselves into serosal surfaces in the abdomen.

lesions and is quite happy that the news for Mrs. Goodlooks is good. Longbreak spoils his excitement somewhat when he explains that adenomas tend to hemorrhage and are frequently resected for that reason; the FNH is difficult to differentiate from fibrolamellar carcinoma. Either a short-term follow-up is needed or a tissue sample must be retrieved. The biopsy is done on the following day and confirms the adenoma. Mrs. Goodlooks discontinues her oral contraceptives and is invited for a follow-up ultrasound or MRI in three months to confirm the size decrease of the adenoma.

**!** Normal cysts and most hemangiomas can be diagnosed with sufficient certainty solely by imaging. Lesions of infectious or parasitic origin tend to come with a fitting clinical symptomatology and history. Multiple solid lesions are metastases until proven otherwise. In all other doubtful cases, short-term follow up is warranted, or tissue samples need be taken, or the lesion needs be removed completely.



### Hepatocellular Carcinoma (HCC)

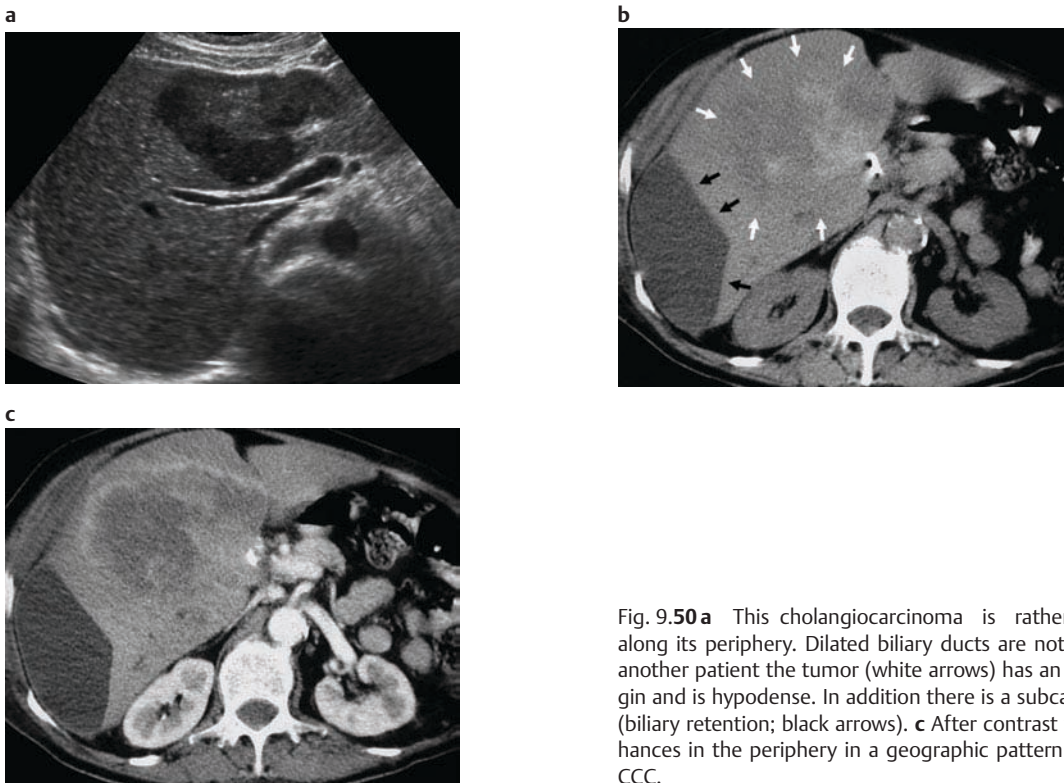


**Fig. 9.49 a** The ultrasound depicts an encapsulated lesion that is partially hyperechoic, partially internally isoechoic compared to surrounding parenchyma. The liver contour is irregular, the liver edge rounded—all of this fits well with a liver cirrhosis that is associated with a higher risk of developing HCC. **b** In this typical case of a hepatocellular carcinoma the liver is diffusely cirrhotic: the parenchyma has a nodular appearance. Ascites

is also present already. The early arterial phase after contrast administration (do you see the “tiger pattern” of the spleen?) documents the forceful enhancement of the tumor. (By the way: In which segments according to Couinaud is the tumor located?)

The tumor involves segments VII and VIII.

### Cholangiocellular Carcinoma (CCC)



**Fig. 9.50 a** This cholangiocarcinoma is rather hypoechoic along its periphery. Dilated biliary ducts are not present. **b** In another patient the tumor (white arrows) has an irregular margin and is hypodense. In addition there is a subcapsular biloma (biliary retention; black arrows). **c** After contrast the tumor enhances in the periphery in a geographic pattern often seen in CCC.

## Diffuse Liver Disease

### Checklist: Diffuse Liver Lesion

- Is there alcohol abuse?
- Is the patient overweight?
- Has the patient received chemotherapy?
- Is there a history of chronic hepatitis?
- Is there right cardiac failure?

### This Liver Has Done Overtime

Violetta Countess Campari (62) has been examined as part of her follow-up protocol for a previous breast carcinoma. The referring oncologist is naturally interested in whether she has developed any metastases. Giufeng has not found any focal lesions in the liver. She already wants to pass on to the next patient as Gregory comes by and views the images on the monitor with awe. "Just look at that! I need a copy of these," he shouts. "Boy, this is textbook stuff!" Giufeng is taken by surprise; she returns to the scanner and takes another careful look at the images (Fig. 9.51).

### The Case of Violetta Countess Campari

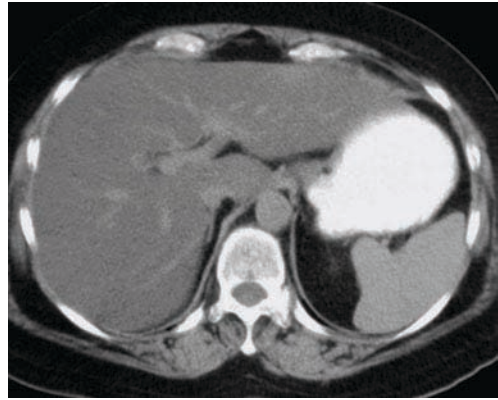


Fig. 9.51 Look at this decisive CT scan of Countess Campari. Can you find anything?

### → What is Your Diagnosis?

**Fatty liver:** Another term for this is hepatic steatosis, a frequent incidental finding in liver examinations (Fig. 9.52a, b). Pathologists see it in approx. 25% of all

### Steatosis of the Liver

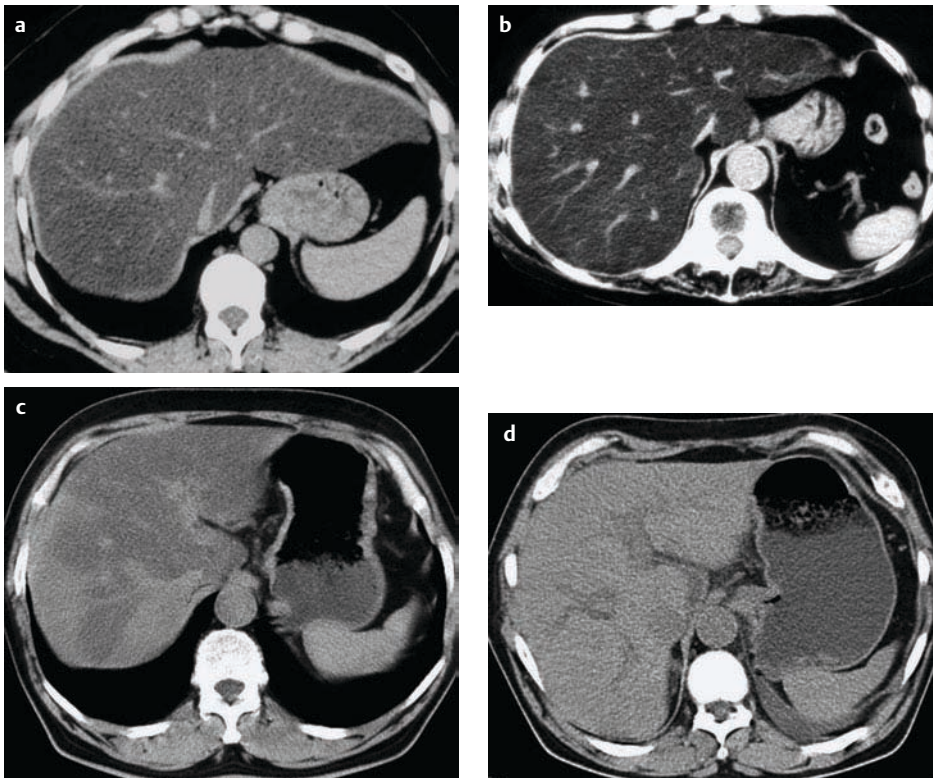
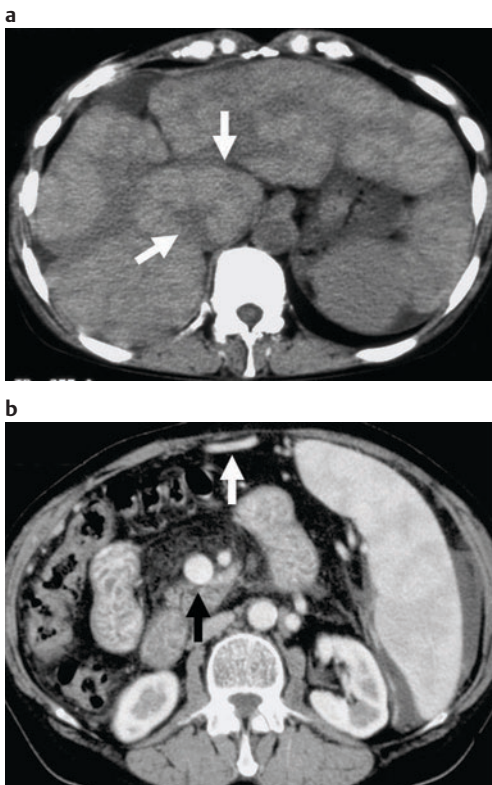


Fig. 9.52 **a** On noncontrast CT images of the liver the vessels appear brighter than the hepatic parenchyma. Normally it is just the other way round. This is a typical finding in fatty liver. **b** The difference in density naturally becomes even more pronounced after

contrast is administered intravenously. If the steatosis is less severe, the vessels may become invisible altogether. **c** This CT-section shows a regional steatosis after chemotherapy. **d** Eight weeks later the liver has returned to its normal homogeneous appearance.



### Liver Cirrhosis



**Fig. 9.53 a** In this patient with advanced liver cirrhosis, dense regeneration nodules are detectable even before contrast is administered. The surface of the organ is nodular, the caudate lobe (arrows) is enlarged. **b** If a portal hypertension ensues, the spleen is enlarged, the superior mesenteric vein is often congested (black arrow), and the umbilical vein is recanalized and dilated as part of a collateral system (white arrow), which allows blood to bypass the liver and drain into systemic veins. Note the ascites around the spleen.

otherwise healthy adults. It can develop within a few weeks and can also disappear within such a time frame. In addition to an unhealthy fatty diet and alcohol abuse, diabetes mellitus or chemotherapy can lead to this effect (Fig. 9.52c). The steatosis can encompass the whole liver (fatty liver) or remain segmental. If a small part of the liver is spared from the fatty infiltration it can take the appearance of a (pseudo)liver lesion on CT or ultrasound. For obvious reasons, this must be differentiated from focal liver disease such as a primary or secondary tumor. Circumscribed fatty infiltration of the liver parenchyma is often seen adjacent to the falciform ligament. In critical cases, MRI with and without fat saturation or a core biopsy will help differentiate true liver lesions from focal sparing in a patient with otherwise fatty liver.

**Liver cirrhosis:** Liver cirrhosis manifests itself with a few changes that can be visualized with imaging modalities. The liver volume increases in the early phase, the outer

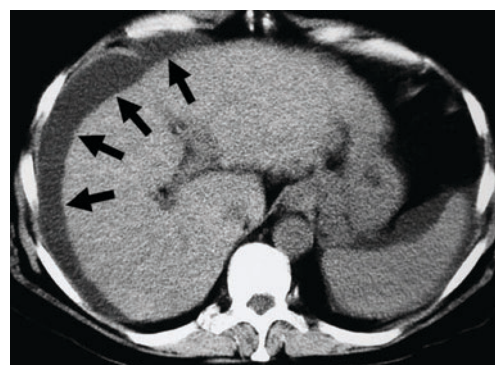
contour becomes irregular, and regenerative nodules develop (Fig. 9.53a). Later the liver may shrink and, as a consequence of progressive fibrosis around the portal vessels and bile ducts and the disorganized regeneration of hepatocytes in nodules, the microcirculation of the liver is gradually destroyed and portal hypertension develops (Fig. 9.53b). The consequences are an enlarged spleen, ascites, and increase in the size of collateral veins, which decompress the portal system into the systemic venous circulation, frequently via the veins of the gastric fundus and the esophagus as well as in the retroperitoneum into the left renal vein. These enlarged veins are called varices and bleed easily, a potentially lethal event. The interventional radiologist can create a shortcut from a large portal vein branch into a large hepatic vein within the liver itself by implanting a transjugular intrahepatic portovenous stent-shunt (TIPSS), thus relieving the abnormally high pressure in the portal venous system (see p. 108).

**!** In a nodular cirrhotic liver, focal lesions such as metastases or hepatocellular carcinomas can be masked and can remain undetected.

**Hemochromatosis:** Hemochromatosis, an abnormally increased iron deposition within the liver, is easily appreciated even on noncontrast CT because the liver density is diffusely increased in comparison with the spleen and the liver vessels (Fig. 9.54). Later a liver cirrhosis develops with all the potential side effects and consequences. The disease occurs in young adults and often necessitates liver transplantation.

→ **Diagnosis:** Giufeng must confess that she simply overlooked the extensive but homogeneous fatty infiltration of Countess Campari's liver. Gregory knows why: "You probably concentrated too much on the patient's history. There were no metastases and so the examination was all finished for you. Could also have been a simple case of 'satisfaction of search.' You're lucky—in this case it's not a problem. But I definitely need one of the images for my teaching file."

### Hemochromatosis



**Fig. 9.54** The density of the liver is increased relative to the density of the spleen. The liver has already developed a cirrhosis, its surface is irregular, and ascites abounds (arrows).



## 9.8 Diseases of the Extrahepatic Biliary System

### Checklist: Diseases of the Extrahepatic Biliary System

- Is there jaundice?
- Is there a history of biliary colic?
- Does the patient have known gallstones?

#### A Man Sees Yellow

Don Cramp (55) has complained about nonspecific pain in the upper abdomen for two days. His general practitioner has a suspicion that his eyes have turned yellow just a bit. Joey is covering CT today. Mr. Cramp comes straight from the internal medicine clinic and an ultrasound examination to the CT unit. The ultrasound report is handwritten and impossible to decipher. Joey puts it aside to concentrate on the CT examination (Fig. 9.55).

#### The Case of Don Cramp

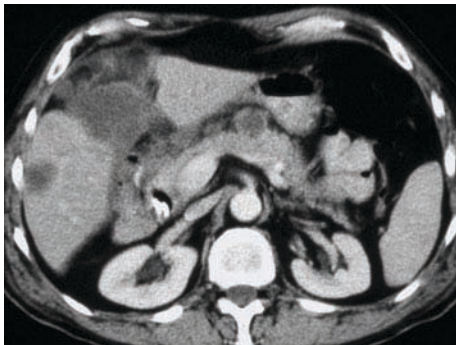

Fig. 9.55 What is there to see on this CT section of Mr. Cramp?

#### → What is Your Diagnosis?

**Cholelithiasis:** Gallstones are frequently and definitively diagnosed by ultrasound (Fig. 9.56a). Often they are an incidental finding without any symptoms whatsoever. The relevant complications of cholelithiasis are:

**Acute cholecystitis:** This acute inflammation of the gallbladder is frequently the consequence of an obstruction of the cystic duct or the infundibulum of the gallbladder due to a stone. On ultrasound the thickening of the gallbladder wall is typical (Fig. 9.56a), and sometimes there is an accompanying inflammatory reaction of the neighboring liver parenchyma (Fig. 9.56b). The diagnosis of cholecystitis is made on the basis of the clinical picture, however.

### Cholelithiasis and Its Consequences

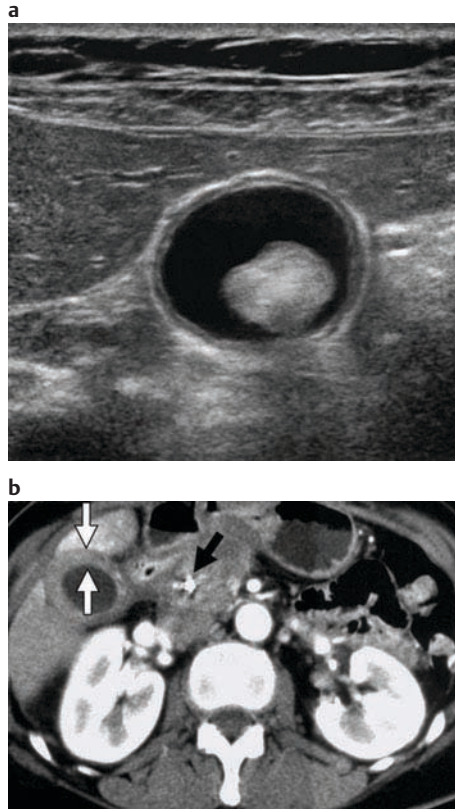


Fig. 9.56 **a** The stone within the gallbladder is seen well sonographically—the distal acoustic shadow is quite characteristic. The gallbladder wall shows normal thickness. **b** This stone in the common bile duct of another patient (long arrow) has led to a swelling of the gallbladder wall as part of an acute inflammation (cholecystitis, short arrows). The thickness of the bladder wall exceeds the normal value of 1–2 mm.

**Stone migration/stone impaction:** A migration of a stone into the cystic duct and onward into the common bile duct is always accompanied by colicky pain. If the stone becomes impacted in the infundibulum of the bladder or in the cystic duct, thereby occluding or severely narrowing the common bile duct from outside (Mirizzi syndrome), or if the main choledochal duct is obstructed by stones, bile backs up into the liver; this is also called cholestasis.

**Gallbladder carcinoma:** A primary adenocarcinoma of the gallbladder can develop in the wall of the gallbladder and its immediate vicinity can be infiltrated by this tumor (Fig. 9.57). Risk factors for the development of gallbladder carcinoma are cholelithiasis and chronic cholecystitis. One late symptom may be obstructive jaundice. Cholestasis, however, can also have other causes (Fig. 9.58a). One possibility is a small cholangiocarcinoma located at the bifurcation of the common hepatic duct (*Klatskin tumor*) that can cause severe cholestasis (Fig. 9.58b).

! Small tumors can obstruct and dilate the biliary system without themselves being detectable on CT.

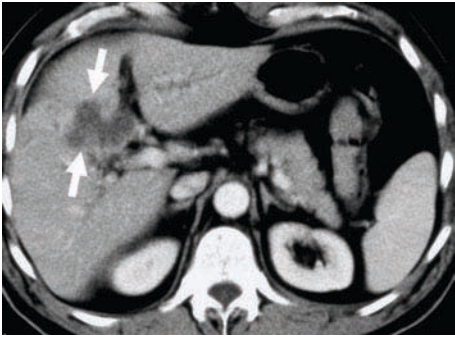
**Gallbladder Carcinoma**

Fig. 9.57 The tumor is located in the bed of the gallbladder (arrows); it infiltrates the adjacent structures and shows little enhancement after contrast administration.

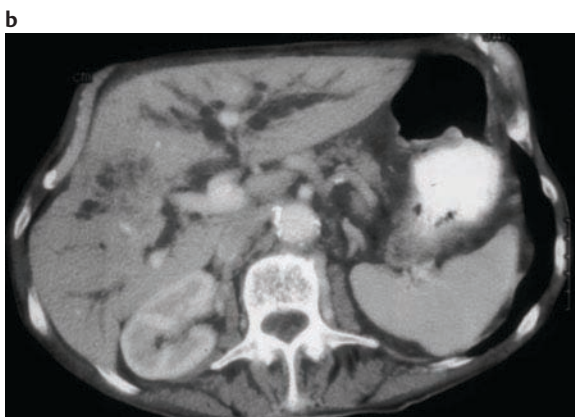
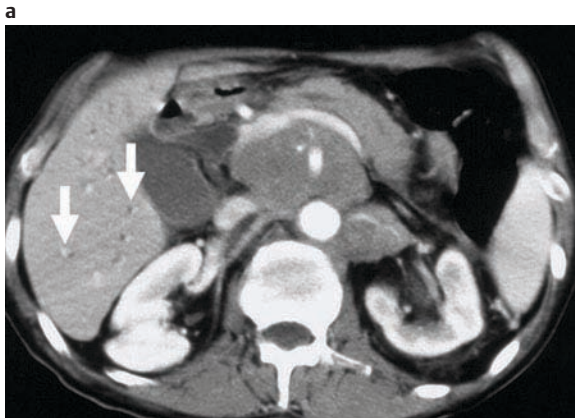**Biliary Obstruction**

Fig. 9.58 **a** If the dilated biliary ducts are detectable alongside the vessels (arrows) this is called the “shotgun sign.” Come back to this image after you have seen the next case to find the cause of the biliary obstruction—or are you smart enough already?

vessels.  
There is a carcinoma of the pancreatic head, which causes the biliary obstruction and has already infiltrated the mesenteric

**b** In another patient with a Klatskin tumor, the biliary obstruction is even more pronounced. The tumor itself remained beneath the detection threshold of CT.

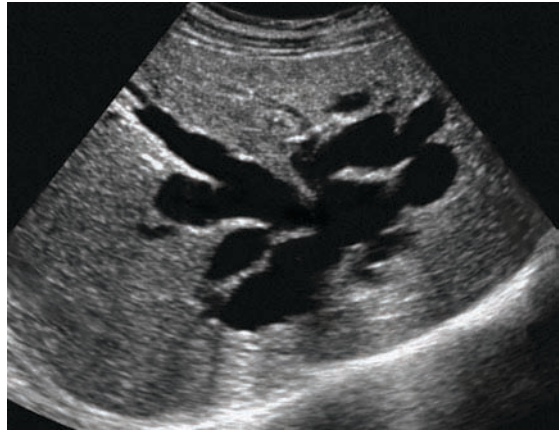**Caroli Syndrome**

Fig. 9.59 The extensive dilatation of the bile ducts is well seen. Stones may also be demonstrated with ease.

**Caroli syndrome:** Caroli syndrome is an extreme and rare form of congenital cavernous ectasia of bile duct dilatations of the biliary system. It is diagnosed very well by ultrasound because the dilatation of the biliary ducts is easily seen (Fig. 9.59; see also Fig. 9.44a).

→ **Diagnosis:** Joey checks the biliary system and finds it normal in caliber. But the gallbladder bed has a strange appearance. Is this an advanced cholecystitis? And then there is a round lesion close to it in the liver parenchyma! The contour of that lesion is so ill-defined that a cyst seems very unlikely. He adds up all the findings: a carcinoma of the gallbladder with regional metastases in the liver would explain all of it. Giufeng drops by for lunch and agrees—a nice conclusive diagnosis. A week later Mr. Cramp comes back for his staging CT of the chest—a biopsy has confirmed the gallbladder carcinoma.

**9.9 Diseases of the Pancreas****Checklist: Diseases of the Pancreas**

- Is there a history of alcohol abuse or diabetes?
- Does the patient complain about epigastric pain that radiates to the sides and back like a belt?
- Is there steatorrhea?
- Are the caliber and contour of the pancreas normal?
- Are calcifications present?
- Are the pancreatic ducts dilated or irregular?
- Is there a definite tissue plane between the pancreas and surrounding structures?



### The Case of Timothy Booze

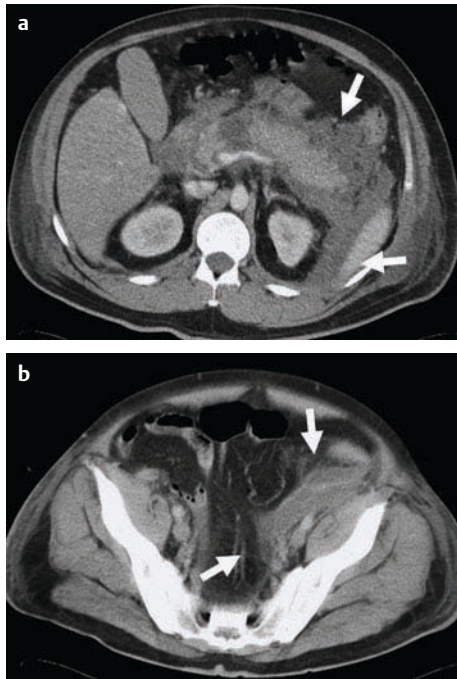


Fig. 9.60 These are the relevant sections of a CT through Mr. Booze's upper abdomen (a) and the pelvis (b). Can you think of a diagnosis already?

### Disarray of Juices

Timothy Booze (37) is not exactly an uptown boy and life has not been too kind to him. He tends to drown his regular frustrations in alcohol. His fingernails have turned yellow from chain-smoking filterless cigarettes. Yesterday evening he developed constant pain in his upper abdomen. This morning he barely made it to the walk-in clinic of the local city hospital. He simply couldn't take the pain any longer. The physician of the day examines him and then orders a CT to see what's going on in his belly. Hannah is working in the CT unit today and studies the examination. Two of the axial images particularly attract her attention (Fig. 9.60).

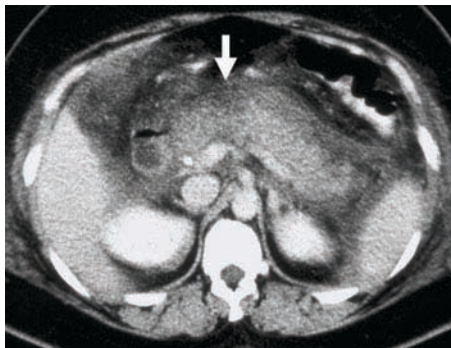
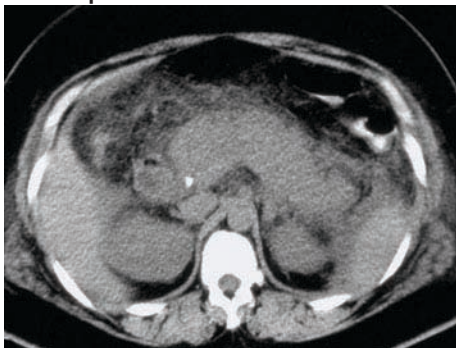
### → What is Your Diagnosis?

#### Pancreatitis:

*Acute pancreatitis:* Acute inflammation of the pancreas is caused by alcohol abuse or blockage of the pancreatic ducts (most commonly by gallstones) in 90% of cases (Fig. 9.61a). The extent of the inflammation is best evaluated by CT, but the diagnosis itself is based on the clinical appearance and the laboratory findings—in particular serum amylase and lipase.

### Pancreatitis

#### a Acute pancreatitis



#### b Chronic pancreatitis

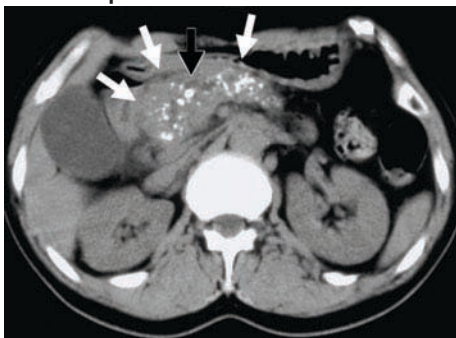


Fig. 9.61 a The noncontrast CT scan displaying the corpus and tail of the pancreas demonstrates coexisting swelling and ill-defined margins of the gland (left). Fluid collections extend into the splenic bed. After contrast administration, a perfusion defect in the body of the pancreas is appreciated (right; arrow). This indicates partial organ necrosis. b Chronic pancreatitis is characterized by coarse popcorn-like calcifications along the course of the pancreas (white arrows). The pancreatic duct is slightly dilated (black arrow).



### Pancreatic Adenoma

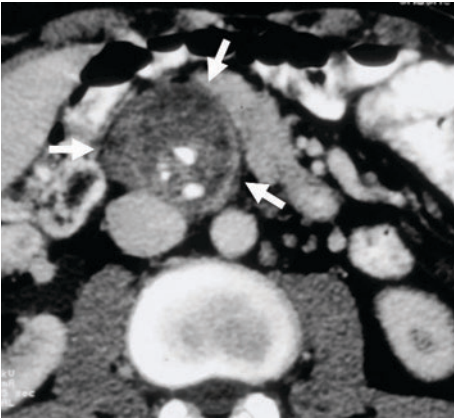


Fig. 9.62 You see here a typical microcystic pancreatic adenoma. The tumor is located anterior to the vena cava and aorta (arrows) and shows characteristic calcifications and small cysts. Histological work-up and verification are necessary in any case.

! Not every pancreatitis results in changes of the CT appearance of the gland. Thus pancreatitis cannot be excluded by CT.

Pancreatitis may cause swelling of the gland that may be associated with ill-defined borders. Stranding of the surrounding fat planes develops. The lipolytic and proteolytic pancreatic secretions find their way through the retroperitoneal spaces into and around Gerota's fascia to the kidneys and along the iliopsoas muscle down into the groin. Another commonly affected structure is the mesocolon. Fluid collections, so-called "pseudocysts," can form in and around the pancreas (see also Fig. 7.11, p. 108).

! The prognosis of the disease correlates with the extent of pancreatic necrosis

**Chronic pancreatitis:** Chronic pancreatitis is the consequence of recurring bouts of inflammation (Fig. 9.61b), frequently in persistent alcohol abuse. Calcifications begin to line the course of the pancreas, the pancreatic ducts (the little side branches in particular) are irregularly dilated, which is easily diagnosed on MRCP.

### Pancreatic tumors:

**Pancreatic adenoma:** A benign adenoma of the pancreas is difficult to differentiate from a pancreatic carcinoma on the basis of imaging alone (Fig. 9.62). It should be verified histologically unless there is a very specific history such as Von Hippel-Lindau disease, which is associated with

### Pancreatic Carcinoma

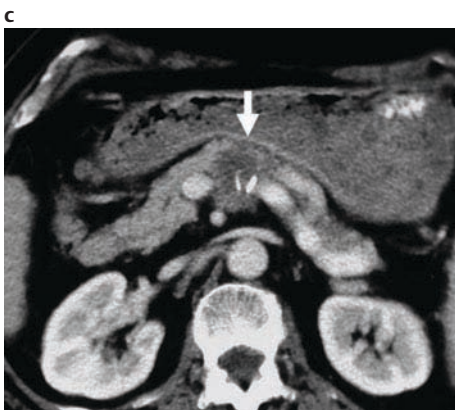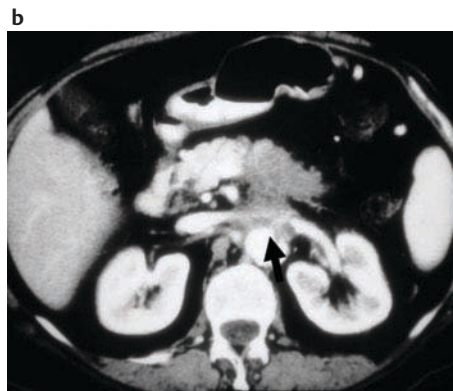
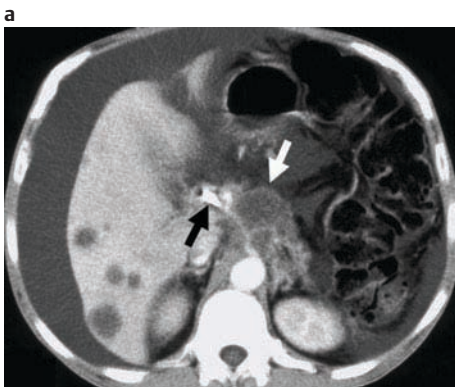


Fig. 9.63 **a** This CT section shows an extensive unresectable pancreatic carcinoma. The tumor (white arrow) completely surrounds the celiac trunk. It has caused a biliary obstruction, which has been treated/drained with a biliary stent (black arrow, see the stent tip in the duodenum). Liver metastases and extensive ascites are already present. The reason for the ascites is most likely a peritoneal carcinomatosis. **b** In this patient the cancer infiltrates the duodenum and the para-aortic space (arrow). **c** This tumor alters the organ contour just a little. Only after contrast administration does it become well visible as a low-attenuation lesion surrounded by normally enhancing pancreas (arrow).

multiple pancreatic adenomas. Biopsy is best obtained minimally invasively by ultrasound- or CT-guided percutaneous core needle biopsy or by ultrasound-guided endoscopic biopsy from stomach or duodenal lumen.

**Pancreatic carcinoma:** Pancreatic carcinoma—when located in the head of the pancreas—becomes symptomatic with painless jaundice in half of cases (Fig. 9.63a, b). Apart from that the symptoms remain rather nonspecific. Any irregularity of the pancreatic contour is suspicious and should be analyzed with special care (Fig. 9.63c). The tumor tends to be hypovascularized in comparison to the surrounding parenchyma. Therefore, multiphase contrast-enhanced CT or MRI are the best tests to detect its presence. If the celiac vessels, the portal vein and the mesenteric vessels are encased, the tumor becomes unresectable for the surgeon. Therefore the radiologist should carefully examine the relationship of the tumor to the vessels close by and comment on it. Liver metastases are also not infrequent. The detection of a carcinoma within a chronically inflamed organ poses a particular challenge because the pancreatic parenchyma can be scarred from the inflammation and mimic a tumor.

**!** In the imaging of pancreatic carcinoma, determination of surgical resectability is the primary issue apart from the diagnosis itself.

**Islet cell neoplasm:** An islet cell tumor, such as an insulinoma or gastrinoma to name the most frequent ones, is normally diagnosed on the basis of the clinical symptoms, which are caused by the hormone production, and with laboratory tests. Imaging is mainly used to localize the tumor preoperatively (Fig. 9.64).

→ **Diagnosis:** Hannah has never had any doubt that this must be a case of acute pancreatitis—the clinical history was so obvious. The inflammation is severe in Mr. Booze's case, the fluid collections can be followed all the way into the groin, and a large necrotic defect is present in the body

of the pancreas. Probably pseudocysts will develop in the days to come. Mr. Booze has a few tough weeks ahead of him.

## 9.10 Diseases of the Peritoneum and Retroperitoneum

### Checklist: Diseases of the Peritoneum and Retroperitoneum

- Is the abnormality cystic or solid?
- Is the abnormality focal (tumorlike) or diffusely infiltrating?

### Somewhere In Between

Mary Soames (64) has lost 6 kg within a few weeks. She has not really felt well for more than two months. Joey is the first to have a look at the abdominal CT that was done to find the reason for her weight loss. He notices a lesion in the posterior abdomen that he cannot assign to a specific organ (Fig. 9.65). To get to the heart of this he starts with the basics.

### → What is Your Diagnosis?

**Ascites:** Ascites may develop in a number of diseases, *liver cirrhosis* being the most frequent (see Fig. 9.49b). Diffuse metastases in the abdomen that sit directly on the peritoneal surfaces also cause ascites (Fig. 9.66a). If the peritoneal carcinomatosis is severe, solid tumor nodules and diffuse thickening of the omentum (“omental caking”) may be observed (Fig. 9.66b, c). A paralytic ileus may also ensue (Fig. 9.66d).

### Islet Cell Tumor

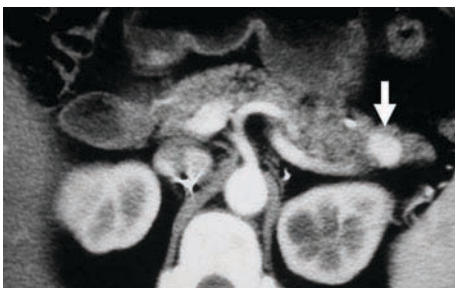


Fig. 9.64 This insulinoma (arrow) enhances markedly in the arterial phase of contrast administration. Small tumors can escape detection completely. A nuclear medicine study with radiolabeled octreotide is a very sensitive test to detect even small islet cell tumors. Modern hybrid scanners combine images of the metabolic activity of the tumor with the superb anatomical detail one is acquainted with from CT images.

### The Case of Mary Soames

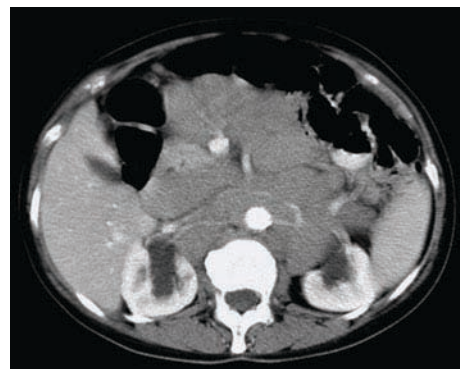
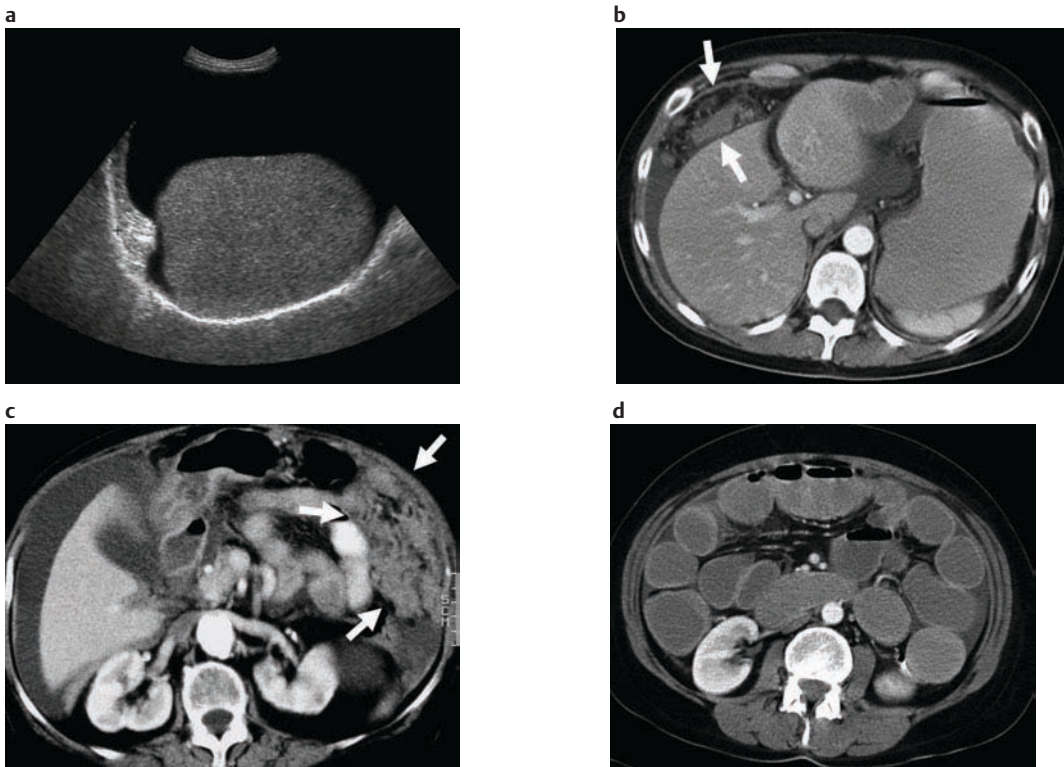


Fig. 9.65 Analyze the relevant CT sections of Mrs. Soames. What grabs your attention immediately?

### Peritoneal Carcinosis



**Fig. 9.66 a** The ultrasound cross-section shows the liver surrounded by ascites. There is a tumor at the underside of the diaphragm. It is a peritoneal metastasis of a pancreatic carcinoma. **b** The CT of another patient shows some tumor nodules in the omentum (arrows) ventral to the liver. **c** The extensive

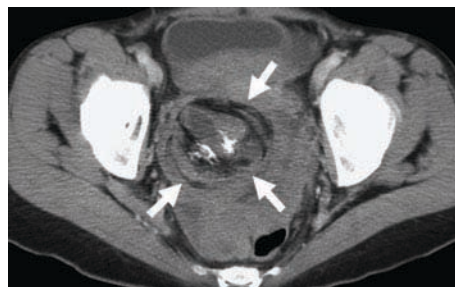
infiltration of the major omentum ("omental caking," arrows) is appreciated on this scan of another patient. **d** In the final stages of extensive peritoneal carcinomatosis a paralytic ileus may develop, which manifests itself in a dilatation of intestinal loops.

**!** In case of ascites the cause must be found.

**Teratoma:** A teratoma is an infrequent incidental finding in the abdomen (Fig. 9.67). A fatty component and remnants of dental or osseous buds hint strongly at the diagnosis.

**Retroperitoneal lymph node enlargement:** This is most commonly associated with lymphoma. The nodular structure is typical and they can be discriminated from blood vessels by careful evaluation of successive images and also by contrast administration (Fig. 9.68). Some cancers such as testicular cancer can be associated with enlarged lymph nodes in the retroperitoneum next to the large vessels.

### Teratoma



**Fig. 9.67** The fat planes and the calcifications that probably correspond to dental remnants are well appreciated in this case.



### Retroperitoneal Lymphoma

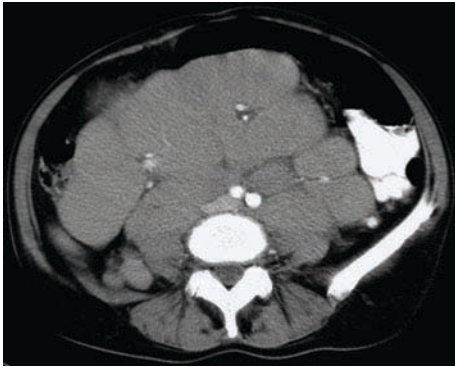


Fig. 9.68 The whole abdomen of this patient is filled with enlarged lymph nodes; the mesenteric vessels are filled and displaced.

**Retroperitoneal fibrosis:** This entity is also called Ormond disease (Fig. 9.69). It can be induced by medication. Frequently, however, the cause remains obscure. Retroperitoneal metastatic disease may look similar; a core needle biopsy may therefore be necessary to verify the histology.

→ **Diagnosis:** Joey has recognized the nodular character of the retroperitoneal mass at once. He considers this to be a lymphoma until proven otherwise. Joey calls up the ward and makes an appointment for a CT-guided biopsy. He hopes, of course, that Dr. Chaban will let him have a go at it. The oncologists are quite happy to get the diagnosis so rapidly and agree to the test.

! Every retroperitoneal tumor needs histological verification.

### Retroperitoneal Fibrosis

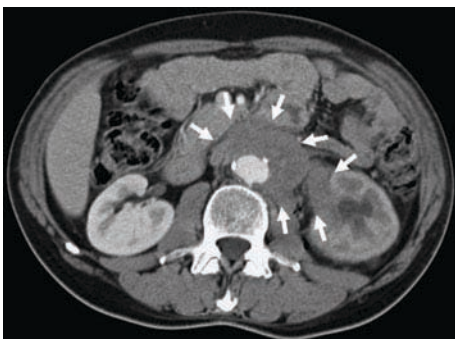


Fig. 9.69 The fibrotic tissue in the retroperitoneal space (arrows) surrounds the aorta, infiltrates the mesentery, and also involves the renal hilum.

## 9.11 Gregory's Test

Friday afternoon around 3 p.m., the onrush and excitement in the gastrointestinal clinic has died down. McDougal, the technician from Fluoroscopy, has obtained a few of the good old hotdogs from the food shack downstairs in the lobby. "Watch those breadcrumbs, lads. I don't want them to mess up the developer!" he tells our students, who are leaning against the x-ray developer unit chewing away quietly. Suddenly the peace is disturbed and backs are straightened. A fair shock of hair appears at the opposite end of the hallway. "It's Blondy the shark," groans Paul. "Quick! Hide the hotdogs!" Giufeng throws him a red-hot angry glance. Gregory strolls over to them and cheerfully hurls a load of x-ray folders on the table in front of the viewbox. "Hi, friends of the opera. Boy, does this smell good. You don't happen to have a spare sausage for this poor fella, have you?" "We're really sorry, Gregory, but there are none left," apologizes Paul with a cold smile. "You can have a bite of mine," Giufeng says into the intense silence. Paul turns pale and Hannah and Ajay fall into a big grin. Greg clears his throat and—very cautiously—bites off a little piece of Giufeng's sausage. "Well, ahem, thanks a lot, Giufeng. Where was I now? Oh yes, well, I have a few cases for you, to get you ready for the weekend as it were. Hey, Paul, how about starting with this one?" "Paul is indisposed," declares Hannah; she pushes Paul back into the second row and positions herself in front of the viewbox. "Show us the beef, Greg!" Go ahead and try on your own (Fig. 9.70)! The last case (Fig. 9.70n) is for true intellectuals. You'll find the solutions to the test cases on p. 342.

### Test Cases

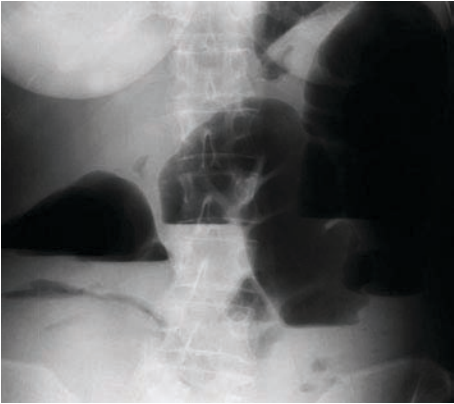
a This patient has swallowing problems.

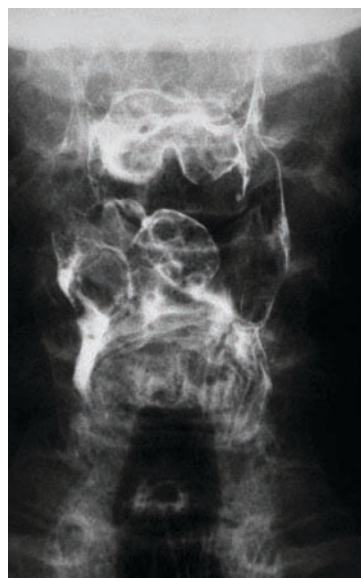

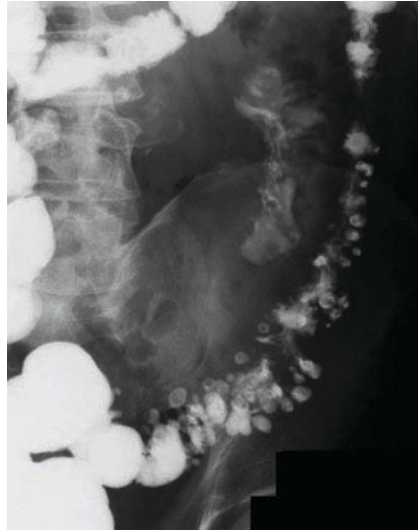Fig. 9.70

## Test Cases

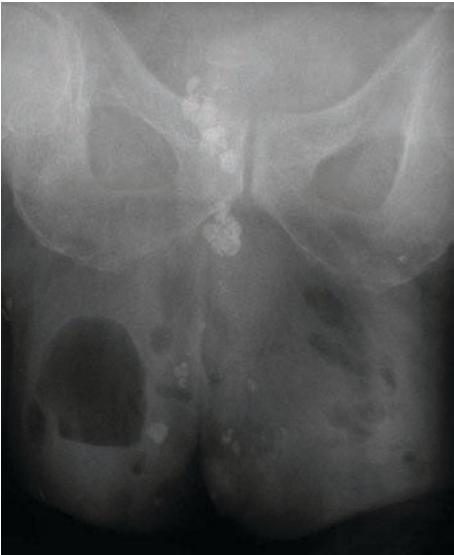b Abdominal pain is the major symptom here.



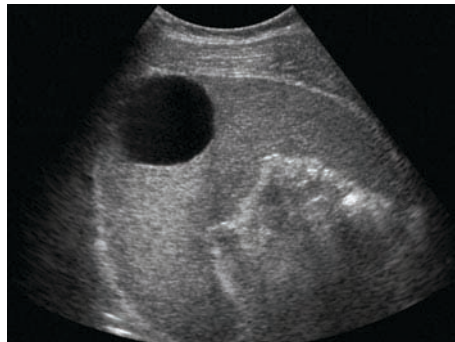
c This patient had a routine check.



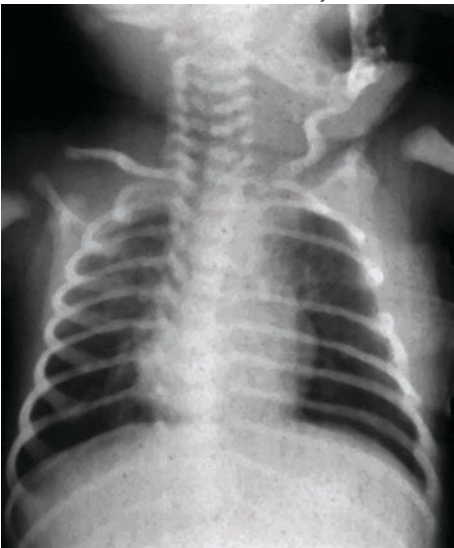
d An incidental finding in an obese patient.



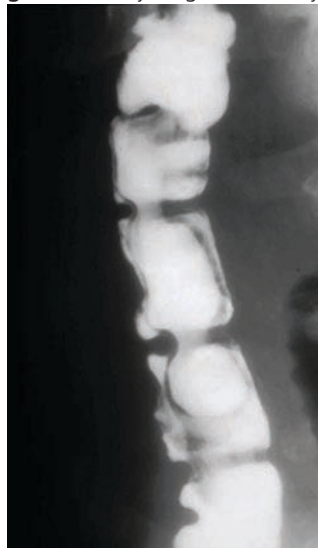
e An incidental finding in another patient.



f This neonate behaved abnormally.

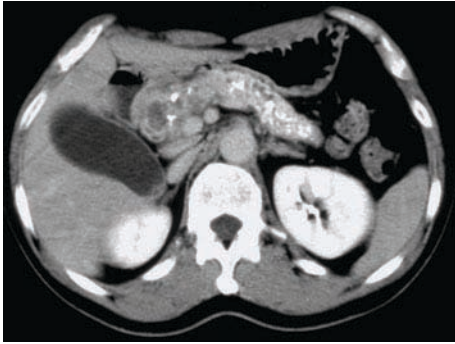


g Loss of body weight was the symptom here.

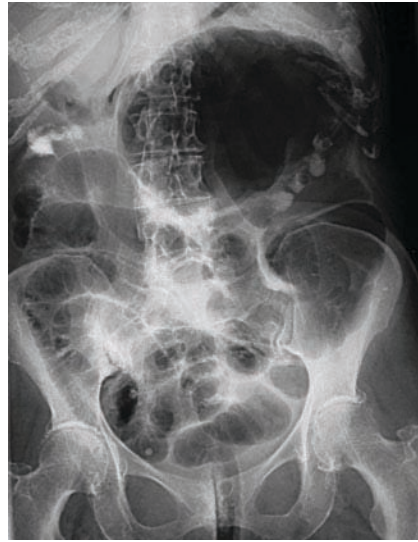


### Test Cases

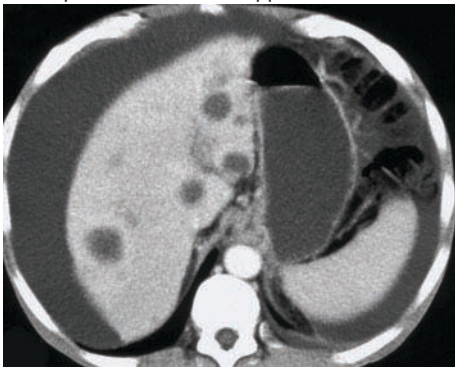
**h** This patient is well known.



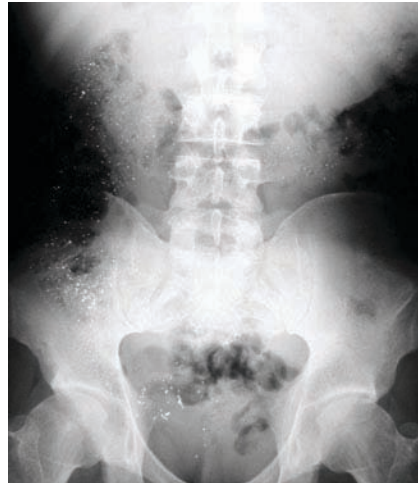**j** Severe abdominal pains developed acutely in this case.



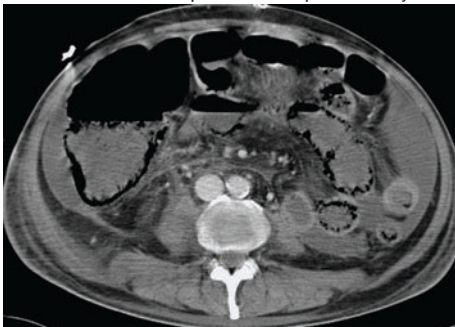**i** This patient has lost his appetite.



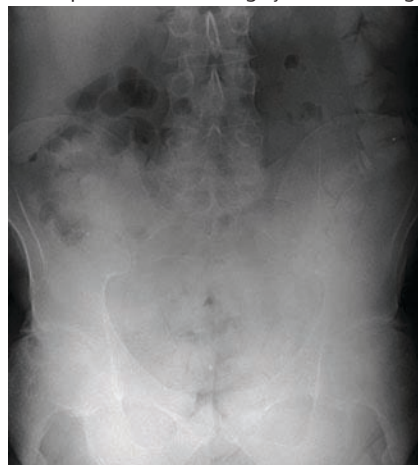
**k** The patient was referred from a mental hospital.



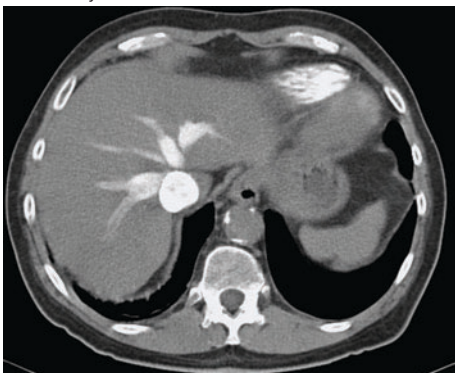
**l** Severe abdominal pains developed acutely in this case.



**n** The patient acted strangely when coming to Sydney.



**m** History withheld.





# 10 Genitourinary Tract



Currently ultrasound (US) and computed tomography (CT) are the most important imaging techniques in uro-radiology. Renal US is a very important and frequently performed investigation, hence you should be familiar with the fundamentals of this modality.

Renal and adrenal tumors are mainly diagnosed by US, CT, and magnetic resonance imaging (MRI). Renal calculi can be demonstrated on US, renal and ureteric calculi on CT (Table 10.1). The intravenous urogram (IVU) or pyelogram (IVP), once the mainstay of imaging of the genito-

urinary (GU) tract has lost much of its importance. Obtaining an additional frontal scout image at the end of a contrast-enhanced CT examination provides a good overview of the ureters in analogy to the KUB (kidney–ureter–bladder) radiograph formerly obtained during an IVP.

Diseases of the lower urinary tract are mostly diagnosed by endoscopy. Specific investigations of the lower urinary tract and genitals are performed by radiologists, urologists, and gynecologists.

Table 10.1 Suggestions for radiographic work-up of genitourinary conditions<sup>1</sup>

Clinical problem	Investigation	Comment
<b>Disorders of the kidneys</b>		
Hematuria, macroscopic and microscopic	US	To determine calcifications and tumors of kidneys, bladder, and prostate.
	CT	Noncontrast CT demonstrates calculi down to the bladder level. Contrast CT reveals tumors of the kidneys, ureters, and bladder.
	IVU	Demonstrates collecting system tumors, especially in ureters; less suitable for assessment of renal parenchymal abnormalities.
Hypertension: in the young adult or in patients unresponsive to medication	US	To determine renal size and assess renal parenchyma. Doppler US not sensitive enough for diagnosis.
	Angiography (DSA/CTA/MRA)	To show stenosis if surgery or angioplasty is considered as a possible treatment; CTA and MRA allow noninvasive visualization of renal vasculature; may exclude significant stenosis or vascular disease such as fibromuscular dysplasia.
Renal failure	US and AXR	US first investigation to measure kidney size and parenchymal thickness and detect pelvicaliceal dilatation indicating possible obstruction. AXR or stone protocol CT to detect calculi not detectable by US.
	CT/MRI	If US is nondiagnostic or does not show the cause of obstruction. MRI is the alternative, especially if nephrotoxic contrast medium must be avoided.
Suspected ureteric colic	CT/IVU	Stone protocol (unenanced) CT is the method of choice for demonstration of renal and ureteric calculi. IVU is the alternative if CT is unavailable.
	US/AXR	Used in combination where radiation or contrast medium is contraindicated.

<sup>1</sup>Modified after: RCR Working Party. *Making the best use of a Department of Clinical Radiology. Guidelines For Doctors*, 5th ed. London: The Royal College of Radiologists, 2003.

AXR, abdominal radiography; BUN, blood urea nitrogen; CT, computed tomography; CTA, CT angiography; DSA, digital subtraction angiography; IVU; intravenous urography; MRA, magnetic resonance angiography; MRI, magnetic resonance imaging; PSA, prostate specific antigen; US, ultrasound.

Table 10.1 Suggestions for radiographic work-up of genitourinary conditions (Continued)

Clinical problem	Investigation	Comment
Renal calculi in absence of acute colic	CT/AXR	CT best baseline assessment in renal stone disease. AXR is adequate for the majority of calculi.
	US	Can detect urate calculi but is less sensitive than CT. Good hydration is essential.
Renal mass	US	Sensitive at detecting masses >2 cm; differentiation between cystic and solid mass.
	CT	Sensitive at detecting renal masses of 1.0–1.5 cm or greater and accurately characterizes masses; staging.
	MRI	If iodinated contrast medium is contraindicated.
Urinary tract obstruction	US	To assess the upper tract (after catheterization and relief of bladder distention), particularly if BUN/creatinine levels remain raised.
<b>Disorders of the adrenal glands</b>		
Suspected adrenal mass	CT/MRI	To demonstrate and characterize an adrenal mass.
<b>Disorders of the prostate</b>		
Benign prostatic hyperplasia	US	Renal and bladder US (with measurement of post-void residual volume and urine flow rate).
Rising PSA, suspected prostate cancer	Transrectal US	US-guided biopsies after clinical examination.
<b>Disorders of the testicles</b>		
Scrotal mass or pain	US	For scrotal swelling and when presumed inflammatory scrotal pain does not respond to treatment. Allows differentiation of testicular from extratesticular suspected scrotal mass.
Suspected testicular torsion	Doppler US	Only if clinical findings are equivocal

AXR, abdominal radiography; BUN, blood urea nitrogen; CT, computed tomography; CTA, CT angiography; DSA, digital subtraction angiography; IVU, intravenous urography; MRA, magnetic resonance angiography; MRI, magnetic resonance imaging; PSA, prostate specific antigen; US, ultrasound.

## 10.1 How Do You Assess a Renal Ultrasound?

The renal US should always be performed in combination with a complete upper abdominal ultrasound. Why? Because on the next ward round nobody will remember that the “normal” ultrasound was a limited investigation of the kidneys and bladder only.

Renal US is usually performed in supine position. The side to be examined can be slightly elevated. After visualizing the kidney from a posterior and lateral angle, the long axis of the transducer is aligned with the long axis of the kidney. The resulting longitudinal cross sections are best suited to determining renal size and assessing cortical thickness as well as the configuration and size of the renal pelvis (Fig. 10.1a). The transducer is then rotated by 90° to scan up and down the kidney perpendicular to its long

axis. As with all paired organs, comparison with the opposite side is essential for the evaluation of the images. Finally, cast an eye on the (hopefully) fluid-filled bladder.



### Have You Memorized the Renal Size?

The normal adult kidney measures approximately 13 cm in length and 4–6 cm in width. The thickness of the renal cortex can be 12 mm. The renal pelvis measures about 4 cm in length.

### I See an Abnormality—What Do I Do Now?

If you see a **renal mass** on US, its echogenicity provides important diagnostic clues.

- A simple renal cyst is anechoic (black).
- A stone is quite echogenic (white) and shows a posterior acoustic shadow (black).

- If you see a solid parenchymal structure in the interpolar (middle) kidney, this often represents a column of Bertin, a normal variant (Fig.10.1b).
- Any other mass requires further investigation by CT scan.

**!** Check for mobility of the kidney on the psoas muscle during respiration. If it is restricted or reversed, a renal tumor may have extended through the renal capsule.

If there seems to be **urinary obstruction indicated by dilatation of the renal pelvis and calices**, try to find the level of the obstruction. The thickness of the renal parenchyma indicates the duration of the obstruction, a thin parenchyma giving the clue that it may have been present for a long time.

If there is **marked atrophy** of the kidney or **focal attenuation of the renal parenchyma** (a scar), investigation of the renal arteries is required.

**Swelling of the renal parenchyma** can be secondary to inflammation, diffuse infiltration with tumor cells, or vascular congestion, e.g., in lymphoma or renal vein thrombosis.

### Normal Renal Ultrasound (US) Scan

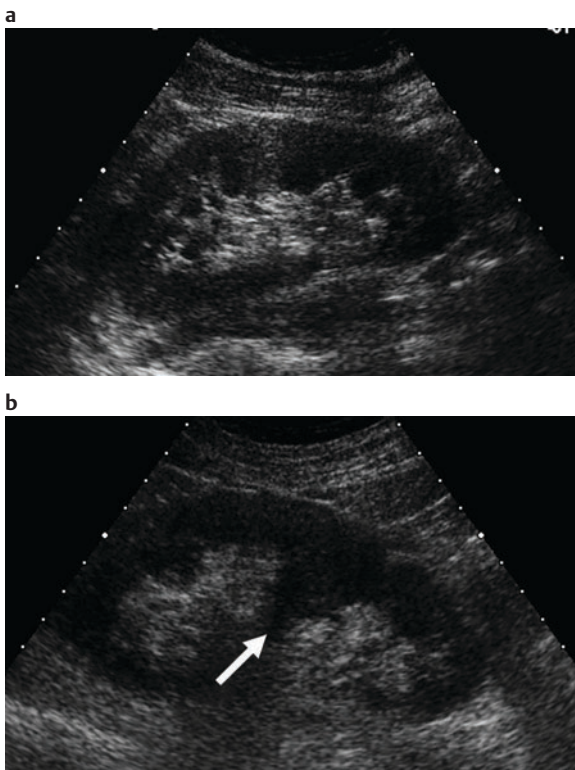


Fig. 10.1 **a** The US shows a longitudinal image of the kidney. This is the best way to assess size, parenchymal thickness, and configuration of the renal pelvis. **b** If there is segmentation of the renal pelvis into an upper and lower part, the parenchyma in between can appear very prominent (column of Bertin; arrow). This is a normal variant without pathological significance.

Now that you know the basic rules of ultrasound, we will approach our first patient.

## 10.2 Renal Masses

### Checklist: Renal Masses

- Is the lesion cystic, solid, and/or fatty?
- Is the lesion solitary and/or unilateral?
- Is renal mobility on the psoas muscle restricted?
- Is there normal blood flow in the renal vein?
- Does the mass enhance following contrast injection in CT?
- Is there para-aortic lymph node enlargement?

### The Villain in the Kidney

Johnny Drip (54) has been generally unwell and so his local doctor is going through a comprehensive check-up with him. An abnormal finding on US made our colleague refer Mr. Drip for further investigation. Paul has a quick look at the renal US before establishing intravenous access (Fig. 10.2a). He later carefully examines the three-phase contrast-enhanced CT scan of the kidneys (Fig. 10.2b).



### Three-phase CT Scan of the Kidney

This renal investigation consists of an unenhanced scan, a scan during the arterial phase of contrast enhancement, and a scan during the parenchymal phase. Calcification is best seen without contrast. Hypervascular tumors, such as a renal cell carcinoma, are best demonstrated in the arterial phase; cysts are best seen in the parenchymal phase.

### → What is Your Diagnosis?

**Renal cyst:** This common benign entity is found in approximately 30% of all elderly patients. It often occurs bilaterally and can be associated with hepatic cysts (Fig. 10.3). Simple renal cysts have a thin, smooth margin, have no internal echo on US, and are of water density on CT (less than 20 Hounsfield Units). They are predominantly found in the renal cortex, but can also protrude into the renal hilum, in which case they have to be distinguished from a dilated renal pelvis. Parapelvic renal cysts located in the renal sinus fat can also create the impression of hydronephrosis but are easily discernible from the actual renal pelvis on the excretory phase of a contrast-enhanced CT scan.

**!** Any cystic structure that does not fulfill these criteria requires at least a follow-up or—depending on the findings and symptoms—immediate further work-up.



### The Case of Johnny Drip

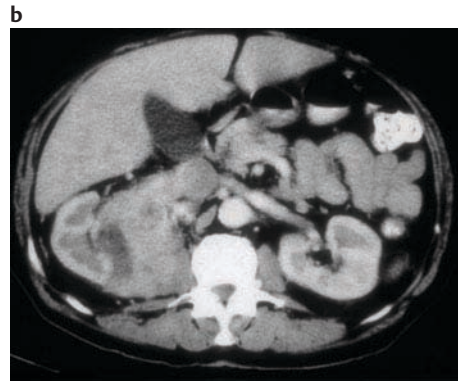
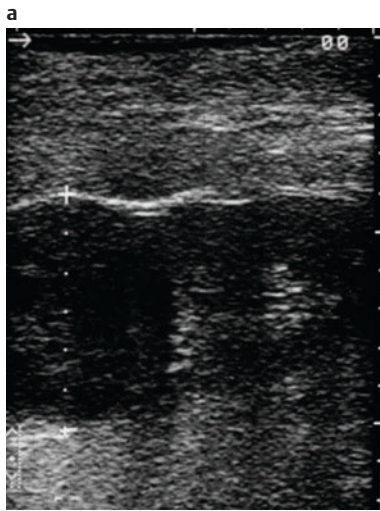


Fig. 10.2 Johnny Drip's US (a) and CT (b). What do you notice?

**Polycystic kidneys:** Polycystic kidney disease eventually leads to renal failure in adults, requiring hemodialysis or renal transplantation. Patients also frequently present with arterial hypertension. The cysts cause bulging of the renal outline and show different densities on CT, probably secondary to previous hemorrhage (Fig.10.4). In 30% of cases cysts are also found in the liver.

**Horseshoe kidney:** The horseshoe kidney, characterized by a partial fusion of the kidneys at the upper or lower pole, is a developmental anomaly associated with an increased risk for development of transitional cell carcinoma, Wilms tumor, and the rare renal carcinoid (Fig.10.5). The "bridging" or so-called "isthmic" tissue can be mistaken for adenopathy or a mass on US.

**Renal abscess:** Development of renal abscesses is possible in pyelonephritis (Fig. 10.6). Clinical signs and symptoms will point to the inflammatory nature of the lesion.

**Angiomyolipoma:** An angiomyolipoma is a hamartoma of the kidney (Fig 10.7). In 10% of cases it is associated with tuberous sclerosis. The angiomyolipoma is a benign lesion that contains varying amounts of blood vessels and fat. It often becomes symptomatic after hemorrhage into the tumor or perinephric space; occasionally hemorrhage can be quite extensive, requiring embolization or surgery.

**Renal lymphoma:** Lymphoma can also be found in the kidney and present as a well-circumscribed mass that takes up contrast less avidly than the renal parenchyma (Fig. 10.8). With successful treatment it will regress with residual scarring.

### Renal Cyst

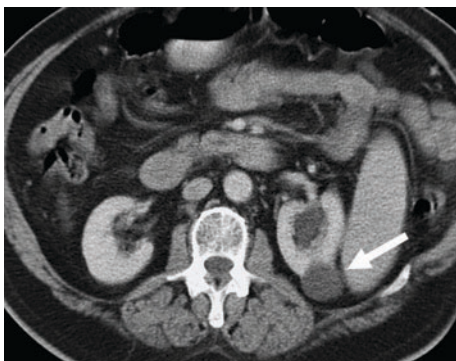


Fig. 10.3 This simple renal cyst has sharp margins (arrow), is of low density equivalent to water, and does not enhance after contrast administration. This patient also has a dilated renal pelvis. Differentiation from a parapelvic cyst is only possible with certainty after contrast accumulation in the renal pelvis.

### Polycystic Kidneys

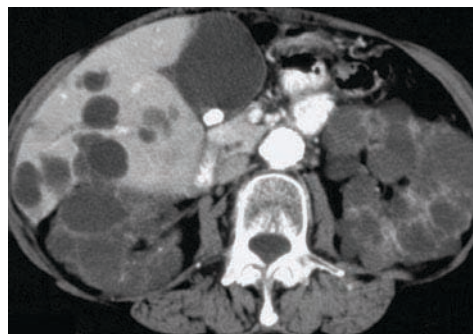

Fig. 10.4 In polycystic kidney disease, multiple cysts gradually replace the renal parenchyma. These cysts can contain calcification and can become hyperdense on CT after hemorrhage or display an internal hematocrit level. Additionally, several hepatic cysts, which are commonly associated with renal cysts, are noted in this patient.

### Horseshoe Kidney

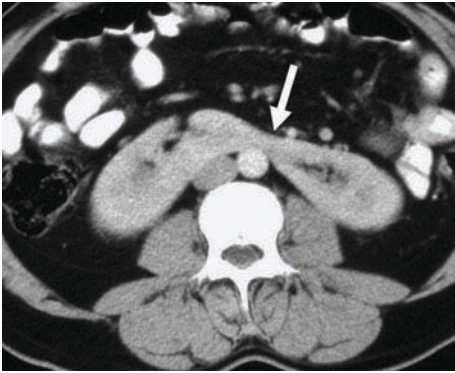


Fig. 10.5 In a horseshoe kidney a tissue bridge (“isthmus,” arrow) is seen anterior to the aorta. There is inferior and medial displacement of both kidneys. The isthmus often has its own arterial blood supply arising from the distal aorta or common iliac arteries.

### Renal Abscess

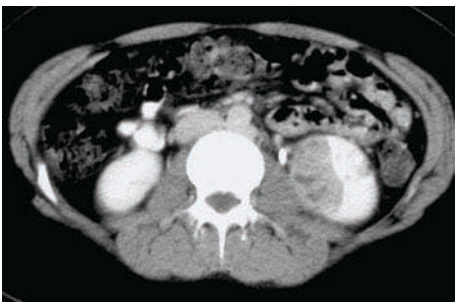


Fig. 10.6 A hypodense subcapsular mass with a fluid center is demonstrated in the left kidney during the parenchymal (nephrographic) phase, i.e., the phase of most intense contrast enhancement by the renal parenchyma.

### Angiomyolipoma of the Kidney

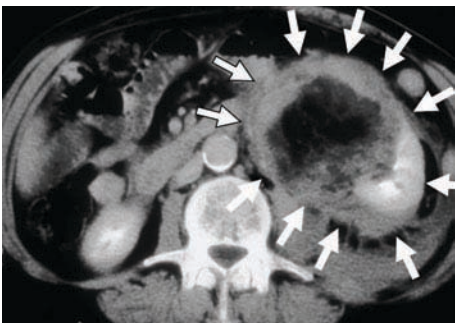

Fig. 10.7 This patient presented with severe acute flank pain. A left perirenal hematoma (arrows) is demonstrated on CT. Foci of fat density, characteristic of angiomyolipoma, are clearly visible within the hematoma. This kidney had to be surgically removed; sometimes acute bleeding from an angiomyolipoma can be stopped by the interventional radiologist embolizing the main feeding vessel to the tumor.

**Renal cell carcinoma:** Eighty percent of all solid renal tumors are renal cell carcinomas (Fig. 10.9a). They are predominantly found in the elderly. Any solid lesion in the kidney represents a malignant neoplasm until proven otherwise, unless there are definite benign features such as internal fat (Fig. 10.9b). Suspicion of renal cell carcinoma always warrants surgery, as tissue biopsy is contraindicated.

Renal cell carcinoma is often very vascular and can contain areas of calcification and necrosis; occasionally it can be predominantly cystic. There is a tendency for vascular invasion by the tumor, growing into renal veins, and sometimes also extending into the inferior vena cava, even up to the right atrium.

Lymph node metastases are first found in the para-aortic lymph nodes at level of the renal vein/caval junction. Metastases also tend to be very vascular. In cases of planned surgical removal of metastases, prior radiologically guided embolization may be a useful adjunct.

**Perirenal hematoma:** Perirenal hematoma can be post-traumatic, especially in patients with abnormal blood clotting, but it can also happen spontaneously or after minor trauma (Fig. 10.10).

### Renal Lymphoma

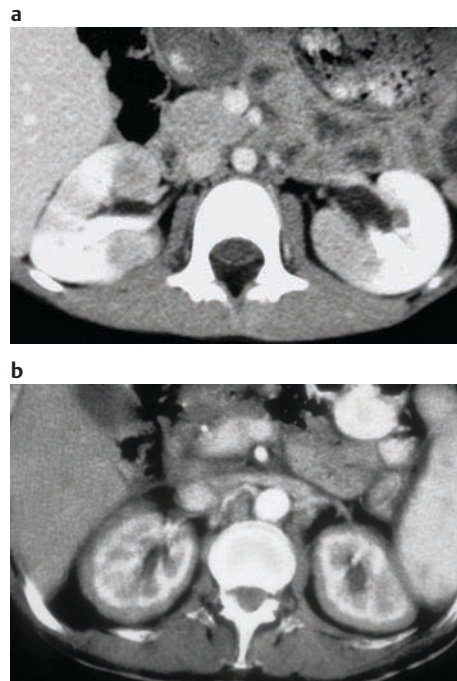
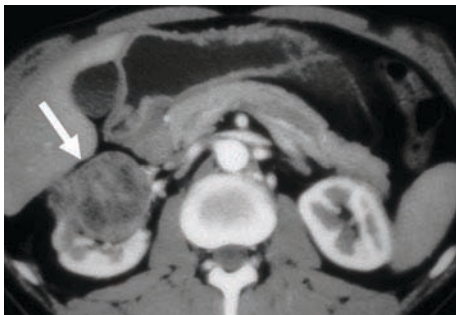


Fig. 10.8 **a** In this patient with histologically proven lymphoma, both kidneys are affected. There seems to be bilateral focal swelling of the parenchyma and decreased parenchymal contrast enhancement. Under therapy there was complete remission of this lymphoma. **b** In this patient with lymphoma, abnormal perirenal tissue is seen bilaterally. Both kidneys are affected in this case, too.



### Renal Cell Carcinoma and Renal Adenoma

#### a Renal cell carcinoma



#### b Renal adenoma

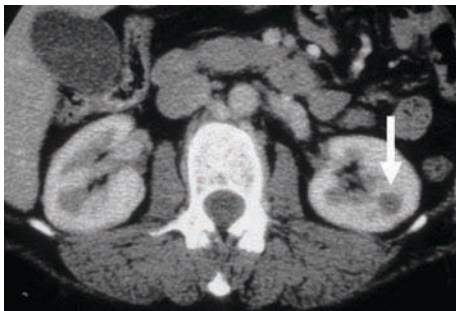


Fig. 10.9 **a** There is a large mass (arrow) demonstrated in the right kidney, which seems to be hypodense compared to the contrast-enhanced renal parenchyma. This tumor, formerly known as a hypernephroma, is highly vascularized. The next step is to ascertain that the renal vein is not invaded by viable tumor thrombus and to check the lymph node status in the renal hilum as well as para-aortic and pericaval nodes. Another important anatomical landmark is the perirenal (Gerota's) fascia, which can be invaded or broken through by more locally advanced tumors. **b** This lesion proved to be a renal adenoma (arrow). Renal adenomas are difficult to differentiate radiologically from renal carcinomas and are for that reason treated like carcinomas until proven otherwise.

### Perirenal Hematoma

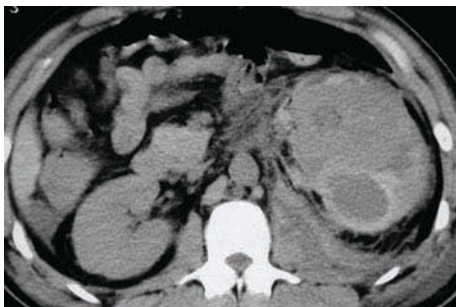


Fig. 10.10 On the unenhanced CT scan there is a very heterogeneous left perirenal mass that displaces the kidney anteriorly. The dense parts of the mass represent recently coagulated blood. The cause of hemorrhage in this patient was extracorporeal shock wave lithotripsy (ESWL) administered in an attempt to fragment renal calculi.

### Urinoma

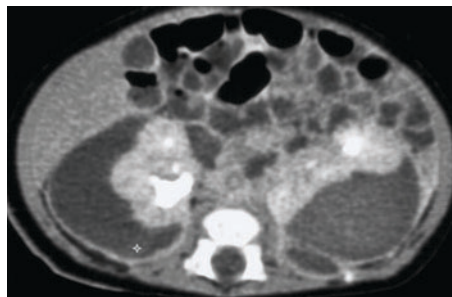


Fig. 10.11 In this child (vertebral epiphyses are not calcified yet) urinary diversion of both kidneys was attempted via external percutaneous catheters (nephrostomy). This caused bilateral leakage from the renal pelvis, resulting in a perirenal fluid (urine) collection. Each renal pelvis shows calcification.

### Tumors of the Renal Pelvis

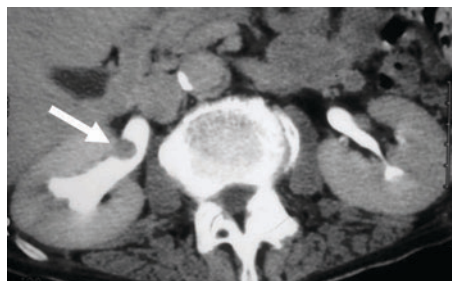


Fig. 10.12 A tumor of the renal pelvis is easily overlooked in the early contrast phase. Only when the collecting system is completely filled with contrast is the tumor of the renal pelvis (arrow) easily detected. Remember to use wide window/level settings when assessing the contrast-filled renal pelvis on CT, otherwise you may miss a small mural lesion in the ocean of white contrast.

**Urinoma:** Urinoma can develop after trauma to the renal pelvis or the ureter (Fig. 10.11). The distinctive feature of a urinoma is a mostly perirenal fluid collection with density equivalent to water. When a stone obstructs the ureter, a calyx can spontaneously rupture, decompressing the renal pelvis into the perinephric space, forming a urinoma.

**Tumor of the renal pelvis:** Transitional cell carcinoma of the renal pelvis is much less common than renal cell carcinoma. It arises from the urothelium; even small lesions can become symptomatic because of hematuria. On CT it is best demonstrated in the late contrast phase on wide window settings, when it is seen as a filling defect in the otherwise contrast-filled renal pelvis (Fig. 10.12).

! The main role for imaging in renal pelvis tumors is staging of the disease.



## Wilms Tumor

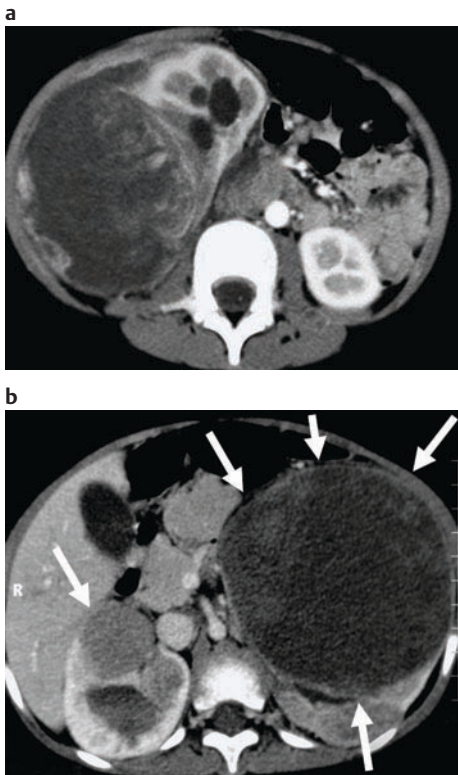


Fig. 10.13 **a** The right kidney is deformed by the tumor and shifted anteriorly. The renal perfusion is reduced (compare the density of the left kidney). The renal pelvis is markedly dilated secondarily to ureteric obstruction. **b** In a different patient both kidneys are affected by Wilms tumors (arrows).

→ **Diagnosis:** Because of the abnormal US result, Paul was mainly thinking about a renal cell carcinoma. CT confirmed the diagnosis and showed the extent of the tumor with invasion into the inferior vena cava. This is a typical feature in advanced renal cell carcinoma. If Mr. Drip were 50 years younger, Paul would also have had to consider Wilms tumor in addition to some inflammatory diseases (Fig. 10.13). Wilms tumor often occurs bilaterally and at diagnosis is often large enough to be palpated on abdominal examination. Hemorrhage and central necrosis are common. Fortunately, it is quite responsive to treatment.

! CT of the kidneys consists of an unenhanced scan as well as an arterial (corticomedullary) and parenchymal (nephrographic) contrast phase. If a tumor of the collecting system is suspected, a CT scan during the excretory phase is also indicated.

## 10.3 Renal Volume Loss/Renal Atrophy

### Checklist: Renal Volume Loss

- Is there focal or generalized loss of renal tissue?
- Is it unilateral or bilateral?
- Is there any preexisting renal failure?
- Is there known arteriosclerosis?
- Is there any past or present renal disease?

### A Close Shave

Jaqueline Tebbits (75) only recently moved from the south of the country to the city to be near her children. She regularly attends the oncology clinic for follow-up after excision of a breast cancer two years ago. When looking at the films of the abdominal CT that was requested, Paul noticed an abnormality of the right kidney (Fig. 10.14).

### → What is Your Diagnosis?

**Renal infarction:** Renal infarction predominantly occurs in patients with preexisting arteriosclerotic changes of the renal arteries. Most of the time it is clinically insignificant and is an incidental finding on CT (Fig. 10.15a). Infarction causes tissue loss and results in scarring. The appearance of a scar is nonspecific, however, and does not necessarily indicate the underlying disease process.

**Atrophic kidney:** Atrophic kidneys show generalized loss of volume (Fig. 10.15b) with marked cortical thinning, the patient develops renal failure over time. Causes include glomerulonephritis, arteriosclerosis of the renal arteries, or chronic obstruction.

→ **Diagnosis:** Paul can see only focal scarring of the renal parenchyma. His correct diagnosis is an old renal infarct, probably secondary to an embolus on the background of arteriosclerosis. Renal function may be adequate. The liver

### The Interesting Case of Jaqueline Tebbits

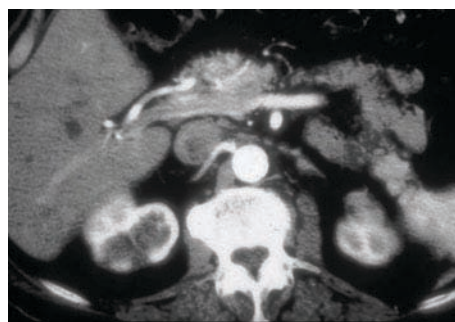
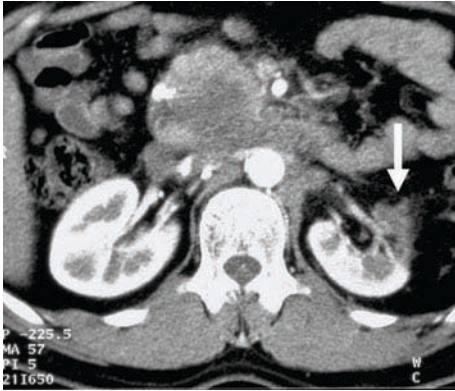


Fig. 10.14 This is the essential image of Mrs. Tebbits' CT. What do you notice?

**Renal Diseases with Loss of Volume**

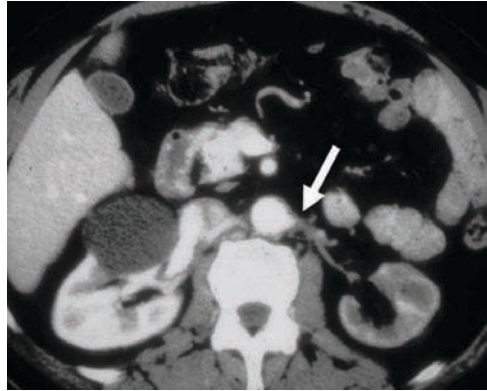
**a Renal infarction**



**Fig. 10.15 a** The anterior part of the parenchyma (arrow) of the left kidney is atrophic and barely accumulates contrast. There has been an infarct in the past. Compare with the normal features of the right kidney. Do you notice anything else?

There is a large tumor, a lymphoma, anterior to the aorta.

**b Atrophic kidney**



**b** The left kidney is significantly smaller than the right and also takes up less contrast. This is what an atrophic kidney looks like. The origin of the left renal artery (arrow) is clearly visible and shows marked plaque formation. This suggests that renal atrophy is secondary to renal artery stenosis in this case. Additionally we see a renal cyst on the right.

looks OK, too, and so Mrs. Tebbits can join her friends at the café, much to her relief.

**!** If there is bilateral renal atrophy, the patient is either on dialysis or has a transplanted kidney. You might want to take a peek at the left or right iliac fossa.

**10.4 Increase in Renal Volume**

**Checklist: Increase in Renal Volume**

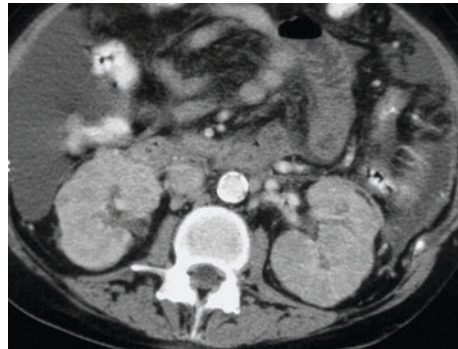
- Is the increase in renal volume unilateral or bilateral?
- Are both kidneys visualized?
- Is there any urinary obstruction?

**Why Are They So Big?**

It is almost impossible to obtain a history from Lydia Peacock (34) because of her mental impairment secondary to meningitis at a young age. Her young caretaker has only known her for three days. The referral note does not provide any more useful information: follow-up CT has been requested. Paul makes numerous attempts to contact the referring doctor, but he is away making house calls.

Paul finally gives up and postpones taking the history. He thinks the marked ascites is due to the liver metastases seen on previous CT images. But what is wrong with the kidneys (Fig. 10.16)?

**The Case of Lydia Peacock**



**Fig. 10.16** Demonstrated is a representative image of Ms. Peacock's CT. Can you help Paul?

**→ What is Your Diagnosis?**

**Compensatory renal hypertrophy:** Compensatory hypertrophy occurs when there is only one kidney or when the other kidney is significantly impaired in its function. The cortical-medullary ratio of the affected kidney does not change.

**Pyelonephritis:** Pyelonephritis causes swelling of the kidney (Fig. 10.17). It is only an incidental finding for the radiologist, as imaging is not really required for the diagnosis. On CT there may be delayed contrast enhancement of the affected portion of the renal parenchyma on earlier images and retention of contrast on delayed images.

## Pyelonephritis

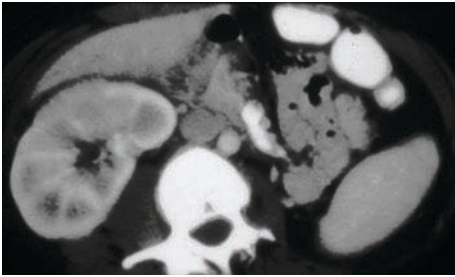


Fig. 10.17 The entire right kidney is enlarged and there is no differentiation between cortex and medulla. These findings point to advanced generalized pyelonephritis.

**Lymphoma:** This disease can present as hypoattenuating abnormal soft tissue in the perinephric space or in the renal parenchyma. It can also affect the entire kidney diffusely and cause an increase in size (see Fig. 10.8b).

**Renal vein thrombosis:** Renal vein thrombosis can cause venous congestion with associated swelling of the kidney.

**Hydronephrosis:** An increase in renal size is also seen in hydronephrosis secondary to urinary obstruction associated with enlargement of the renal pelvis (see Fig. 10.13a).

→ **Diagnosis:** Paul is still not sure how to explain the bilateral renal enlargement. It is not until late in the afternoon that he gets some essential clinical information from Ms. Peacock's general practitioner. She has been on antibiotics for pyelonephritis over the last two days. The unfortunate findings of liver metastases and ascites are explained by her advanced breast cancer.

## 10.5 Renal Calculi

### Path of the Stone

Olivia Stone (45) has been referred by her general practitioner for investigation of recurrent left-sided renal colic. The colicky pain radiates into the left groin. The GP already suspected renal calculi, but they have not been treated successfully. Initially an intravenous urogram was requested, but after discussion with a friendly older colleague it was decided to perform a CT scan for diagnosis of calculi. Paul stares spellbound at the unenhanced thin CT sections appearing one after the other on the monitor. He knows that most renal calculi can be demonstrated on ultrasound scan (Fig. 10.18a). But on CT they are—as in the case of Mrs. Stone—even more likely to be detected in the

## Renal Calculi

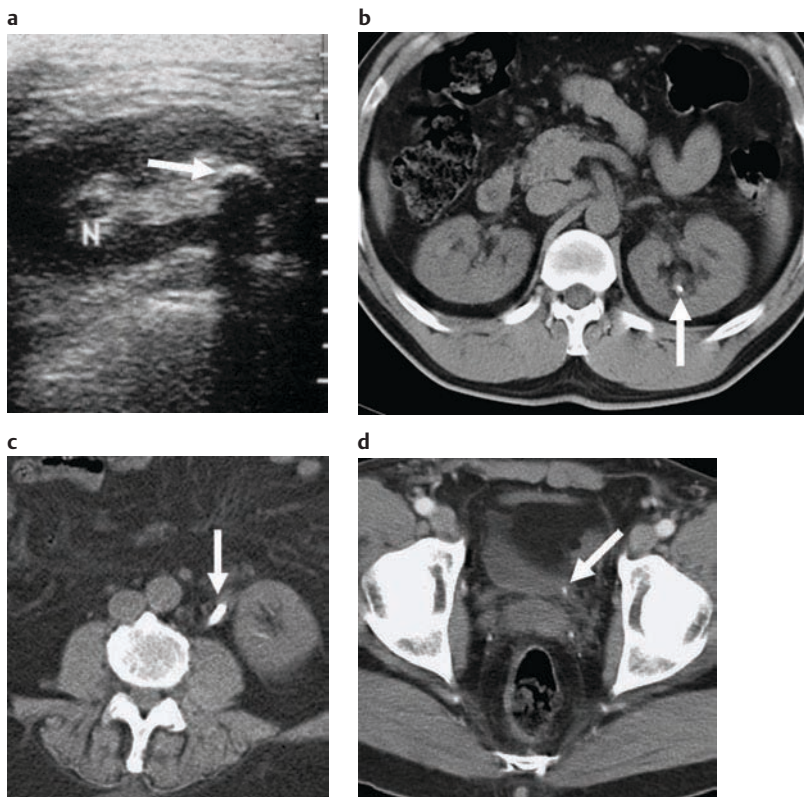


Fig. 10.18 On US (a) renal calculi are strongly echogenic structures (arrow) with posterior shadowing. On CT they are very dense and are demonstrated in the renal pelvis (b, arrow) as well as in the ureter (c, arrow) and down to the ureterovesicular junction (d, arrow). The structures with high density anteriorly are vessels enhanced by contrast.



kidneys (Fig. 10.18b) and the ureters (Fig. 10.18c, d) (97% should be visible). Only stones formed by HIV patients under indinavir treatment are not visible on CT. Complications such as hydronephrosis or caliceal rupture can also be documented. In addition, CT is very good at finding other diseases that can mimic renal colic such as diverticulitis, appendicitis, or appendagitis. Paul is quite satisfied with his findings: several calculi are present that have not passed yet. One of them is stuck at the left ureterovesicular junction. The patient will be referred to urology service for further management.

## 10.6 Adrenal Tumors

### What a Coincidence!

Gill Bates (45) is being worked up by his general practitioner for persistent decreased appetite and a slightly elevated erythrocyte sedimentation rate. Today he is booked for an abdominal CT. He is a little nervous, but Paul reassures him, while giving him a big cup of dilute oral contrast that will fill the lumen of the stomach and the small and large intestine. An intravenous cannula is inserted before the investigation. Contrast is injected after an initial unenhanced CT scan to better evaluate blood vessels and parenchymal organs of the abdomen. Paul looks through the CT images and discovers an abnormal-appearing adrenal gland (Fig. 10.19).

! The adrenal glands have a “Y” or “V” configuration with a thickness of 5–8 mm. As a rule of thumb, the width should not exceed that of the adjacent crus of the diaphragm.

### → What is Your Diagnosis?

**Adrenal adenoma:** An adrenal adenoma is a frequent incidental finding in the absence of symptoms, which is why

### The Case of Gill Bates

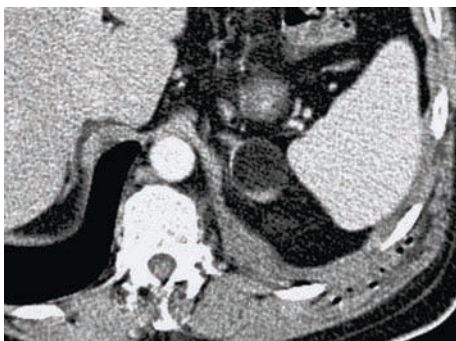
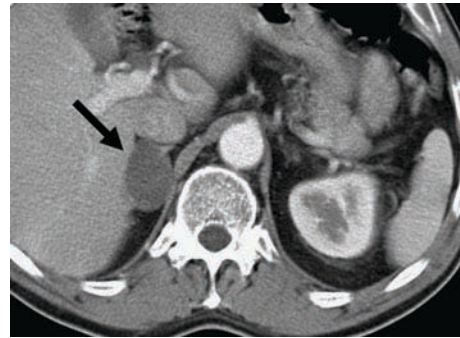


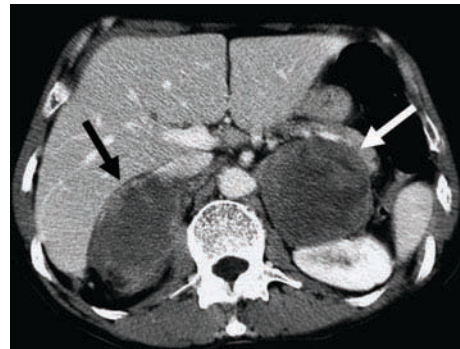Fig. 10.19 This is the relevant CT image of Gill Bates. What is your diagnosis?

## Adrenal Tumors

### a Adenoma



### b Metastasis



### c Myelolipoma

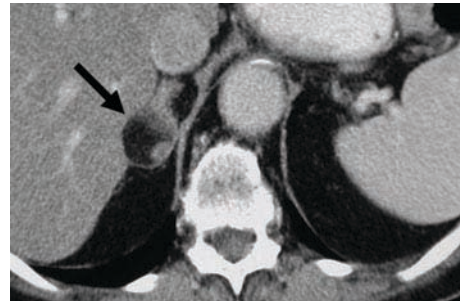


Fig. 10.20 **a** The arrow points to a homogeneous well-circumscribed adrenal mass of about 2 cm in diameter and of low density. This is a textbook case of an adenoma. **b** In this patient with bronchogenic carcinoma, both adrenal glands (arrows) are enormously enlarged and accumulate contrast in the periphery, a typical picture of adrenal metastasis. **c** This fat-containing capsulated mass (arrow) of the adrenal gland is well demarcated from the surrounding fatty tissue. This is the characteristic appearance of a myelolipoma.

it is also often called an “incidentaloma” (Fig. 10.20a). Any adrenal mass <3.5 cm maximum diameter with a density less than 10 Hounsfield Units on unenhanced CT and smooth in outline is most likely to be an adenoma. Follow-up CT should be performed as clinically indicated. If the mass is >3.5 cm in diameter, if it shows a tendency to grow, or if the patient is symptomatic because the tumor secretes adrenal hormone, surgical removal needs to be considered.

**Adrenal metastases:** Adrenal metastases are common in bronchogenic carcinoma, but certainly also occur with other primary malignancies (Fig. 10.20b). When performing a thoracic CT for staging of a bronchogenic carcinoma, the adrenal glands should always be included. Normally, heterogeneous enhancement, irregular outline, and rapid growth can suggest the diagnosis of adrenal metastases.

**Myelolipoma:** An adrenal myelolipoma is a benign mass with—as the name implies—a high fat content (Fig. 10.20c). It does not require follow-up.

**Other tumors:** All other adrenal lesions such as cysts or carcinomas are fairly rare. On CT, cysts have the same density as water and do not take up contrast; on US, they do not produce echoes but do give posterior acoustic enhancement. Endocrinologically active adrenal tumors (e.g., pheochromocytomas) are usually diagnosed clinically and biochemically. Imaging helps to localize the tumor and for surgical planning.

→ **Diagnosis:** Of course Paul spotted the fat in the tumor right away. This is confirmed by comparing densities of tumor and subcutaneous fat. This lesion is a myelolipoma. Good news for Mr. Bates, because it is of no clinical significance and needs no further work-up or therapy.

Further investigation of his low appetite is unsuccessful. Three months later Paul runs into him in the street and has a chat with him. After some candid conversations with his wife and a wonderful holiday together, Mr. Bates has started to enjoy his food again.

## 10.7 Where Is Greg?

Paul is happy to have seen such a wide range of urological findings over the last few days. He also got some reading done and feels quite confident. Giufeng has taken a day off for a research project and Ajay is organizing the birthday party of one of his kids. Hannah is snowed under with work at the orthopedic clinic. Joey has finally persuaded the angiographers to let him do an angio himself under strict supervision, and Greg is at a conference for the day. Paul gazes around and suppresses a yawn. Suddenly he pauses and straightens up: There is a thin x-ray bag hidden behind the viewing box. He pulls it out and reads the fine pencil writing: “Hands off! Greg’s uro-collection.” As he whips the first case up on the viewbox, his boredom melts away. Can you solve the cases faster than Paul and before Greg gets back? (Fig. 10.21a–g).

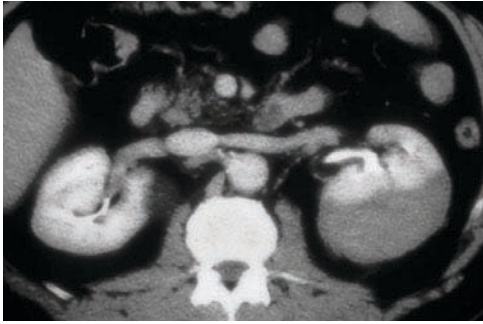
### Greg’s Secret Collection

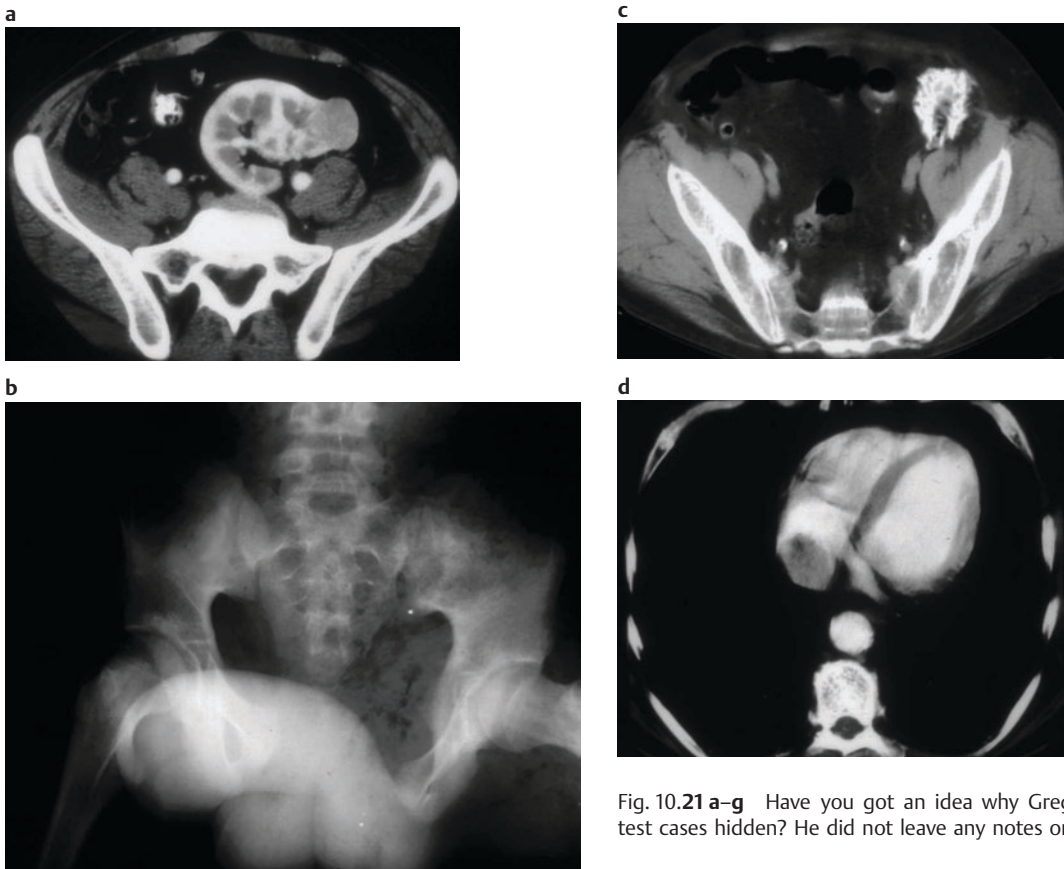

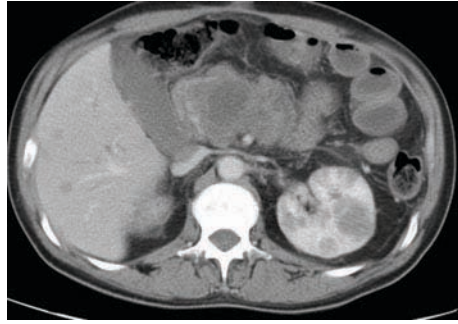
Fig. 10.21 a–g Have you got an idea why Greg keeps these test cases hidden? He did not leave any notes on the cases.

## Greg's Secret Collection

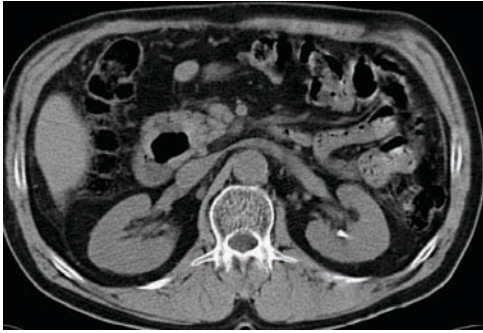
e



g

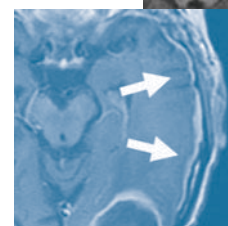

f





# 11 Central Nervous System



New imaging modalities have often been developed for and evaluated in the head region before their introduction to clinical body imaging. The reasons for this are straightforward: the head is relatively small (at least in most of us), and—on a larger scale—there is no significant biological motion that can give us so much trouble when imaging heart, lungs, and abdomen. Yet a lot can go wrong in the head ... and since without brains life just isn't the same, advances in head and brain imaging are of prime interest to all of us. Consequently, the first computed tomography (CT) and magnetic resonance imaging (MRI) scanners were used exclusively for brain imaging. MRI made its earliest and biggest advances in the diagnosis of central nervous system (CNS) diseases because the composition of the brain parenchyma could be depicted with

much greater clarity than ever before or with any other imaging modality. On these grounds, the relevance of head CT examinations tends to decrease in the elective setting for diagnosis of subtle CNS abnormalities. CT remains the modality of primary choice in acute CNS problems, in trauma, and—of course—if MRI is contraindicated or not available (Table 11.1). Since the advent of CT perfusion imaging and CT angiography of neck vessels and circle of Willis, both modalities offer strong diagnostic tools for the diagnosis of acute stroke and their use depends mainly on their availability and local physicians' preference. Some contrast media studies of the spinal canal (myelographies) are still performed.

Because very subtle lesions may have an enormous clinical impact in the CNS, mostly depending on their location,

Table 11.1 Suggestions for diagnostic modalities in CNS imaging<sup>1</sup>

Clinical problem	Investigation	Comment
Congenital disorders	MRI	The definitive examination for all malformations that avoids ionizing radiation. Sedation is usually required for young children.
	3D-CT	3D-CT may be needed for bone anomalies. Sedation is usually required for young children.
	US	Consider in neonates.
Acute stroke	CT/CTA/CT-PI	Readily available in most institutions. Immediate CT adequately assesses most cases and shows hemorrhage; useful in determining the cause, site, and appropriate primary treatment and secondary prevention. Contrast enhanced CTA/CT-PI may show perfusion defect immediately.
	MRI/MRA/DW imaging	Should be considered in young patients; more sensitive in early infarction and for posterior fossa lesions. May show previous hemorrhages. "Round-the-clock" availability is limited in most hospitals. Advanced techniques permit very detailed and sensitive work-up of acute stroke.
	US carotids	Should only be performed in (1) stroke patients after full recovery in whom carotid surgery is contemplated for secondary prevention; (2) evolving stroke where dissection or acute occlusive embolus is suspected; (3) young patients with stroke.
Transient ischemic attack (TIA)	CT/CTA of aortic arch, carotids, and circle of Willis	May be normal. Can detect established infarction and hemorrhage and exclude disease processes that can mimic stroke syndromes, such as glioma, extracerebral hemorrhage, and cerebritis. Contrast-enhanced advanced vascular imaging techniques (CTA) comprehensively assess extracranial and intracranial vasculature.

CT, computed tomography; 3D-CT, three-dimensional CT; CTA, CT angiography; CT-PI, CT perfusion imaging; DW, diffusion weighted; ENT, ear, nose, and throat; MRI, magnetic resonance imaging; NM, nuclear medicine; PET, positron emission tomography; rCBF, regional cerebral blood flow; SPECT, single-photon emission computed tomography; US, ultrasound; XR, radiography.

Table 11.1 Suggestions for diagnostic modalities in CNS imaging<sup>1</sup> (Continued)

Clinical problem	Investigation	Comment
	US carotids	To assess suitability for carotid endarterectomy or angioplasty. Angiography, MRA, and CTA are alternatives to show vessels.
Demyelinating and other diffuse white-matter disease	MRI	Most sensitive and specific investigation for establishing a diagnosis of multiple sclerosis; may be negative in up to 25% of those with established multiple sclerosis.
Space-occupying lesion	MRI	More sensitive for early tumors, in resolving exact location (treatment planning); superior modality in the assessment of posterior fossa and for vascular lesions. MRI may miss calcification.
	CT	Often sufficient in supratentorial lesions.
Headache: acute, severe; subarachnoid hemorrhage (SAH)	CT	Clinical history is critical. Classic migraine and cluster headaches are usually diagnosed without CT. SAH-related headache typically occurs within seconds, rarely in minutes, and hardly ever over more than 5 minutes. CT provides adequate assessment in most cases of SAH and other types of intracranial hemorrhage and associated hydrocephalus. <b>N.B.:</b> A negative CT does not exclude SAH and, when clinically suspected, lumbar puncture should follow if there are no contraindications (e.g., obstructive hydrocephalus). Lumbar puncture may also be needed to exclude meningitis.
	MRI	Better than CT for inflammatory causes. SPECT may be the most sensitive investigation for encephalitis and may provide evidence of circulatory derangement in migraine.
Headache: chronic	XR skull, sinus, cervical spine	Of little use in the absence of focal signs/symptoms.
	CT/MRI	In the absence of focal neurological symptoms, imaging is not usually indicated. The following features significantly increase the odds of finding a major abnormality on CT/MRI: <ul style="list-style-type: none"> <li>■ Recent onset and rapidly increasing frequency and severity of headache</li> <li>■ Headache on waking up patient from sleep</li> <li>■ Associated dizziness, lack of coordination, tingling, and numbness.</li> </ul>
Pituitary and juxtaseellar problems	MRI	Urgent referral when vision is deteriorating.
	CT	If MRI is not available or is contraindicated.
Posterior fossa signs	MRI	Much better than CT. CT images are often degraded by beam hardening artifacts.
Hydrocephalus; ?shunt function	CT	Adequate in most cases.
	MRI	Sometimes necessary and may be more appropriate in children.
	US	First choice for infants.
	XR	Can demonstrate the whole valve system and assess continuity and configuration of ventriculoperitoneal shunt line if there is evidence of hydrocephalus on sectional imaging.
Middle or inner ear symptoms (including vertigo)	CT	Clinical evaluation of these symptoms requires ENT, neurological, or neurosurgical expertise.

CT, computed tomography; 3D-CT, three-dimensional CT; CTA, CT angiography; CT-PI, CT perfusion imaging; DW, diffusion weighted; ENT, ear, nose, and throat; MRI, magnetic resonance imaging; NM, nuclear medicine; PET, positron emission tomography; rCBF, regional cerebral blood flow; SPECT, single-photon emission computed tomography; US, ultrasound; XR, radiography. ▶

Table 11.1 Suggestions for diagnostic modalities in CNS imaging<sup>1</sup> (Continued)

Clinical problem	Investigation	Comment
Sensorineural deafness	MRI	Much better than CT, especially for acoustic schwannomas. In children, both MRI and CT may be needed in congenital and postinfective deafness.
Dementia and memory disorders; first onset psychosis	CT	Yield is low, even in younger patients, unless there are neurological signs and rapid progression. Over the age of 65, CT can be reserved for patients with an onset within the last year or with an atypical presentation, rapid unexplained deterioration, unexplained focal neurological signs or symptoms, a recent head injury (preceding the onset of dementia), or urinary incontinence and/or gait ataxia early in illness.
	MRI, SPECT	No proven clinical value, although they may be used in research.
Epilepsy	MRI	Multiplanar capability affords greater sensitivity and specificity for the identification of cortical lesions. Particularly valuable in partial epilepsy, e.g., temporal lobe epilepsy, if surgery is being considered.
	CT	Following trauma; may complement MRI in the characterization of lesions, e.g., detection of small calcifications
	PET/NM;SPECT/rCBF	Ictal SPECT or interictal PET is useful in planning of epilepsy surgery when MRI is negative or results conflict with EEG or neurosurgical evidence. Regional cerebral blood flow (rCBF) agents are also of value.

<sup>1</sup>Modified after: RCR Working Party. *Making the best use of a Department of Clinical Radiology. Guidelines For Doctors*, 5th ed. London: The Royal College of Radiologists, 2003.

CT, computed tomography; 3D-CT, three-dimensional CT; CTA, CT angiography; CT-PI, CT perfusion imaging; DW, diffusion weighted; ENT, ear, nose, and throat; MRI, magnetic resonance imaging; NM, nuclear medicine; PET, positron emission tomography; rCBF, regional cerebral blood flow; SPECT, single-photon emission computed tomography; US, ultrasound; XR, radiography.

good anatomical/spatial resolution and superior contrast resolution are paramount. And you as the interpreting radiologist have to know the anatomy well!

**!** Imaging of the CNS is clinically extremely important and very sophisticated. The clinical neurological examination remains the first step for the clinician, however, and must not be neglected. Clinical signs and symptoms may in fact provide key information. Any imaging findings must be interpreted in their light; only the combination of clinical presentation and imaging allows for correct management decisions.

## 11.1 How Do You Analyze a Sectional Study of the Head?

### Key Points of Thorough Image Analysis

The basic steps of image evaluation are similar for CT and MRI of the brain. Let us run through the analysis of a head CT to familiarize you with a good standard approach. The first aspect to pay attention to is the **gross morphologic appearance of the brain** (Fig. 11.1a, b): How wide are the inner and outer cerebral fluid spaces? For example,

how well can you see the cerebellar gyri and sulci? Is the temporal horn of the lateral ventricle of normal caliber? Does the appearance of the brain correlate with the age of the patient or does it suggest prior disease, or abnormalities induced by toxins, lifestyle, or drugs?

The next point of interest is the **appearance of the actual brain parenchyma**: Is the gray–white matter differentiation normal? Are sulci and gyri of the same width bilaterally? Are the median structures really in the middle, do the lateral ventricles appear symmetric? Are there any focal parenchymal lesions?

We also evaluate the CSF **space surrounding the brain within the skull**, which is, of course, restricted to start with: Are the cisterns of normal caliber or obliterated, particularly infratentorially (Fig. 11.1c)?

Finally, we analyze the image after intravenous **contrast administration**: Is there evidence for abnormal contrast enhancement in any focal lesions or the meninges? Enhancement of the pituitary gland, the choroid plexus and the vessels is, of course, normal.

**!** The normal appearance of the brain, perhaps more than that of any other organ, changes profoundly from birth to death. Sound knowledge of the age-appropriate normal appearance is crucial to detect significant abnormalities without overcalling normal phenomena.



## Evaluate the Brain Status!

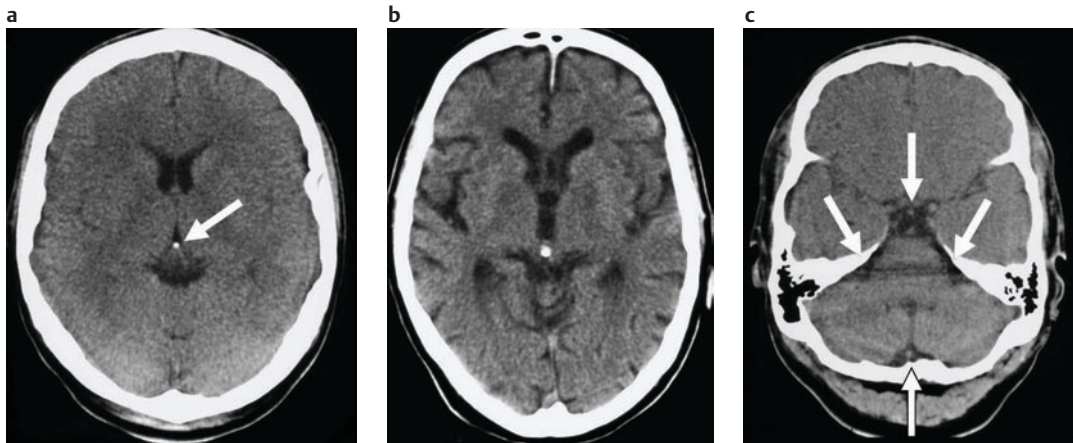


Fig. 11.1 **a** This typical head CT of a 25-year-old demonstrates narrow ventricles and well-defined sulci and fissures. Calcification in the pineal gland area (arrow) is normal and develops early in life. **b** The typical head CT of an 85-year-old, on the other hand, shows significantly wider ventricles and external CSF spaces. In a 25-year-old this pattern would, of course, be highly pathological. One would have to consider, for example, HIV-

encephalopathy, prior meningitis, and alcohol- or drug-induced toxic injury of the brain. Temporary volume loss of the brain during high-dose steroid therapy or forced dehydration could result in this appearance. **c** The size of the infratentorial cisterns (arrows) tells us something about the pressure in the posterior fossa. If they become obliterated, herniation of the brainstem becomes a possibility.

## I See an Abnormality—What Do I Do Now?

Did you notice a diffuse abnormality of the brain parenchyma or a circumscribed lesion? In **diffuse parenchymal disease** changes of brain volume (atrophy, edema) and changes of the meninges (meningitis, subarachnoid hemorrhage) are the most frequently encountered.

If a **focal lesion** has been detected several aspects have to be evaluated:

- Is the lesion located inside (arising from) the brain parenchyma (intra-axial) or outside of the brain (extra-axial)? In particular, extra-axial meningiomas and sellar tumors have to be differentiated from parenchymal lesions.
- Is the lesion solitary or multifocal? Primary brain tumors tend to be solitary lesions. Multiple lesions suggest metastatic disease, infectious etiology, or a vascular or embolic process. Imaging findings need to be correlated with the clinical findings to arrive at the correct diagnosis since many of these entities may look similar on your study.
- Is the lesion hypodense or hyperdense (CT), or hypointense, isointense, or hyperintense (MRI) relative to surrounding parenchyma? Meningiomas tend to be hyperdense on plain CT and isointense in noncontrast MRI.
- Is the lesion homogeneous or heterogeneous? Hemorrhage frequently appears very heterogeneous. Some primary brain tumors can calcify partially and develop necrosis and secondary hemorrhage, which also gives them a very heterogeneous appearance.
- Is the lesion surrounded by edema or is there no significant associated surrounding parenchymal reaction? Pronounced surrounding edema indicates rapid growth

and is often seen in metastases and high-grade gliomas, while the absence of edema generally indicates a more benign biological behavior.

- Does the lesion accumulate contrast medium and, if so, centrally or peripherally? Loss of the blood–brain barrier is always pathological. Ringlike enhancement, for instance, may be indicative of an abscess or a highly malignant glioblastoma.

## Are You Ready for Your First Case?

Paul and Giufeng have been assigned to neuroradiology for a week. They follow all the radiological rounds for the neurologists and neurosurgeons and—if the neurointerventionalist has his friendly day—some of those really sophisticated neuroradiological interventions. Gregory is quite pleased with Giufeng's lively interest in his favorite field, and Paul plows through his neuroanatomy book every evening to impress Giufeng and hold his own in the face of Greg's pestering attacks.

## 11.2 Perfusion Disturbances of the Brain

### Brain Hemorrhage

#### Checklist: Sudden Headache

- Does the patient suffer from chronic headache attacks or is this a new type of headache?
- Is there a history of medication with headache as potential side effect or could the patient be intoxicated?
- Did the headache occur under physical stress or exertion?
- Does the patient suffer from arterial hypertension?
- Is the headache accompanied by other neurological symptoms or loss of consciousness?

#### Out of the Blue

Will Klington (37) is brought to the emergency unit unconscious. It is late at night. His escorts report that Will started to complain about a sudden, severe headache completely “out of the blue,” then vomited and lost consciousness a few minutes later. The colleague on duty has immediately transferred the patient to CT, where Giufeng and Greg are working together this evening. The CT shows an impressive finding (Fig. 11.2). Gregory leaves Giufeng exactly one minute for her diagnosis and runs out of the room.

#### The Case of Will Klington

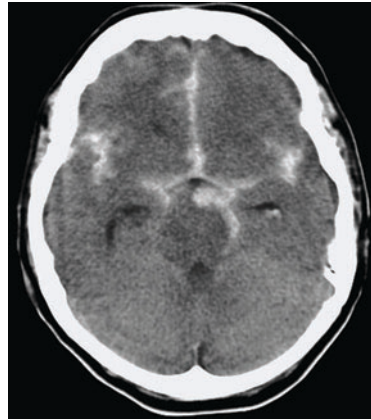


Fig. 11.2 Here you see the relevant CT image of Will Klington's head.

#### → What is Your Diagnosis?

**Migraine, cluster-headache:** Migraine and cluster headache are clinical diagnoses and are not associated with any positive findings on imaging modalities. CT and MRI usually do not show any abnormality.

**Subarachnoid hemorrhage (SAH):** This type of hemorrhage is most often caused by the rupture of a preexisting *aneurysm of the circle of Willis* but can also occur in trauma. It is diagnosed with great accuracy by simple noncontrast CT (Fig. 11.3a) and may be missed in standard MRI. SAH

#### Subarachnoid Hemorrhage (SAH) and Its Consequences

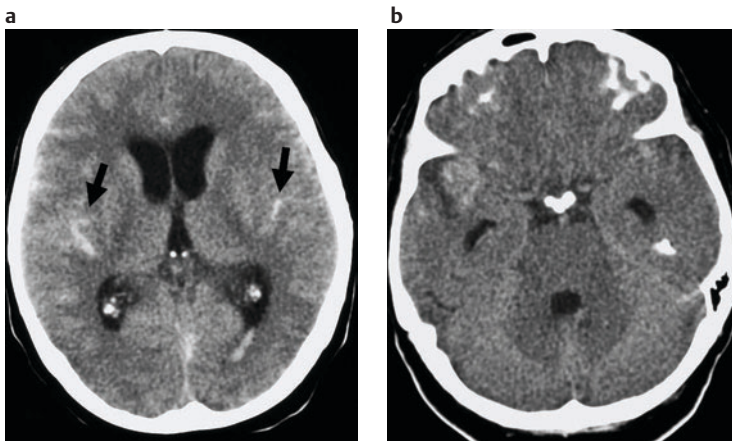


Fig. 11.3a The fine, dense lines in the sylvian fissure (arrows) correspond to blood in the subarachnoid space. A small amount of blood is also seen in the posterior horn of the left lateral ventricle: The acute hemorrhage must have worked its way through the cerebral parenchyma (visible on other sections) and broken through into the ventricle. The ventricles are already distended because blood clots almost always find their way into the narrow aqueduct and tend to obstruct it. A ventriculostomy needs to be

inserted. b After pronounced SAH, normal-pressure hydrocephalus may develop. In this patient, two weeks after an SAH the temporal horns are distended and the fourth ventricle also appears enlarged. Obstruction of the aqueduct alone would not explain this combination of findings. CSF resorption over the cerebral convexities, however, is severely compromised by the SAH sequel. Normal-pressure hydrocephalus is treated by spinal tap or insertion of a drain to relieve the pressure.

## Embolization of an Aneurysm

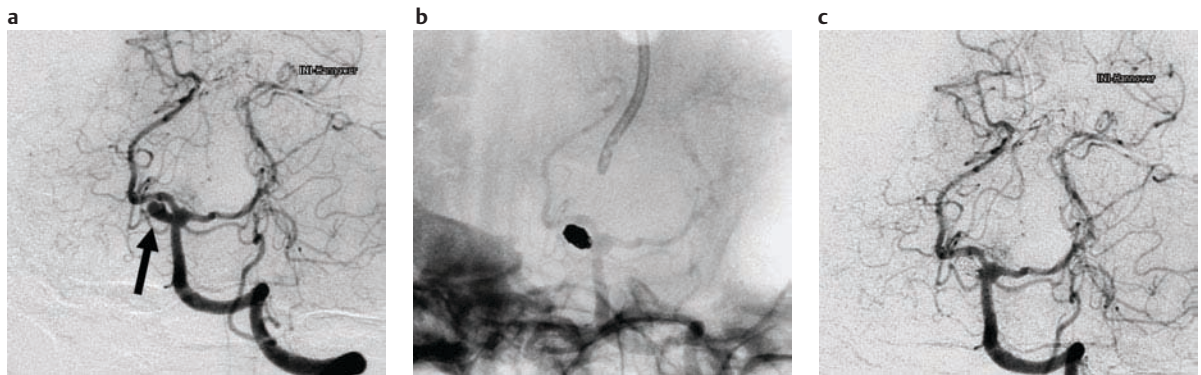


Fig. 11.4 **a** Subtraction angiography of the posterior cranial circulation in this patient demonstrates a pedunculated aneurysm (arrow) originating from the tip of the basilar artery close to the origin of the posterior cerebral arteries. **b** A number of

small coils are deposited in the aneurysm through a very fine catheter under fluoroscopic guidance. **c** The postinterventional angiographic image shows a normalized vascular pattern.

without trauma should always prompt angiography to search for an aneurysm (Fig. 11.4a), because it may continue to bleed or re-bleed with lethal consequences. A considerable number of aneurysms can be taken care of right away by interventional neuroradiology therapy (Fig. 11.4b, c). In all other cases it is the neurosurgeon's turn. Other reasons for SAH are *venous hemorrhages* or bleeding *arteriovenous malformations (AVM)*.

One major complication of SAH in an aneurysmal rupture is the breakthrough of the hemorrhage into the brain parenchyma and further into the ventricular system (see below). If the SAH is so pronounced that it obliterates a major part of the total subarachnoid space of the brain and thus hinders the resorption of the CSF that normally takes place there, an absorptive hydrocephalus may develop (Fig. 11.3b).

**Intracranial hemorrhage:** Spontaneous intracranial hemorrhage may occur as a sequel of long-standing poorly controlled arterial hypertension, particularly in the basal ganglia. If rupture into the ventricles occurs, ventricular tamponade and obstruction of the aqueduct may ensue, which leads to hydrocephalus. Neurosurgical ventriculostomy must then be performed immediately. Vascular malformations, tumors, metastases, infarction, vasculitis, and coagulopathies (including iatrogenic warfarin!) can also cause hemorrhage into the brain parenchyma. Diagnosis of an intracranial bleed is made with noncontrast CT (Fig. 11.5). MRI serves to establish the etiology of the bleed at a later time.

→ **Diagnosis:** Giufeng quickly realizes why Gregory has left right away. He is a passionate neuroangiographer and interventionalist and has already made sure that the angiography suite and the staff there are prepared

## Intracranial Hemorrhage

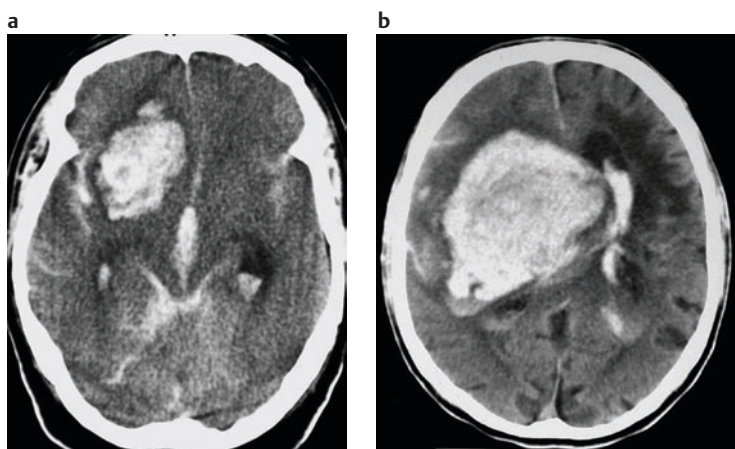


Fig. 11.5 **a** This precontrast head CT shows parenchymal hemorrhage in the frontal lobe caused by a ruptured medial cerebral artery aneurysm. The hemorrhage has broken into the ventricle. **b** In another patient, massive hemorrhage has occurred in the right hemisphere. There is a slight associated SAH on the right. The mass effect is considerable: midline shift to the left of more than 2 cm has occurred. CSF flow is already impaired, as you can see by the dilatation of the anterior horn of the left lateral ventricle. Periventricular hypodensity as seen here is thought to be associated with high ventricular pressure. This patient, unfortunately, is beyond any promising therapeutic options.



for the cerebral angiography that is about to follow. There is indeed a severe SAH, the cause of which must be found and treated as soon as possible. Giufeng briefs Mr. Klington's escorts about the findings and about what has to be done. The two ladies have known each other for a few hours only. One of them is Mr. Klington's girlfriend, the other is his wife. The girlfriend was absolutely helpless and desperate after the patient had collapsed in bed. She had telephoned Mrs. Klington for help, who was smart enough to alert and bring along the ambulance at the same time. Will Klington is lucky. The neurointerventional team finds the source of the bleed and during an intricate procedure obliterates the aneurysm with a few platinum coils. The patient leaves the hospital four weeks later without any lasting neurological deficits and with full restitution of his relevant physical abilities.

! Only noncontrast cranial CT shows small hemorrhages with sufficient certainty. For that reason, emergency CT of the head needs to be done before any other CT examinations are performed and this first run must always be done without intravenous contrast.

## Cerebral Infarction

### Checklist: Cerebral Infarction

- Are the basal ganglia and the white matter of normal density?
- Are the sulci narrowed? Are the gyri thickened?
- Do the vessels appear dense on noncontrast CT?
- Is there evidence for hemorrhage?
- If so, does the hemorrhage cause any displacement?

### Suddenly the Tea Cup Fell

Anastasia Peabody-Smith (57) had her girlfriends over for that regular 5 o'clock tea at her Woolloomooloo mansion when she suddenly suffered a stroke. Her friends called the ambulance at once and so she reached the emergency unit only half an hour after the incident. The neurologist in the emergency room diagnosed a hemiparesis on the left and transferred her immediately for a cranial CT to verify and further specify the stroke. Giufeng happens to be on duty and is the first to see the CT images flip onto the monitor (Fig. 11.6). She knows that everything depends on rapid management in these cases. Thrombolytic treatment has the potential for fast resolution of the underlying clot obstructing a brain vessel. This is hopefully followed by resolution of the symptoms. Therapy is best initiated in less than 3 hours (and in some cases up to 6 hours) after onset of symptoms but can only be performed if there is no associated intracranial hemorrhage.

### The Case of Anastasia Peabody-Smith

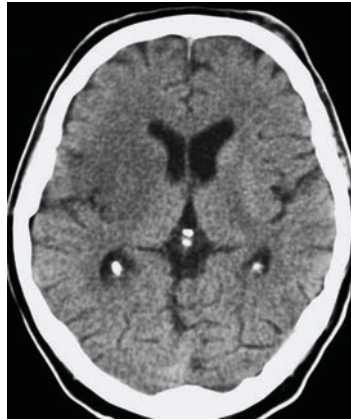

Fig. 11.6 Depicted you see the relevant CT image of Mrs. Peabody-Smith. Can you already make the diagnosis?

### → What is Your Diagnosis?

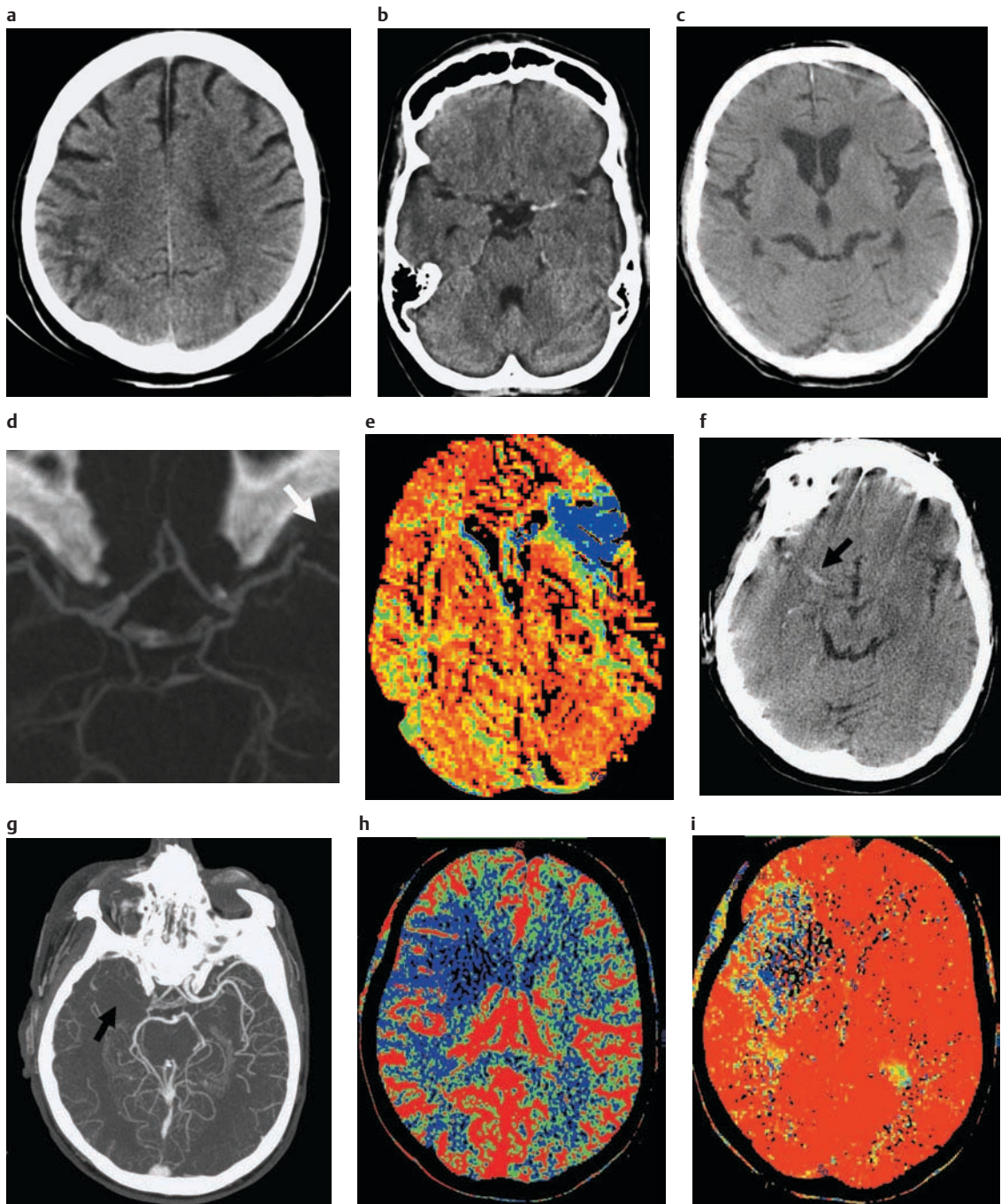
**Transient ischemic attack (TIA):** This phenomenon cannot be imaged because the underlying blood clot is too small and vessel obstruction is transient, as is the change in the dependent parenchymal territory.

**Stroke: Acute ischemic infarction (0–6 hours)** causes dependent territorial edema and subtle fading of contrast of the cerebral parenchyma (Fig. 11.7a). However, early infarcts more often than not are initially invisible on CT. Sometimes a dense thrombus is directly visible in the lumen of the medial cerebral artery (Fig. 11.7b). With modern CT angiography–perfusion imaging, defects can be detected more easily and early (Fig. 11.7c–i) Such an early nonhemorrhagic infarction can be treated with regional or systemic thrombolysis. The therapeutic success can be so dramatic that patients may be back on their feet the day after an initially paralyzing infarction. However, there is also a substantial risk of a lethal hemorrhage as a complication of thrombolysis, which must be weighed against the expected consequences of a conservatively treated infarction (Fig. 11.8).

**Subacute brain infarction (6–32 hours)** demarcates itself with more clarity against normal parenchyma (Fig. 11.9a) in comparison to the acute infarction. If, owing to the normal physiological thrombolytic processes, the previously obstructed vessels are reperfused, secondary intraparenchymal hemorrhage, so-called hemorrhagic transformation of the infarct, may be the consequence (Fig. 11.9b, c). Other underlying lesions and hemorrhage due to other etiologies must be considered and excluded (see p. 235). In most cases this differentiation is possible on the basis of the clinical history.

In patients with a *chronic ischemic infarct*, the damaged, necrotic tissue is progressively cleared by microglial cells. During this process superperfusion or “luxury”-perfusion may occur (Fig. 11.10a, b). Eventually the infarcted area may become a CSF-filled parenchymal defect with the

## Acute Stroke

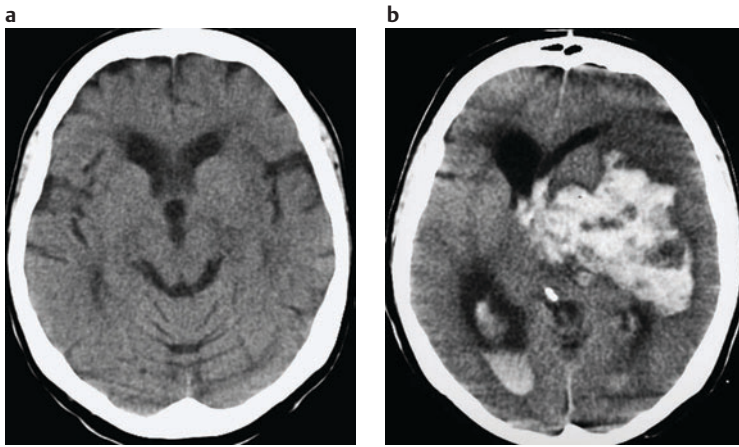


**Fig. 11.7 a** In this patient with a one-hour history of left arm weakness, the right parietal sulci are swollen and the parenchymal density is decreased. **b** In another patient with right-sided hemiparesis, the noncontrast CT shows an obvious hyperdensity of the left medial cerebral artery—a phenomenon called “dense media sign.” You are actually looking at the thrombus within the vessel! **c** In this patient there is a very subtle swelling of the left frontal lobe anterior to the sylvian fissure. **d** CT angiography of the circle of Willis shows vascular obstruction of a left middle cerebral branch (arrow). **e** The calculated perfusion image shows the perfusion defect where we suspected it on the

basis of the conventional imaging. Take a step back and look at **c–e** together. **f** This CT of a restless patient shows a dense media sign (arrow) on the right. No hemorrhage is seen here and elsewhere on the slices. **g** CT angiography confirms the obstruction of the right medial cerebral artery (arrow). **h** The flow map proves the perfusion defect in the vascular territory of the medial cerebral artery. **i** The mean transit time is visibly altered in the same area. The area does not exceed two-thirds of the vascular territory of the medial cerebral artery. This is a good case for immediate locoregional thrombolysis.



### Risk of Thrombolysis



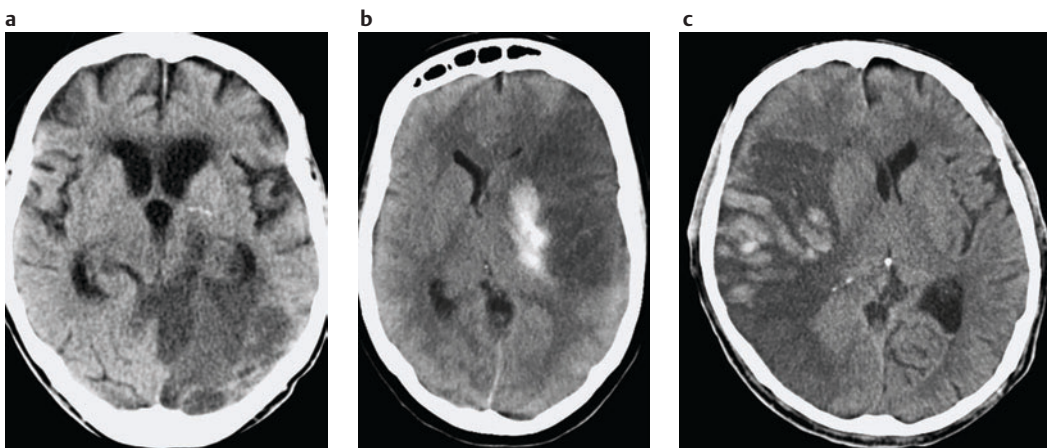
**Fig. 11.8 a** Initial noncontrast head CT of this patient shows very subtle edema of the basal ganglia on the left, indicating infarction that has led to an acute right-sided hemiparesis. There was definitely no hemorrhage present at the time of diagnosis. **b** Regional thrombolysis initiated immediately after the head CT was complicated by massive hemorrhage extending into the ventricle and a subsequent CSF flow obstruction. See the blood in the right posterior horn of the lateral ventricle. There is extreme midline shift. This patient did not survive.

neighboring ventricles widening to compensate for the loss of tissue (Fig. 11.10c).

**Sinus thrombosis:** Thromboses of the venous sinuses can cause brain infarctions owing to congestion and outflow obstruction. They occur in a number of disease entities: if oral contraceptives are used or as a complication of septic intracranial processes. Clinically they manifest with varying uncharacteristic neurological symptoms and epileptic seizures. It is crucial for the clinician to consider them in the differential of not so typical acute CNS problems! The diagnosis is verified by MRI (Fig. 11.11). The “empty delta sign” is pathognomonic: thrombus surrounded by contrast-enhanced blood is seen within the venous confluence.

→ **Diagnosis:** Giufeng calls Greg and also gets in touch with the neurologist. She thinks Mrs. Peabody-Smith has a fresh stroke without a hemorrhagic component. She sees some loss of gray–white matter differentiation in the right basal ganglia compared with the contralateral side: the right internal capsule, the caudate head, and the globus pallidum cannot be differentiated. Thrombolysis is a real option in this case, but inherent risks have to be considered. Whether the therapy is going to be administered intravenously by the neurologists or regionally into the feeding artery by the interventional neuroradiologist must be decided now. But that is definitely something for Gregory to manage.

### Subacute Stroke



**Fig. 11.9 a** This patient came to the hospital with cortical blindness of two days’ duration. The head CT shows an already well-demarcated infarction in the left occipital lobe. **b** In another

patient, reperfusion of the infarcted territory has led to secondary parenchymal hemorrhage—a hemorrhagic infarction. **c** Such hemorrhage can also occur in infarcted gray matter.



## Old Stroke

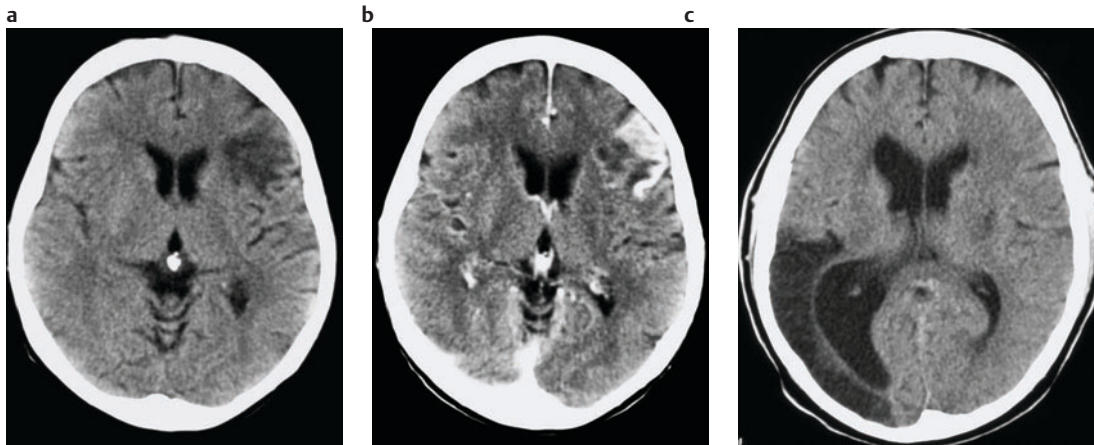


Fig. 11.10 **a** The precontrast head CT shows circumscribed hypodensity in the left frontal region. **b** After contrast administration, accumulation of contrast in the cortex indicates increased vascularity in this area during resorption of the necrotic

tissue. **c** This stroke in the posterior vascular territory of the right medial cerebral artery has been all but completely resorbed. In response there is impressive ex-vacuo dilatation of the posterior horn of the right lateral ventricle.

## Venous Sinus Thrombosis and Venous Infarction

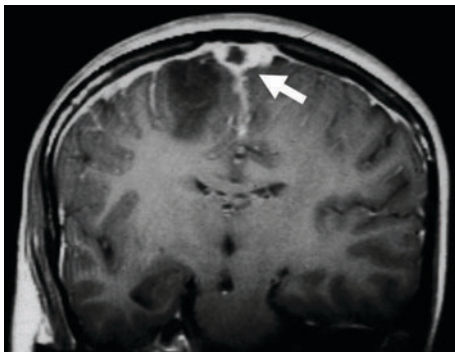


Fig. 11.11 This T1-weighted coronal MRI sequence after contrast administration shows signal loss in the right paramedian region of the cortex next to the interhemispheric fissure caused by venous infarction. A typical filling defect seen in the superior sagittal sinus is the underlying occlusive venous thrombus (arrow).

**!** The first 6 hours are crucial in the management of stroke: The patient must be rushed into a hospital with a stroke center. Get a CT immediately to exclude hemorrhage. Unless contraindicated, initiate systemic or regional thrombolysis as soon as possible if the risks appear acceptable under the circumstances.

## 11.3 Brain Tumors

## Checklist: Brain Tumors

- How old is the patient?
- Is the mass in the brain (intra-axial) or outside the brain parenchyma (extra-axial)?
- Is it a solitary mass or are there multiple lesions?
- What is the predominant CT density of the mass?
- Does it contain cystic components?
- Is there any noticeable contrast enhancement or none?
- What, if any, degree of associated edema is present in the surrounding brain parenchyma?
- Is there any midline shift and, if so, how much? Is there a suggestion of impending brain herniation?
- Is there any hydrocephalus?

## What on Earth is Wrong with My Husband?

Joe-James Lee-Chong (47) is accompanied by his wife. They have consulted the neurologists together because Mr. Lee-Chong has had a chronic headache for quite a few weeks. Before that he was never really sick. His wife reports that he is normally a very active and humorous personality. Now he tends to sit in this armchair and does not seem to care about anything. A sudden tonic seizure last week scared the daylights out of them and made his wife get an urgent appointment with the neurologist. Paul is covering one of the MRI scanners today. He has spoken to the couple before, briefed them about the examination and about the administration of contrast medium. After leafing through the images of the first MRI sequence, he has asked for additional contrast-enhanced series in the sagittal and

### The Case of Joe-James Lee-Chong

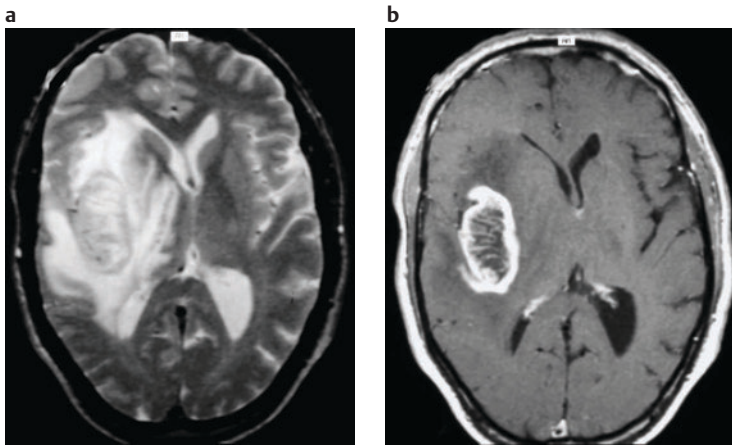


Fig. 11.12 Here you see the relevant MRI images of Mr. Lee-Chong. Figure out what kind of MRI sequence images **a** and **b** may be part of.

coronal planes. Now he delves into the complete MRI examination and singles out a representative section (Fig. 11.12).

#### → What is Your Diagnosis?

**Meningioma:** Meningiomas are the most frequent intracranial tumors. Their biological behavior is that of a benign tumor, i.e., they do not metastasize. But they can grow over time and press on important neighboring structures in and around the brain and therefore may need to be removed. They originate in the meninges, that is, the periosteum of the skull, the falx cerebri, and the tentorium. Thus they are located extra-axially and are not primary brain tumors in the strict sense. Frequently they involve the skull base. They grow very slowly, often ossify, and expand the neighboring bone and sclerose it. The surrounding brain tissue is rarely edematous. On CT they often appear dense even before contrast is given (Fig. 11.13) and they always enhance significantly after intravenous contrast administration. On

MRI meningiomas may be overlooked on noncontrast sequences because they rarely have regressive changes in them and are roughly isointense with brain parenchyma; however, after contrast administration they often show dramatic enhancement (Fig. 11.14).

**Oligodendroglioma:** Oligodendrogliomas constitute about 5% of all true brain tumors of adulthood. They grow slowly, prefer the frontal lobe location, and tend to develop coarse calcifications (Fig. 11.15).

**Astrocytoma:** Astrocytomas (or gliomas) are the most important primary brain tumors. They are classified into four groups (with distinctly different biological behavior and prognosis) that show differences in imaging appearance:

- Grade 1 astrocytomas are also called pilocystic astrocytomas. They occur primarily in children (see Fig. 11.24).
- Grade 2 astrocytomas are tumors of early adulthood. They are typically sharply margined, have little surrounding edema, and enhance only minimally or not

### Meningioma on CT

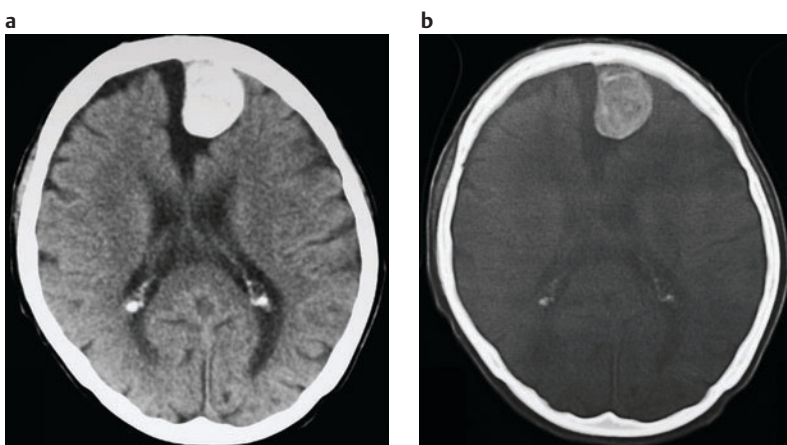


Fig. 11.13 **a** A noncontrast head CT study clearly depicts the meningioma originating from the falx cerebri. **b** The bone window demonstrates partial calcification of the lesion.

### Meningioma on MR Imaging

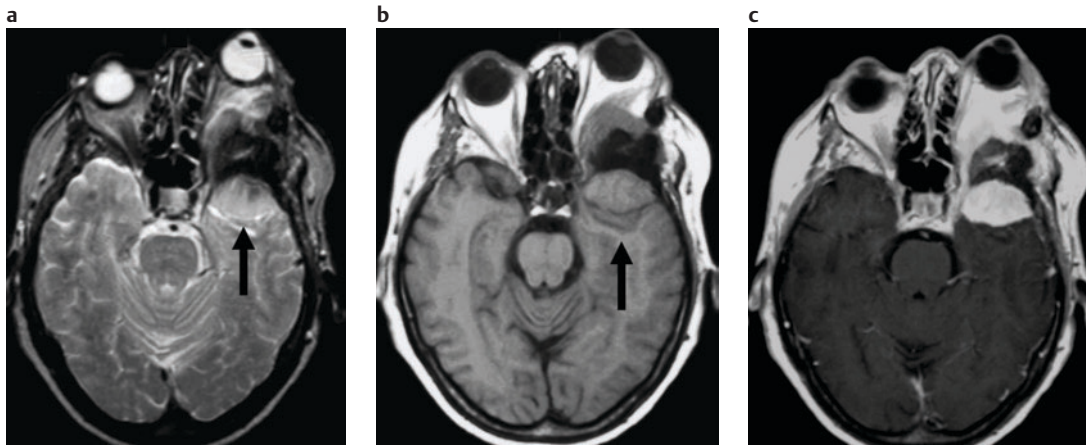


Fig. 11.14 **a and b** On T2-weighted (**a**) and noncontrast T1-weighted (**b**) MR images you recognize a sphenoid wing meningeoma only after a careful analysis of the anatomy. The T2 sequence does not show any associated edema. The soft tissue component is isointense to the cerebral parenchyma (arrow). The adjacent sphenoid wing is expanded and sclerotic. **c** After

contrast administration, the situation becomes much clearer: The soft tissue component enhances markedly and is easily differentiated from surrounding normal brain parenchyma. However, the tumor is now almost impossible to distinguish from the orbital fat because no fat-suppression technique was used when this study was acquired!

at all after contrast administration (Fig. 11.16a). Morphological differentiation from an infarction is not always possible without a follow-up examination.

- Grade 3 astrocytomas are also called anaplastic astrocytomas. They are tumors of the middle-aged adult. Their margins tend to be diffuse; they are surrounded by considerable edema and accumulate contrast inhomogeneously.
- The grade 4 astrocytoma or glioblastoma multiforme is the most common primary malignant brain tumor. It

predominates in older adults. It is characterized by a pronounced perifocal edema, an intense and frequently serpiginous contrast enhancement, large central necroses, and an unsharp contour (Fig. 11.16b). The lesion is difficult to differentiate from an abscess on purely morphological grounds. The tumor has an infiltrative growth pattern and can rarely be resected completely. The part of the tumor that is visible on diagnostic imaging unfortunately represents only the “tip of the iceberg”; at the time of diagnosis, tumor cells have virtually

### Oligodendroglioma

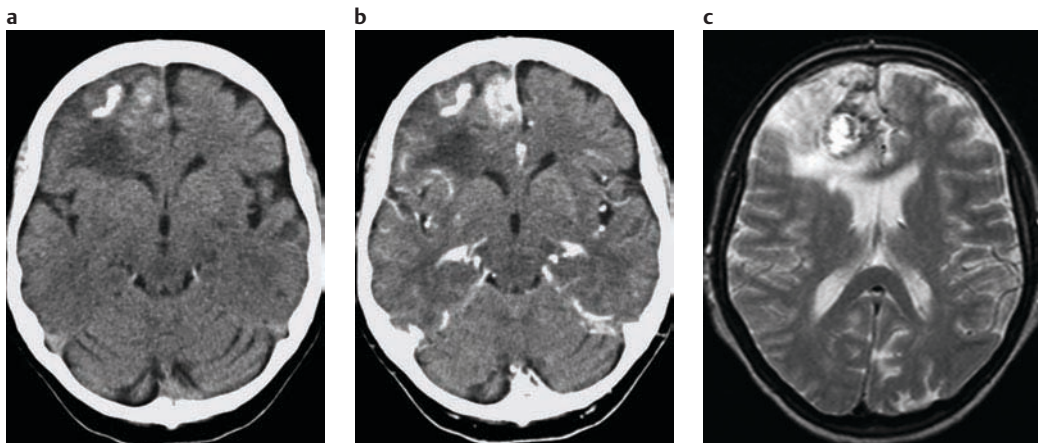


Fig. 11.15 **a** Noncontrast head CT demonstrates a mass in the right frontal lobe with obvious perifocal edema containing coarse calcifications. **b** After contrast administration, the lesion enhances in an inhomogeneous fashion. This combination of

findings is highly suggestive of an oligodendroglioma. **c** The T2-weighted MR image confirms the presence of white-matter edema; the central components of poor signal in the tumor correspond to the calcifications seen on CT.



## Astrocytoma

## a Astrocytoma grade 2

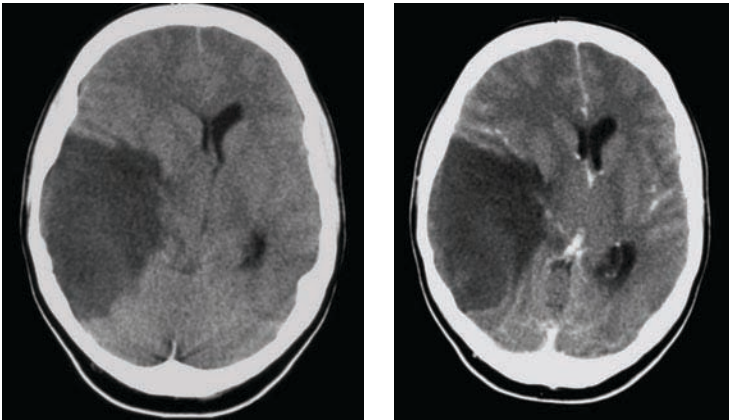
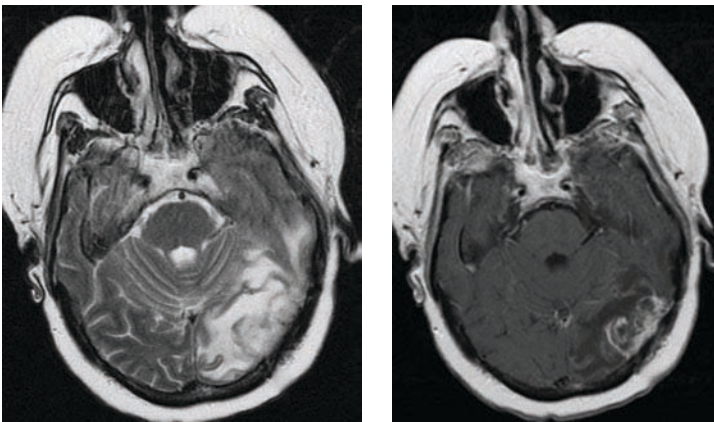


Fig. 11.16a Noncontrast head CT (left) depicts a hypodense, well-demarcated lesion in the right temporal lobe. After contrast administration (right), the tumor, a grade 2 astrocytoma, remains unchanged. A subacute stroke could have a similar appearance. **b** In the T2-weighted sequence (left), edema is seen in the left occipital lobe. After contrast administration, the T1-weighted sequence (right) demonstrates small contrast-enhancing foci, compatible with but not specific for a malignant tumor. This is a grade 4 astrocytoma. Small abscesses, for example, in toxoplasmosis, may look similar.

## b Astrocytoma grade 4



always already spread along white-matter tracts into other parts of the brain, invisible to the radiologist or neurosurgeon.

**!** Preoperative imaging of brain tumors requires a complete depiction of their configuration, size, and spatial relationship to important neighboring anatomical structures in three planes with contrast-enhanced T1-weighted sequences.

**Hemangioblastoma:** Hemangioblastomas occur in middle-aged adults and are preferentially located in the cerebellum. In 15% of cases they are associated with von Hippel–Lindau disease. The typical image appearance is that of a large cyst with a strongly contrast-enhancing mural nodule (Fig. 11.17).

**Brain metastases:** Brain metastases are multifocal in 70% of cases (Fig. 11.18). MRI is the most sensitive modality for detection of metastases (Fig. 11.19). Metastases are often characterized by extensive perilesional edema and strong contrast enhancement; lung and breast carcinomas are among the most common primary tumors to cause brain metastases.

## Hemangioblastoma

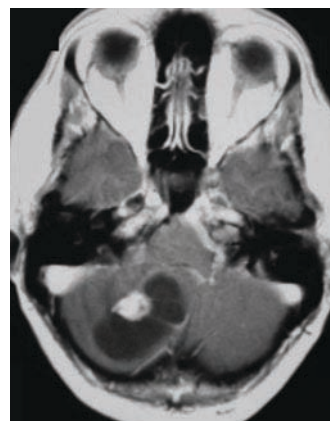
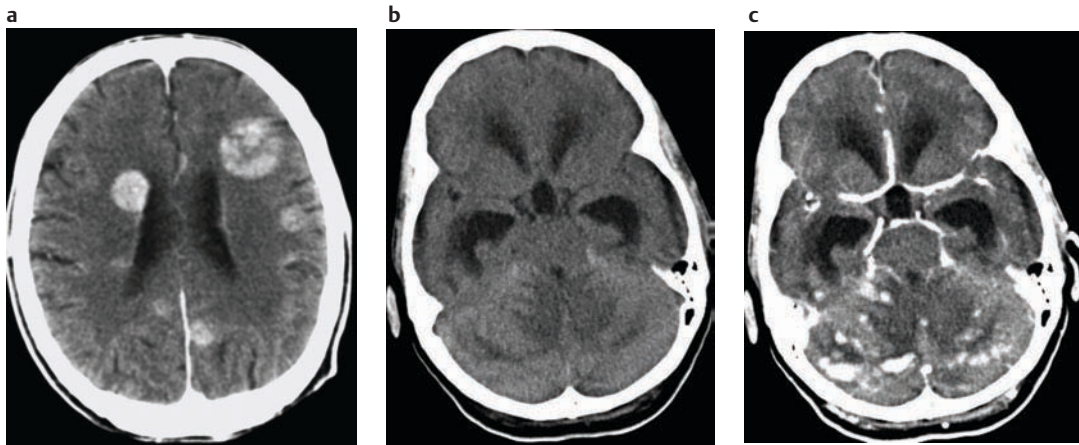


Fig. 11.17 This hemangioblastoma is located in the right cerebellar hemisphere. The T1-weighted sequence after contrast administration shows the typical appearance of a cyst with a peripheral enhancing nodule.

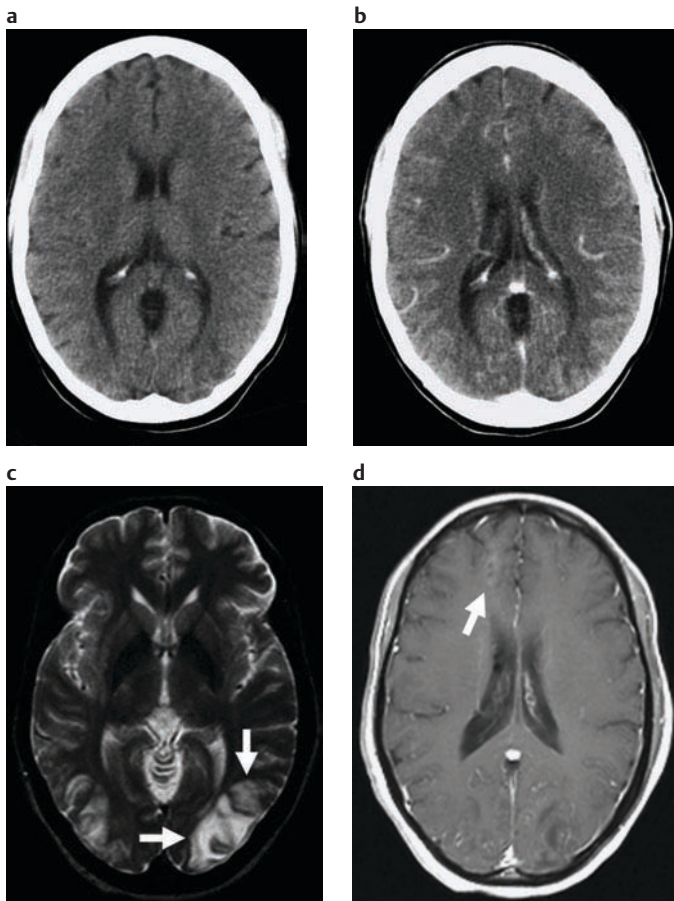
## Brain Metastases



**Fig. 11.18 a** This postcontrast CT image shows multiple metastases from a bronchial carcinoma. Now the radiation oncologists have to get to work. **b** The exterior CSF space is completely used up in this posterior fossa. A supratentorial obstruction hydrocephalus has developed. The reasons for this are unclear in

this precontrast scan. **c** After contrast administration, the metastases in the posterior fossa are delineated with great clarity. The lesions themselves and the surrounding edema led to the obliteration of the exterior CSF spaces.

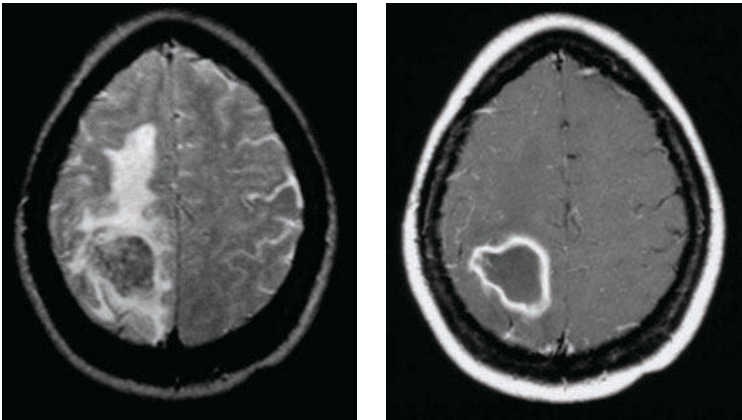
## Detection of Brain Metastases



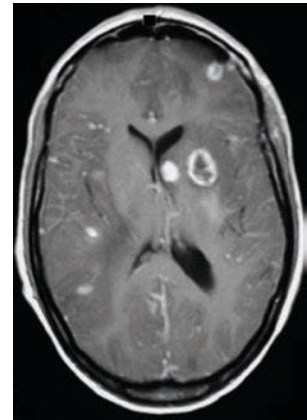
**Fig. 11.19** This image sequence illustrates the differential sensitivity of CT and MRI in diagnosing brain metastases. **a** This noncontrast CT could very well be reported as normal. **b** Even after contrast administration a lesion is difficult to appreciate. **c** It is the T2-weighted MRI that shows the associated edema in both occipital lobes (arrows). **d** The T1-weighted sequence after contrast administration just a little more superiorly suggests a vague contrast accumulation occipitally and another very small metastasis in the right frontal lobe (arrow). These are early brain metastases of a breast carcinoma.

## Intracranial Infection

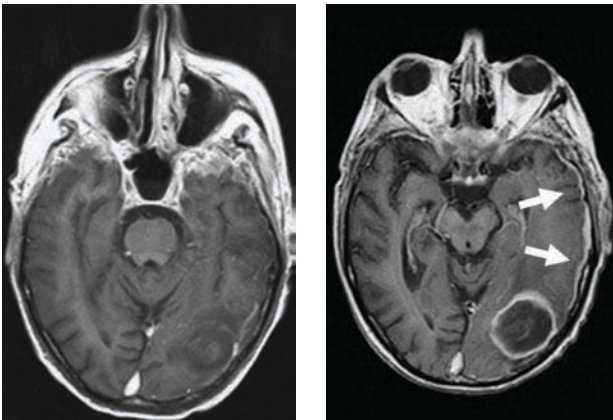
a Tuberculosis



b Toxoplasmosis



c Invasive aspergillosis



d Subdural empyema

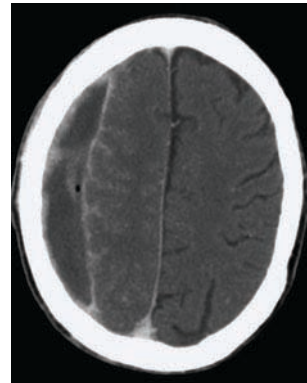


Fig. 11.20 **a** The T2-weighted sequence (left) reveals a tuberculous abscess in the right parietal lobe that is surrounded by extensive edema. In the contrast-enhanced T1-weighted sequence (right), the typical accumulation of contrast in the abscess wall is very well appreciated. **b** Multiple small contrast-enhancing lesions are visible in white matter and subependymally (around the ventricle). Some of them show ringlike structure. This cerebral toxoplasmosis developed in a patient with HIV infection. Based on imaging alone, HIV-associated lymphoma is a possible differential diagnosis. **c** This neutropenic patient with

an acute myeloid leukemia has developed a mycotic abscess in the left occipital lobe with no perilesional reaction to speak of even after contrast administration (left). Only two weeks later (right), after the blood marrow has recovered, the patient is able to mount a more vigorous immune response and the same sequence reveals contrast accumulation in the abscess wall as well as along the adjacent meninges (arrows). **d** This chronic subdural hematoma has become infected after a primary and ineffective drainage. After contrast administration, the surrounding leptomeninges enhance significantly.

**Brain abscess:** A brain abscess develops after the hematogenous spread of septic emboli to the brain (for example, in patients with endocarditis), in immunosuppressed patients, and with direct or venous intracranial spread of bacteria stemming from infected paranasal sinuses (see Fig. 13.7d, p. 290) or the mastoid air cells. In an immunocompetent patient, a brain abscess typically shows strong contrast enhancement in the periphery of the lesion and extensive surrounding edema (Fig. 11.20a).

Advanced HIV infection, therapeutic immunosuppression after solid organ transplantation, advanced hematological diseases, and aggressive chemotherapy can significantly impair the immune response of a patient and disseminated fungal abscesses may develop (Fig. 11.20b, c). These fungal lesions often fail to exhibit the strongly contrast-enhancing abscess membranes that reflect the intact normal immune response in the common bacterial infections. Of course, hematomas can also become superinfected (Fig. 11.20d).

**Lymphoma:** Two percent of all brain tumors are lymphomas. These are particularly frequent in HIV-infected patients. Lymphomas enhance significantly after contrast administration. Morphologically it may be challenging to differentiate them from a glioblastoma or an abscess (Fig. 11.21).

Advanced HIV infection, therapeutic immunosuppression after solid organ transplantation, advanced hematological diseases, and aggressive chemotherapy can significantly impair the immune response of a patient and disseminated fungal abscesses may develop (Fig. 11.20b, c). These fungal lesions often fail to exhibit the strongly contrast-enhancing abscess membranes that reflect the intact normal immune response in the common bacterial infections. Of course, hematomas can also become superinfected (Fig. 11.20d).



### Intracranial Lymphoma

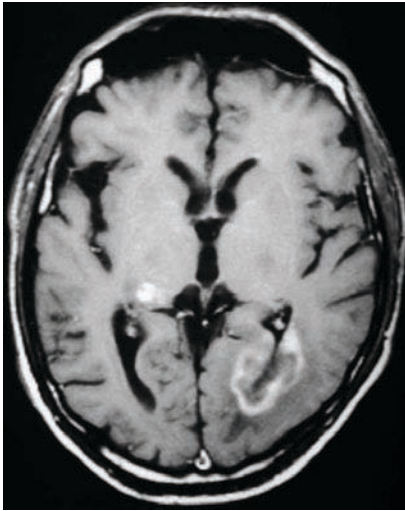


Fig. 11.21 In this patient, lymphoma involves the basal ganglia and insinuates itself around the ventricle. Such findings in an HIV patient are difficult to differentiate from toxoplasmosis on morphological grounds. Correlation with laboratory findings helps.

**Multiple sclerosis (MS):** Multiple sclerosis is a demyelinating disease of early adulthood and of unknown etiology. It may run an acute relapsing or a continuously progressive course. The symptomatology is quite variable, which is why brain tumors must also be excluded as a cause when nonspecific neurological symptoms are encountered. The demyelinated lesions are typically located in the immediate vicinity of the lateral ventricle and are oriented in a centrifugal pattern. In active disease the lesions may accumulate contrast (Fig. 11.22). MS is generally diagnosed by CSF analysis.

→ **Diagnosis:** Paul diagnoses a solitary, aggressive, intra-axial primary brain tumor—most likely a glioblastoma. Gregory has to agree: an inflammatory process seems very unlikely on the basis of the patient history. The neurosurgical biopsy performed a few days later unfortunately confirms the suspected tumor type. The Lee-Chongs need a lot of strength now to deal with the dire consequences of this devastating diagnosis.

! Brain tumors very rarely metastasize to extracranial locations, but quite a few extracranial tumors metastasize into the head.

### Multiple Sclerosis

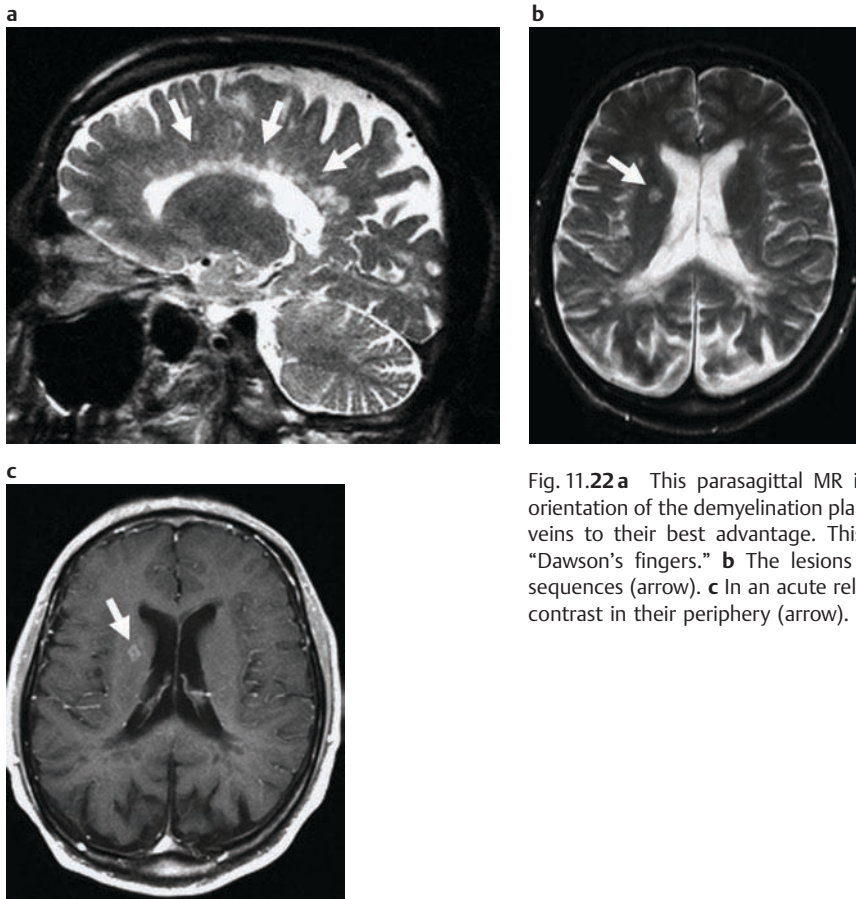


Fig. 11.22 **a** This parasagittal MR image shows the typical centripetal orientation of the demyelination plaques along the long axis of medullary veins to their best advantage. This phenomenon is sometimes called “Dawson’s fingers.” **b** The lesions have a high signal in T2-weighted sequences (arrow). **c** In an acute relapse, the lesions tend to accumulate contrast in their periphery (arrow).

## The Case of Jerry Flockheart

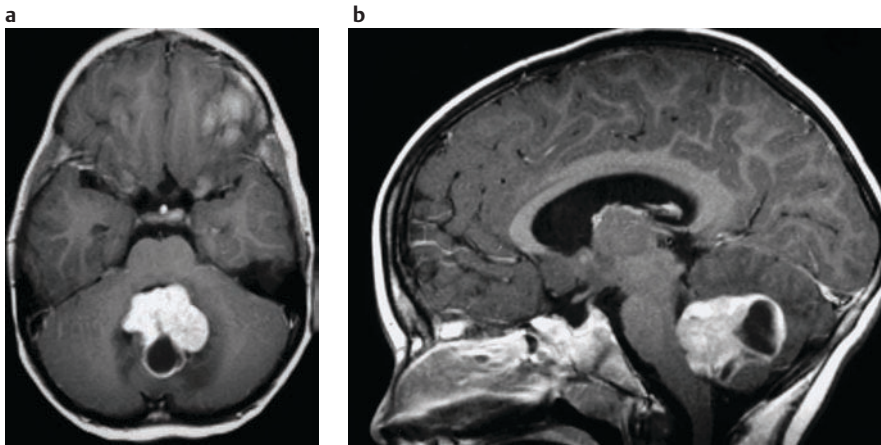


Fig. 11.23 What comes to your mind when you look at these representative images of Jerry Flockheart's cranial MRI?

## Our Child is So Sick

The parents of Jerry Flockheart (8) are extremely worried. The little fellow has repeatedly complained about headaches, cannot walk straight anymore, and has vomited several times during the past week. The pediatrician has immediately requested an MRI. Giufeng and Paul have prepared the frightened boy as well as possible for the examination, especially the long stay in the narrow MR gantry. They want to spare him the general anesthesia that is otherwise necessary. During the examination Jerry's father sits down at the head end of the gantry and talks to him now and then. At last the scan is completed and the first images become available. Jerry has been brave and has kept perfectly still. Both students are eager to view the images on the monitor (Fig. 11.23)

## → What is Your Diagnosis?

**Pilocytic astrocytoma (see p. 241):** Pilocytic astrocytoma, also called grade 1 astrocytoma, is the most frequent brain tumor in childhood. It occurs primarily in the posterior fossa (Fig. 11.24) and around the optical chiasm. Frequently the tumor has a cystic component. Its solid parts accumulate contrast intensely.

**Medulloblastoma, ependymoma:** Medulloblastomas constitute about 20% and ependymomas about 5% of primary brain tumors in children. Both originate in the cerebellum, contain cysts and calcifications, and enhance moderately after contrast administration (Fig. 11.25). Both may lead to CSF flow obstruction and thus to a hydrocephalus.

**Pontine glioma:** This tumor is the third most frequent CNS tumor in childhood (Fig. 11.26). It enhances minimally and behaves morphologically like a grade 2 astrocytoma (see p. 241).

## Pilocytic Astrocytoma

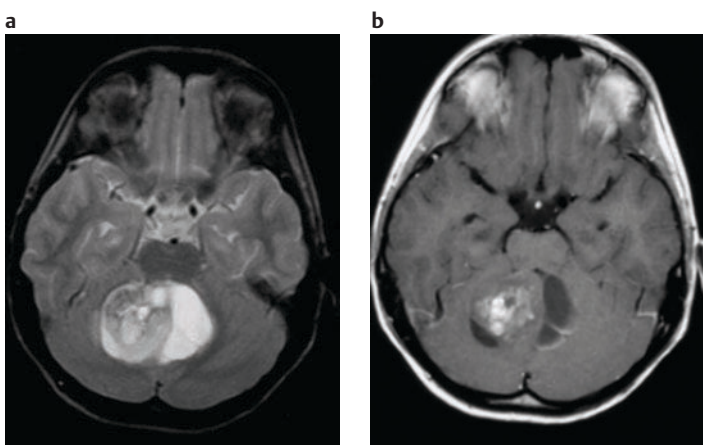


Fig. 11.24 **a** This T2-weighted MR image demonstrates a typical pilocytic astrocytoma. The tumor is partially cystic and lacks surrounding edema. **b** After contrast administration, the solid components enhance significantly.

### Medulloblastoma

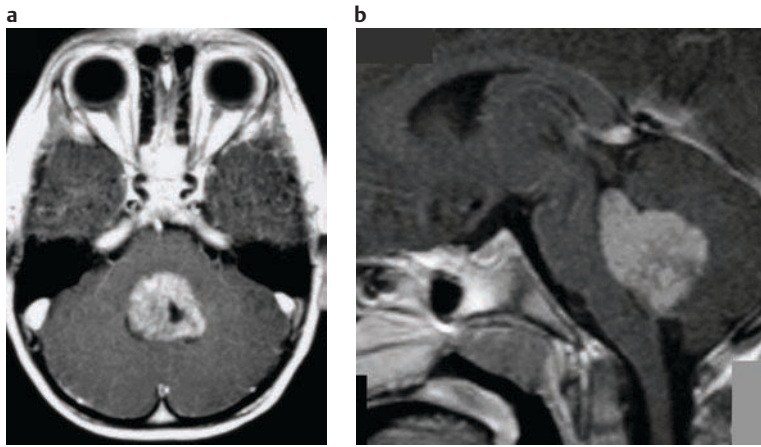


Fig. 11.25 The post-contrast axial (a) and sagittal (b) MR images reveal a mass in or around the fourth ventricle with a small cyst inside. This is a medulloblastoma. Based on its imaging appearance, the differential diagnosis includes an ependymoma.

### Pontine Glioma

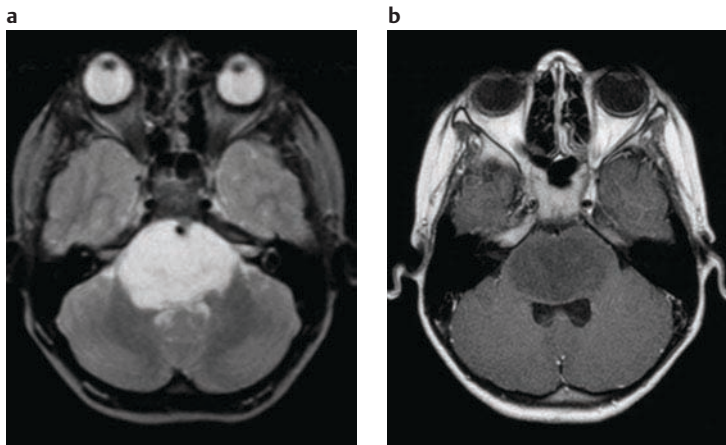


Fig. 11.26 a Massive signal increase and expansion of the pons are very well appreciated on the T2-weighted images. b After contrast administration, there is no perceptible enhancement, as is frequently the case in pontine glioma.

**Arachnoid cyst:** Arachnoid cysts are located extra-axially and as a rule are asymptomatic. They may expand, however, causing headaches in due course. They are preferentially located at the skull base, often in the temporal fossa. In MRI and CT their signal/density follows that of cerebrospinal fluid, with which they are filled (Fig. 11.27).

**Colloid cyst:** This entity is a cystic tumor whose content is rich in protein. It originates in the immediate vicinity of the foramen of Monroe (Fig. 11.28). If the tumor blocks the foramen, an obstruction of the physiological CSF circulation results in acute hydrocephalus. This crisis is characterized by a sudden intense headache associated with nausea and emesis. Occasionally syncope ensues. The clinical appearance can be quite characteristic: a young adult suddenly becomes unconscious, falls to the ground, shakes the head and gets up again, becomes unconscious, falls to the ground, shakes the head and gets up again, becomes unconscious ....

### Arachnoid Cyst

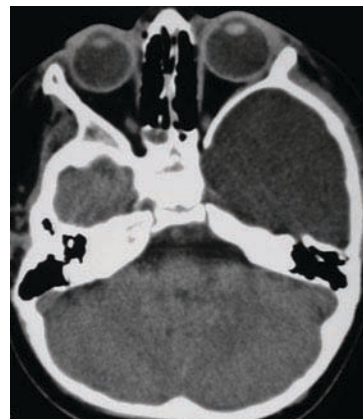


Fig. 11.27 The CT section shows a mass of CSF density that has expanded the temporal fossa. This patient suffered from epileptic seizures. Most arachnoid cysts are much smaller and basically represent normal variants.



## Colloid Cyst

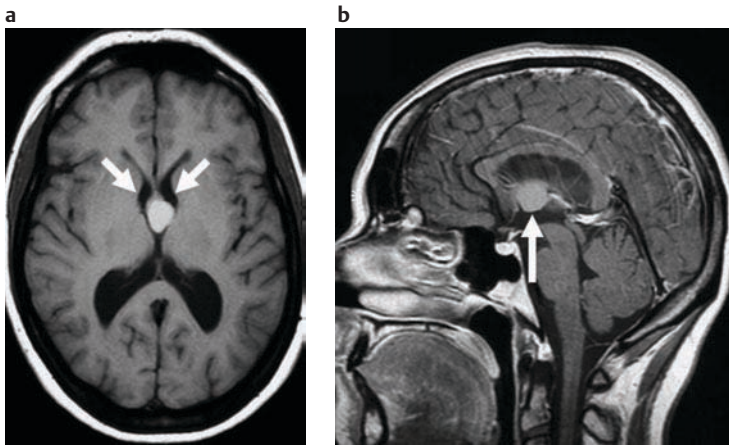


Fig. 11.28 **a** The T1-weighted image beautifully displays this cyst in the area of the foramen of Monro (arrows) even before contrast administration. It is high in signal because its content is protein rich. **b** This sagittal postcontrast image demonstrates the origin of the cyst (arrow) at the roof of the third ventricle.

**Arteriovenous malformation:** A congenital vascular malformation may become symptomatic owing to repetitive intraparenchymal and subarachnoidal bleeds. Without therapy the prognosis is dismal. On CT, calcifications within the brain parenchyma point to the diagnosis. MRI shows to advantage the vascular character of the lesion as well as remnants of previous hemorrhages (Fig. 11.29). Preferred therapy is minimally invasive occlusion of the lesion by the neurointerventional radiologist (Fig. 11.30). This dangerous procedure should only be done by experienced specialists in the field.

→ **Diagnosis:** Giufeng and Paul scratch the back of their heads. This is definitely an infratentorial tumor within or around the fourth ventricle. Medulloblastoma, ependymoma, or a pilocytic astrocytoma? The last is the most probable. A hemangioblastoma would fit morphologically but does not occur in this age group. Gregory comes around and cuts their academic discussion short. “It’s gonna have to come out anyway,” he says and blows his nose. “For crying out loud, call it a pilo!” Giufeng and Paul are taken aback a little by his cavalier tone—it is a brain tumor in a child, after all. Greg sinks back into his chair: “Listen, folks, for you it is the first pediatric brain tumor. I have been through this a couple of times. You somehow need a little distance from the situation. Otherwise you crack up.” He pulls himself up again, adjusts his tie, and walks to the door slowly. “I’m gonna have a word with the parents,” he mutters.

## Arteriovenous Angioma

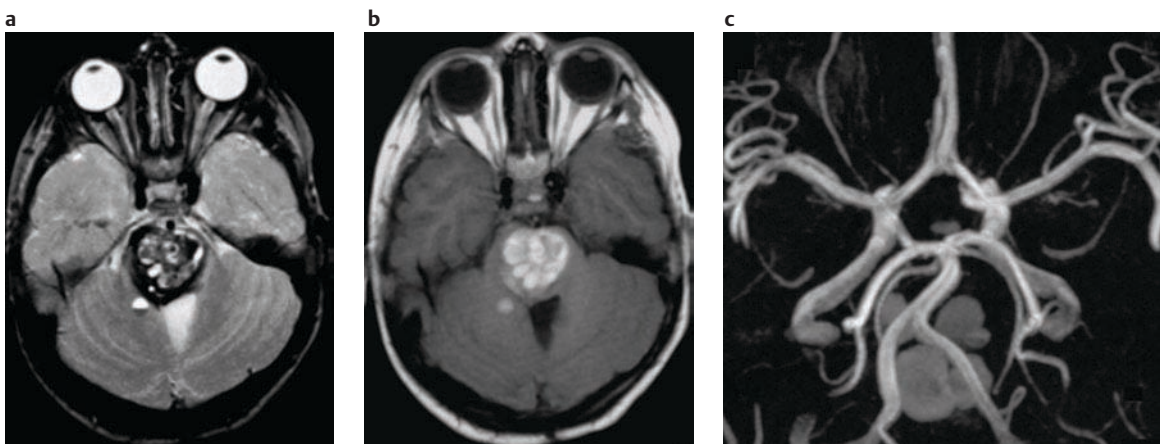
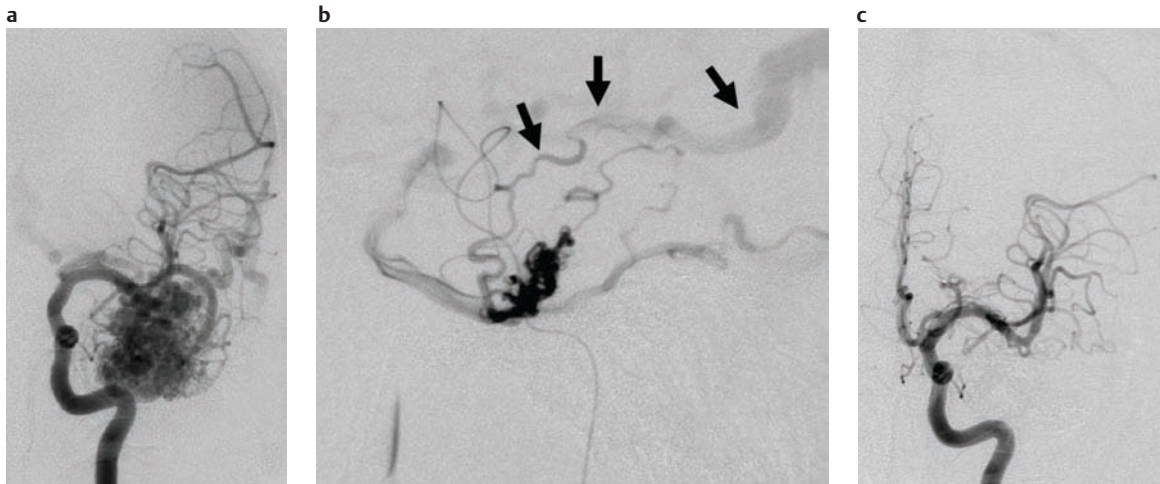

Fig. 11.29 **a** The axial T2-weighted MR section reveals a mass in the pons with very heterogeneous signal. **b** Portions of the tumor also have high signal on the T1-weighted images, indicating

of extracellular methemoglobin related to previous hemorrhage. **c** MR angiography (this is an inferior projection of a 3D image) confirms a hypervascular lesion in the pons.

### Therapy of an Arteriovenous Angioma



**Fig. 11.30 a** This angiographic image (A-P projection) of another patient shows an extensive vascular malformation in the left temporal region that originates from the middle cerebral artery. **b** Selective angiography with a very fine coaxial catheter

shows the angioma and its early venous drainage (arrows) with greater clarity. **c** This angioma was embolized and the normal vascular anatomy was completely reconstituted.



#### What Should You Pay Attention To in an MR Examination?

The cooperation of the patient is very important in MR imaging because of the long scanning times. In children and uncooperative patients one should make sure ahead of time that they will be able to lie still for the required time and that they will tolerate the unusually loud noises of the gradient coils in the scanner. Individuals who accompany the patient to the examination are permitted to stay in the scanner room but have to follow the same precautionary measures that apply to the patient. Thorough briefing of the patient may save the patient general anesthesia! If general anesthesia is necessary, the whole team should be 100% focused to get all the required information out of the study and to keep the anesthesia time short. And, of course, the lights and the voices in the room should be low.

#### The Car Came Out of Nowhere

Cathy Nuremberg (22) has just about recovered from a serious motor vehicle accident that she caused because she ignored someone else's right of way. She feels quite guilty and was relieved when she heard that no one else was seriously hurt. And now she has another problem on top of that: the doctor in the eye clinic whom she consulted merely to get a new pair of ultrathin glasses has sent her for an MRI because something was wrong with her eye examination. The little request note says something about a visual field defect. Paul has talked to Mrs. Nuremberg and is quite eager to see the result of the dedicated sellar MRI (Fig. 11.31).

**!** Masses in and around the sella can cause endocrine disturbances and characteristic visual field defects.

### Perisellar Brain Tumors

#### Checklist: Perisellar Brain Tumors

- Are there visual disturbances or endocrine symptoms?
- Does the mass originate in the sella or is it extrasellar, compressing the sellar content?
- Is the mass solid or cystic?
- Is the cavernous sinus involved?
- Is the sphenoid sinus normally pneumatized?

#### → What is Your Diagnosis?

##### Tumors:

**Pituitary adenoma:** Pituitary adenoma is the most frequent sellar or juxtaseilar mass. It originates from the anterior pituitary lobe. When a tumor is hormonally active (classic clinical syndromes are acromegaly and Cushing disease), it can be diagnosed early and is frequently very small at the time of diagnosis (microadenoma). A microadenoma does not accumulate contrast as avidly as normal pituitary parenchyma, which is why it appears hypointense in comparison to its surrounding. A hormonally inactive tumor becomes symptomatic as it compresses the neighboring structures (bitemporal hemianopsia, pituitary insuffi-

### The Case of Cathy Nuremberg

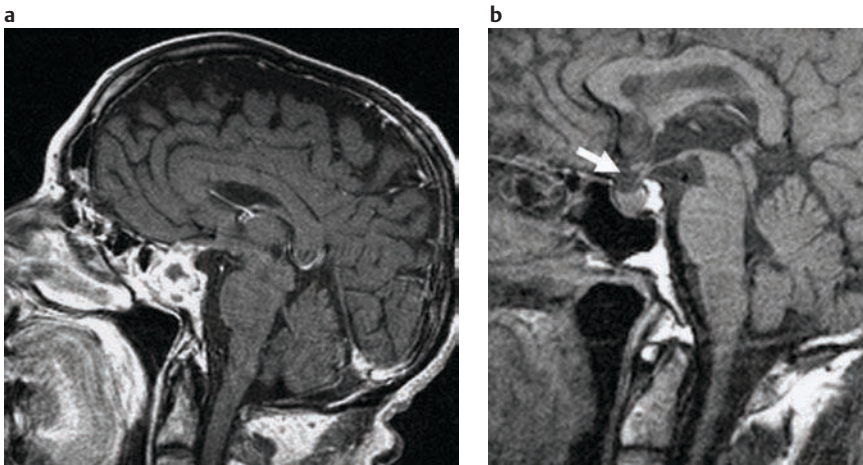


Fig. 11.31 **a** Here you see a representative MR section of Cathy Nuremberg's head. Do you notice any abnormalities? **b** Compare her image to this normal sagittal noncontrast MRI section of the pituitary gland. Typically the fine pituitary stalk (arrow) leads to the low-signal-intensity anterior adenohypophysis,

which occupies most of the sella, and the smaller high-signal-intensity dorsal neurohypophysis. The brightness of the dorsal pituitary lobe is considered to be due to signal characteristics of its hormone content.

ciency). If the tumor is large it may enhance significantly after contrast administration (Fig. 11.32) and invade its vicinity.

**!** After contrast administration, a microadenoma typically appears hypodense in comparison to the surrounding strongly enhancing pituitary gland. A macroadenoma, on the other hand, accumulates contrast rapidly and stands out against the compressed surrounding structures.

**Craniopharyngioma:** This slow-growing tumor arises from the squamous epithelial remnants of Rathke's pouch in children and young adults. This tumor has cystic, solid, and calcified components as well as a firm capsule (Fig. 11.33). From the suprasellar region it can extend into the third ventricle. Compression of perisellar structures may cause bitemporal hemianopia and even pituitary insufficiency may develop.

**Miscellaneous perisellar tumors:** Metastases to the skull base (Fig. 11.34a) as well as regional tumors such as

### Pituitary Adenoma

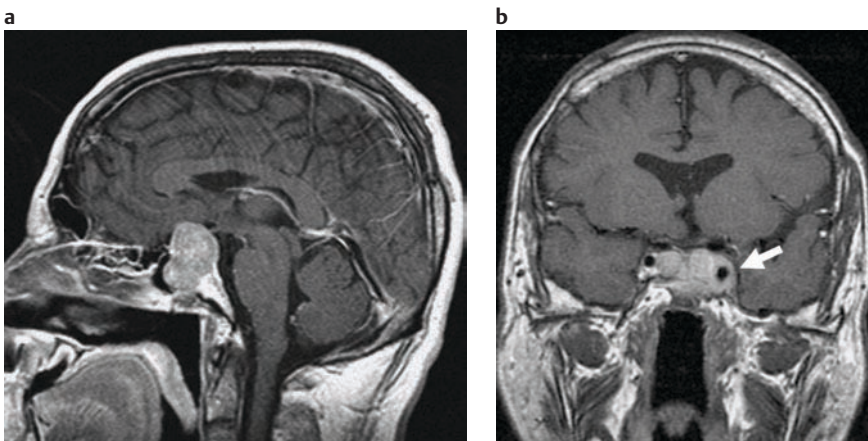


Fig. 11.32 **a** Sagittal MRI after contrast administration displays an intensely and homogeneously enhancing tumor that has expanded the sella and presses against the floor of the third ventricle. This is a macroadenoma of the pituitary gland. **b** The

coronal MR images document invasion of the cavernous sinus by the macroadenoma and a tumor sleeve extending around the carotid artery (arrow).



### Craniopharyngioma

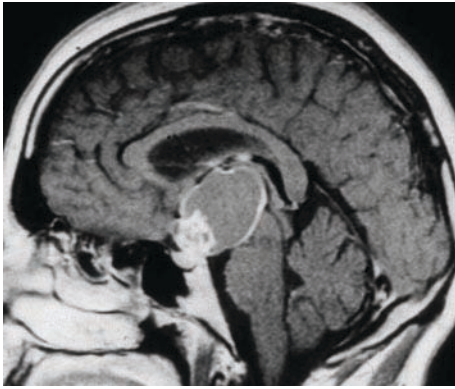


Fig. 11.33 Sagittal MRI after contrast administration shows a tumor that accumulates contrast intensely in its periphery while its center appears to be cystic. The tumor has invaded the third ventricle. This is a craniopharyngioma.

chordomas of the clivus (Fig. 11.34b) or epidermoids (Fig. 11.34c) can also lead to compressive symptoms in the perisellar area.

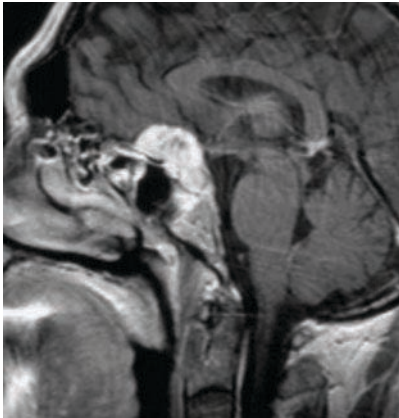
**Giant aneurysm:** A giant aneurysm can originate anywhere in the circle of Willis and extend cranially, occasionally causing a compression of sellar and/or perisellar components (Fig. 11.35).

**“Empty sella”:** The term “empty sella” designates a CSF-filled herniation of the meninges into the sella (Fig. 11.36) that can compress, for example, the pituitary gland. A similar situation (and image appearance) may of course develop after sellar surgery.

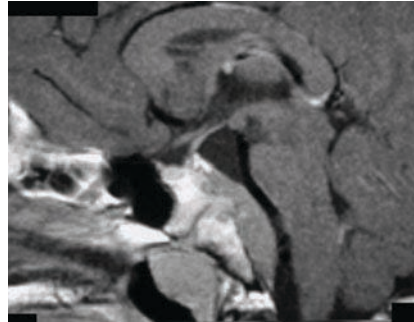
→ **Diagnosis:** Paul puts two and two together. Mrs. Nuremberg is young and denies any endocrine symptoms. The lesion is primarily cystic and sits in the right location: this should be a craniopharyngioma. Paul is right. The visual field defect is associated with this tumor and its particular location characteristically is a bitemporal hemianopia. In

### Other Perisellar Tumors

#### a Skull base metastasis



#### b Chordoma of the clivus



#### c Epidermoid

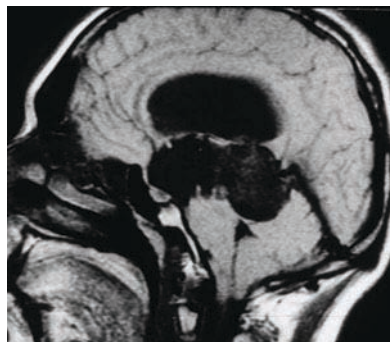
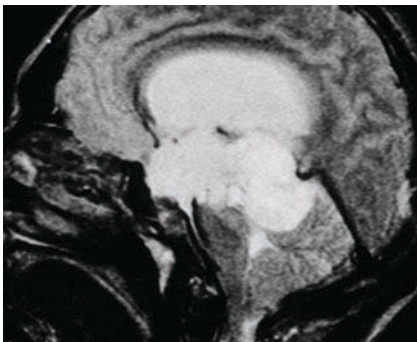
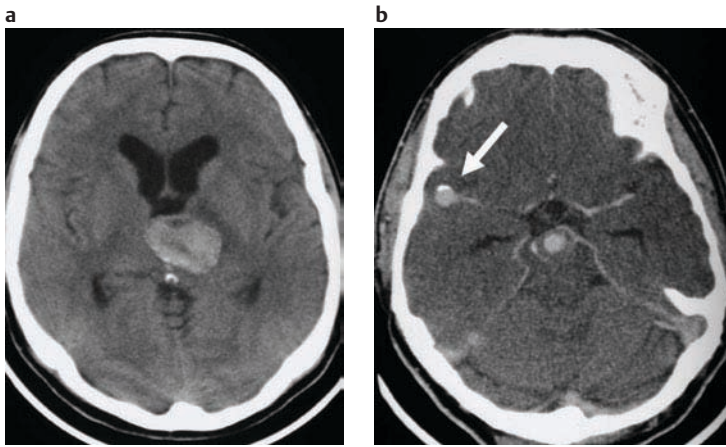


Fig. 11.34 **a** This metastasis from breast cancer is located just anterior to the pituitary. Differentiation from a primary pituitary adenoma is impossible on the basis of imaging alone. Clinical findings and the patient history need to be considered. **b** The clivus just posterior to the sella is expanded and surrounded by a sleeve of strongly enhancing soft tissue. This is

a typical chordoma of the clivus. **c** The cystic epidermoid contains fluid rich in cholesterol that has signal characteristics of CSF on T2-weighted (right) and T1-weighted (left) MR images. This epidermoid has completely obliterated the third ventricle and impinges on the pituitary from a posterior superior direction.

### Giant Aneurysm



**Fig. 11.35 a** A rounded mass that appears very dense on plain CT impinges upon the third ventricle. **b** Contrast-enhanced CT at a lower level demonstrates not only the lumen of the partially thrombosed giant aneurysm but also an additional aneurysm of the right middle cerebral artery (arrow).

hindsight the accident now also appears in a different light: Mrs. Nuremberg had overlooked a car that came from a side where her visual field is indeed impaired. This is little comfort for the young woman, who now faces cranial surgery. Preoperatively the neurosurgeons want to know about possible invasion of the tumor into the cavernous sinus and get a good idea of the anatomical configuration of this patients' sphenoid sinus, because that is the most practical way to approach and resect the tumor.

### Tumors of the Cerebellopontine Angle

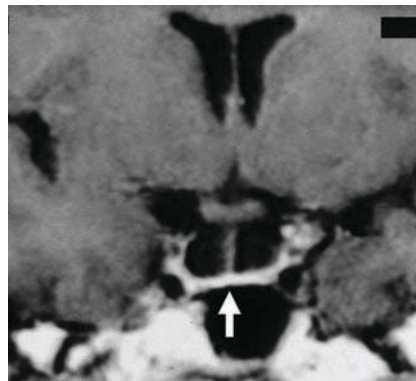
#### Checklist: Tumors of the Cerebellopontine Angle

- Does the mass center within or outside of the porus acusticus?
- Is it cystic or solid?
- Does it merely expand or destroy the bone?

#### One Ear is Giving Up on Me

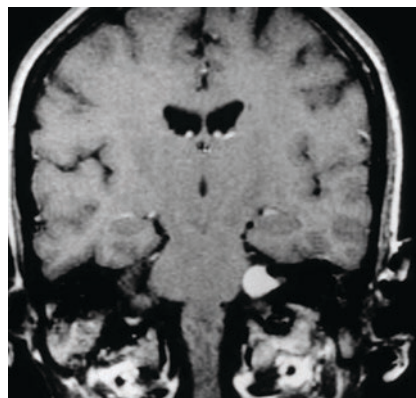
Danny Hardware's (54) right ear has been deaf for quite some time. Since he works a pretty noisy steel grinder during the day and likes to spend his evenings playing the drums in his old rock band, he is not really bothered by it. But last week, to his embarrassment, he fell off the stage because of ever increasing dizziness. Now he has had it. The dizziness nags him day and night. A dedicated study of the cerebellopontine angle is performed (Fig. 11.37). Pierre, the new third-year student doing a radiology elective, is at Paul's side today. He grabs the images and whips them up on the viewbox before Paul can get going himself. Paul adapts to the situation: "Well now, Pierre, whaddayathink?"

### "Empty Sella"



**Fig. 11.36** Coronal MRI after contrast administration illustrates the fine median pituitary stalk and the pituitary gland severely compressed by downward herniation of the meninges (arrow).

### The Case of Danny Hardware



**Fig. 11.37** Here you see the relevant coronal MRI of Danny Hardware's head. Analyze the image. Can you make the diagnosis already?

## Acoustic Schwannoma

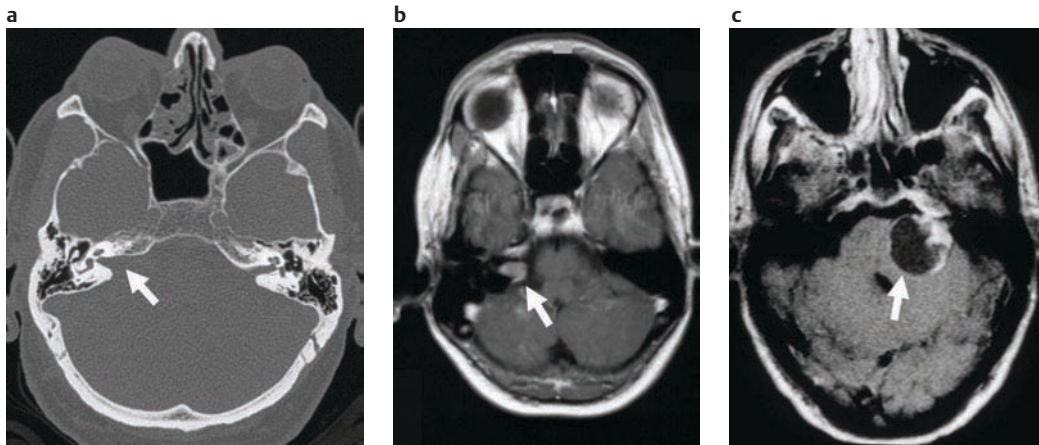


Fig. 11.38 **a** High-resolution CT of the internal acoustic meatus reveals a funnel-shaped expansion of the right meatus (arrow). **b** The axial T1-weighted MRI after contrast administration documents a small but strongly enhancing tumor at the entry

of the internal acoustic meatus (arrow). **c** In another patient, the acoustic schwannoma is a lot larger and partially cystic (arrow).

### → What is Your Diagnosis?

**Acoustic schwannoma:** The acoustic schwannoma is basically a nerve sheath tumor of the vestibular component of the vestibuloacoustic nerve. It becomes symptomatic with loss of hearing and tinnitus and is also associated with neurofibromatosis type 2. The internal porus acusticus can be expanded over time by the mass (Fig. 11.38a). In MRI the intense contrast enhancement of the tumor is very well appreciated (Fig. 11.38b). Frequently, cystic components are also observed (Fig. 11.38c). Angiographically an acoustic schwannoma usually remains invisible.

**Meningioma (see p. 241):** This tumor frequently arises from the skull base (Fig. 11.39). It does not expand the acoustic porus and appears very vascular on catheter-based angiography.

**Glomus jugulare tumor:** The glomus jugulare tumor arises from the paraganglionic tissue around the skull base and may erode the tip of the petrous bone (Fig. 11.40a, b). Patients tend to hear a systolic murmur because the tumor is very vascular. The therapy of choice is neurosurgical, but preoperative embolization is often requested to limit intraoperative blood loss (Fig. 11.40c, d).

→ **Diagnosis:** Pierre is fired with ambition. Frantically he leafs through the large book on neuro-MRI that he has found in one of the drawers. After a few minutes he looks up: “Textbook example of an acoustic schwannoma!” he declares triumphantly with his elegant French accent. “Right you are,” growls Paul. Gregory stops by on his way to the neurointerventional suite: “Hey, a typical janitor’s lesion!” Pierre is puzzled and for an explanation turns to Paul, who gives him a secretive glance: “Gregory thinks that this a lesion so easy to see that even the cleaning lady can diagnose it. ‘Janitor’ means ‘concierge,’ Pierre. Gregory

picked that up when he was in New England for, oh let’s see, Greg, was it three or four weeks that you ‘worked’ in Boston?” he asks Gregory slyly. Greg ignores Paul and hurries on to his original destination. Pierre hasn’t lost the big grin on his face: “A ‘istological diagnosis is a ‘istological diagnosis,” he says, unperturbed.

! B.i.Bs—people who have “Been in Boston”—are quite frequent in academic institutions around the world: some of them identify themselves to their peers by wearing bowties. If you want to please them, ask them about the “when,” the “where,” the “with whom.” Remain wry when inquiring about the “how long” as it touches the private sphere in some. The question “what really came out of it” should be reserved for folks with stable friendships.

### Meningioma of the Cerebellopontine Angle

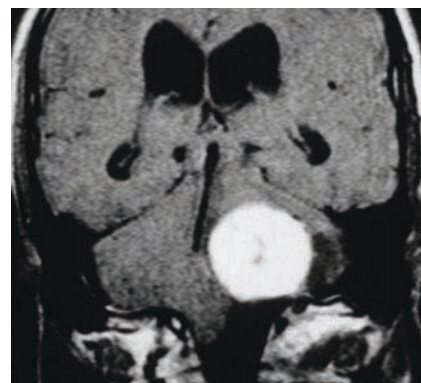


Fig. 11.39 This large tumor considerably enhances with contrast. It does not reach the internal acoustic meatus, in contrast to the typical acoustic schwannoma. This turned out to be a meningioma of the cerebellopontine angle.



### Glomus Jugulare Tumor

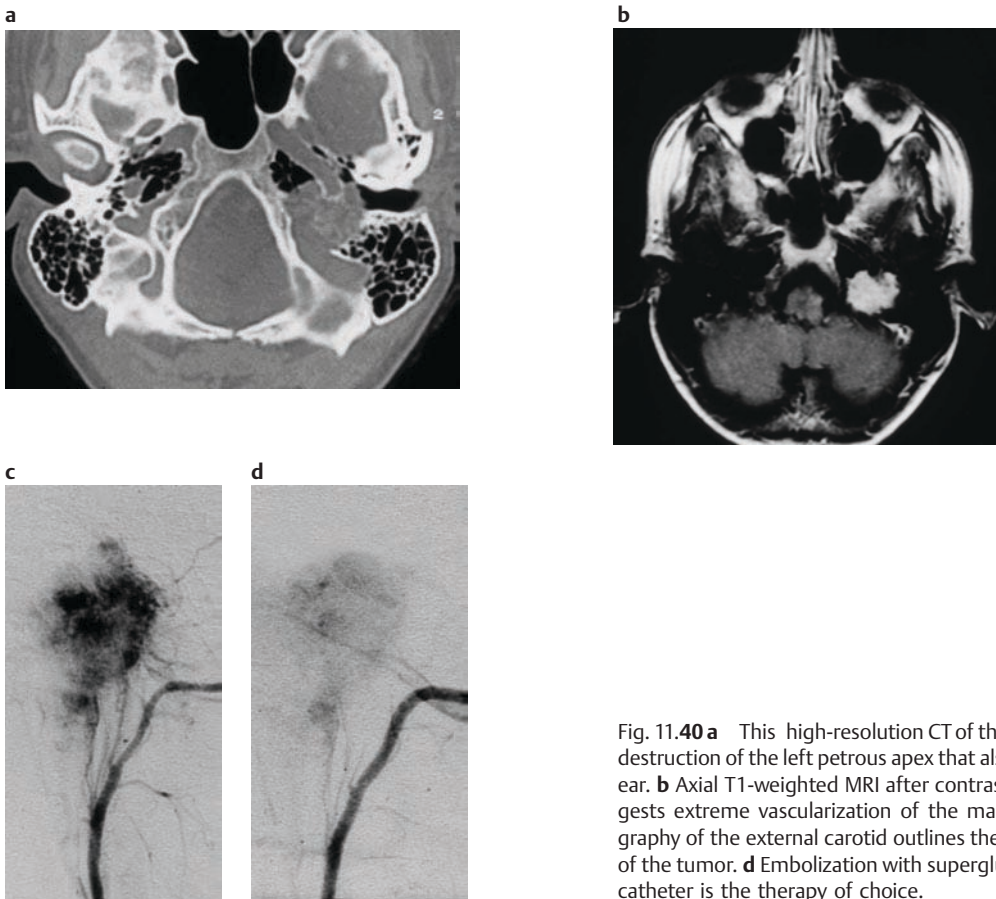


Fig. 11.40 **a** This high-resolution CT of the petrous bone shows destruction of the left petrous apex that also involves the middle ear. **b** Axial T1-weighted MRI after contrast administration suggests extreme vascularization of the mass. **c** Selective angiography of the external carotid outlines the main feeding vessels of the tumor. **d** Embolization with superglue via a coaxial microcatheter is the therapy of choice.

## 11.4 Neurodegenerative Diseases

### Checklist: Brain Volume Change

- How old is the patient? How wide are the CSF spaces normally at that age?
- Is the parenchymal volume change regional or generalized?

#### *In case of volume loss of the brain*

- Is there known clinical dementia, or drug or alcohol abuse?
- Is there any evidence for prior infarcts? History of arterial hypertension?
- Is the white-matter signal or structure altered? Are the ventricles dilated?

#### *In case of volume increase of the brain*

- Has there been an acute injury (trauma, anoxia)?
- Is the gray-white matter differentiation normal?
- Are the ventricles dilated or compressed?
- Are the external CSF spaces obliterated?

### My Wife Doesn't Know Me Anymore

Charlotte Braggbag (62) was quite a well-known personality in her neighborhood, generously sharing her opinion about absolutely everything with all those who cared to listen and those who did not. Her husband could live with it. For a few months now she has not really had an opinion about anything. Her husband could have lived with that as well. But when she looked at him mistrustfully a week ago, and asked him who he was and what he was doing in her apartment, he decided to seek help. Eventually the two ended up at the neurologist. Now they sit side by side in the CT waiting area. Giufeng and Paul are mulling over the study (Fig. 11.41), a few images of which had to be repeated because the patient would not lie still for any length of time.

### The Case of Charlotte Braggbag

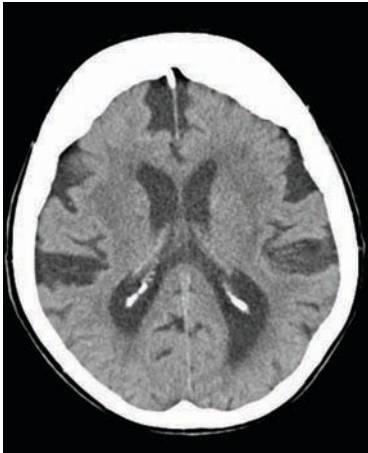

Fig. 11.41 This representative CT image of Mrs. Braggbag was selected for your analysis. What do you see?

### → What is Your Diagnosis?

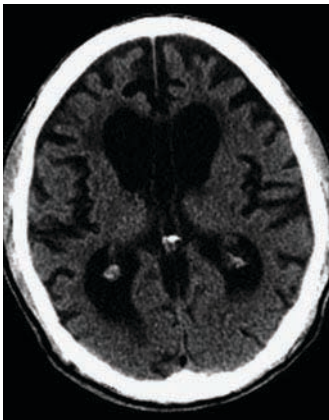
**Dementia of the Alzheimer type:** Alzheimer dementia is the most frequent of the dementias. Morphologically it is characterized by global brain atrophy—that is, irreversible shrinkage of the brain and resulting dilatation of the inner and outer CSF spaces (Fig. 11.42a).

**Pick disease:** This entity is also associated with dementia and is caused by a pronounced atrophy of the frontal brain (Fig. 11.42b).

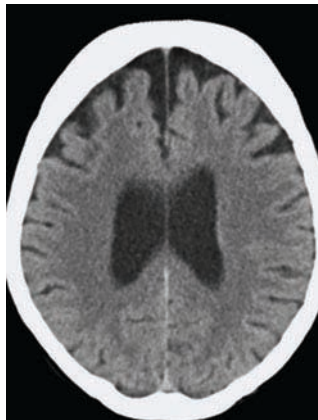
**Binswanger disease:** This form of a dementia is caused by a subcortical arteriosclerotic encephalopathy (SAE or Binswanger encephalopathy; Fig. 11.42c), which tends to develop on the basis of chronic arterial hypertension. Characteristic findings on CT and MRI include degenerative changes in the periventricular white matter and lacunar infarcts in the basal ganglia. Often there is associated ex vacuo dilatation of the ventricles.

### Degenerative Brain Disease

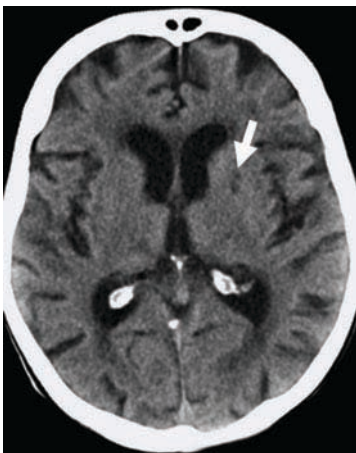
a Dementia of the Alzheimer type



b Pick disease



c Binswanger disease



d Normal-pressure hydrocephalus

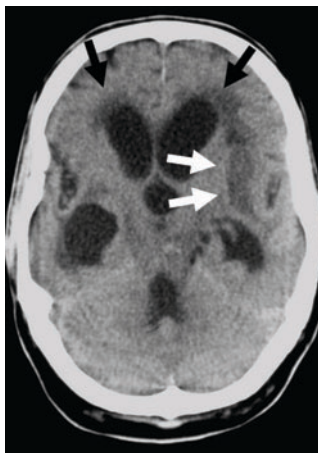
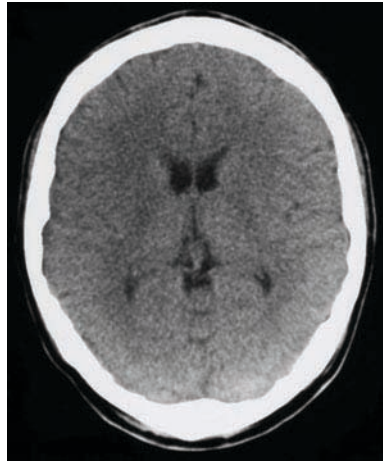
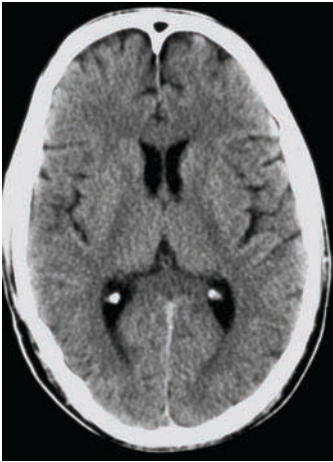


Fig. 11.42 a Inner and outer CSF spaces are much too wide for the age of this patient (65) and indicate generalized atrophy of the brain as seen in Alzheimer disease. b In Pick disease, parenchymal atrophy is limited to the frontal lobe. c Inner and outer CSF spaces are wide and the periventricular parenchyma is lower than usual in density. A small lacunar infarct is seen in the left basal ganglia (arrow). This is a patient with subcortical arteriosclerotic encephalopathy (SAE or Binswanger encephalopathy). d Anterior and temporal horns of the lateral ventricles as well as the third and fourth ventricle are dilated; the outer CSF spaces are of normal caliber. Scattered periventricular hypodensities (black arrows) suggest increased ventricular pressure. There is also evidence of prior infarction in the left external capsule (white arrows). (By the way: Where is the internal capsule?)

## Loss of Brain Volume

## a HIV encephalopathy



## b Steroid-associated volume loss

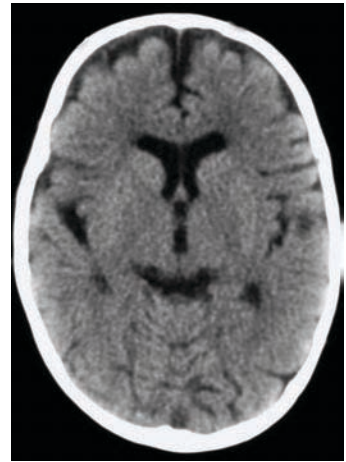


Fig. 11.43 **a** The brain volume is diffusely reduced (left) in this 45-year-old HIV patient who was becoming increasingly disoriented. On the right you see a normal age-matched CT for comparison. **b** This child is treated with high-dose steroids

after receiving a liver transplant. The brain volume is reduced significantly. CT after termination of steroid therapy in these patients shows a return to normal brain size.



### Do You Know about Alzheimer, Pick, and Binswanger?

**Alois Alzheimer** was a neurologist and psychiatrist in Wroclaw (the former Breslau) around 1900. His special field of interest was

brain pathology. He searched for the substrate of the presenile dementia that was named after him. The neurologists **Arnold Pick** and **Otto Binswanger** worked on the same topic around the same time as Alzheimer, the former in Prague and the latter in Jena. Binswanger's major contribution to medicine was his research on the microangiopathy of the brain.

**Normal-pressure hydrocephalus:** Normal-pressure hydrocephalus may also go along with dementia and can occur after meningitis or subarachnoid hemorrhage (see p. 235), and—most often—idiopathically. The inner CSF spaces are all dilated, the outer ones remain normal in caliber. Periventricular hypodensities seen on CT have been interpreted by some as a result of parenchymal stretching (Fig. 11.42d).

**Brain infarction:** Isolated brain infarction due to embolic occlusion of a small end-artery, for example, in the region of the thalamus, can also cause a clinical syndrome resembling dementia (see also p. 237).

→ **Diagnosis:** Paul thinks he is looking at an SAE; Giufeng tends toward Alzheimer. Pierre drops in and asks whether this could also be Creutzfeldt–Jakob disease. Greg arrives just in time to keep Pierre from asking the unfortunate Mr. Braggbag about any beef consumption. “The poor man has got enough to worry about as it is. Leave him alone, please. Creutzfeldt–Jakob is incredibly rare! The atrophy is obvious. The most likely diagnosis is Alzheimer.” Gregory

sinks into a chair and grabs the cup of coffee that Giufeng has just brought along for Paul. “Brain volume loss is a tricky thing,” he starts to lecture. “It doesn't always go along with dementia. Always keep the age of the patient in mind. Then look at the social background. Wanna know a secret? But don't tell anyone I told you: Check the dental status on the CT scout image for information about past oral hygiene—that will tell you a little about what type of patient you are dealing with. Alcohol- and/or drug-induced atrophy we see by the dozen in this hospital. The same is true for HIV encephalopathy, which can

## Increase of Brain Volume

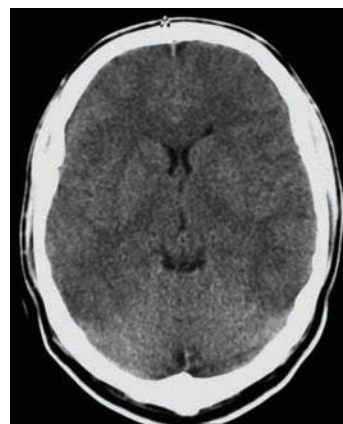


Fig. 11.44 Generalized brain edema is present after an overdose of the drug ecstasy. The widths of inner and outer CSF spaces in this 23-year-old addict are significantly reduced.



also lead to atrophy [Fig. 11.43a]. But dehydration or therapy with high-dose steroids [Fig. 11.43b] also causes a loss of brain volume. You go ahead and diagnose brain atrophy in a patient on steroids and check the neurologist's reaction when the brain volume returns to normal a few days after discontinuation of the medication: They'll laugh their heads off and you're the one they will laugh about! Happened to me once, as a matter of fact." Giufeng and Paul prick up their ears, Pierre looks bewildered. "It was early in the training, of course!" Greg adds hastily. "And then there is the other extreme—much more dangerous and relevant in acute care: the increase in brain volume. You can get a generalized brain edema from a drug overdose (Fig. 11.44) or after a prolonged anoxia."

**!** Brain volume can change. Genuine brain atrophy, however, is irreversible. Generalized brain edema may be fatal.

## 11.5 Congenital Disorders of the Brain

### Checklist: Congenital Malformations of the Brain

- Are the ventricles normally configured?
- Is the corpus callosum present?
- Are there islands of gray matter visible within the white matter (heterotopia)?
- Is the posterior fossa configured normally?
- Is the gyration normal?

### Something is Wrong with This Child

Jimmy Slowly (4) has been brought to the hospital by his parents. He somehow cannot compete with his peers in nursery school. The pediatrician has also found a serious developmental deficit. The MRI study is performed under general anesthesia because little Jimmy naturally cannot keep still that long. Giufeng and Paul have been held up by another case and are quite relieved to see Gregory already busy staring at the console. After analyzing the study, he keeps the two in the dark for a while (Fig. 11.45).

### → What is Your Diagnosis?

**Meningocele:** The embryological development of the neural axis is rather complex, hence congenital disorders are not uncommon. A meningocele is an outpouching of the meninges, mostly dorsally (Fig. 11.46a). If it also contains brain parenchyma, it is called a *myelomeningocele*.

**Dandy-Walker complex:** In Dandy-Walker complex, aplasia of the cerebellar vermis goes along with cystic dilatation of the fourth ventricle (Fig. 11.46b). The posterior fossa is enlarged, the tentorium is raised. Resulting compromised CSF flow is frequently associated with hydrocephalus.

**Arnold-Chiari malformations:** The Arnold-Chiari I malformation is a complex group of malformations characterized by the downward displacement of the cerebellar tonsils and the medulla oblongata into the cervical spinal canal (Fig. 11.46c). Arnold-Chiari II malformations are more complex and include spinal dysraphism and meningoceles or myelomeningoceles.

### The Case of Jimmy Slowly

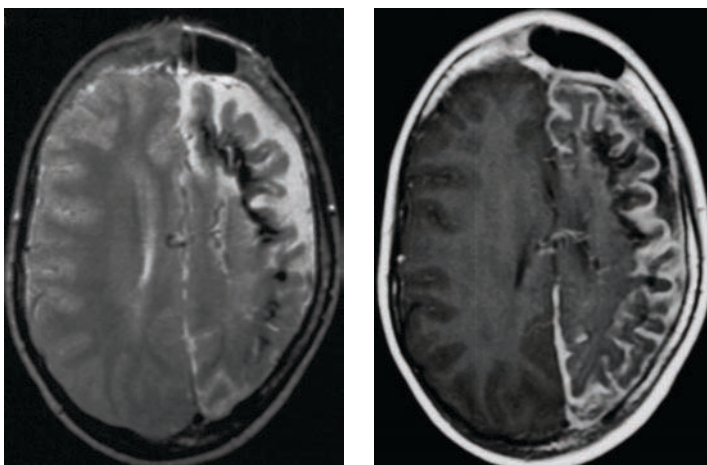
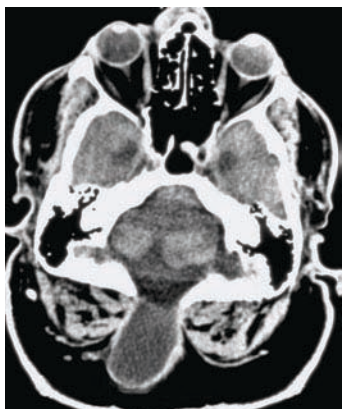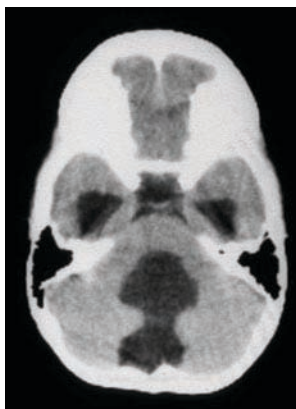
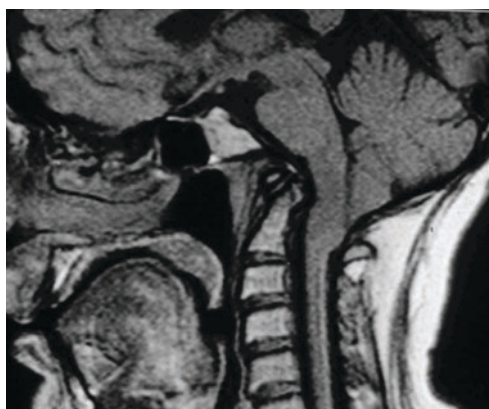
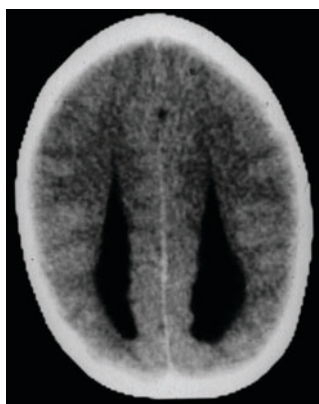
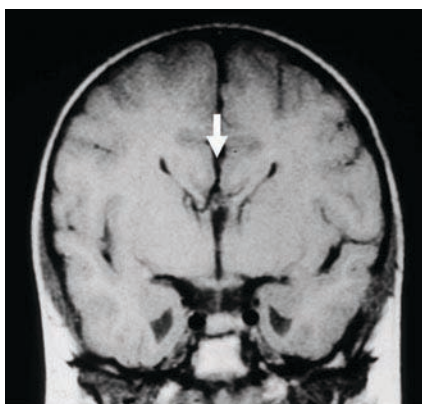
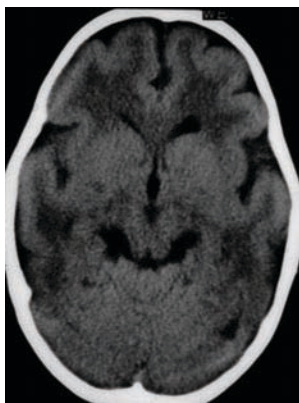
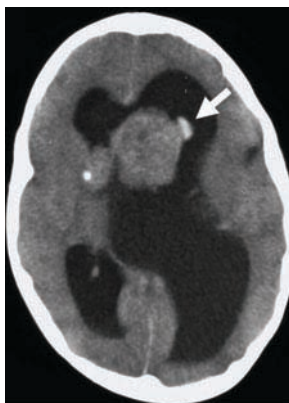
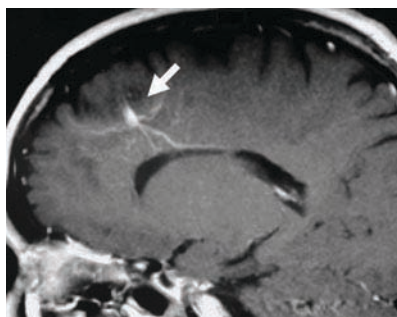


Fig. 11.45 Can you determine Jimmy's histological diagnosis on the basis of these representative images?

## Congenital Malformations of the Brain

**a Meningocele****b Dandy–Walker complex****c Arnold–Chiari malformation****d Agenesis of the corpus callosum****e Pachygyria****f Tuberos sclerosis****g Venous angioma**

**Fig. 11.46 a** This meningocele presents itself as a dorsal out-pouching of the dura through an osseous defect. The dural pouch is filled with CSF. **b** On this axial CT image the vermis is missing, the fourth ventricle is enlarged, and the temporal horns are dilated considerably, indicative of hydrocephalus. This is a patient with Dandy–Walker complex. **c** Descent of cerebellum and brainstem into the spinal canal is characteristic of the Arnold–Chiari malformation. There is also an associated malformation of the osseous craniocervical junction zone. **d** The corpus callosum is missing completely (arrow, left image) on this coronal MR image (compare the normal anatomy in Fig. 11.32b). Agenesis of the corpus callosum leads to a club-shaped dilata-

tion of the posterior horns of the lateral ventricles (right image). **e** This 1-year-old, severely retarded child has extremely thickened and coarse-appearing gyri. This configuration is termed pachygyria. Compare to the normal gyri in Fig. 11.1a. The child also suffered from corpus callosum agenesis that caused the club-shaped dilatation of the posterior horns. **f** Tuberos sclerosis is characterized by the formation of tubers (nodules) alongside the ventricular wall (subependymally), which may calcify (arrow). **g** This median sagittal MR image, which was obtained after contrast administration, displays an atypically thick centripetal vein (arrow). This is a textbook case of a venous angioma. ▶

## Congenital Malformations of the Brain

### h Sturge–Weber syndrome

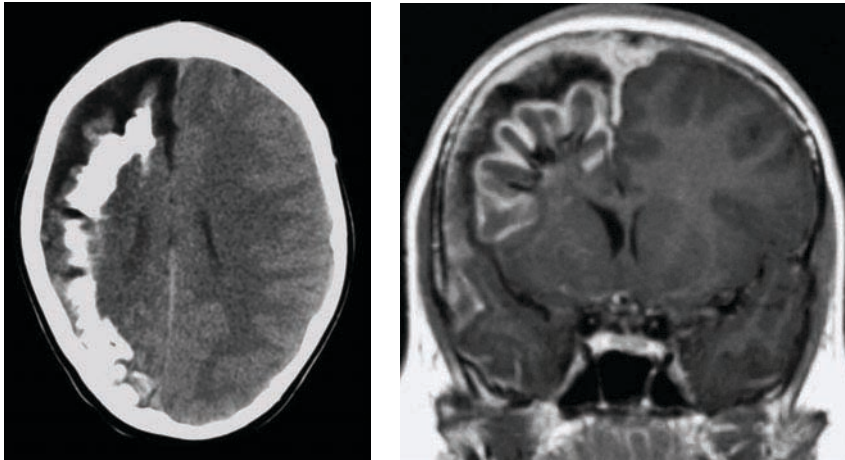


Fig. 11.46h In this patient with a Sturge–Weber angiomas, the cranial CT reveals extensive calcification of the gray–white matter junctional zone (left), which can sometimes even be appreciated on plain radiography of the skull. The angiomatous

region accumulates contrast avidly, as seen on this coronal MR image after gadolinium administration (right). The calcified portion appears as a signal void.



#### Who Are the Persons behind These Names?

**Walter E. Dandy** was a neurosurgeon in Baltimore in the first half of the 20th century. He was an assistant to Harvey Williams

Cushing and the first to develop a method to look inside the living brain: pneumoencephalography. **Arthur E. Walker** was a younger colleague of his.

**Julius Arnold** and **Hans Chiari** were pathologists in the late 19th century, the former in Heidelberg, the latter first in Prague and then in Strasbourg.

**Anomalies of the corpus callosum:** Agenesis of the corpus callosum is often associated with other complex brain malformations (Fig. 11.46d, e). It can be complete or partial.

**Pachygyria:** Disturbed migration of the neuronal cells during the embryonal period can interfere with the orderly formation of the brain cortex. This is the case, for example, in pachygyria (Fig. 11.46e) where the cortical gyri are thickened and abnormally smooth.

**Tuberous sclerosis:** This inherited autosomal-dominant disease is associated with intellectual retardation and a facial skin efflorescence called adenoma sebaceum. Subependymal hamartomas are found in the brain parenchyma, which typically calcify partially (Fig. 11.46f).

#### Angioma:

**Venous angioma:** A venous angioma represents an abnormally prominent vein draining normal functional brain tissue and is not normally associated with any other developmental deficits or symptoms. As a rule these lesions are

normal variants without any therapeutic relevance (Fig. 11.46g) but they must not be mistaken for an arteriovenous malformation of the brain because their removal leads to venous infarction of the parenchyma drained by this vessel.

**Arteriovenous angioma:** For details on this entity see above (p. 249).

**Sturge–Weber syndrome:** This autosomal congenital dominant disease may also occur de novo. Patients may have a cutaneous vascular nevus (“port wine stain”), seen usually along the distribution of the trigeminal nerve, and are mentally retarded. CT or MRI demonstrates an ipsilateral angioma in the parieto–occipital region, which is regularly calcified. The hemisphere is atrophic at the same time (Fig. 11.46h).

→ **Diagnosis:** Giufeng and Paul are absolutely convinced that this is a case of Sturge–Weber syndrome. Gregory gives them a big smile: “That is what the anesthesiologist said half an hour ago. Had you been here earlier and looked at the little boy before the study you would have noticed the port wine stain in his face. It is a nice case for us—unfortunately not so for the boy and his parents.”

! Congenital brain malformations can be very complex. These patients belong in experienced neuropediatric centers where sound genetic counseling is also available.



## 11.6 Spinal Cord Tumors

### Checklist: Spinal Cord Tumors

- Is there paraparesis?
- Is the spinal cord of normal caliber and of normal signal on T2-weighted images?
- Is the spinal canal of normal caliber?

#### If masses are present in the spinal canal

- Is the mass intradural or extradural, intramedullary or extramedullary?
- Is it solid, cystic?
- Is there evidence for peripheral enhancement?
- Radicular symptoms
- Is there any malalignment of the spinal column?
- How wide is the osseous spinal canal? How wide are the intervertebral foramina?
- How extensive is the degeneration of the intervertebral disks, the intervertebral, uncovertebral, and facet joints?

### When Both Legs Fail

Ann Ray (45) is brought to the MRI unit on a Sunday afternoon on a stretcher. During the past week she has felt an increasing lower limb weakness. This weekend her legs quit on her altogether. Her desperate husband and the two adolescent kids had called the on-call general practitioner, who immediately had her transferred to the hospital. The neurologist on duty diagnosed an acute paraplegia and asked for an immediate MRI (Fig. 11.47). Giufeng and Paul know that this is a classic indication for an emergency MRI—day or night. After the obligatory sagittal scans of the whole lumbar spine, the suspicious area is also examined with axial scans.

### The Case of Ann Ray

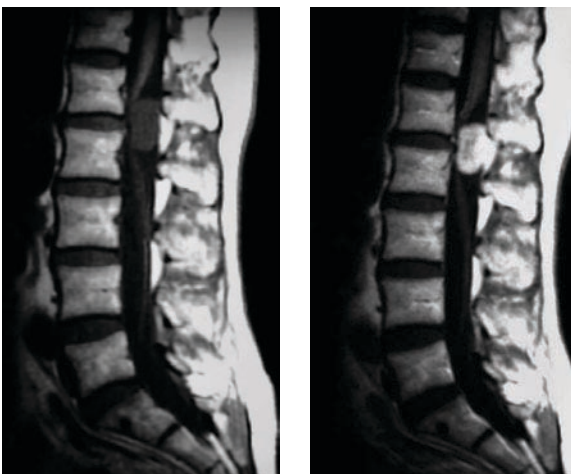


Fig. 11.47 Take a look at these representative MR images of Ann Ray. Do you have a suspicion what this could be?

### → What is Your Diagnosis?

**Massive intervertebral disk prolapse:** Massive prolapse of a disk can lead to acute paraplegia (Fig. 11.48).

**Extradural spinal tumor:** Typical extradural spinal tumors are multiple myeloma (Fig. 11.49a) and lymphoma. Masses originating in parenchymal organs may also invade the spinal canal by direct extension (Fig. 11.49b).

#### Intradural spinal tumor:

**Intradural extramedullary spinal tumor:** The most frequent intradural extramedullary spinal solid tumor is the spinal meningioma. It is a slow-growing tumor that may also expand the spinal canal (Fig. 11.50a; see also p. 241). Metastases—often spread via the CSF—also settle in the thecal sac (Fig. 11.50b). They are a feared complication, particularly in pediatric tumors of the posterior fossa.

**Intramedullary spinal tumor:** Intramedullary spinal masses tend to be primary CNS-type tumors such as astrocytomas and ependymomas. Metastases are also seen (Fig. 11.50c).

**Spondylodiskitis:** Bacterial spondylodiskitis may be associated with an epidural abscess and can impinge on the thecal sac, resulting in acute paraplegia (see Fig. 8.41, p. 143). The involvement of the intervertebral space is characteristic, with a loss of diskal height, loss of vertebral end plate distinction, and strong accumulation of contrast in the periphery of the disk.

**Spinal trauma and preexisting spinal canal stenosis:** In a stenotic spinal canal even minor trauma may induce major cord damage. This can be due to sudden compression of the whole myelon (Fig. 11.51a) or the focal compression of the anterior spinal artery (Fig. 11.51b).

### Intervertebral Disk Prolapse

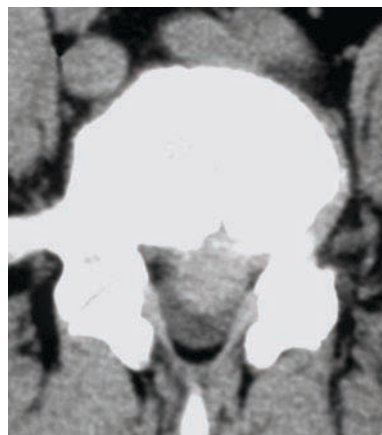
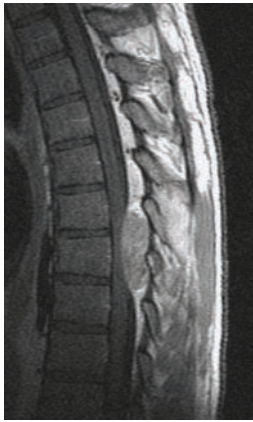

Fig. 11.48 The CT section obtained parallel to the vertebral end plates shows severe compression of the thecal sac by soft tissue isodense to intervertebral disk substance. This is a massively prolapsed disk.

### Extradural Spinal Tumor

**a Plasmacytoma**



**b Pancoast tumor**

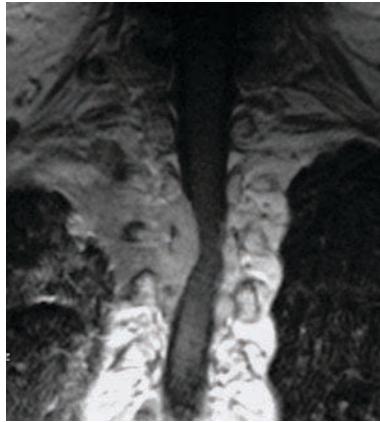


Fig. 11.49 **a** The spinal cord on this sagittal T1-weighted contrast-enhanced MR image is compressed considerably by the soft tissue component of a plasmacytoma. Plasmacytoma frequently causes destruction of the cancellous and cortical bone. **b** The coronary T1-weighted MRI section after contrast administration reveals a Pancoast tumor, a mass originating in the pulmonary apex that may invade the spinal canal through the neuroforamina and subsequently may cause spinal cord compression. Cranially it involves the brachial plexus and can present with Horner syndrome.

### Intradural Spinal Tumor

**a Spinal meningioma**

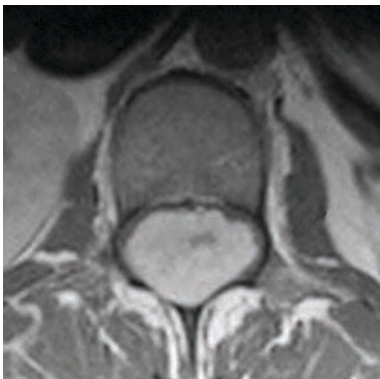
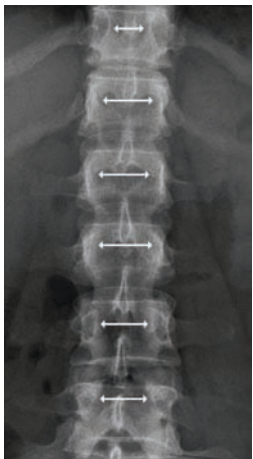
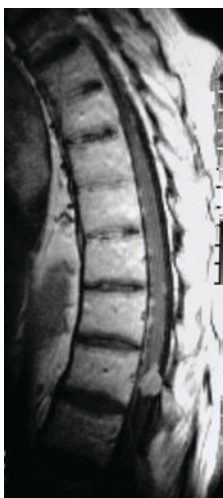
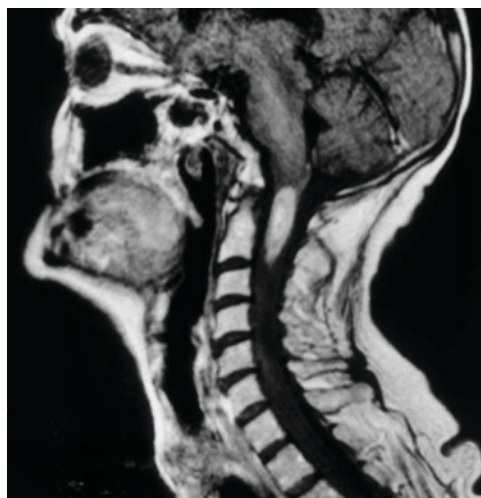Fig. 11.50 **a** This spinal meningioma is even detectable on the lumbar radiograph (left) because its slow growth has forced the pedicles apart (arrows). The axial T1-weighted MR image obtained after contrast administration (right) displays the avidly enhancing tumor, which has expanded the spinal canal. **b** A number of smaller and one larger metastases of an esophageal carcinoma are seen here studding the spinal cord. The primary tumor has directly invaded the spinal canal at a higher level. **c** After contrast administration, the intra-axial spinal metastasis of a breast carcinoma is very well appreciated.

**b Thecal metastatic disease**



**c Metastatic disease involving the spinal cord**



## Spinal Column Trauma in Spinal Canal Stenosis

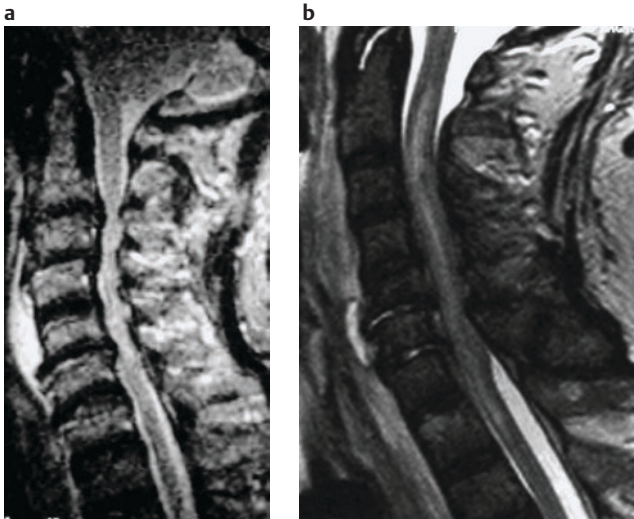


Fig. 11.51 **a** The spinal canal of this patient is extremely narrow secondarily to severe degenerative changes of the cervical spine with associated malalignment. Additional minor trauma was sufficient to induce a severe spinal cord injury with transverse paralysis. **b** In another patient who sustained minor trauma, signal changes can be seen in the spinal cord extending inferior to the level of the preexisting spinal canal stenosis. In this case the anterior spinal artery, which provides crucial blood supply to the cervical and upper thoracic spinal cord, has been compressed. Ischemia of the spinal cord is a feared complication (anterior spinal artery syndrome).

→ **Diagnosis:** Giufeng and Paul diagnose a slow-growing and well-demarcated intradural extramedullary mass to be at the root of the problem, most likely a meningioma. That is good news for Ann Ray. The neurosurgeons resect the tumor that same day. Three weeks later she is back on her feet—in a rehabilitation clinic undergoing intensive physiotherapy.

! Acute paraplegia requires an immediate MRI and subsequent rapid therapy.

! Particularly if radicular symptoms are present, imaging findings and clinical symptoms should be seen in conjunction with the imaging findings to come to a sound and correct diagnosis. Many people have one or several herniated disks without ever developing any associated symptoms. Therefore, only the presence of both radicular symptoms and a matching positive finding in the expected corresponding anatomical location suggests a causative relationship with acceptable certainty. A radiograph of the lumbar spine should always be performed to exclude misalignments/spondylolisthesis of the spinal column.

## Tap-Dancing for Another Reason

Ted Aslair (45 years; 72 kg [158 pounds]) is accompanied by his wife Saffron (41 years; 95 kg [209 pounds]). After a long pause they have visited a refresher course to brush up on their dancing. In that last lesson they did the classic rock 'n' roll with “advanced liftwork.” Mr. Aslair’s back has not really been up to that exercise. In fact it has been acting up now and then for quite a while. Three days later he finds that apart from the pain he endures he cannot raise his right foot tip anymore. At first glance his wife congratulates him for finally having understood this special step they need to do the Rumba but eventually it becomes clear: Aslair has a serious neurological problem—a foot drop. Gregory is all on his own today in the neuro-imaging unit and has a good look at the images (Fig. 11.52).

## → What is Your Diagnosis?

**Disk prolapse:** Intervertebral disk herniation is the most frequent cause of radicular neurological symptoms. In prolapse the nucleus pulposus substance perforates the annulus fibrosus and the dorsal spinous ligament and compresses one or several spinal nerve roots (Fig. 11.53a–d).

## The Case of Ted Aslair

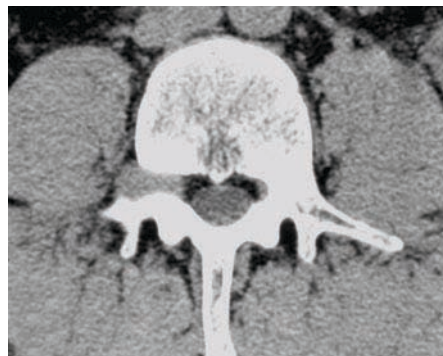

Fig. 11.52 This is a representative CT image of Ted Aslair. What finding catches your attention?



### Prolapsed Intervertebral Disk

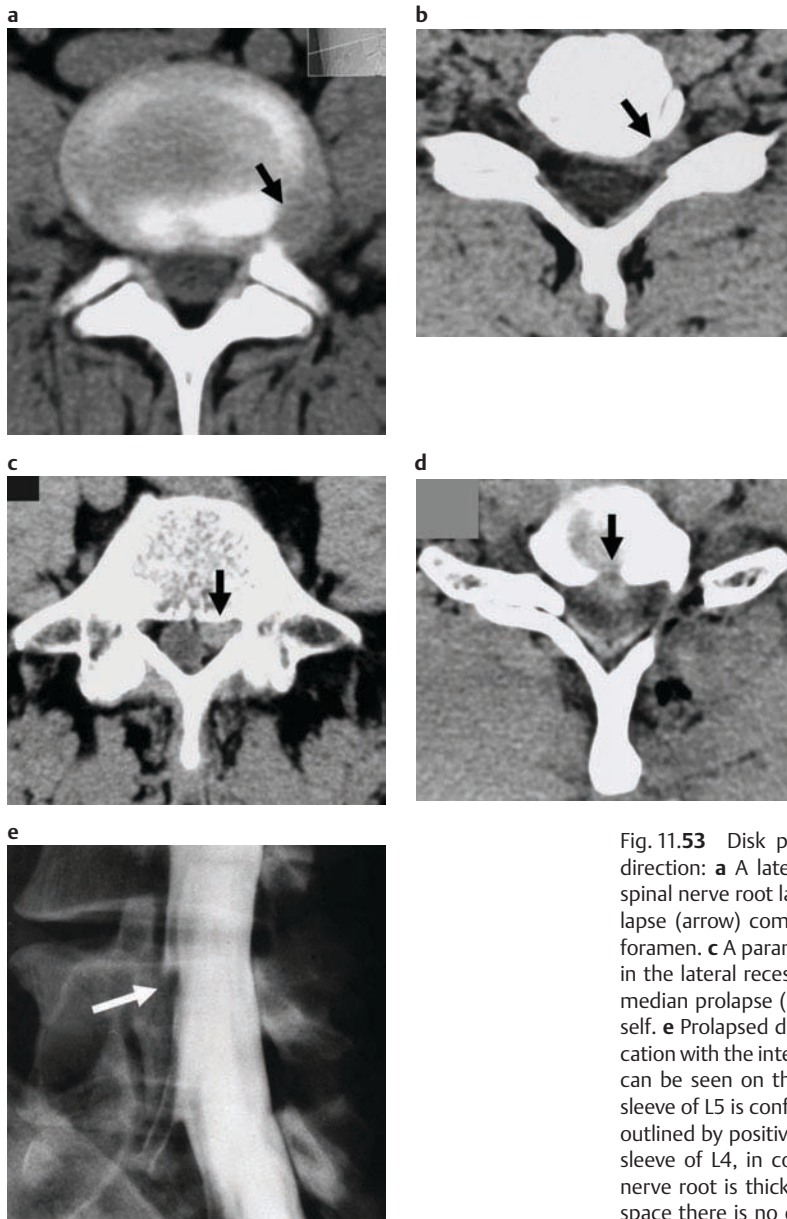


Fig. 11.53 Disk prolapses are classified according to location/direction: **a** A lateral prolapse (arrow) can impinge upon the spinal nerve root lateral to the neuroforamen. **b** Foraminal prolapse (arrow) compresses the spinal nerve directly within the foramen. **c** A paramedian prolapse (arrow) is frequently located in the lateral recess, where it impinges upon the nerve. **d** The median prolapse (arrow) tends to compress the spinal cord itself. **e** Prolapsed diskal tissue in this case has lost its communication with the intervertebral space above (sequester; arrow), as can be seen on this myelographic image. The lower radicular sleeve of L5 is configured normally with a slim spinal root nicely outlined by positive intrathecal contrast. The superior radicular sleeve of L4, in contrast, appears compressed and the spinal nerve root is thickened. At the level of the intervertebral disk space there is no extrinsic impression of the thecal sac.

When diskal tissue loses its connection to the disk it originated from, this is called a sequester or fragment. Sequesters do not usually recede under conservative therapy (Fig. 11.53e) and are thus more often treated surgically.

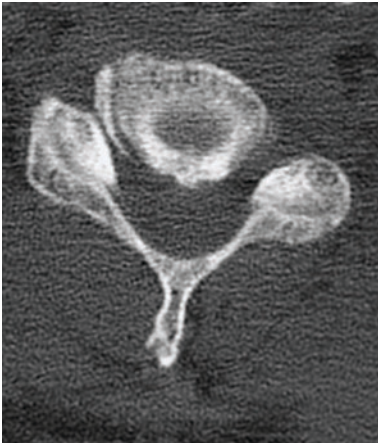
**Degenerative neuroforaminal stenosis:** In the cervical region, degenerative foraminal stenosis is primarily caused by osteoarthritic hypertrophic changes of the uncovertebral joints (Fig. 11.54a); in the lumbar region, it is caused by osteoarthritis of the facet joints (Fig. 11.54b) and by hypertrophy of the ligamentum flavum (Fig. 11.54c).

**Synovial cyst:** The synovial cyst, a diverticulum of the facet joint, can also impinge on the spinal nerve roots (Fig. 11.55). In that instance it must be excised surgically. Synovial cysts are, however, difficult for the surgeon to find because they may rupture very easily during surgical exploration. Later, the cystic space may seal itself off again during the postoperative healing, with a potential undesirable effect: cyst and symptoms recur.

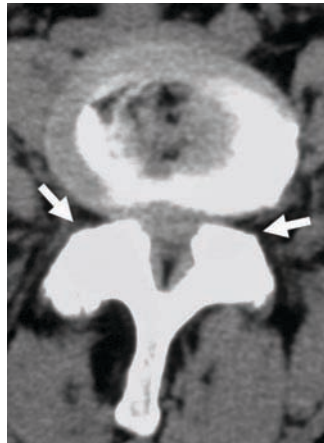**Schwannoma:** Peripheral schwannomas follow the course of the spinal nerve root through the intervertebral foramen, assuming a dumbbell shape in the process (Fig. 11.56). Intravenous contrast administration is necessary to differentiate it from a prolapsed disk.

### Degenerative Neuroforaminal Stenosis

**a** Hypertrophy of the uncovertebral joints



**b** Osteoarthritis of the intervertebral joints



**c** Hypertrophy of the ligamentum flavum

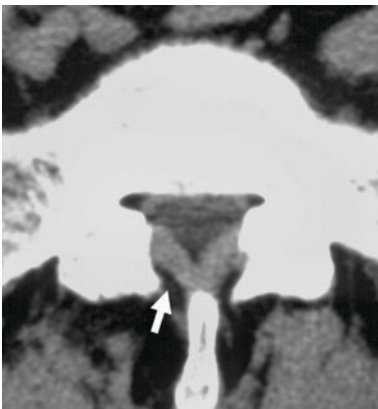


Fig. 11.54 **a** The uncovertebral joints are located directly adjacent to the cervical intervertebral neuroforamina. Hypertrophic degenerative changes in these joints may cause foraminal stenosis as seen here on the right side. **b** Expansion of the posterior facet joints (arrows) has a similar effect in the lumbar region. Hypertrophic degenerative disk disease with diskal bulging at these levels (note the vacuum phenomenon!) further aggravates the situation. **c** The frequently associated hypertrophy of the ligamentum flavum (arrow) further increases the degree of stenosis affecting the intervertebral foramen.

### Synovial Cyst

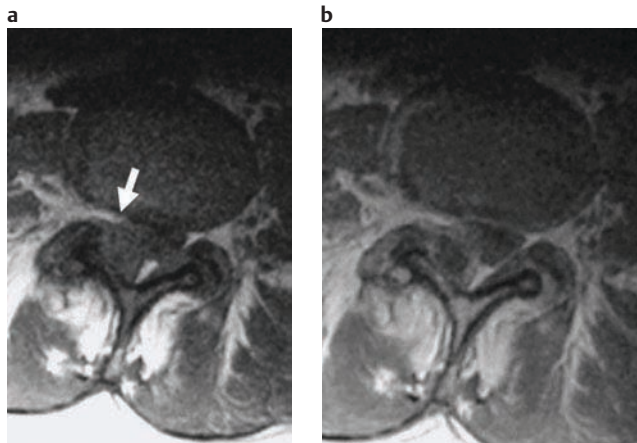


Fig. 11.55 **a** On this axial T1-weighted MR image a small mass is seen in the spinal canal directly adjacent to an intervertebral joint (arrow). **b** Only after contrast administration can the thin synovial membrane be distinguished, which clarifies the true character of the lesion.

## Schwannoma

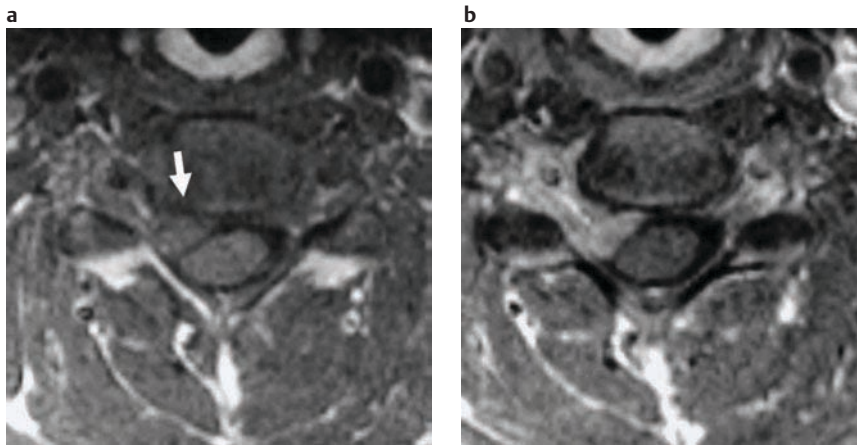


Fig. 11.56 **a** The usual axial T1-weighted MR image displays a mass (arrow) in an intervertebral foramen on the right. It is reminiscent of a dumbbell. **b** After contrast administration, the typical dumbbell configuration of the schwannoma becomes much clearer.

**Spondylolysis, degenerative or pseudospondylolisthesis, spinal canal stenosis:** Spondylolysis, degenerative or pseudospondylolisthesis, and congenital spinal canal stenosis also have to be considered in the differential diagnosis (see p. 144).

→ **Diagnosis:** Gregory has finished dictating his report and has diagnosed a foraminal disk prolapse in Aslair's case. He shows the images to Giufeng and Paul. Giufeng is amazed about the smooth and stretched configuration of the process and scratches her head: could this also be a schwannoma? Gregory has another close peek: "Holy cow, Giu, you could be right! We have to give it a contrast-enhanced run!" The following contrast study a few minutes later shows a strong enhancement of the tissue in question, confirming the diagnosis of a schwannoma. Giufeng is as proud as can be, Paul congratulates her and Gregory. . . Gregory gets this bright gleam in his eyes.

## 11.7 Gregory's Vernissage

The week in neuroradiology has been a breeze. As Greg has taken a day off to work on yet another paper, Paul hopes to get by without the usual pimping procedure. It is 5 p.m. on a Friday and he unwinds more with every minute that goes by. Giufeng, however, is a little tense and looks around nervously. A few minutes later, Greg walks through the door with a bunch of films under his arm. With a big grin he whips four test cases up on the viewbox (Fig. 11.57). "Now you didn't really think I'd let you down, Paul, did you?" he jokes benevolently. Giufeng sets herself up in front of the viewbox. "Are you coming along after this?" Greg whispers in her ear. Paul pricks up his ears: "Now what's going on, the two of you?" he asks sharply. "Ahem, well, Giufeng and I are going to a spiffy vernissage, my dear Paul!" says Greg. "Oh, dear, naïve art, I presume?" Paul fires back. Giufeng takes the sting out of the situation: "First things first, you guys. I'll start with this case and you, Paul, will do the next."



## Test Cases

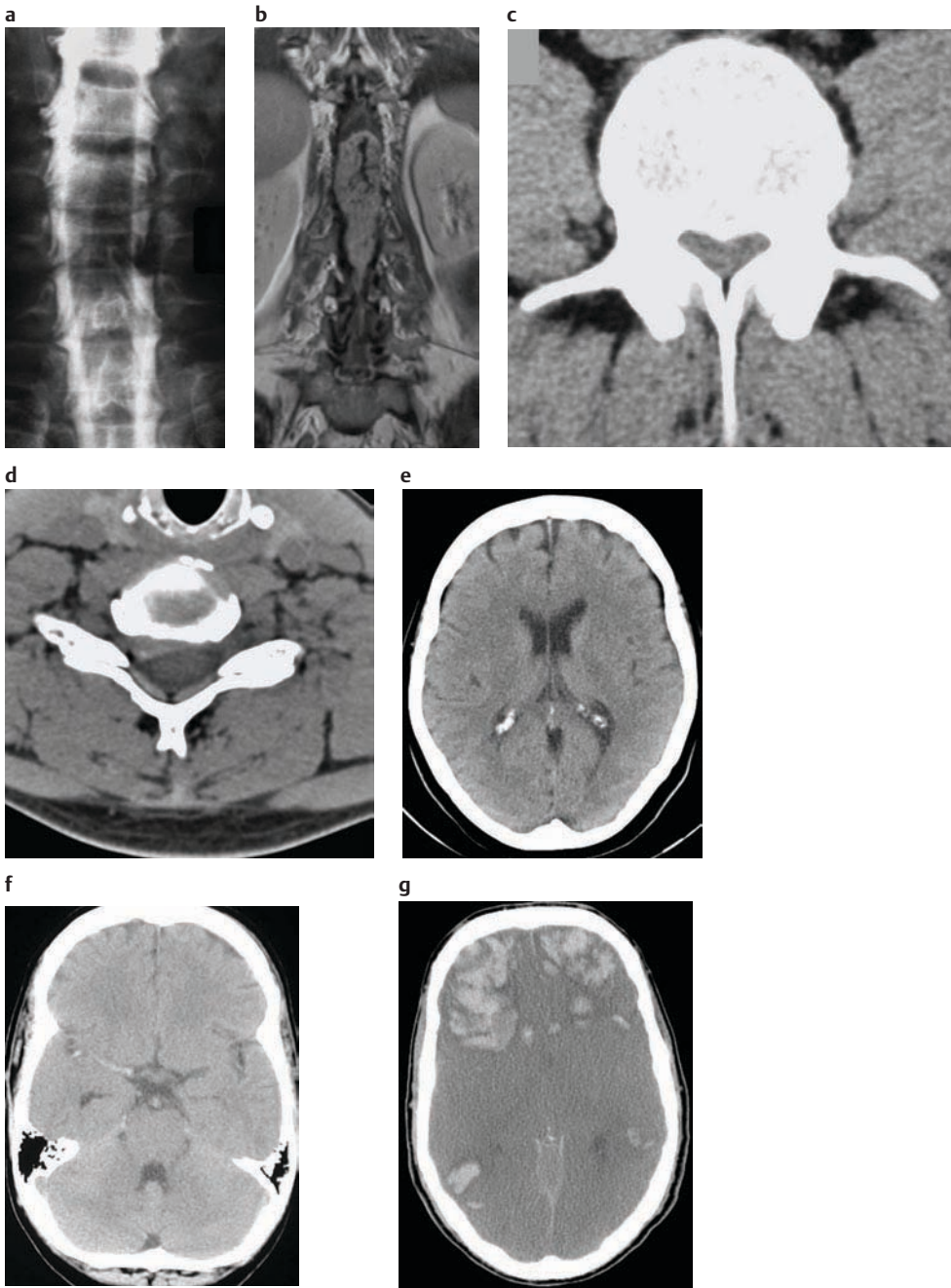
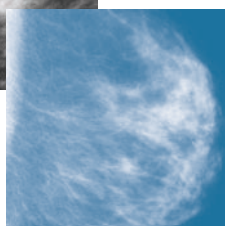


Fig. 11.57 a–g All histories are withheld.

## 12 Breast



The radiological examination of the female breast (mammography) assumes a very special status within the spectrum of all imaging modalities, for several reasons. First of all, it is a pure soft tissue examination with which ultrafine calcifications are supposed to be detected. For that reason it is performed with a much lower exposure voltage than normal in projection radiography (25–32 kVp) (see p. 34).

**!** With this technology carcinomas can be found that are only a few millimeters in size. Nowhere else in the body can current radiology hope to achieve anything like that.

Secondly, the contact between the radiologist and the patient is particularly close—something that is not the rule in other radiology subspecialties (with the exception of interventional radiology). The time of the examination is often a period of intense psychological stress for the women involved. Within a few minutes a recently palpated breast lump might turn out to be a harmless cyst

or a potentially lethal carcinoma with all its implications for the private and professional future of the patient. The resulting turmoil of emotions does not leave the diagnostician unaffected. A clear decision cannot always be reached right away; uncertainty must be carefully considered and explained by the radiologist, who needs to make very specific recommendations for further diagnostic work-up at the conclusion of the encounter with the patient.

Eventually, however, and this is something to rub in real deep, mammography is a modality that can lower breast cancer mortality by up to 40% if done technically well by expert mammographers in the context of a well-organized population-based breast screening program. No other imaging modality even comes close to that kind of extraordinary impact on women's health! Ultrasound and MRI of the breast are secondary but essential auxiliary modalities for evaluation of the breast (Table 12.1).

Table 12.1 Suggestions for diagnostic modalities in breast imaging<sup>1</sup>

Clinical problem	Investigation	Comment
<i>Mammographic screening in asymptomatic patients<sup>2</sup></i>		
Screening <40 years	Mammography	Not indicated because there is no proven benefit to screening of women <40 years old who are not at increased risk of breast cancer. Breast cancer is uncommon under the age of 35 and the sensitivity of mammography for detection of malignancy can be reduced in younger patients owing to dense breast parenchyma.
Screening 40–49 years	Mammography	Women seeking screening at this age should be made aware of the risks and benefits. While cancers can be diagnosed by screening, total benefit to the population of this age group is limited.
	US	Only as special adjunct to mammography in women with dense breasts and those with implants.
Screening 50–64 years	Mammography	Decreased mortality results from regular population-based and quality-controlled certified screening in this age group.
	US	Only as a special adjunct to mammography in women with dense breasts and those with implants.
Screening 65+ years	Mammography	Screening by invitation in some programs until 70 years. Self-referral required in some programs.
	US	Useful adjunct to mammography in women with dense breasts and those with implants.

Table 12.1 Suggestions for diagnostic modalities in breast imaging<sup>1</sup> (Continued)

Clinical problem	Investigation	Comment
Family history of breast cancer	Mammography	Evidence of benefit is emerging for women at significantly increased risk in their 40s and appears to outweigh the harm of screening. Screening should only be undertaken after genetic risk assessments and appropriate counseling as to the risks and unproven benefits. Consensus is that screening of women <50 years old with a family history should only be undertaken when the lifetime risk of breast cancer is greater than twice the average. Further guidelines for mammographic and other forms of screening in these women remain under review.
	US	Useful adjunct to mammography in women with dense breasts and those with implants.
Women <50 years having or being considered for hormone replacement therapy (HRT)	Mammography	HRT has been shown to increase density and benign changes in the breast. There is a related drop in sensitivity and specificity and an increased recall rate in screening of such breasts. There is no evidence to support performance of routine mammography prior to starting HRT. Women on HRT 50 years old and over can be appropriately monitored within a regular breast screening program.
	US	Only as a special adjunct to mammography in women with dense breasts and those with implants.
Augmentation mammoplasty (50 years and over)	Mammography, US	As part of the regular breast screening program: mammography is best performed at a static unit as there may be a need for extra (implant displacement) views and US.
<b>Symptomatic patients</b>		
Clinical suspicion of carcinoma	Mammography	Referral to a breast clinic should precede any radiological investigation. Mammography ± US should be used in the context of triple assessment—clinical examination, imaging, and cytology/biopsy.
	US	The modality of choice for women <35 years old. Should be performed at specialist breast clinic.
	MRI	Breast MRI should be considered after histological proof of cancer to exclude multifocality or multicentricity and if disagreement arises between imaging and pathology results.
? Carcinoma recurrence (posttherapy)	Mammography	For detection.
	US	For detection and image-guided biopsy.
	MRI	In ambivalent cases at least 6 months after surgery or 12 months after radiotherapy.
Generalized lumpiness, generalized breast pain or tenderness, or long-standing nipple retraction	—	In the absence of other signs suggestive of malignancy, imaging is unlikely to influence management. Focal, rather than generalized pain may warrant investigation.
Cyclical painful breasts (mastalgia)	—	In the absence of other clinical signs suggestive of malignancy and localized pain, investigation is unlikely to influence management.
Augmentation mammoplasty (clinical suspicion of carcinoma, rupture)	US, MRI	The assessment of integrity of breast implants and potentially co-existing palpable masses requires specialist skills and facilities. MRI is the most comprehensive study.





Table 12.1 Suggestions for diagnostic modalities in breast imaging<sup>1</sup> (Continued)

Clinical problem	Investigation	Comment
Paget disease of the nipple	Mammography	Will show abnormality in 50% of women. Helpful to determine the possibility of image-guided biopsy. When invasive disease is confirmed, it influences surgical management of the axilla.
Breast inflammation	US	Can distinguish between an abscess requiring drainage and diffuse inflammation, and can guide aspiration when appropriate.
	Mammography	May be of value where malignancy is possible.

<sup>1</sup> Modified after: RCR Working Party. *Making the best use of a Department of Clinical Radiology. Guidelines For Doctors*, 5th ed. London: The Royal College of Radiologists, 2003.

<sup>2</sup> In many countries quality-assured population based mammographic breast screening is not yet in place. MRI, magnetic resonance imaging; US, ultrasound.



### Is Breast Screening Worthwhile?

Ten of 100 women eventually get breast cancer; three of those die of the disease. Population-based quality-controlled screening (as performed in Sweden, the Netherlands, Australia, the United Kingdom, to name just a few) saves the life of one of these three women. One percent of all women are thus kept from dying from breast cancer. To reach this result, the Dutch health system spends about 1% of its total health budget. Just imagine if the residual 99% of the budget had a similar effect!

## 12.1 How Do You Analyze a Mammogram?

Always view a mammogram under optimal lighting conditions, that is, with a bright viewbox, well collimated, with a magnifying glass at hand, a hot or bright light on your side, and all of this in a room with low ambient light. To do a bilateral comparison, always put both sides on the viewbox facing each other. Make sure you have a look at previous films, which should also be mounted on the viewbox. If old mammograms exist but are not available to you at the time of image interpretation, perform a preliminary interpretation, request the prior mammograms, and review the images again when they become available. At that time, an addendum to the report should be made. Only image analysis under such strict conditions yields the maximum diagnostic results that we owe our patients.

! Mammography calls for: bright viewbox, bright light, bright brain.

### How Do You Evaluate the Image Quality?

The optical density of the film is optimal if you can appreciate the skin contour well with the hot light. The glandular parenchyma should be penetrated to the extent

that vessels are discernible even in the densest areas of the breast. Principally the breast images should be as symmetric as possible. Digital mammography systems allow adjustment of some image parameters by the radiologist, which can compensate to a certain degree for suboptimal exposure while interpreting the radiograph. However, this option does not replace careful radiographic technique. The positioning of the breast by the mammography technologist should be such that:

- The mamilla is always imaged as integral part of the skin contour and is seen in profile on the craniocaudal view
- The fatty tissue dorsal to the glandular parenchyma and/or the pectoral muscle are—if barely—visible on the craniocaudal view
- On the oblique projection the contour of the pectoral muscle runs from the approximate middle of the upper film edge to the approximate middle of the dorsal film edge.

! In mammography, highly motivated, exquisitely trained, and communicative technologists are crucial.

### What Do You Have to Pay Attention to in Image Analysis?

First compare the **distribution of the glandular parenchyma** of both breasts: it should be distributed almost symmetrically (Fig. 12.1a). Breasts are not always of the same size, however!

When **stellate lesions** are seen (Fig. 12.1b, c), try to determine whether they are due to the superimposition of normal parenchymal structures or whether the architecture of the breast is truly disturbed, that is, distorted or scirrhous. Is the stellate figure visible on the second projection? Sometimes a magnified coned-down view is needed to differentiate a real stellate lesion from a summation phenomenon. Spot compression views can also be very useful in this situation: a radiolucent compression paddle is applied to the area overlying the observed stellate lesion. The added focal pressure causes the various layers of normal breast tissue to spread out, while a stellate

## Mammogram: Normal Findings

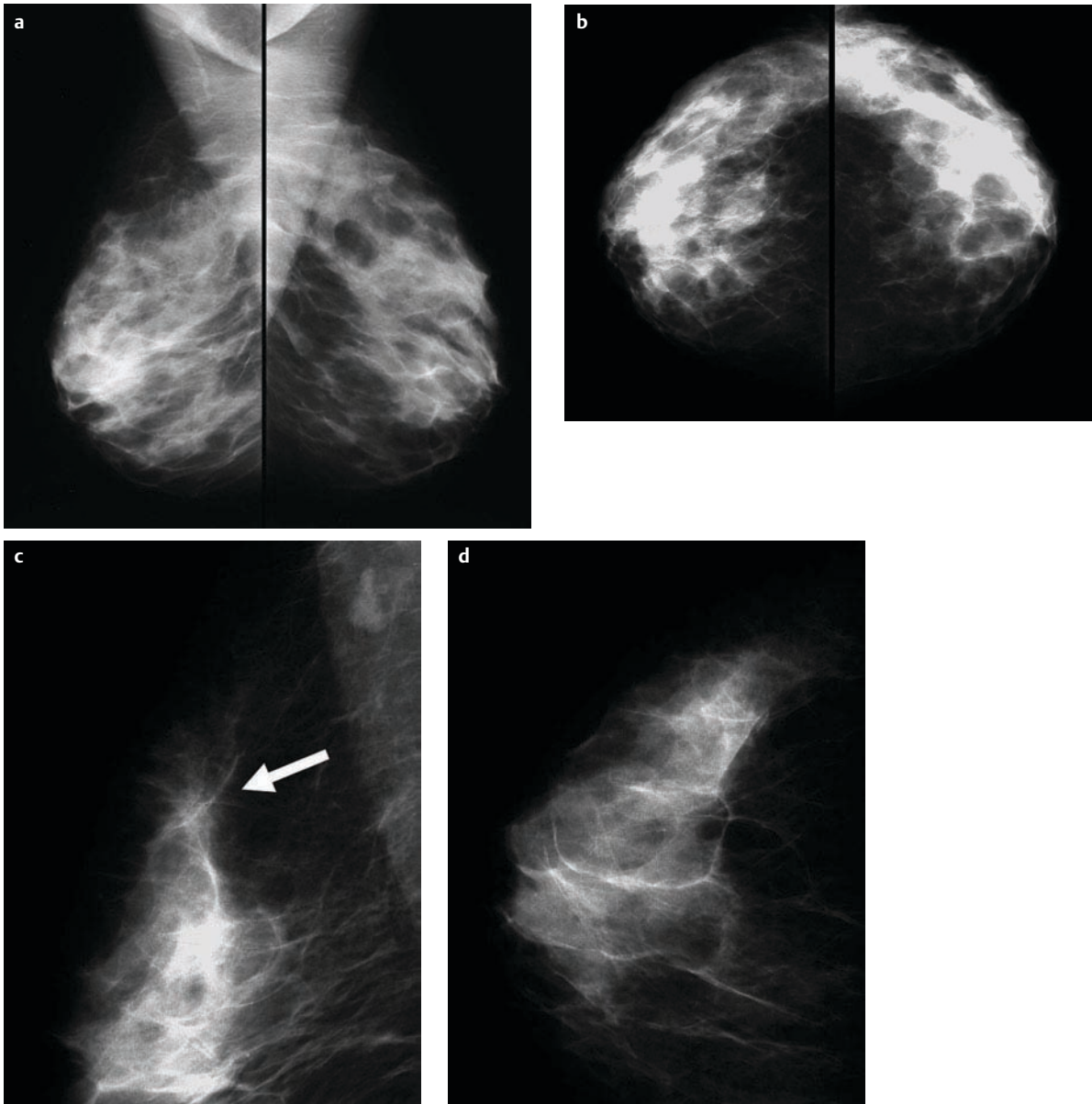


Fig. 12.1 **a** You see the normal medial oblique view of both breasts (note the contour of the pectoral muscle coursing down to the middle of the posterior image margin). The lobulated appearing parenchyma is distributed almost symmetrically in both breasts. **b** On this craniocaudal view the fat tissue

posterior to the glandular parenchyma is well appreciated. **c** This oblique view shows a stellate figure (arrow) in the axillary tail of the breast. **d** The structure is invisible on the craniocaudal view. It was due to a superimposition of multiple different normal structures.

cancer will not spread and may in fact become more conspicuous as the superimposed tissue is moved out of the way. Is there a soft tissue mass in the center of the star? Are there any calcifications visible inside?

If there is a **circumscribed soft tissue mass** in the breast, examine its contour with care. Does it have sharp borders all the way around? Do you perhaps see a halo—a narrow rim of decreased density—around the mass? Or do finger-like extensions of the mass seem to infiltrate the neigh-

boring tissue? Are there any calcifications associated with the mass?

Finally, the mammograms are searched with a magnifying glass and the skin contour is assessed with a hot light. Again, are there **calcifications** detectable? If yes, are they large and coarse or fine, linear, or branching? Do they follow the normal course of vessels or do they align themselves to the glandular duct system? Magnification views facilitate the analysis of suspicious calcifications.

In a symptomatic patient, a palpable lesion or a positive mammographic finding will be further assessed by an ultrasound examination for further characterization.

### Ready for Your First Case? Let's Go!

The mother of Hannah's best and long-time girlfriend has recently learned that she has breast cancer. Hannah has experienced the woman's and the family's constant worry during her visits to the hospital and thus has a very personal interest. She has looked forward to her stay in the breast clinic to learn more about this dreadful disease. She also very much enjoys the contact with the patients, which is much more intense than elsewhere in the radiology department. Dr. Skywang receives her warmly and promises to give her a good introduction into the matter.

## 12.2 Tumorlike Lesions and Tumors of the Breast

### Checklist: Breast Tumors

- Are both breasts depicted symmetrically?
- Is the entire breast parenchyma included on the image?
- Are there any masses?
- How do they relate to their neighborhood?
- Do they alter the parenchymal architecture?
- Are microcalcifications detectable?

### Horror at Dawn

Meg Dyan (26) is horrified: on Saturday morning, while taking a shower, she has felt a lump in her left breast that she believes was definitely not there before. Her

### The Case of Meg Dyan

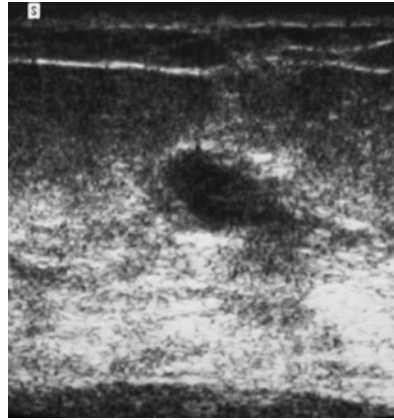


Fig. 12.2 This is the relevant ultrasound image of the lesion in Mrs. Dyan's breast.

breasts always feel a little lumpy and shortly before her menstrual period they tend to be swollen and painful to touch. But now this! The whole weekend was a mess, trying to get help and information on what this could be. An internet search freaked her out even more. First thing on Monday she got herself an emergency appointment in the breast clinic after talking to on the phone to a trusted colleague and her gynecologist. The mammography technologist sends her directly to the radiologist of the day. Dr. Skywang and Hannah listen carefully to her story, ask about occurrence of breast cancers in her family, and then physically examine her breasts. There is a palpable lump, no doubt about it, about 1.5 cm in size. It is mobile relative to the chest wall. The overlying skin is soft and unremarkable. Hannah scans both breasts carefully with the ultrasound probe under Skywang's supervision and then concentrates on the lump in the left breast (Fig. 12.2).

### Fibroadenoma

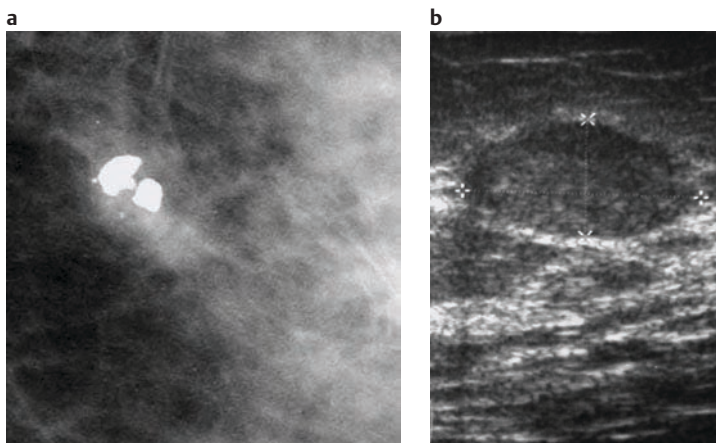


Fig. 12.3a These coarse calcifications are a typical mammographic finding associated with a fibroadenoma. They are reminiscent of popcorn. The soft tissue mass of the actual adenoma is also visible. b Sonographically, a fibroadenoma typically displays a homogeneous internal echo and a regular and smooth border. The echo shadow is minimal, just barely different from the surrounding glandular parenchyma.





### No Reason to Panic!

The normal structure of the glandular breast can be so irregular that separate lumps are felt although they represent nothing but variations of the normal parenchyma. This is particularly so shortly before the menstrual period, when the breasts also tend to be rather dense. For that reason any imaging should be performed in the second week of the menstrual cycle.

### → What is Your Diagnosis?

**Fibroadenoma:** This is a benign tumor of the breast that develops in younger women and then remains in place for a while and often involutes later in life, especially after

menopause. In older women, new fibroadenomas are a rarity and are always very suspect. On physical examination, the fibroadenoma is usually a very mobile lesion. As it may grow rapidly and occasionally reaches a spectacular size, patients are often frightened. The mammogram displays the fibroadenoma as an oval and smoothly margined mass, frequently speckled with coarse calcifications that may remind you of popcorn (Fig. 12.3a). Sonographically the appearance of a fibroadenoma is compatible with a solid mass that shows a rather homogeneous internal echo without any dorsal echo shadowing and also a smooth contour (Fig. 12.3b). If the appearance of the lesion is not that clear-cut or if there is suspicion otherwise, an ultrasound-guided core needle biopsy is rapidly performed, which usually ends the diagnostic uncertainty.

## Cysts of the Breast

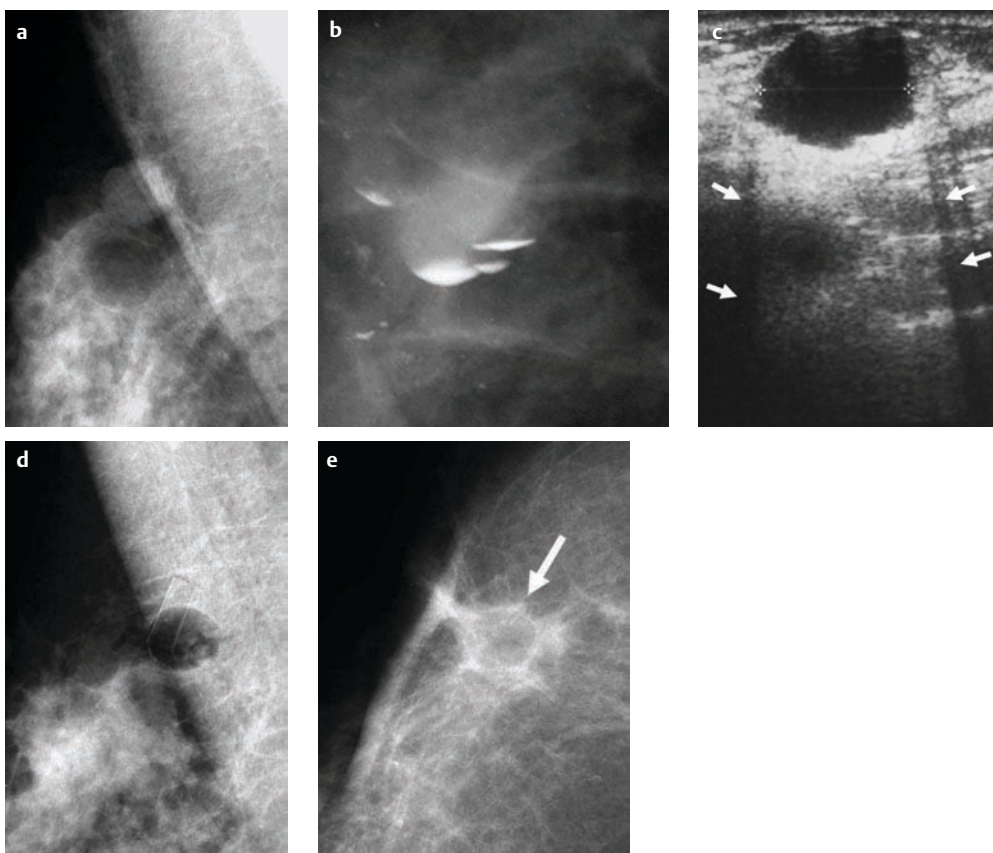


Fig. 12.4a This cyst projecting over the contour of the pectoral muscle has the typical appearance of a benign lesion: a well-defined and smooth margin along the entire circumference. Could this also be a fibroadenoma? Sure. Can breast cancer be excluded? Not based on the mammogram alone. b This lateral magnified view of a breast shows a lamination in some cysts, which are partially filled with milk of calcium—the so-called “teacup” phenomenon. This appearance is pathognomonic for cysts. c The ultrasound appearance of cysts is straight-forward: there is no internal echo and an increased through-transmission of sound, which causes a segmental hyperechogenicity of the tissue distal to the cyst (arrows). d If the cyst

has been punctured and evacuated, air is frequently injected into it again. This is done for two reasons: On the one hand, a subsequent mammogram can now image the cyst wall and any tissue previously masked by the cyst content because of potentially equal radiographic density. This is particularly important in large cysts. On the other hand, it is hoped that the air instillation will support the shrinking of the cyst and prevent recurrence. e This patient had a breast carcinoma removed two years ago. The patient history makes an oil cyst the most likely diagnosis for this lesion in the tumor bed. The lesion is of fat density and shows a thin capsule (arrow). A lipoma of the breast could also look like this.

**Cyst:** A cyst often has its origin in dilated glandular ducts or lobules. It can gain size quickly, can become inflamed, and also—but very rarely—contain a cancer. Mammographically it appears in most instances as a well-margined rounded mass (Fig. 12.4a). The cysts may contain “milk of calcium,” which causes a characteristic interface between the cyst fluid and small calcific particles layering along the dependent portion of the cyst: this is best observed on mammograms taken with a horizontal beam. This so-called “tea-cup” phenomenon is seen on strictly lateral projections (Fig. 12.4b). Occasionally the cyst wall may calcify. On ultrasound a clear-cut cyst shows no internal echogenicity at all and a strong through-transmission of sound (a sector of higher echogenicity directly distal to the cyst; Fig. 12.4c). Absolute proof, of course, is provided by the ultrasound-guided puncture and aspiration of the cyst fluid. If any blood residua are perceived within the aspirated fluid, it should be sent to the pathologist for cytological analysis. In older women and in otherwise very dense breasts, the cyst fluid should be replaced by air before the mammography is repeated. On this immediate follow-up mammogram the cyst wall and the immediate neighborhood of the cyst are scrutinized again with special care (Fig. 12.4d).

An *oil cyst* is a remnant of an injury to the breast that has caused a hematoma and some focal fatty tissue necrosis. The patient history is, of course, the clearest hint at the true nature of the process. On the mammogram the oil cyst appears as a round mass of fatty density (Fig. 12.4e). Sonographically it cannot be distinguished from a simple cyst.

→ **Diagnosis:** The ultrasound examination has been the definitive modality in Mrs. Dyan’s case. Hannah is abso-

### Relief



Fig. 12.5 The cyst content has a dark coloring, much like Coca Cola. From the look in Mrs. Dyan’s eyes you can tell she’s been through 2 days of worry and feels a great relief after the diagnosis and aspiration of this benign cyst.

### The Case of Nastassja Rimzky I

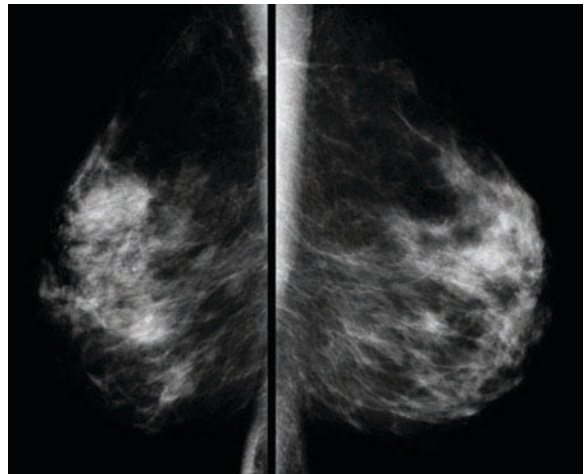


Fig. 12.6 These are the mammograms of Mrs. Rimzky.

lutely certain: the mass in Mrs. Dyan’s breast is definitely a cyst that has acutely increased in size. A number of other smaller cysts are spread over the rest of the parenchyma. When she tells the patient the good news, Mrs. Dyan takes

### Hematoma in the Breast

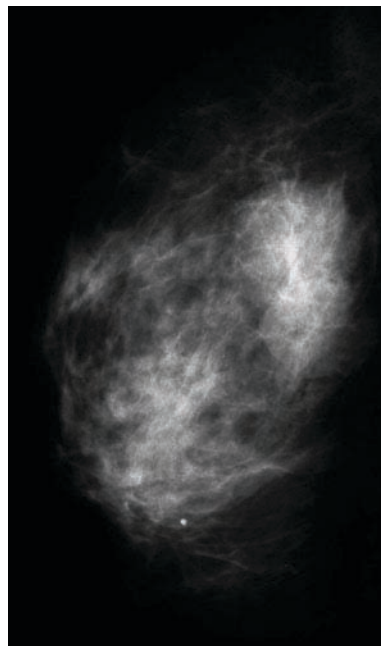


Fig. 12.7 This lady underwent a vacuum core biopsy for a suspect breast lesion two days prior to this follow-up mammogram. A rather large hematoma has developed close to the chest wall. Patient history is the key in this case. But beware! Not every injury to the breast is remembered or admitted to. The reverse is also true: if a lump is discovered in the breast, minor injuries are often blamed as the cause. This may be an unnecessary reminder, but patient psychology plays an important role in medicine.

a deep breath and turns her head sideways. As she turns her head back a little later and looks Hannah straight in the face, her eyes are filled with tears. Hannah also feels choked up a bit and smiles warmly to reassure her. The cyst is punctured under ultrasound guidance, and the fluid is evacuated and sent to the cytology laboratory just to be absolutely sure (Fig. 12.5). Back in the waiting room, Mrs. Dyan embraces her colleague who has accompanied her.

### Tell Me the Truth, Doc!

Nastassja Rimzky (35) has been sent for mammography by her gynecologist. During a routine examination, this physician has palpated a lump in her right breast and sent her for a diagnostic mammogram to further work it up. Mrs. Rimzky had discontinued her breast self-examinations a long time ago. It made her too nervous, she says. She is quite tense now. There is no family history of breast cancer, but her family is rather small. She finds breast compression during mammography quite painful. Hannah studies the films with great care. In the right breast she finds a suspicious mass (Fig. 12.6).

### → What is Your Diagnosis?

**Fibroadenoma, cyst:** These have been discussed above (see p. 273) and may occur in any developed breast.

**Scar, hematoma:** A scar or a hematoma, either posttraumatic or postoperative, can also have the mammographic appearance of a soft tissue mass (Fig. 12.7).

**Invasive breast carcinoma:** An invasive breast carcinoma can have a variety of appearances. If it has a shaggy or ill-defined border (Fig. 12.8a) or if it significantly disturbs the surrounding parenchymal architecture of the breast, this diagnosis is more likely. But breast cancer can also reside inside the parenchyma without any visible involvement of the immediate vicinity; its contour may be sharp and smooth (Fig. 12.8b). On ultrasound, acoustic shadowing and an irregular margin are the most frequent findings (Fig. 12.8c).

**Intramammary lymph nodes:** These are particularly frequent in the lateral quadrants of the breast. Mammographically they may be centrally lucent; their contour is lobulated and a little dent may be visible that corresponds to the hilum of the lymph node (Fig. 12.9).

## Invasive Breast Carcinoma

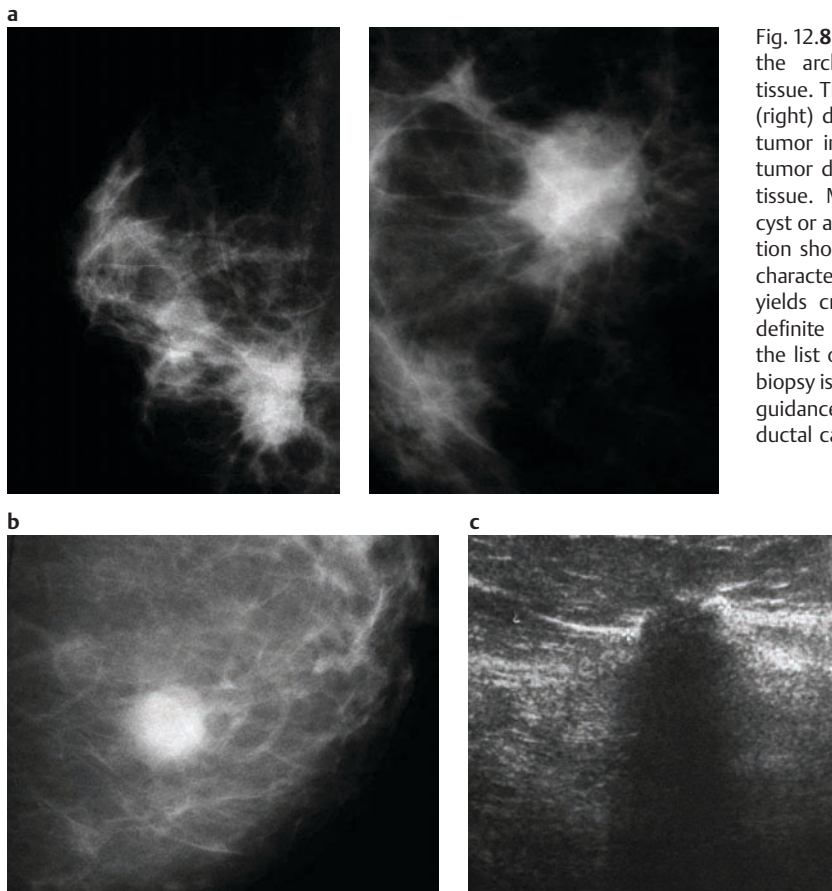


Fig. 12.8a This large lesion (left) has changed the architecture of the neighboring breast tissue. The magnified view in another projection (right) displays the scirrhous extensions of the tumor into the glandular parenchyma. b This tumor does not visibly invade the surrounding tissue. Mammographically it could also be a cyst or a fibroadenoma. An ultrasound examination should definitely be performed for further characterization. c The ultrasound examination yields crucial additional information: There is definite distal echo shadowing. Cysts fall off the list of differential diagnoses. A core needle biopsy is performed right away under ultrasound guidance. The histological result was an invasive ductal carcinoma.



### Intramammary Lymph Nodes

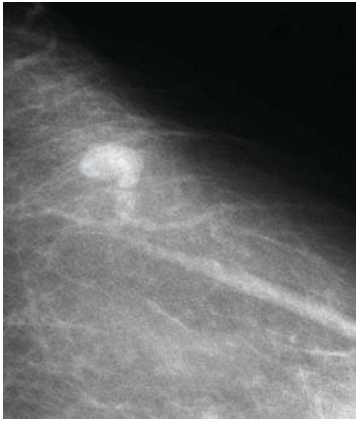


Fig. 12.9 Lymph nodes typically show a little hilar retraction and a fine lobulation.

→ **Diagnosis:** After some consideration Hannah has little doubt that this lesion is a breast cancer. On the magnified views she has also detected a little calcification, which is the case in up to 40% of all carcinomas (Fig. 12.10a). Dr. Skywang asks her to perform an ultrasound of the lesion, which also points towards a malignant character of the lesion (Fig. 12.10b). Dr. Skywang advises the patient to have an ultrasound-guided core needle biopsy done. Mrs. Rimzky agrees right away. The final result is available two days later: it is an invasive breast cancer. MRI of both breasts is then performed, which demonstrates several other lesions in close vicinity to the dominant lesion (Fig. 12.10c).

! In more than 40% of mastectomy specimens, pathologists find additional foci of cancer that went undetected by mammography and/or ultrasound. Contrast-enhanced magnetic resonance tomography of the breast can find many of these lesions with great accuracy and reliability.

Mrs. Rimzky undergoes surgery only a few days later. Instead of the initially planned quadrantectomy, a complete mastectomy and axillary lymph node dissection is done. Fortunately the lymph nodes prove to be unaffected.

### That Tiny Bit of Calcium

Dorothy Lamour (45) has dropped by the breast clinic to get herself “screened.” After being told that the clinic is not part of a breast screening scheme, she pauses for a while, then complains about lumps she has felt in both breasts recently. On clinical examination, Hannah confirms the lumpy consistency of both breasts but cannot find any dominant lesion. Skywang repeats the examination and comes to the same conclusion. Mrs. Lamour does not know of any breast cancer in her family. Mammograms are done and put on the

### The Case of Nastassja Rimzky II

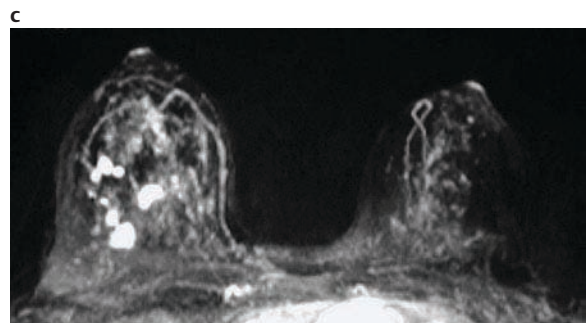
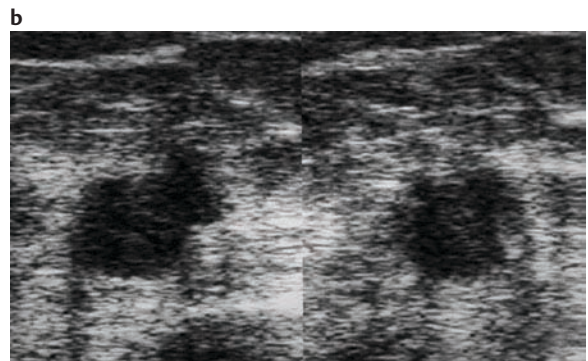



Fig. 12.10 a The magnified view documents the invasion of the surrounding tissue by the cancer a little better. There are fine irregular calcifications in the center of the lesion (arrow). b Sonographically, Hannah sees an irregularly marginated, partially hypoechoic mass. This is definitely not a cyst. The minimally increased through-transmission does not change her opinion at all. c The MRI examination verifies the lesion and finds additional tumors in the same breast.

### The Case of Dorothy Lamour

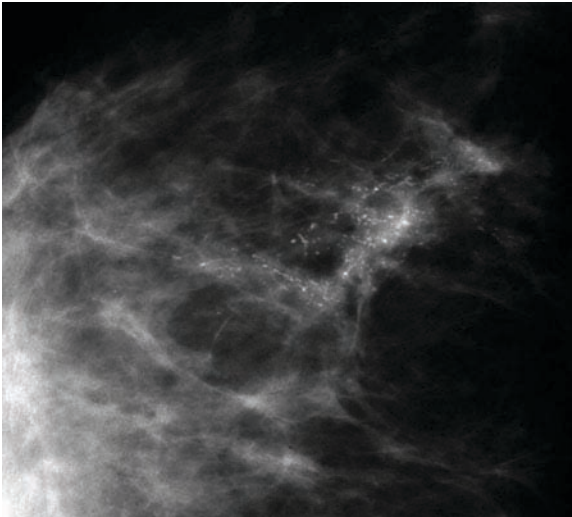


Fig. 12.11 This is the relevant magnified view of Mrs. Lamour's mammogram.

viewbox for analysis. Hannah collimates them carefully and studies them meticulously (Fig. 12.11). Are these not microcalcifications? She grabs the magnifying glass and starts to think about potential differential diagnoses.

#### → What is Your Diagnosis?

**Vascular calcifications:** Vascular calcifications are naturally frequent in older patients but they may also be found in younger women suffering from diabetes or renal insufficiency (Fig. 12.12). The calcifications homogeneously line the vascular walls with an appearance of two fine parallel lines. Their differentiation from calcium within the glandular ducts is unproblematic in most cases.

### Vascular Calcification

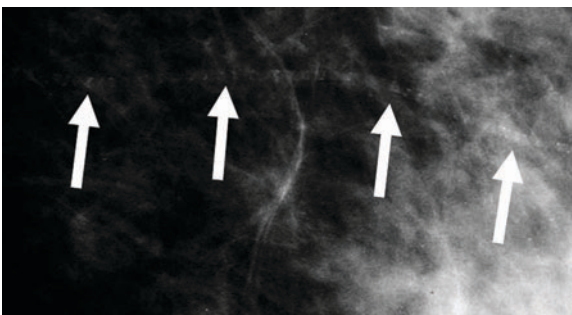


Fig. 12.12 This vessel (arrows) displays fine, regular calcifications along its wall. This appearance is characteristic and can hardly be confused with more ominous intraductal calcifications.

### Fat Necrosis

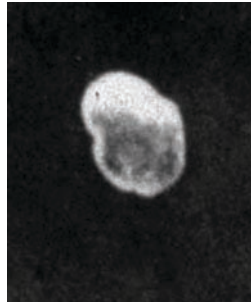


Fig. 12.13 This magnification view shows the typical appearance of a necrosis of fatty tissue. The calcification is relatively large and round and has a central lucency. A calcification in the wall of a cyst would probably be coarser. The differentiation is a purely academic one, though, because neither entity is associated with an increased risk of malignancy.

**Fat necrosis:** This entity often presents as a relatively large calcification with a central lucency (Fig. 12.13). Its radiological characteristics are fairly reliable and may not require any further action other than the regularly scheduled follow-up examination.

**Cysts:** Cysts may show a similar appearance if they develop calcifications within their walls.

### Plasma Cell Mastitis

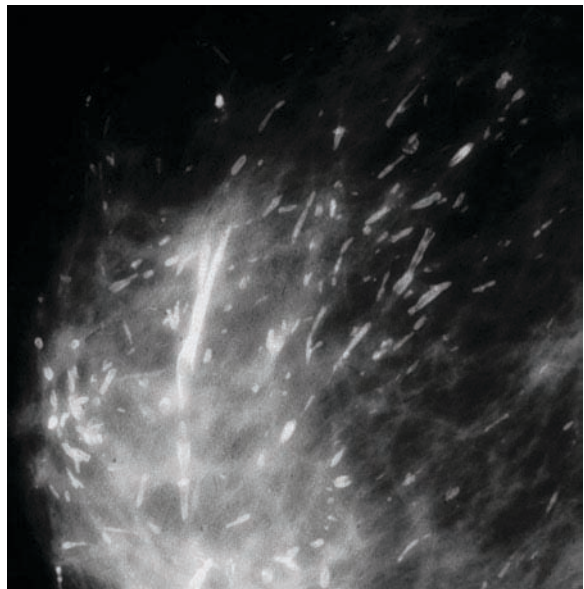

Fig. 12.14 Plasma cell mastitis is characterized by stiletto-like, smoothly marginated and dense calcifications located within the glandular ducts and pointed toward the mamilla. So this is a pretty safe diagnosis. But beware: Patients with plasma cell mastitis, as all other women, can also develop a breast carcinoma. Remember the "satisfaction of search" effect and always carefully scrutinize the entire mammogram even if you find an obvious diagnosis!

### Sclerosing Adenosis

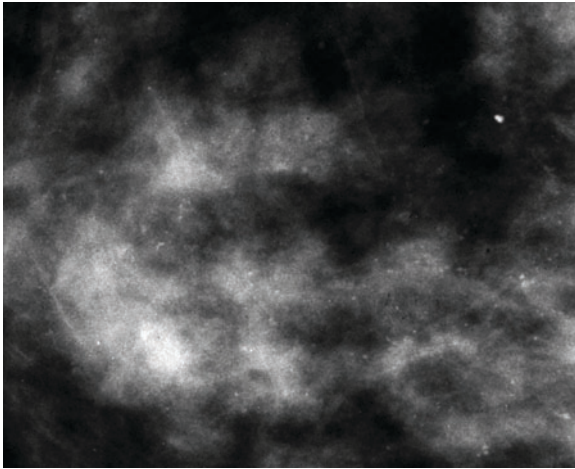


Fig. 12.15 Here they are—the little dog's paw-like calcifications of the sclerosing adenosis. They must be analyzed with extreme care and frequently one will resort to a core needle biopsy: Malignant calcifications are not that different in appearance and may be present on a radiograph that also shows extensive sclerosing adenosis, distracting the radiologist. The comparison with previous films is therefore especially crucial.

**Plasma cell mastitis:** In plasma cell mastitis, solid, rod-shaped calcifications are formed within the glandular ducts of the breast (Fig. 12.14). These calcifications are much more regular and denser than malignant calcifications.

### Ductal Carcinoma In Situ

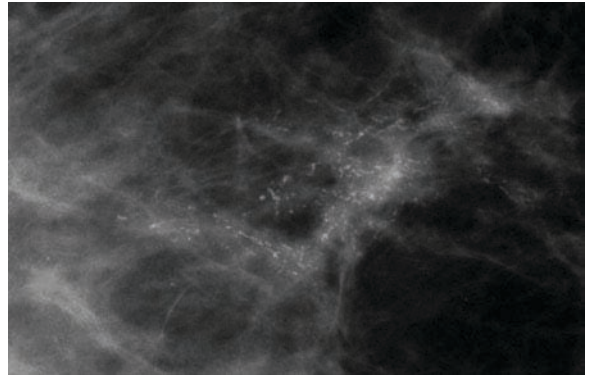


Fig. 12.16 These irregular calcifications follow the course of the glandular ducts and therefore appear branching. This is a ductal carcinoma in situ.

**Sclerosing adenosis:** Sclerosing adenosis of the breast goes along with scattered microcalcifications, almost always bilateral, that are round, grouped, and rather regular (Fig. 12.15). The Dutch love to call them "hondepotjes" (little dog's paws).

**Ductal carcinoma in situ (DCIS):** The DCIS consists of a cellular heap that replicates and spreads within the glandular ducts. It is characterized by fine and branching calcifications (Fig. 12.16). The neighborhood is rarely infiltrated. The DCIS can encompass a large part of the ductal system and may also occur in different divisions of the gland. The

### Stereotactic Biopsy

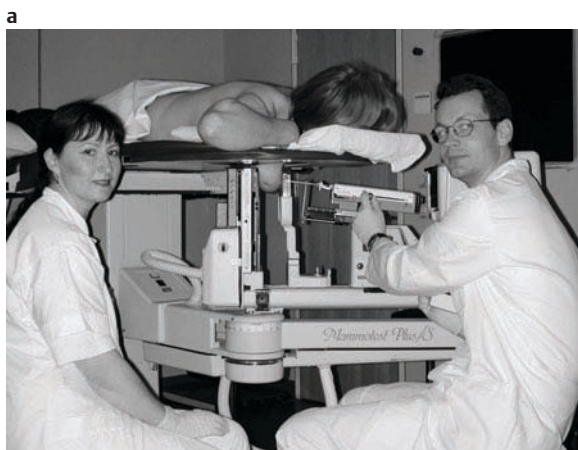
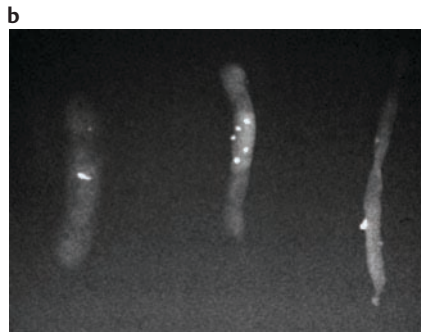
Fig. 12.17 **a** This dedicated stereotactic table is used to perform core biopsies with a vacuum needle. In this technique a hollow needle is advanced into the immediate vicinity of the calcifications with high precision. Tissue is then sucked into a lateral opening of the needle, excised with a circular cutting knife, and removed from the inner core of the needle while the outer wall of the needle remains in place. These steps are



repeated, rotating the needle in a clockwise fashion until the entire tissue surrounding the needle has been sampled. **b** The magnified specimen radiograph of the harvested cores confirms that the microcalcifications are included in the tissue sample. It is only then that you can be certain to have targeted and removed tissue from the correct region in the breast.



determination of invasiveness cannot be made on a mammogram.

→ **Diagnosis:** The calcifications in Mrs. Lamour's breast are irregularly configured and arranged in a triangular formation oriented toward the nipple, much like a "flock of wild geese" as some call it. Hannah has another, closer look together with Dr. Skywang. Unfortunately, there is little doubt that these are malignant calcifications. Ultrasound of the area is unremarkable: the calcifications are too small to detect and no discrete soft tissue mass is discernible. Mrs. Lamour takes the bad news calmly but she wants something to be done quickly. An appointment for a stereotactic needle biopsy is made for the next day (Fig. 12.17a). After the procedure, the harvested tissue cores are radiographed once again to verify that they do indeed contain the suspicious microcalcifications (Fig. 12.17b). The histological examination finds a DCIS with smaller invasive components.

### Please, Not Again

About year and a half ago, Trudy Hansson (55) had a 1 cm carcinoma removed from her left breast. She received radiation therapy and now returns for the follow-up appointment. Hannah examines the breast and finds the scar soft and mobile. But there is some palpable resistance in the tumor bed. The mammogram is definitely abnormal—there is a soft tissue mass in the previous location of the cancer (Fig. 12.18). Hannah lists the potential differential diagnoses.

### → What is Your Diagnosis?

**Hematoma:** A hematoma normally occurs in conjunction with breast surgery but may also develop after minimally invasive biopsies (see Fig. 12.7) and other injuries to the breast. In most cases the connection with the trauma is

### The Case of Trudy Hansson I

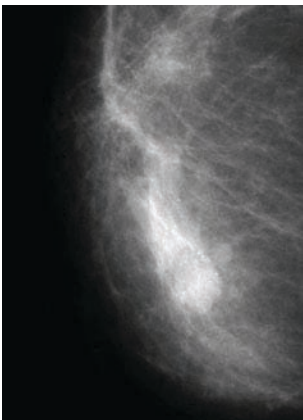


Fig. 12.18 This is the relevant subsection of Mrs. Hansson's mammogram.

### Skin Alterations

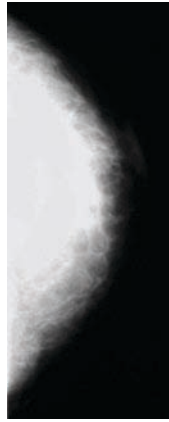


Fig. 12.19 This breast is edematous and dense after radiation therapy. Recurrent breast cancer is difficult to exclude on a conventional mammogram under these circumstances.

evident and indicative of the diagnosis. Beware, however, of injuries suddenly remembered *after* a lesion is found: patients may be in denial and understandably tend to look for nonmalignant causes of a lump in the breast.

**Oil cyst:** Fat necrosis may develop at the site of tumor resection and ultimately may turn into an oil cyst (see p. 274). Oil cysts are easy to differentiate from other lesions mammographically because of their fat-equivalent density (see Fig. 12.4e).

**Skin alterations after surgery:** The retraction of the skin and the scarring of the cutaneous and breast tissue may assume the mammographic appearance of a tumor recurrence. In addition, therapeutic radiation leads to skin thickening and the parenchyma may develop some radiation fibrosis; this makes mammographic evaluation of the treated breast extremely difficult (Fig. 12.19). Contrast-enhanced MRI of the breast may be of use in this situation and is being evaluated as an adjunct tool to mammography.

**Recurrent carcinoma:** The recurrence of a breast carcinoma is diagnosed mammographically mainly by the comparison of sequential postoperative examinations. Its appearance is not really different from what a primary tumor looks like (see Fig. 12.8).

### The Case of Trudy Hansson II

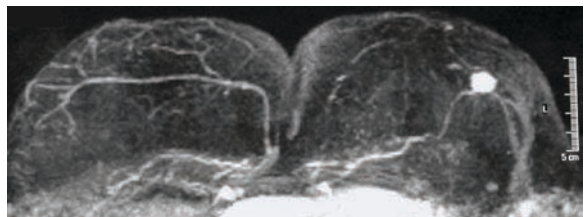


Fig. 12.20 The breast MRI confirms the presence of a contrast-enhancing lesion in the suspicious region. There is little chance for this to be anything but a carcinoma. Fortunately, there are no associated additional malignant foci.

### Galactography: Normal Findings

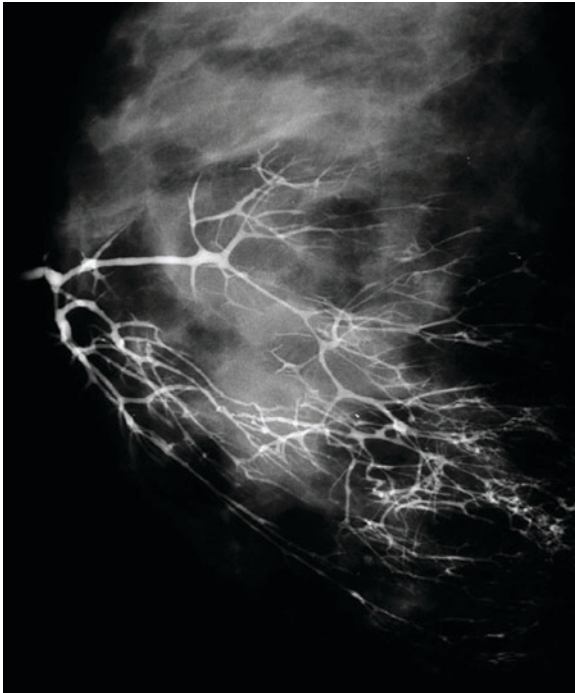

Fig. 12.21 This galactogram is completely normal. The ducts can be followed up to the mamilla; there are no cysts, no dilations, no filling defects; and there is no abrupt termination of filling. In some women, fluid can be gently squeezed out of the ducts with just a little compression during the clinical examination. This is a normal phenomenon—even nonlactating breasts secrete minimal amounts of fluid, which are reabsorbed by the ductal epithelium.

→ **Diagnosis:** Hannah does not really believe that the abnormality on Mrs. Hansson's radiographs represents a hematoma more than a year after surgery. The density of the lesion is too high to consider an oil cyst. A scar is possible and pretty difficult to differentiate from a recurrence. The only other mammogram available is the preoperative film. Dr. Skywang decides to get an MRI of the breast because it is more or less the only modality that can exclude a recurrence in this case (Fig. 12.20). The result of the MRI is highly suggestive of a tumor recurrence. Poor Trudy Hansson is going to go through it all over again.

#### A Little Speck in the Brassière

Catherine Winnipeg (42) has noted secretions coming out of her right nipple lately. For the time being she has put a little panty liner in her bra. The fluid appears dark. Whether it was also bloody she cannot say. Her left breast never gave her any trouble. After she had breastfed her three children, both breasts kept on secreting for quite a while but she did not really attribute any relevance to it. Now she worries. Her mammogram shows nothing abnormal. During the clinical examina-

### The Case of Catherine Winnipeg

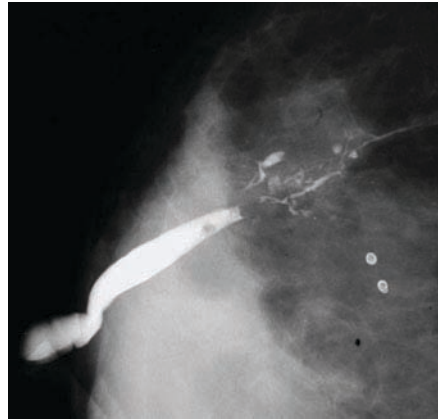


Fig. 12.22 One of the mamillary ducts is quite dilated and obstructed. A filling defect is visible: the papilloma has been located. Have you seen the two calcifications in the immediate neighborhood? You should be able to make that diagnosis by now!

Fat necrosis.

tion, Hannah is able to gently squeeze some more dark fluid out of the right breast. Together with Dr. Skywang, Hannah calms Mrs. Winnipeg. The reason for these secretions is most likely papillomas, she tells her, and these hardly ever turn malignant. She advises the patient to have a galactography done. For this procedure, the glandular duct in question is cannulated from the nipple with a fine blunt needle and a little contrast is given. Subsequently, a mammogram is performed. In Figure 12.21 you can see what a normal galactogram looks like. Mrs. Winnipeg's galactography shows a typical filling defect in the affected duct, compatible with a papilloma (Fig. 12.22). Dr. Skywang suggests having it removed surgically. Apart from getting rid of the annoying secretions, the histological work-up would end any uncertainty about the benign or malignant nature of the lesion.

## 12.3 Breast Implant

### Cup A to Cup C, or Beauty Has Its Price

Pamela Baywatch (63) is an impressive lady who has always been preoccupied with her looks. She has made a lot of sacrifices to appear young. Now her internist has found a liver lesion during a routine check-up that included an ultrasound. He thinks it might be a metastasis of an unknown primary tumor and naturally thought of a breast carcinoma first. Mammography, however, did not really help—for a clear reason (Fig. 12.23a). MRI of the breast was scheduled. Hannah looks at the images and is absolutely perplexed

## The Case of Pamela Baywatch I

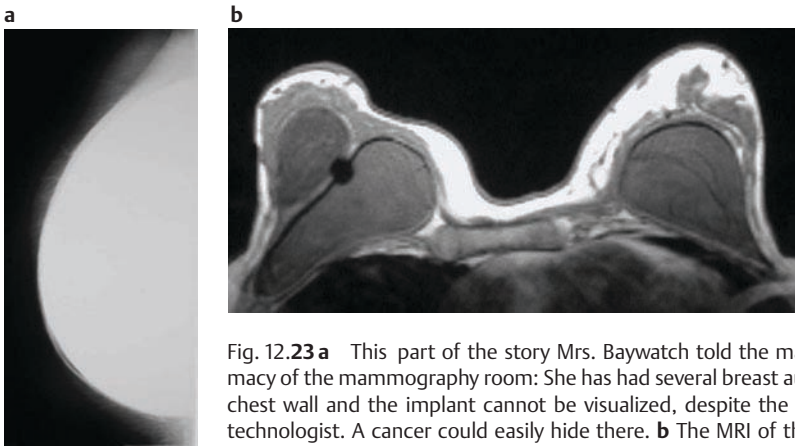


Fig. 12.23 **a** This part of the story Mrs. Baywatch told the mammography technologists only in the intimacy of the mammography room: She has had several breast augmentations in her life. The tissue between chest wall and the implant cannot be visualized, despite the efforts and tricks of the most experienced technologist. A cancer could easily hide there. **b** The MRI of the breast will hopefully clarify the situation.

(Fig. 12.23**b**). What on earth is going on in this breast? Skywang also has some problems, at least before talking to Mrs. Baywatch.

#### → What is Your Diagnosis?

**Breast implant:** Certain types of breast implants consist of a silicone rubber envelope filled with fluid. Until a few years ago, silicone gel was used exclusively. Now combinations of silicone gel and saline are used (saline in an outer lumen, silicone in the inner lumen of a double-lumen implant). After the implantation, a fibrotic capsule forms around the rubber envelope of the implant (Fig. 12.24**a, b**). The capsule often retains the fluid even after the rubber envelope has ruptured and collapsed (Fig. 12.24**c**).

**!** If a breast implant is inserted in an attempt to reconstruct the breast after breast cancer surgery, a tumor recurrence can often only be excluded by MRI (Fig. 12.25). If a breast has been enlarged for cosmetic reasons, special implant displacement views are obtained in addition to regular mammographic views. If the breast parenchyma cannot be visualized adequately, or if implant rupture is suspected, patients may need to be examined with MRI.

→ **Diagnosis:** Hannah still has no clue what to say about Mrs. Baywatch's breasts. After contrast administration, Mrs. Baywatch's breasts show no contrast enhancement whatsoever, so an invasive carcinoma can be excluded with sufficient certainty. And the rounded signal void in the right breast is best explained by a metal artefact, which would not surprise anyone after the apparent surgery. But what is the second large structure anterior to the silicone implant? Two additional MRI sequences point Hannah in the right direction (Fig. 12.26). Apart from that she takes the time to have a long conversation with the patient, which helps a lot in sorting out image findings in patients with a complex past surgical history.

## Breast Implant

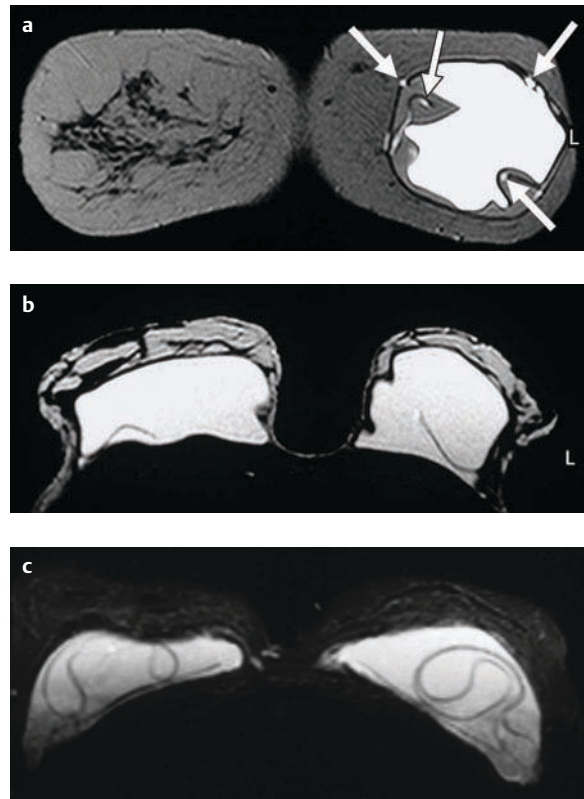


Fig. 12.24 **a** This silicone-selective MRI sequence amplifies the silicone signal inside the implant. The fibrotic capsule around it is filled with fluid. A few drops of silicone (arrows) can be seen within the folds of the implant, indicating a leak of the implant envelope. **b** These folds have to be differentiated from frank ruptures of the implant envelope. **c** The MRI appearance of ruptured implant envelopes is characterized by a typical pattern reminiscent of a popular Italian dish: it is called the “linguini” sign. The silicone remains within the outer fibrotic capsule around the collapsed rubber envelope.



### Recurrent Carcinoma in a Breast Reconstructed with an Implant

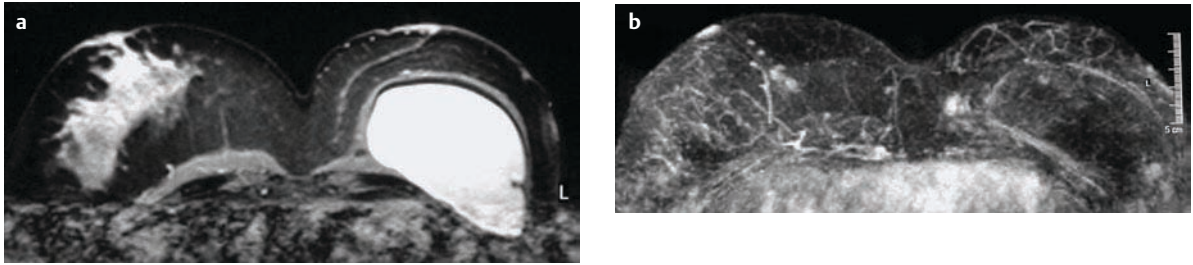


Fig. 12.25 **a** This T2-weighted and fat saturated MRI sequence shows the intact implant in the left breast three years after the resection of a carcinoma. **b** After contrast administration, an enhancing lesion is appreciated medially in the left breast

and another group of suspicious lesions appears in the contralateral breast. The left-sided lesion is a recurrence until proven otherwise. The finding in the right breast must also be examined histologically.

### The Case of Pamela Baywatch II

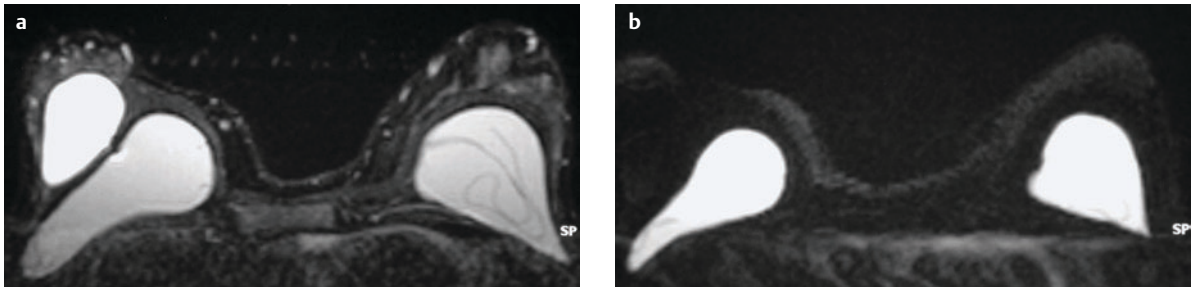


Fig. 12.26 **a** This T2-weighted and fat-saturated sequence documents the implant rupture on the left with a nice “linguini” sign. On the right, two adjacent fluid collections are seen. **b** Another silicone-selective sequence—you have seen one

in Fig. 12.24a already—solves the problem: The anterior fluid collection does not contain silicone and is a residual cyst; the posterior collection is the silicone implant.

The story Mrs. Baywatch tells sounds unreal but is true and indicative of what some will do for beauty and for money. In the Swinging Sixties she had both her breasts augmented with allogenic fat implants. These became infected on one side and were removed and replaced with silicone implants. The fluid retention in the right breast visible on MRI is most likely a remnant of this first fat implant. Apart from that, the left implant envelope is ruptured.

For Mrs. Baywatch the story took a fortunate turn: the liver lesion was surgically removed and proved to be benign. For the surgeon who illegally implanted the allogenic fat in her breasts and in the breasts of a number of other women back in the sixties, the opposite was true: he committed suicide a few years later.

## 12.4 Tumors of the Male Breast

### Alone among Women

Clark Winterbottom (55) was persuaded to go to the breast clinic by his wife. He had felt a lump behind his right nipple a few weeks ago. To top it off, the whole thing now started to be painful. He sits in the waiting room and leafs through a fashion magazine uneasily. During her clinical examination of his breasts, Hannah palpates a lump in the retromamillary region on both sides. The ultrasound examination confirms the presence of glandular tissue. Hannah knows that there are only two major differential diagnoses for a man with a lump in the breast: a gynecomastia caused by a variety of factors (Fig. 12.27)—as is fortunately true in Mr. Winterbottom’s case—and a breast carcinoma, which is very rare in men (Fig. 12.28). If there is the slightest doubt as to the benign character of the tumor, all of the glandular tissue is removed, which is in the interest of most patients anyway.

### The Case of Clark Winterbottom

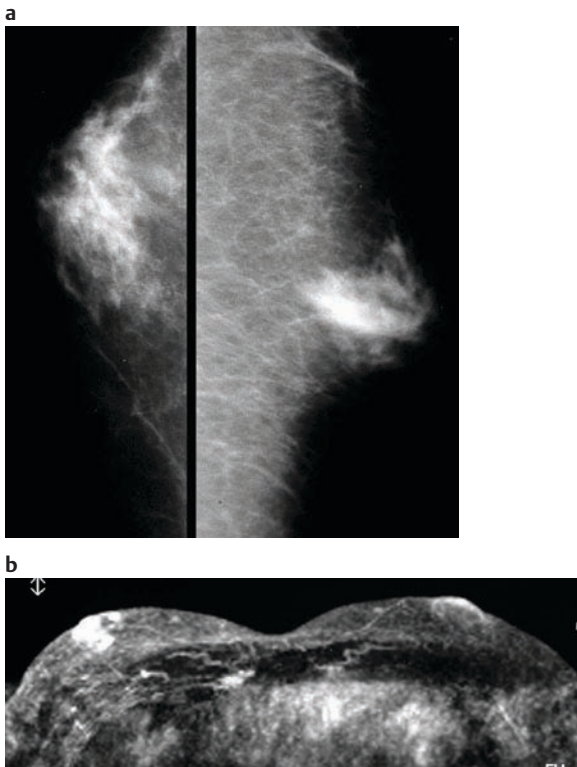


Fig. 12.27 The MR image after contrast administration displays the strong enhancement of the proliferative glandular parenchyma on both sides, but more on the right than on the left. The pattern fits well with a gynecomastia. The indication for surgery depends to a great extent on patient preference and on the underlying cause of the gynecomastia, which may be reversible and can sometimes be treated medically.

## 12.5 Dr. Skywang's Test

Hannah has told Giufeng about the work in the breast clinic. Giufeng wants to come in for a day with Hannah and also take a look. Milva Skywang takes a little time to show them a few test cases at the end of a busy day in the clinic. Gregory drops by to check what the girls are doing but is sent back to neuroradiology straight away by Mrs. Moore, the technologist in charge of mammography: "Have they run out of work in the Neuro section?" Skywang glances with amusement at the two chuckling students and tells the history of the first test case with smirk.

### The Clock Is Ticking

Samantha Sorrow (42) has decided to get a mammogram—for the first time in her life. Her mother and her aunt have died of breast cancer and now breast cancer has been diagnosed in her younger sister. Mrs. Sorrow therefore is a high-risk patient—no doubt about

### Breast Carcinoma in a Man

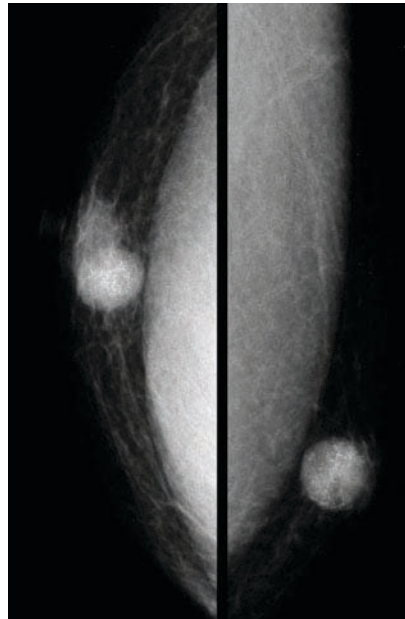


Fig. 12.28 You are looking at a medial oblique (a) and a cranio-caudal mammogram (b) of a man. Located anterior to the pectoral muscle is seen a circumscribed soft tissue mass with fine internal calcifications. This is a breast carcinoma. Breast cancer in men is mammographically identical to the cancer in women.

that. She had a genetic assessment to determine whether she is a carrier of the *BRCA-1* and *BRCA-2* genes, which may be associated with a lifetime risk of developing breast cancer as high as 87%. Her husband accompanies her into the examination room. Her clinical examination is unremarkable. The mammograms, however, show a lesion (Fig. 12.29a). Do you see it?

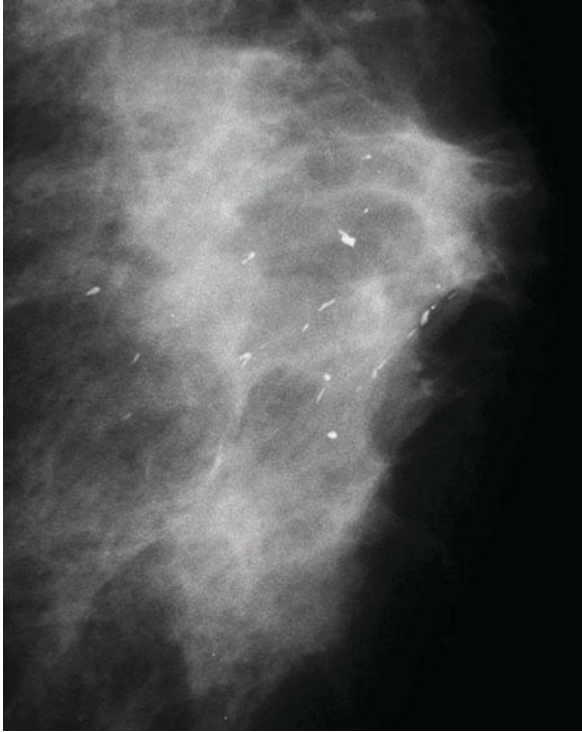Giufeng hasn't a clue—no wonder, it's her first time in mammography. Hannah has a potential diagnosis in the back of her mind but she is not completely sure. The calcifications are definitely intraductal. But they are also smoothly marginated and very dense. Can you help the two women? The next case Dr. Skywang has set aside for Giufeng.

### Free Fall

Joselyn Busy (55) has felt a lump in her left breast after a fall in her bathtub. That was nine months ago, she says. Her daughter brings her to the appointment. Mrs. Busy tells the technologists she has to hurry home because the washing machine is still running. Giufeng looks at the mammogram of Mrs. Busy (Fig. 12.29b). Do you see the problem? What could it be?

## Test Cases

a Samantha Sorrow



b Joselyn Busy

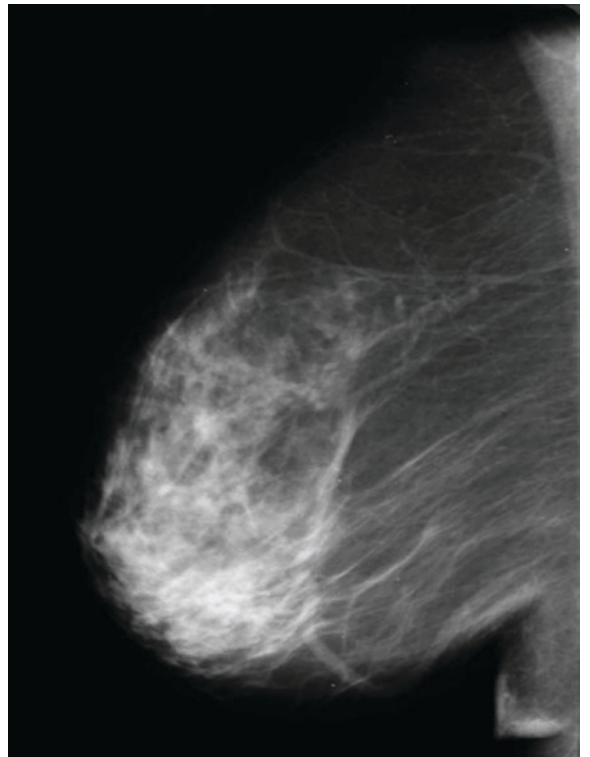
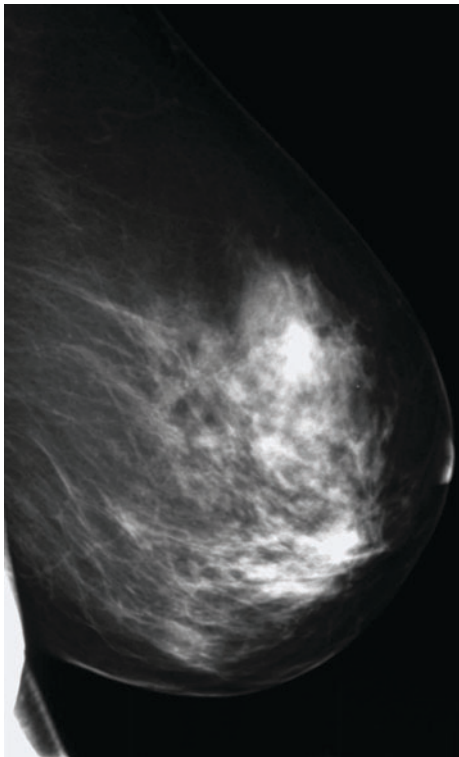
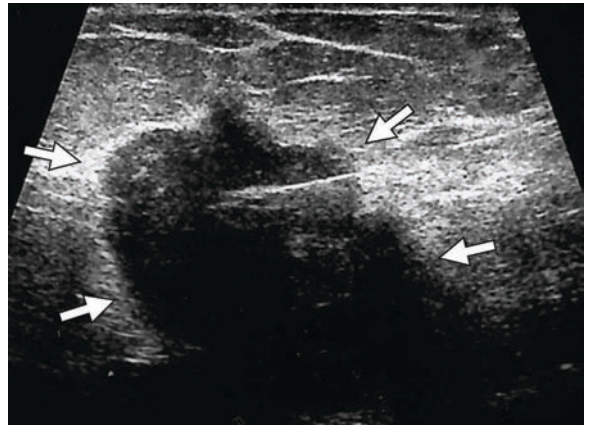
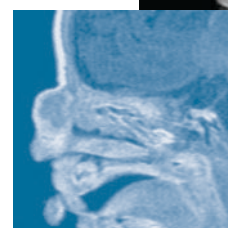


Fig. 12.29 a Here you see a subsection of the mammogram of Mrs. Sorrow. b Check out the left and right lateral mammograms and the ultrasound of Mrs. Busy.



# 13 Face and Neck Imaging



Ear, nose, and throat (ENT) specialists and oral and maxillofacial surgeons consult with radiologists on a regular basis. The ophthalmologists come less often. Classical problems are inflammation of the paranasal sinuses, the dental status, or the localization of metallic foreign bodies in the eye (Table 13.1). Any other face, head, and neck ima-

ging problems tend to get very interesting fast. Frequently the neurologists and the neurosurgeons are also involved. Often confirmation of a clinically suspected diagnosis or the further characterization of a lesion or tumor before aggressive therapy is the objective. Facial fractures will be dealt with in Chapter 14 on “Trauma.”

Table 13.1 Suggestions for diagnostic modalities in face and neck imaging<sup>1</sup>

Clinical problem	Investigation	Comment
<b><i>Disease of the nose, the sinuses, the ear, and the salivary system</i></b>		
Congenital disorder	MRI/CT	Definitive examination for all malformations. CT may be needed to define bone and skull base abnormalities. Sedation or general anesthesia may be necessary for young children.
Sinusitis	XR	Acute sinusitis can be diagnosed clinically. If symptoms persist >10 days, XR or limited sinus CT is indicated. Findings are often nonspecific and encountered in asymptomatic individuals.
	CT	If maximal medical treatment fails, if complications arise (e.g., orbital cellulitis), if malignancy is suspected and surgery is anticipated.
Middle or inner ear symptoms (including vertigo)	CT	Evaluation of symptoms requires ENT, neurological, or neurosurgical expertise.
Salivary gland mass	US	Initial method of choice. Highly sensitive and specific. Can be combined with biopsy.
<b><i>Diseases of the neck</i></b>		
Mass of unknown origin	US	First-line investigation for characterization. Can be combined with biopsy.
	MRI/CT	If the full extent of the lesion is not determined in US, for identifying other lesions and staging.
Congenital disorder	See above.	See above.
<b><i>Diseases of the TMJ and the teeth</i></b>		
TMJ dysfunction	XR	For documentation of osseous degenerative change.
	MRI	Definitive investigation.
Dental status	XR	To find or exclude dental foci, particularly before immunosuppressive therapy.

A-P, anterior–posterior; CT, computed tomography; ENT, ear, nose, and throat; MRI, magnetic resonance imaging; TMJ, temporomandibular joint; US, ultrasound; XR, radiography.



Table 13.1 Suggestions for diagnostic modalities in face and neck imaging<sup>1</sup> (Continued)

Clinical problem	Investigation	Comment
<b>Diseases of the eye</b>		
Orbital lesion	MRI	Investigation of choice. Beware of metallic foreign bodies.
	US	Consider for intraocular lesions.
	CT	To evaluate the osseous structures and the nasolacrimal duct.
Orbital trauma	CT	When orbital trauma is combined with major facial trauma. Additional 3D reconstructions are very helpful.
Orbital foreign body	XR	Single soft-exposure lateral XR can exclude a metallic foreign body. Additional A-P XR before MRI is considered.
	CT	Required by some specialists if a metallic foreign body is found by XR.
	US	If a foreign body is radiolucent or XR is difficult.
Acute visual loss	MRI/CT	MRI is preferable for suspected lesions of the optic chiasm.
	Angiography	Specialist referral is indicated.

<sup>1</sup> Modified after: RCR Working Party. *Making the best use of a Department of Clinical Radiology. Guidelines For Doctors*, 5th ed. London: The Royal College of Radiologists, 2003.  
A-P, anterior–posterior; CT, computed tomography; ENT, ear, nose, and throat; MRI, magnetic resonance imaging; TMJ, temporomandibular joint; US, ultrasound; XR, radiography.

## 13.1 Diseases of the Nose and Sinuses

### Checklist: Diseases of the Nose and Sinuses

#### Congenital lesions

- Is there are a communication to the subarachnoid space or the brain?

#### Paranasal sinuses

- Are the sinuses pneumatized normally?
- Are they normally radiolucent? Have they lost volume? Or is there an air–fluid interface?
- Are the bony structures destroyed or displaced?
- What previous surgical procedures have been performed?

### That Little Nasal Hump

Agostino Martinez (3) has been brought by his worried parents. He is going to be operated on for a little bulge at the base of his nose that has been present since birth. The surgeons want to know the precise extent of the tumor before they resect it and have therefore requested MRI. Giufeng got the word of this interesting case from Greg, who is all exited about it. She actually manages to be the first to view the images as they pop on the monitor one by one (Fig. 13.1). Greg has also told her that it is the extremely complex embryological development of the facial bone with all its pitfalls that makes this examination necessary. Normal fusions, for example, may be delayed or omitted (see Fig. 3.3,

### The Case of Agostino Martinez

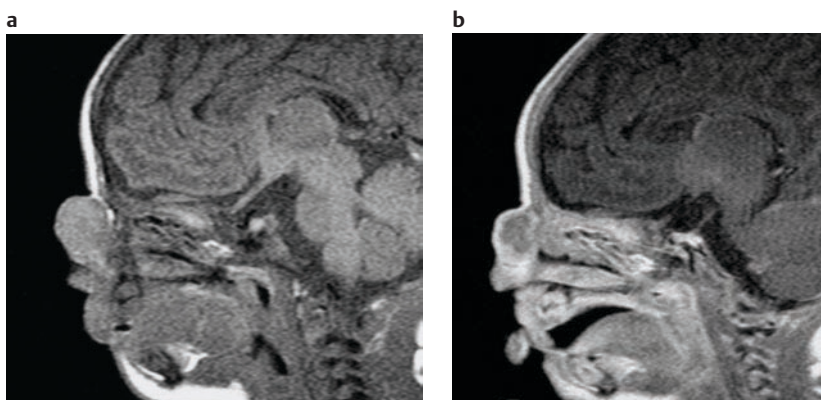


Fig. 13.1 **a** This T1-weighted sagittal MR image shows a lobulated tumor at the base of the nose. **b** After contrast administration, the periphery of the lesion enhances markedly. A communication to the subarachnoid space was not seen on this or on other images in this study.

p. 9) or tissue may be left behind or misdirected on its path of migration. Congenital midline lesions of the face can extend deep into the cranium and ultimately even extend to the subarachnoid space or the brain. Ill-informed surgical procedures may result in serious complications such as cerebrospinal fluid (CSF) leak or meningitis.

Giufeng is mulling over what exactly the problem is with little Agostino and reviews the scan again.

#### → What is Your Diagnosis?

**Nasofrontal encephalocele:** An encephalocele is a protrusion of the dural sac that contains CSF and brain tissue. It can be located anywhere along the neuroaxis posteriorly (Fig. 13.2) as well as anteriorly. If it contains no brain tissue, it is also called a meningocele.

**Dermoid:** A dermoid consists of ectodermal tissue (epidermal and dermal elements) left behind during an embryological migration process. Its facial variety is found at the base of the nasal ridge and expands the bone there (Fig. 13.3). It can also be a component of a nasal CSF fistula.

**Nasal glioma:** The nasal glioma consists of sequestered brain tissue at the base of the nose (Fig. 13.4). It may have a fibrous connection to the subarachnoid space but lacks a communication to the CSF space.

→ **Diagnosis:** Giufeng has looked for the relevant finding. There is no apparent communication between the tumor and the CSF space. A defect in the bone is not seen.

#### Meningocele

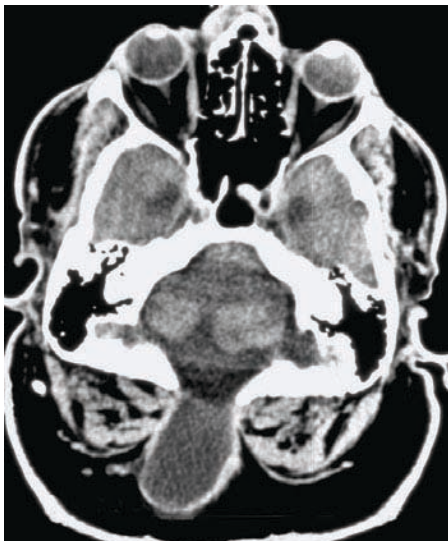

Fig. 13.2 The axial CT section through the skull base demonstrates a posterior osseous defect through which a dural pouch extends into the subcutaneous tissue. This does not contain any brain tissue.

Agostino's small bulge can be resected in a cosmetically optimal fashion. It is most likely a benign nasal glioma that has no malignant potential and does not tend to recur. Greg, who had been held back by a conversation with the chairman, reviews the case himself and agrees with her conclusions. The Martinez family can calm down again. Pathological examination after resection confirmed the presence of brain tissue in this lesion.

#### Dermoid

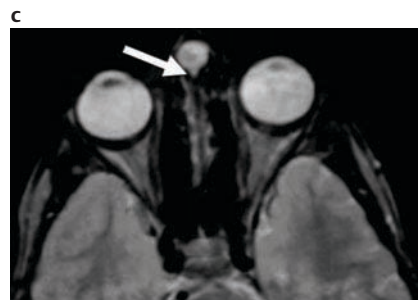
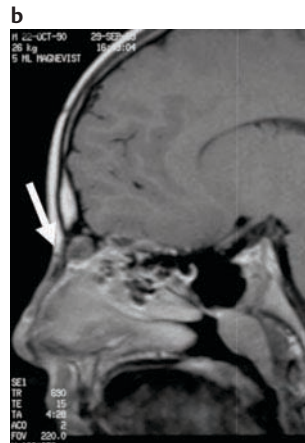
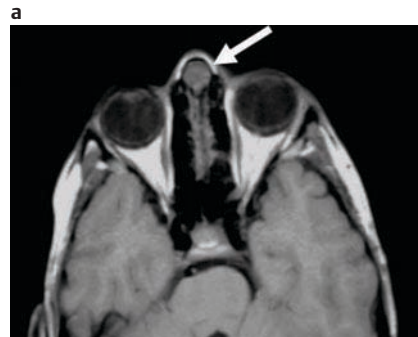


Fig. 13.3 **a** The axial T1-weighted MR image through the nasal base depicts a small tumor (arrow) in the nasal ridge surrounded by signal-free bone. **b** On the sagittal image obtained after contrast administration, there is a suggestion of a cutaneous fistulous tract (arrow) but no evidence for communication with the CSF space. **c** The T2-weighted axial image shows a small dorsal dimple of the tumor (arrow), indicating a possible communication with the intracranial space. Histological examination was compatible with a dermoid.



### Nasal Glioma

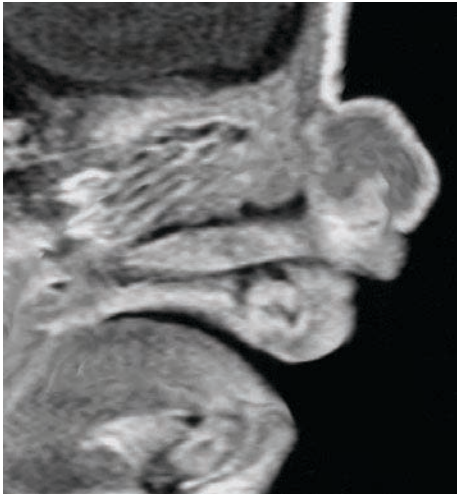


Fig. 13.4 The T1-weighted sagittal section after contrast administration demonstrates a tumor at the nasal base. A tract to the CSF space is not present. This is a nasal glioma.

### A Problem of the Grottos

Sid Cavern (54) has been sent to the radiology department by his doctor to get some sinus radiographs done. The clinician has treated him for a sinusitis for a little while and is worried now because the clinical symptoms have not changed at all despite prolonged therapy. Paul and Hannah are covering the bone unit today. Having gathered a little experience with these patients, they know that two types of radiographs are needed for the proper evaluation of the paranasal sinus: the Waters view (Fig. 13.5a) to see the frontal, ethmoidal, and sphenoid sinuses well and the Caldwell view (Fig. 13.5b) for the important maxillary sinus. The two interns analyze the radiographs of Mr. Cavern (Fig. 13.6). Alternatively, the paranasal sinus can be evaluated with a limited coronal CT. No intravenous contrast administration is needed for this test and a few representative cuts provide a good overview and can exclude a significant inflammatory abnormality. However, in the case of Mr. Cavern, the plain films are well executed and nicely display the pathological finding.

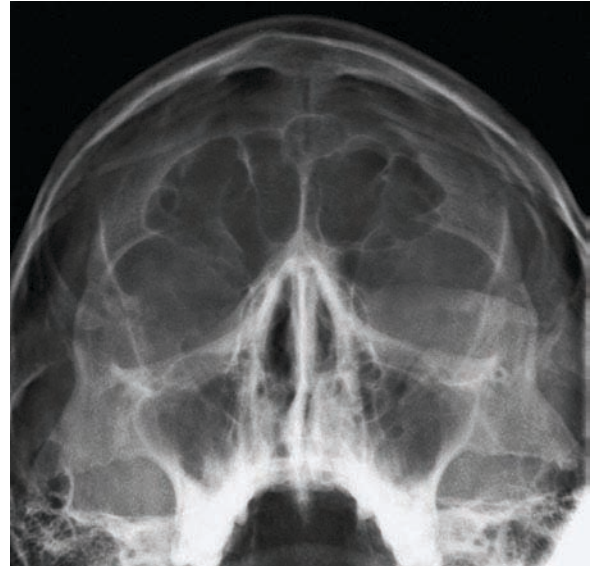
### Technique of Sinus Radiography (Caldwell and Waters Views)

a

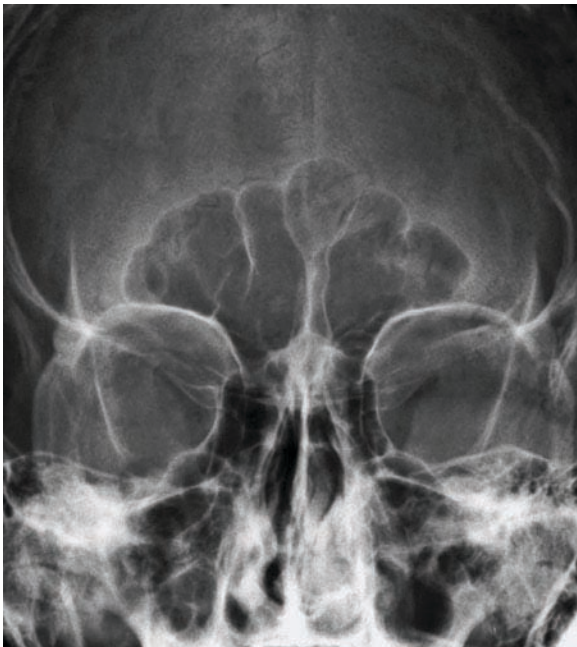

Fig. 13.5a The Caldwell view is obtained by placing the nose and forehead of the patient against the x-ray cassette and by tilting the tube caudally. The image depicts the frontal, ethmoidal, and sphenoid sinuses. The overlying petrosal bone masks the maxillary sinus. By the way, you can see the superior orbital fissure and the round foramen beautifully on this projection. Do you remember which structures run through these openings? b

b



The Waters view is obtained with the chin raised and placed on the x-ray cassette and with the nose 1–1.5 cm off the plate while the x-ray beam stands perpendicular to the cassette. In this projection the frontal and maxillary sinuses as well as the nasal cavity are well appreciated. In this patient there is a cutaneous swelling on the left due to trauma.

### The Case of Sid Cavern

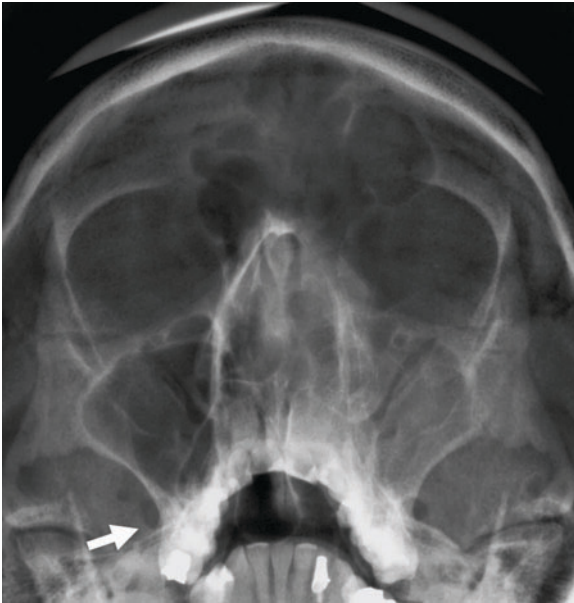


Fig. 13.6 There is loss of normal radiolucency of the left maxillary sinus. The nasal cavity also appears to be too dense. Is it also expanded? Just to bug you—the oval foramen is well visible on the right side (arrow). The small foramen spinosum immediately lateral to it makes it easy to differentiate from other openings. Which nerve runs through this foramen? Which CSF-filled structure lies directly behind it?

Of course, it is the mandibular division of the trigeminal nerve. And the trigeminal or gasserian ganglion lies behind it.

#### → What is Your Diagnosis?

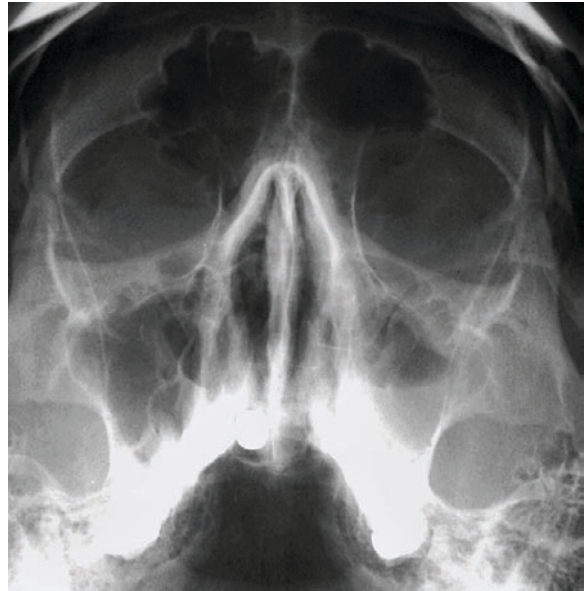##### Sinusitis:

**Acute sinusitis:** Acute sinusitis may go along with a collection of infected secretions in the sinus that can obliterate the sinus completely or partially—an air–fluid level may be visible on the sinus radiographs (Fig. 13.7a). Acute sinusitis is mostly viral in nature, but a dental cause must always be considered. If the dental abnormality is not treated or if the drainage of the paranasal sinuses is hampered—owing to stenosed ostia or chronically swollen mucous membranes—conservative therapy may fail. To evaluate which surgical procedure is best suited, a dedicated CT of the paranasal sinuses is necessary because it depicts the osseous septae and the soft tissues with superb clarity. If the sinusitis is left untreated or therapy is unsuccessful, extension into the facial soft tissues (Fig. 13.7b) is possible. If the infection reaches the orbit (Fig. 13.7c), damage to the optical nerve or the eye bulb may result. If the infection perforates into the cranial vault, the consequences may be fatal (Fig. 13.7d). Septic cavernous sinus thrombosis is another feared complication of any serious and long-standing infection in the nasal/paranasal tissues.

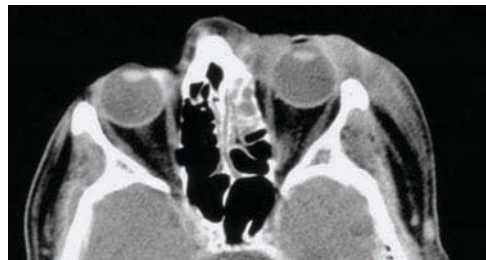**Chronic sinusitis:** Chronic sinusitis is the end result of recurring or therapy-refractory sinus infections (Fig. 13.8). If the perisinusoidal bone is sclerosed and the sinus itself has lost volume, this diagnosis can be made on the basis of imaging.

### Acute Sinusitis and Its Complications

#### a Acute maxillary sinusitis



#### b Perforation into the facial soft tissues



#### c Perforation into the orbit

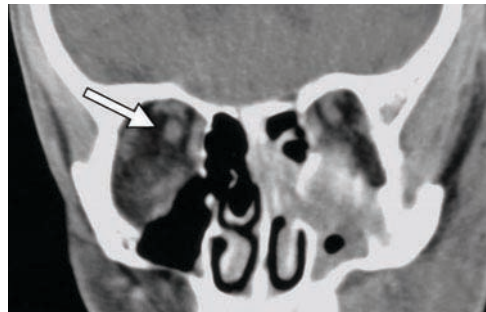


Fig. 13.7a The fluid level in the left maxillary sinus indicates sinusitis if the clinical symptoms fit. A fracture of the maxilla could, of course, also produce such a fluid level when bleeding into the sinus occurs. b The axial CT image through the orbits (note the eye lenses) demonstrates an infiltration of the left peri-orbital soft tissues as a consequence of a treatment failure in maxillary sinusitis. Nicely depicted are the medial and lateral ocular muscles as well as the course of the optic nerve on the right. c This coronal CT image through the posterior orbit—note the optic nerve (arrow) and the orbital muscles on the right—documents the extension of acute maxillary sinusitis into the orbit.



## Acute Sinusitis and Its Complications

### d Perforation into the intracranial vault

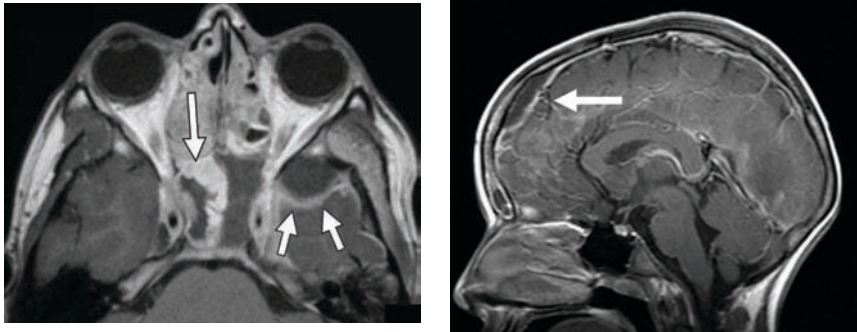


Fig. 13.7d The axial T1-weighted MR image (left) obtained after contrast administration (the content of the eye bulb is dark) shows fluid retention in both sphenoid sinuses with marked mucosal enhancement particularly in the right sinus (long arrow). There is an additional fluid pocket in the

temporal fossa (short arrows) that is surrounded by enhancing, swollen meninges. This is a potentially lethal epidural abscess associated with meningitis as a consequence of sinusitis! Note another frontal epidural abscess on the image to her again. The histological diagnosis a week later comes back from the laboratory as squamous cell carcinoma.

### Benign tumor:

**Retention cyst:** A retention cyst is a fluid-filled, slowly expansile mass arising from the paranasal mucous membranes that can be found in up to 10% of all adults (Fig. 13.9a). Most retention cysts remain clinically silent. They can occasionally erode bone. The cysts may grow out of the maxillary sinus through the ostiomeatal complex and become clinically apparent as choanal polyps.

**Osteoma:** This benign bone tumor tends to occur in the frontal sinus (Fig. 13.9b). The high density of the round or lobulated tumor on the radiograph makes this an easy and definite diagnosis.

**Juvenile angiofibroma:** Male adolescents may develop a juvenile angiofibroma (Fig. 13.9c). This arises in the pterygopalatine fossa and extends into the nasopharynx and can obliterate the sinus. Surgeons prefer embolization of this very vascular tumor prior to resection.

**Malignant tumor:** If conservative therapy fails or if there is radiographic evidence for osseous destruction (Fig. 13.10a), malignant processes need to be considered. To properly evaluate the extent of the tumor, the potential infiltration of vessels, nerves, muscles, and parotid glands as well as the lymph node status for subsequent therapy, MRI is the modality of choice (Fig. 13.10b). CT (with 3D reconstructions) is excellent for assessment of osseous structures and operative planning but lacks the superior contrast resolution for soft tissue structures that MRI has to offer.

→ **Diagnosis:** Hannah thinks that chronic sinusitis is the most likely diagnosis. Paul is bothered by the fact that Mr. Cavern has never had problems with his sinuses in the past. They are still discussing as Gregory happens to drop by on his way to the neurointervention suite. He observes that the nasal septum is destroyed and is also alerted by clinical history and the age of the patient:

“This is an aggressive process until proven otherwise, kiddos. Think cancer!” Hannah reluctantly agrees—she simply did not analyze the image with sufficient care. At a second glance it seems so obvious. This won’t happen to her again. The histological diagnosis a week later comes back from the laboratory as squamous cell carcinoma.

! Four eyes see more than two. To ask someone with more experience for help is not a sign of weakness ... on the contrary it is quite smart. For experienced radiologists it is an honor to help the neophyte—they tend to feel tickled—and you as the neophyte profit from it. But be warned: Radiology is a complex field. “Old hands” may also miss a thing or two—and they know it.

### Chronic Sinusitis

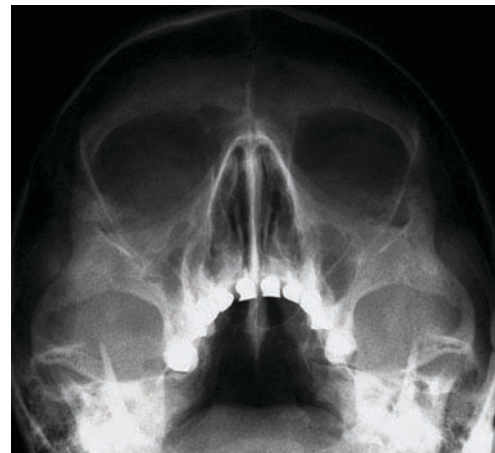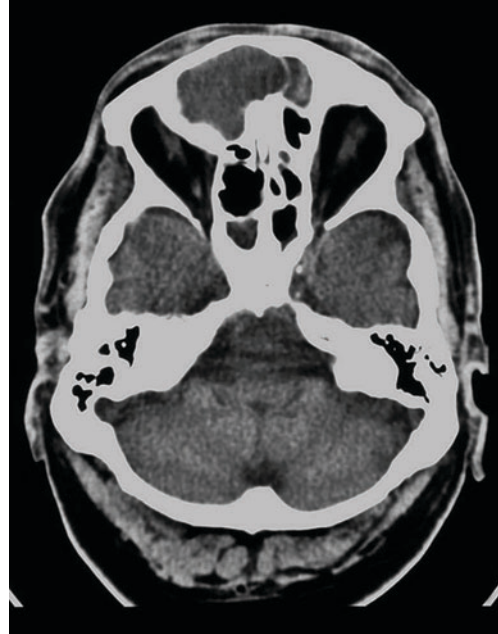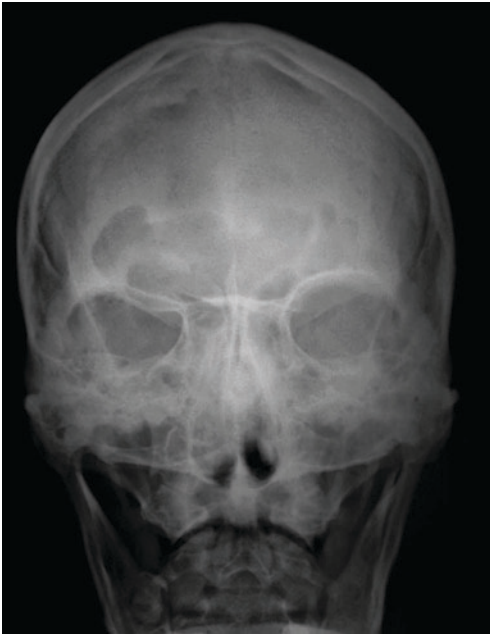


Fig. 13.8 This Waters view illustrates the sclerosis of the bone and volume loss in both maxillary sinuses in a patient with chronic sinusitis. The left frontal sinus is opacified; the right one is not seen at all.

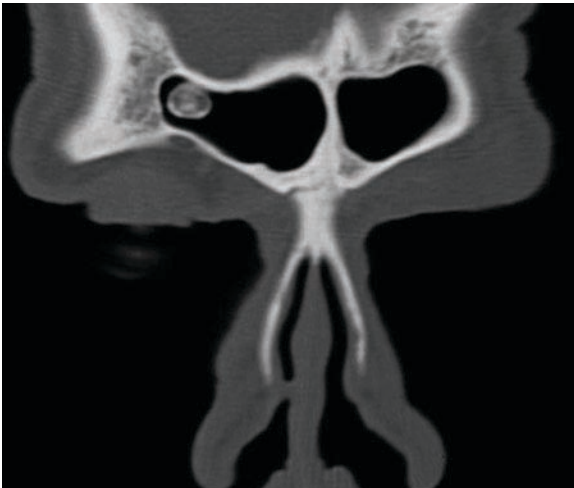


## Benign Tumor

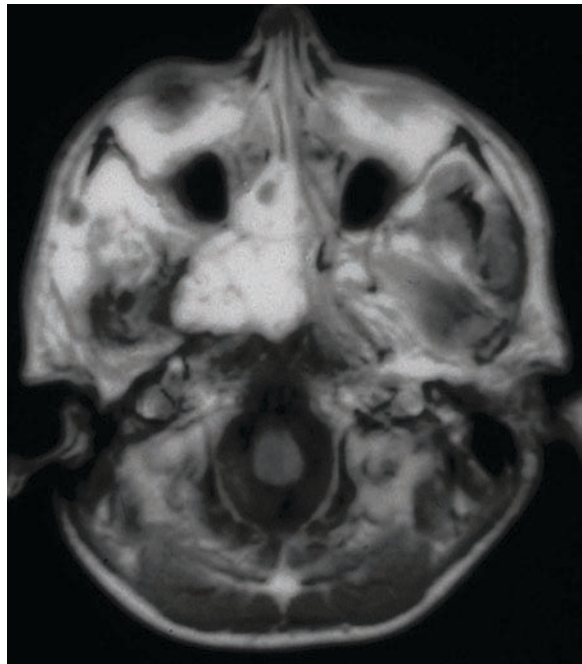
## a Retention cyst



## b Osteoma



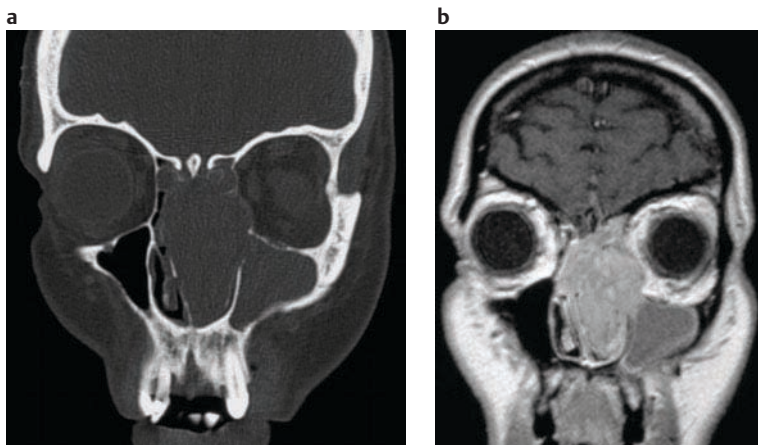
## c Juvenile angiofibroma



**Fig. 13.9 a** The anterior-posterior radiograph of the skull (left) documents an expansion of the right frontal sinus with sclerotic margins. The orbital roof is depressed; the left frontal sinus is obliterated. The axial CT image (right) confirms expansion of the right frontal sinus and shows an impressive deviation of the septum to the left. The cause of this is a retention cyst. **b** A coronal CT section displays a round body of osseous

density and structure in the frontal sinus, probably extending from the roof of the sinus. It is a typical osteoma. **c** The axial T1-weighted MR image obtained after contrast administration documents a large, nodular mass in the dorsal roof of the nasopharynx. This appearance, together with the clinical findings, is compatible with the diagnosis of a juvenile angiofibroma.

## Malignant Tumor



**Fig. 13.10 a** The left maxillary sinus and the nasal cavity are obliterated; the osseous nasal septum, the left sided conchae, and the medial orbital wall (also called lamina papyracea) are destroyed on this coronal CT image viewed in bone window settings. **b** On this coronal MR image after contrast administration, a homogeneously enhancing mass in the nasal cavity and its extension into the frontal sinus are shown. The maxillary sinus was, in retrospect, opacified secondarily to retention of fluid. Are you looking at a T1- or a T2-weighted sequence?

## 13.2 Disease of the Ears

## Checklist: Ears

- Is the mastoid sufficiently pneumatized?
- Are the cells of the mastoid obliterated?

## Lucky Song

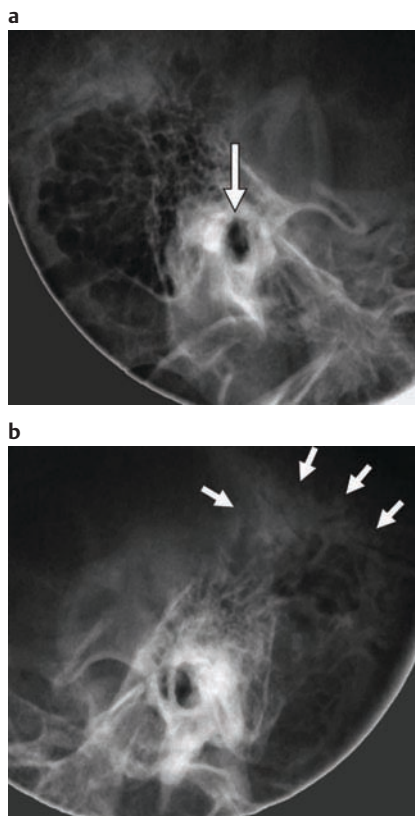
Carlos Antenna (32) has been fighting a middle ear infection for a couple of weeks. He suffers from pain and his hearing has decreased. He was a bit late to visit his ENT specialist because he has been traveling much lately for professional reasons. He has not really been taking his expensive antibiotics, either, because he left the package at home. Now another spike of fever has forced him to see his doctor again. The colleague immediately referred him to radiology for a radiograph. Hannah has a real close look at the Schüller view (Fig. 13.11).



## Do You Know about the Schüller Projection?

When performing a Schüller projection, the central x-ray beam (an imaginary line running from the focus on the x-ray anode to the center of the image) is in line with the external opening of the auditory canal of the imaged side. The extent of pneumatization of the mastoid, the distribution and degree of aeration of the mastoid air cells, and the contour of the porus acusticus can be evaluated very well. Dedicated thin-section temporal bone CT is the study of choice for complex problems.

## The Case of Carlos Antenna



**Fig. 13.11 a** On the symptom-free side, the mastoid air cells are pneumatized normally posterior and superior to the prominent porus acusticus (arrow), which is surrounded by dense bone. Directly anterior to the porus, the mandibular condyle is seen in its articular niche. The faint arching structure a little above and anterior to the temporomandibular joint is the auricle, which is bent forward for this examination. **b** On the symptomatic side, the upper part of the mastoid is attenuated, which indicates a filling of the air cells with reactive secretions or pus (arrows).

## Air in the Mastoid?

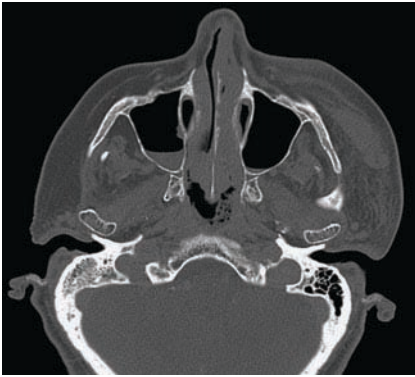

Fig. 13.12 This patient shows a significantly decreased pneumatization of the mastoid air cells on the right side. Middle-ear infections are much more frequent in this setting. The fluid levels in both maxillary sinuses in this patient were due to trauma.

→ **Diagnosis:** The radiological findings in Mr. Antenna's radiograph confirm the clinical impression of a mastoiditis as consequence of a prolonged middle ear infection. Because of the long duration and Mr. Antenna's fever spikes, the decision is made to perform MRI to exclude extension of the process into the cranial vault. Mr. Antenna finally comes to terms with the gravity of the situation and is quite relieved when the MRI turns out to be normal. He promises to closely follow his doctor's advice in the future. Hannah remembers patients with similar problems she has seen in the weeks gone by. She recalls a CT of another patient that showed significantly reduced pneumatization of the mastoid air cells (Fig. 13.12) due to recurrent past ear infections in younger years. She also reminds herself of patients in whom the diagnosis was made by MRI (Fig. 13.13a) and where events took a dramatic turn for the worse (Fig. 13.13b).

## 13.3 Diseases of the Temporomandibular Joint

**Checklist:** Temporomandibular Joint (TMJ)

- What is the relative position of the dorsal disk to the mandibular condyle?
- Does it glide along during mouth opening?
- Is the appearance of the mandibular condyle symmetric?

**Chewing and Problem Solving**

Isabella Nutcracker (41) is passing through a very exciting phase in her life as an engineer. During her nerve-wracking work in the Sydney cross-city tunnel project she has now developed an excruciating pain in her right facial half. She feels a click when opening her mouth. The head and neck surgeon has sent her for a dedicated functional MRI of the temporomandibular joint to establish the cause of her suffering. Giufeng covers the MRI unit today and is—as usual—very well prepared for the examination.

**What Does Giufeng Know about the TMJ?**

She knows that the joint consists of two distinct compartments that are divided by a disk with a dumbbell-like configuration. The disk is suspended by ventral and dorsal ligaments and translates the force from the mandibular condyle to the articular tubercle of the temporal bone. As the mouth is opened, the condyle slides out of the mandibular fossa underneath the articular tubercle. If the mouth is closed, the dorsal part of the disk stands in the 12-o'clock position

## Complications of Otitis Media

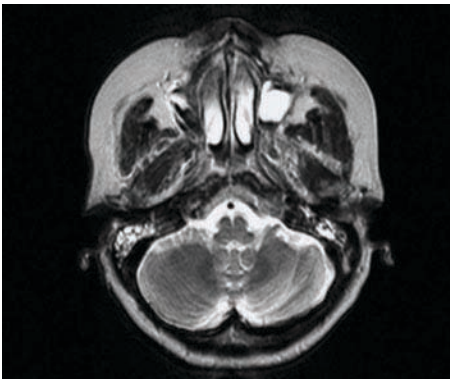
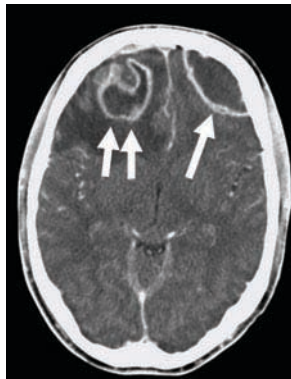
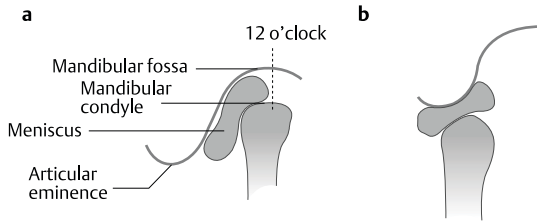
**a Mastoiditis****b Brain abscess**

Fig. 13.13a The axial T2-weighted MRI section through the mastoid shows fluid on both sides. This is indicative of mastoiditis. The patient also presented with the symptoms of middle-ear infection. As an unrelated finding the study shows a reten-

tion cyst in the left maxillary sinus. **b** In another patient the middle-ear infection has perforated into the cranial vault. An acute and potentially lethal epidural (long arrow) and even an intracerebral abscess (short arrows) have resulted.



relative to the mandibular condyle (a); as the mouth is opened it moves to the top of the condyle (b). The mandibular condyle may be hypoplastic, the joint may show degeneration. Bear in mind the enormous forces that the small temporomandibular joint must withstand—that explains why this joint is so prone to developing problems.



Giufeng reviews Mrs. Nutcracker's MRI looking separately at each side with the mouth opened and closed (Fig. 13.14).

#### → What is Your Diagnosis?

**Luxation:** In *fixed luxation* the disk remains anterior to the mandibular condyle no matter whether the mouth is open or closed, and it is frequently compressed (Fig. 13.15a). There are also patients with *intermittent luxation* in whom the disk slides into its normal position when the mouth is opened (Fig. 13.15b).

→ **Diagnosis:** The findings are clear in our engineer's case. Both mandibular condyles show a normal configuration. Giufeng diagnoses a fixed luxation of the disk on the right side. She could not find an abnormality on the left. Now the head and neck surgeons must do what they can to give the tunnel project a real shove.

## 13.4 Injuries and Diseases of the Orbit

### Checklist: Injuries and Diseases of the Orbit

#### Injuries

- Are there intraorbital metallic foreign bodies?
- Are the osseous orbital structures intact?

#### Masses

- In which compartment (bulb, orbit, skull base, pre-septal or postseptal space) is the mass located?
- Does the mass displace or infiltrate the neighborhood?
- Is there a known primary malignancy?

### The Case of Isabella Nutcracker

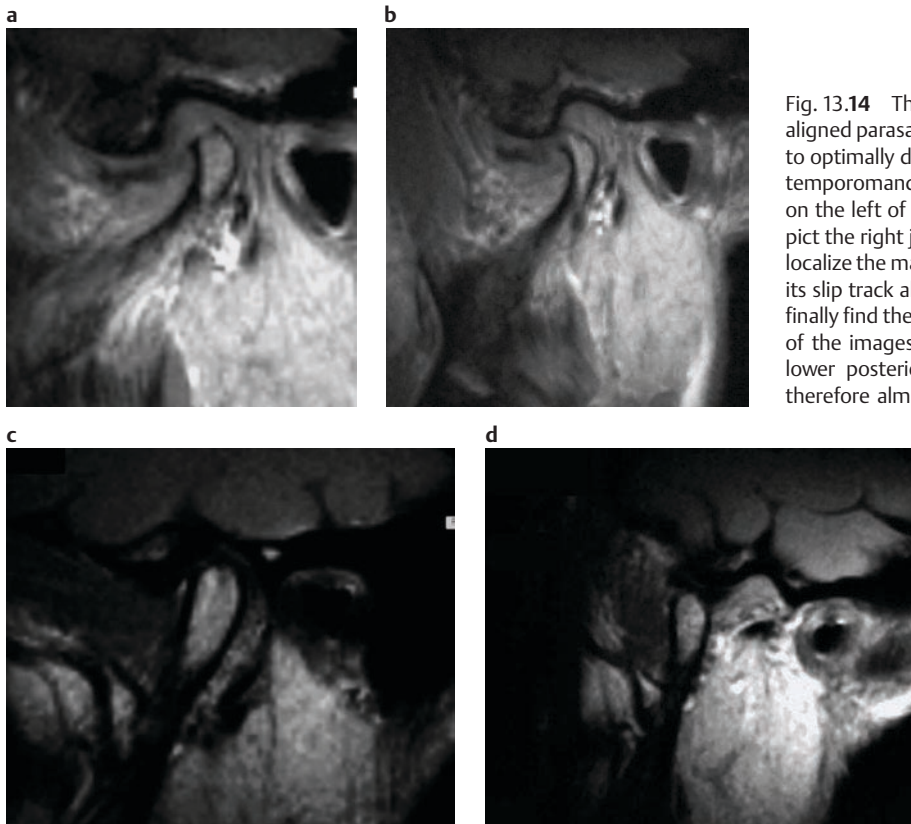
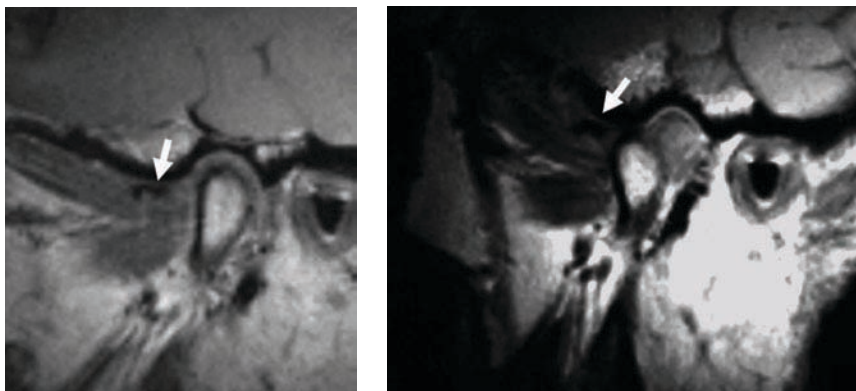


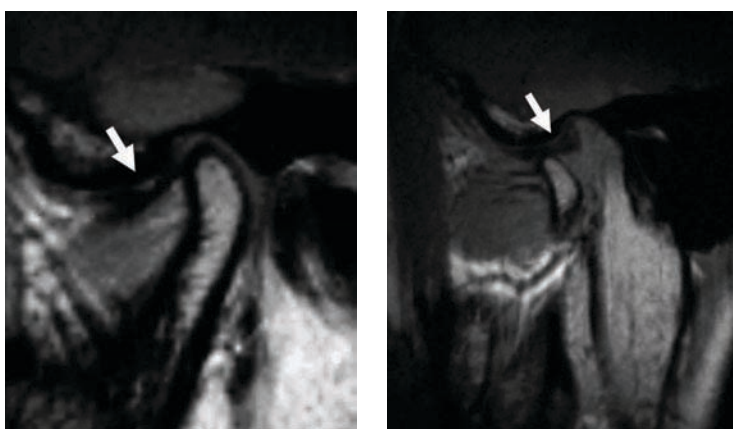
Fig. 13.14 The images of this study are aligned parasagittally at a slight angle in order to optimally demonstrate the function of the temporomandibular joint. The ventral side is on the left of the image. Images a and b depict the right joint, c and d the left joint. First localize the mandibular condyle, then identify its slip track along the articular tubercle, and finally find the low-signal disk. The upper part of the images shows the temporal lobe, the lower posterior part the pneumatized and therefore almost signal-free mastoid.

## Dislocation

### a Fixed dislocation



### b Reducible dislocation



**Fig. 13.15 a** This disk (arrow) is identified ventral to the mandibular condyle no matter whether the condyle is in the mandibular fossa when the mouth is closed (left) or whether it sits under the articular tubercle when the mouth is open (right). **b** This disk (arrow) is seen anterior to the mandibular condyle (at about 10 o'clock) when the mouth is closed (left). It is subluxed anteriorly. As the mouth opens (right) it assumes its normal translational position between the mandibular condyle—which has now moved ventrally—and the articular tubercle.

### Teamwork

Alfried von Trupp und Stahlbach (56) is well known in the world of abstract art for his large, sophisticated stainless-steel sculptures. While he was putting the finishing touches to his latest project “Grand Onlooker” with an angle grinder, his protective goggles fell off and a metallic splinter flew into his eye. The ophthalmologist on call was unable to determine the precise location of the splinter during the ocular examination. His chairman—a great lover of the arts himself—was called but also failed to see the foreign body clearly enough. Joey reviews the orbital radiographs on which the little metal chip is identified very well (Fig. 13.16a). MRI is clearly not the modality of choice to establish the precise location of a metallic foreign body—that much he knows. The metallic fragment would be dislodged by the strong magnetic field and further harm would come to the eye. The CT of the orbit (Fig. 13.16b) displays the foreign body quite well, despite the artifacts, but the eye surgeons feel that its location relative to the lens and the bulbar axis is still not clear enough for a straightforward atraumatic removal. They ask for a radiograph according to *Comberg*, which is a dedicated

examination developed specifically for the purpose of localizing intrabulbar metallic foreign bodies. Now it's Mrs. Koch's turn: she is the most veteran and experienced x-ray technician and she performs the study meticulously under the eager eyes of the whole team (Fig. 13.16c). Joey lends her a hand. Have a look at the radiograph. Can you indicate the exact location of the foreign body on the schematic drawing (Fig. 13.16d)?

! An experienced, dyed in the wool, motivated x-ray technician is a true treasure. If you show your appreciation of and interest in their work they will support you in your work, too.

### That “Evil” Stare

Loretta Hotblood (45) has developed the “evil stare” as she calls it herself. She has noticed that her eyes protrude from the orbit, more so on the right than on the left. In addition, she has difficulties closing her eyelids, which is why her eyes have a tendency to feel dry. Apart from the reactions of other people on the bus and at

The Case of Alfried von Trupp und Stahlbach

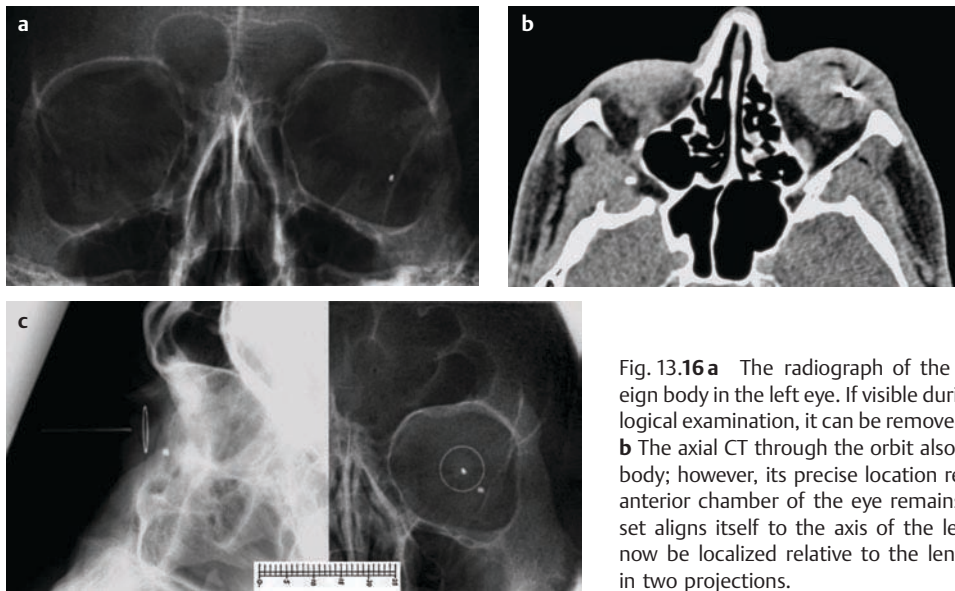
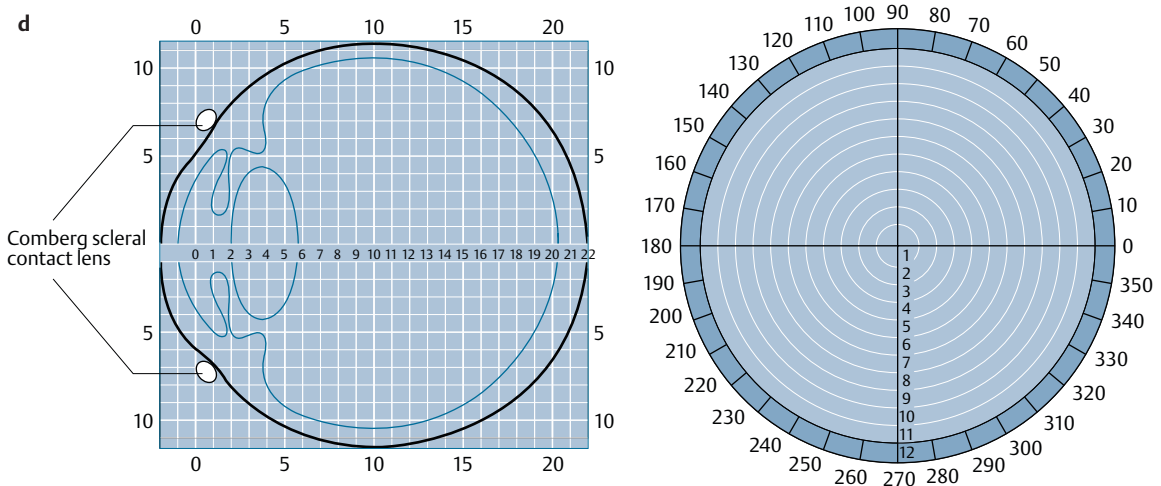


Fig. 13.16 **a** The radiograph of the orbit clearly shows a foreign body in the left eye. If visible during the clinical ophthalmological examination, it can be removed without further imaging. **b** The axial CT through the orbit also demonstrates the foreign body; however, its precise location relative to the lens and the anterior chamber of the eye remains unclear. **c** The Comberg set aligns itself to the axis of the lens. The foreign body can now be localized relative to the lens axis and the metal ring in two projections.



**d** The metal ring of the Comberg set is indicated in the drawing on the left. The axis of the Comberg set corresponds to the center of the circle on the right drawing. Now go ahead and sketch the foreign body into the diagram.

work, she is bothered particularly by increasing double vision. Her visual acuity has also dwindled. The endocrinologist has diagnosed an endocrine orbitopathy, but conventional therapy has so far not led to any substantial improvement. For that reason, additional radiation therapy is being contemplated. Before this procedure, MRI is indicated to verify the diagnosis, to exclude other causes of exophthalmos, to rule out a potential compression of the optical nerve, and to document the pretreatment status. Paul and Joey cover the examination and analyze the images (Fig. 13.17). They know they have to carefully exclude the presence of a number of tumors that may cause exophthalmos.

→ What is Your Diagnosis?

**Endocrine ophthalmopathy:** In endocrine orbitopathy (or Graves disease) the orbital muscles enlarge. The volume of the intraorbital fat increases as well (Fig. 13.18).



Things You Can Learn from Graves

Graves was the Irish doctor who first described endocrine ophthalmopathy in 1835 and also one of the first bedside teachers. He was an extraordinary man, his linguistic talents being so extreme that he was taken in custody as a **German spy** in Austria for two weeks when traveling there without proper identification. On another journey, in the Mediterranean, he



### The Case of Loretta Hotblood

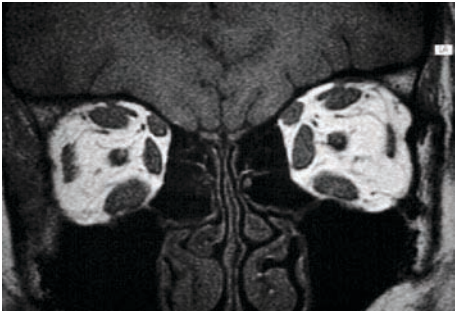


Fig. 13.17 This MRI sequence with enhancement of the orbital fat depicts a coronal image directly posterior to the eyeball.

saved a ship and its rebellious crew by taking over command during a storm. The ship suffered a leak, the pumps broke down, and the crew attempted to abandon ship. Graves destroyed the only lifeboat with an axe and repaired the pumps with leather from his own shoes, and all aboard survived. No doubt you know institutions that could do with formidable men like that today.

**Carotidocavernous fistula:** An exophthalmos may also be caused by a carotidocavernous fistula (Fig. 13.19a). This

### Endocrine Ophthalmopathy

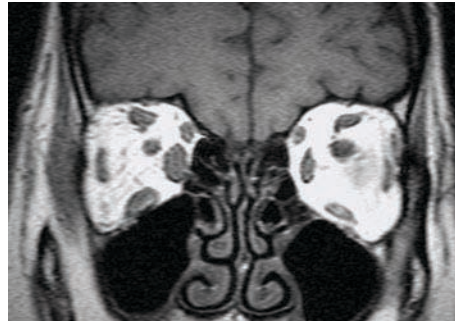


Fig. 13.18 The coronal T1-weighted MR image through the orbit demonstrates very well the centrally located optic nerve and the enlarged ocular muscles on the left—a typical finding in endocrine ophthalmopathy.

entity is a posttraumatic or an idiopathic communication between the carotid artery and the venous cavernous sinus that may have a direct mass effect on the retrobulbar orbit and cause locoregional venous hypertension. Prominent filling of the conjunctival vessels and a vascular bruit detectable by auscultation with a stethoscope are pathognomonic. Interventional radiologists have the opportunity to solve this problem with bravery. After documen-

### Carotidocavernous Fistula

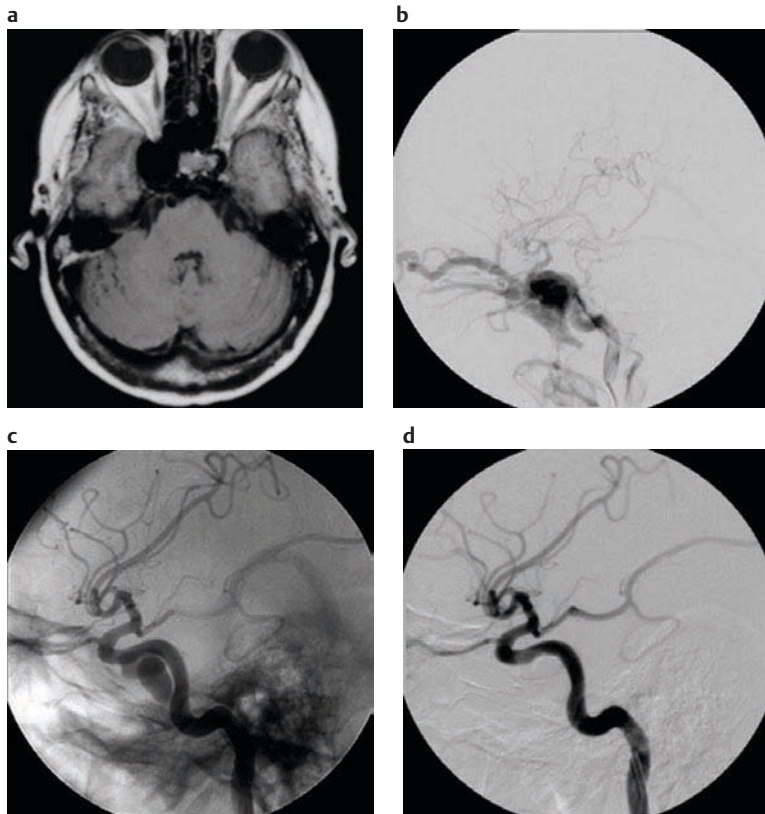


Fig. 13.19 **a** This T1-weighted MR image of the skull base displays a large signal-free structure posterior to the right orbit. It is a large vessel segment that certainly does not belong there. **b** A subtraction angiography is performed by administering contrast via a catheter into the right common carotid artery—you can see the catheter tip—and subtracting the precontrast image from the postcontrast images. An enormous dilatation of an artery in the cavernous sinus with early venous drainage is documented. This is indicative of a carotidocavernous fistula. **c** To close the fistula, it is filled with detachable balloons. The rest of the vascular lumen will hopefully thrombose later, but the early venous drainage has already stopped. **d** After the intervention, the subtraction shows a normalized vascular flow.

### Meningioma

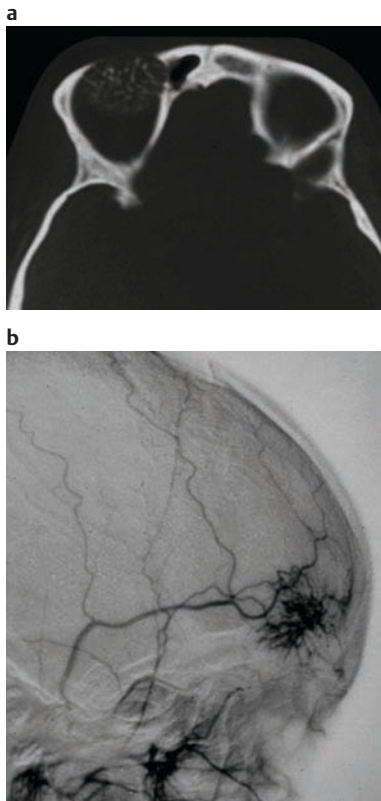


Fig. 13.20 **a** Review of this head CT in bone windows shows a bizarre calcification below the orbital roof. This is suggestive of a meningioma because these tumors tend to calcify in such a fashion. **b** Angiography reveals the typical spoke-wheel-type vascular pattern of a meningioma.

tation of the large-caliber fistula (Fig. 13.19b), detachable balloons can be introduced through a catheter (Fig. 13.19c), filled in situ, and left behind, occluding the fistula.

**Meningioma:** This benign tumor originates from the meninges and is often found adjacent to the sphenoid bone or the orbital roof. It frequently calcifies (Fig. 13.20a) and enhances strongly after contrast administration in a typical

### Lymphoma of the Skull Base

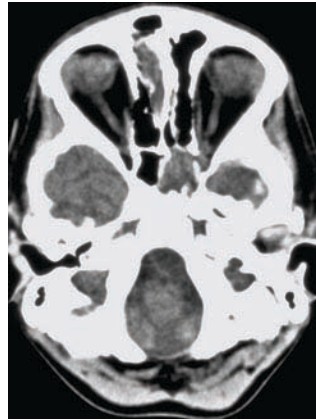


Fig. 13.21 This patient complained of an acute decrease of visual acuity on the left. The axial CT section displays the tumor, which extends from the sphenoid sinus into the left orbit and (on other slices) into the optic canal.

spoke-wheel fashion (Fig. 13.20b). If surgical removal is contemplated, a preoperative embolization of the richly vascularized tumor by the interventional radiologist is often requested—this time of course not with balloons but with coils or small particles that get caught in the capillaries of the tumor.

**Metastases/lymphoma:** Metastatic disease and lymphoma must always be considered in the differential diagnosis (Fig. 13.21). They often display infiltrative and destructive growth. In Mrs. Hotblood's case, breast carcinoma would be the most likely primary tumor.

**Osteopetrosis:** Osseous expansion of the orbit and the sphenoid bone may also cause a protrusion of the eye bulb. This is seen with osteopetrosis (or “marble bone disease” [Fig. 13.22; see also Fig. 8.30c, p. 137]) and Camurati-Engelmann disease (see Fig. 8.30d, p. 137), where the bones become denser and enlarge over time. Both diseases are normally diagnosed during childhood. The cranial foramina become progressively narrowed, often resulting in cranial nerve palsy. Involvement of the optic nerve is particularly precarious and is not uncommon.

### Osteopetrosis

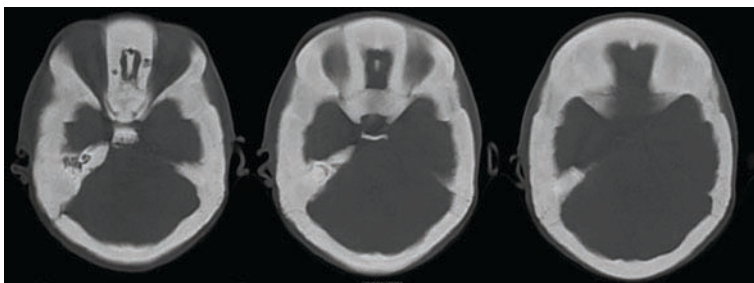


Fig. 13.22 The bone windows of this cranial CT show an enormous increase in density and volume of the bone. It is obvious that the osseous foramina will eventually be so narrow that compression of the respective central nerves is inevitable and that the eyeball will be forced out of the orbit.

## Plexiform Neurofibroma

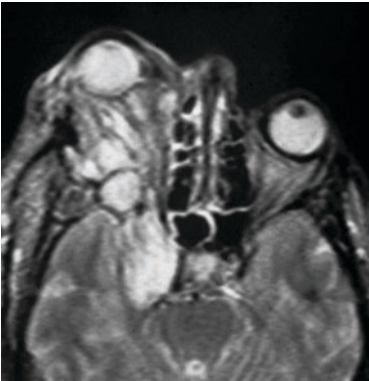


Fig. 13.23 The axial T2-weighted MR image demonstrates a large mass at the skull base that has invaded and filled up most of the orbit. It presents with a high signal and a nodular structure—a typical pattern for a plexiform neurofibroma.

**Plexiform neurofibroma:** Finally, a plexiform neurofibroma of the orbit is one of the hallmarks of neurofibromatosis (Fig. 13.23). It manifests during late childhood and frequently also involves the eyelids and the other neighboring soft tissues.

→ **Diagnosis:** On the basis of clinical history and the MR images, Paul and Joey favor typical endocrine ophthalmopathy as the diagnosis. They are right. Radiation therapy may start now.

## 13.5 Diseases of the Neck

## Checklist: Neck Masses

- Is the tumor solid or cystic (centrally necrotic)?
- Is the tumor solitary?
- Does its location correspond to the typical lymph node sites?
- Which anatomical structure does it originate from?

## One Swelling Too Many

Sylvester Mascarpone (35) has recently noted a swelling on the right side of his rather muscular neck. The swelling does not hurt, but the cosmetic asymmetry bothers him quite a bit. He smokes a Havana cigar every evening while sitting in front of the fireplace, which is a habit his friends at the gym like to tease him about. Joey helps him to find a comfortable position inside the MRI gantry. Mr. Mascarpone has been a little claustrophobic since he was trapped for three hours in a defective metal costume during filming of his last blockbuster film. Joey explains the course of the examination to him once again, slowly administers half an ampule of diazepam intravenously, and puts a light, bright cloth over the patient's eyes. He also sits down at the other end of the MRI gantry to remain close to the patient. Afterwards, Paul and Joey look at the images together (Fig. 13.24). They discuss the potential diagnoses.

## → What is Your Diagnosis?

**Malignant tumor:** In smokers, malignant tumors of the face and neck are frequent (Fig. 13.25a). Often they are diagnosed by the patient or clinically before any abnormality can be verified with imaging modalities. This

## The Case of Sylvester Mascarpone

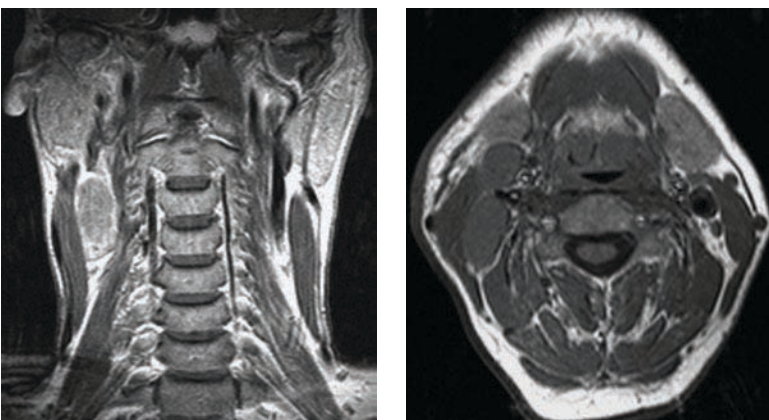
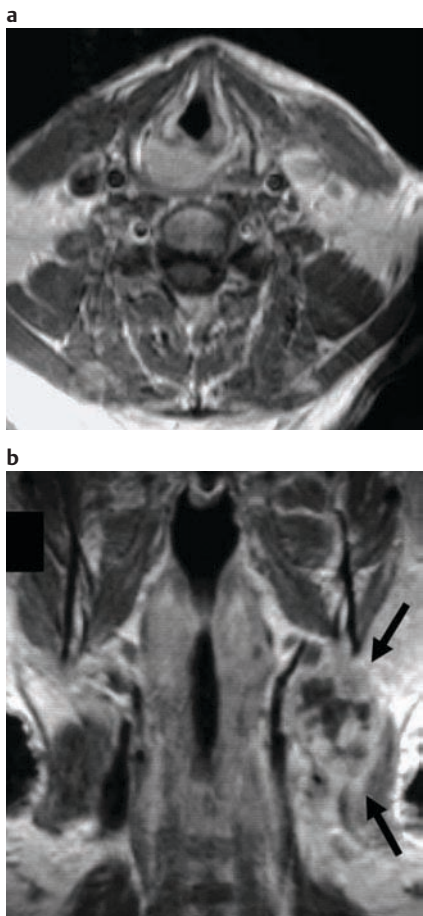


Fig. 13.24 These are the relevant coronal (a) and axial (b) MR images of Mr. Mascarpone. Do you see an abnormality?



### Malignant Tumor of the Head and Neck



**Fig. 13.25 a** Contrast-enhanced axial T1-weighted MR imaging shows the approximate level of the vocal cords. The enhancing mass posterior to the airway causes an obvious asymmetry—an essential radiological observation in the complex head and neck area. This proved to be a carcinoma of the hypopharynx. **b** The enlargement and peripheral irregular contrast enhancement of a left-sided regional lymph node (arrows) lateral to the signal void of the carotid artery on this T1-weighted image proves the regional lymphatic spread. For your orientation: in the middle of the image you see the airway; cranially on both sides at a distance the relatively signal-free mandibular bone with the masseter muscle lateral and the pterygoid muscle medial to it.

is particularly true for tumors of the oral cavity. Parotid tumors are also often first noticed by the patients themselves. Histopathological examination is required in most cases before a treatment decision can be made; biopsy is facilitated by ultrasound guidance in deep lesions. MRI is the most comprehensive modality to evaluate the local extent and regional lymph node involvement (Fig. 13.25b) in patients with head and neck cancer.

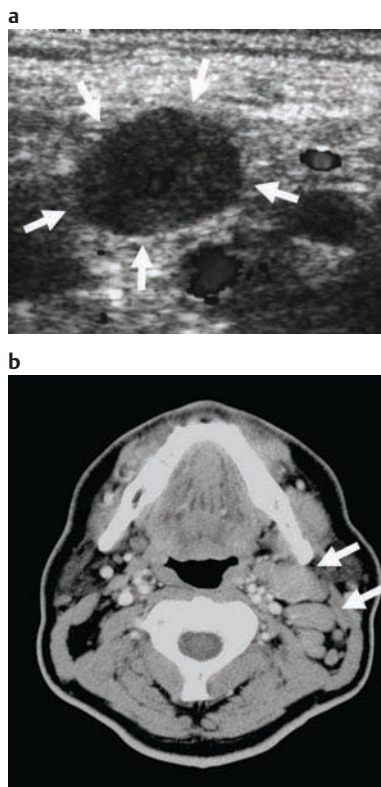
**Lymph node enlargement:** Lymphadenopathy may be due to lymphoma, metastatic disease, or reactive inflammation, for example, in tuberculosis. An ultrasound examination (Fig. 13.26a) with subsequent removal of a tissue core

by needle biopsy helps obtain a tissue diagnosis. If lymphoma is diagnosed, staging is best complemented by CT (Fig. 13.26b).

**Cervical cysts:** Congenital malformations such as lateral or median cervical cyst can cause swelling in the cervical region. The *lateral cervical cysts* or *branchial cleft cysts* (Fig. 13.27) are remnants of the embryonal set of gills. They are located lateral to the jugular vein and dorsal to the submandibular salivary gland. They often become clinically apparent when an acute inflammation develops inside. A fistulous connection of the cysts to the skin surface may form and prompt a search for the underlying etiology. *Median cervical cysts* originate from remnants of the thyroglossal duct, particularly at the base of the tongue. Clinically the tumor is soft and elastic and moves during swallowing.

**Paraganglioma or glomus tumor:** Any pulsatile mass of the neck is diagnosed and treated with special caution. A premature core needle biopsy may result in severe hemorrhage. Paragangliomas arise from extra-adrenal

### Lymphadenopathy in the Head and Neck Region



**Fig. 13.26 a** Ultrasound shows a significantly enlarged lymph node (arrows) in the direct vicinity of the jugular vein. The Doppler signal helps distinguish vessels inside the node and in its neighborhood. This patient had a lymphoma. **b** The CT demonstrates the whole extent of the lymphatic spread dorsal to the mandibular angle (arrows). Multiple nodes of different size are seen. CT of chest and abdomen was subsequently performed for complete staging.

## Lateral Cervical Cyst

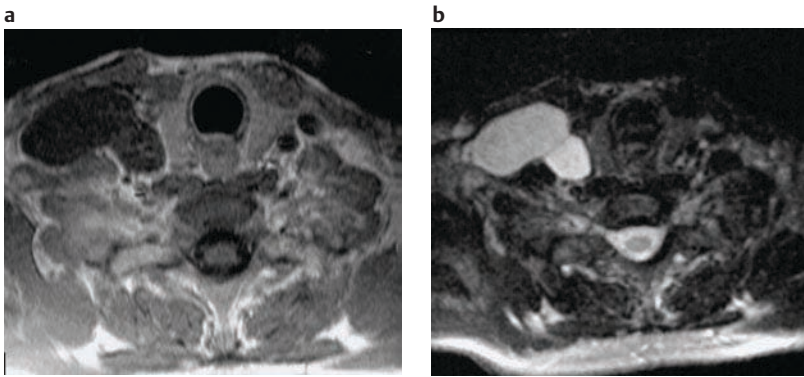


Fig. 13.27 **a** The axial T1-weighted MR image displays a lesion in the right anterolateral cervical soft tissues, nearly homogeneous and low in signal. **b** The T2-weighted, fat-saturated image confirms the cystic character of the mass (fat saturation is incomplete in the posterior subcutaneous fat for technical reasons).

## Paraganglioma

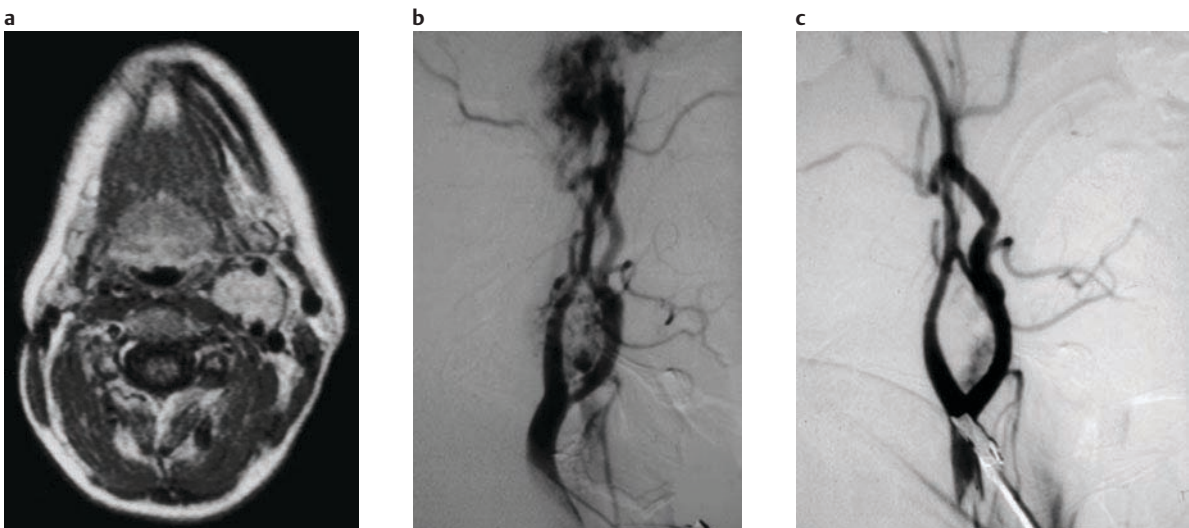


Fig. 13.28 **a** A strongly contrast-enhancing mass in the left carotid bifurcation is visible in this axial MRI section of the tongue base. **b** Selective angiography with the catheter tip in the left common carotid artery documents several well-vascularized tumors at the bifurcation and the skull base. **c** After embolization with small particles via a branch of the external carotid artery, the vascular blush is gone and chances for a safer and effective curative surgical procedure are greatly improved.

portions of the sympathetic nervous system. They can arise at different levels along the cervical vascular bundle. In Mr. Mascarpone's case a paraganglioma of the carotid bulb would need to be considered. Cervical paragangliomas are typically located at the carotid bifurcation and enhance intensely after contrast administration (Fig. 13.28a). Because the lesion is very vascular, a preoperative embolization via the branches of the external carotid artery is often requested by the surgeons (Fig. 13.28b, c).

**Arteriovenous fistula:** Aneurysms or an arteriovenous fistula can also cause a pulsatile mass or bruit anywhere in the body. If the fistula has a large caliber, the arteriovenous

shunt volume may induce high-output cardiac failure. The documentation of an arteriovenous fistula (Fig. 13.29a, b) and frequently also its therapy—embolization with balloons or metallic coils (Fig. 13.29c)—is performed by the radiologist.

→ **Diagnosis:** Joey and Paul have made up their minds. This is definitely a lateral cervical cyst in a typical location. The patient is visibly relieved by the good news. His sedation makes it necessary to keep him in the unit him for a little while before his driver can take him back to the Park Hyatt in his turbo-charged Humvee. The head and neck surgeons will take care of him in due course.

**Arteriovenous Fistula**

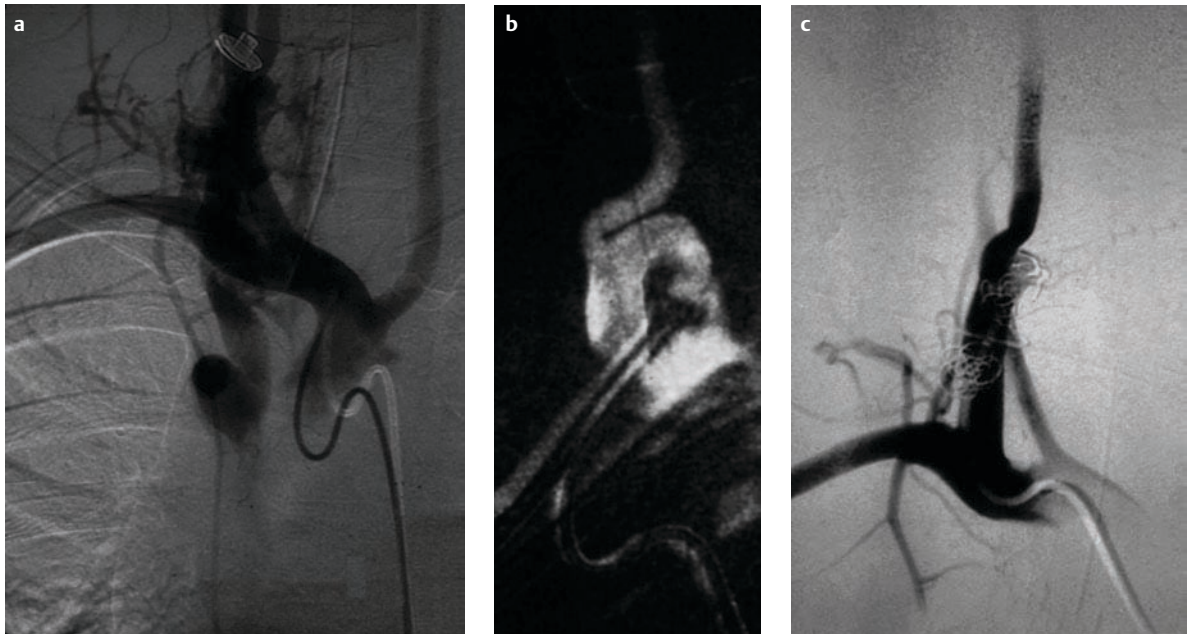


Fig. 13.29 **a** Angiography with the catheter tip in the brachiocephalic artery illustrates the immediate venous shunting into the azygos vein system (at the orifice into the vena cava, the contrast medium is diluted). The first segment of the vertebral artery is significantly dilated by the increased blood flow; its caliber resembles that of a large carotid artery. **b** Selective

angiography using an individually angulated projection and with a catheter in the vertebral artery orifice depicts the arteriovenous fistula to its best advantage. The vessel running cranially is the normal segment of the vertebral artery. **c** After embolization of the fistula with metallic coils, normal anatomical blood flow is restored.

**13.6 The Teeth You Need**

Hank Colgait (35) has been sent by an oromaxillofacial surgeon. Lately he has felt a painful swelling in his left mandibular angle during eating. The colleague has asked for an orthopantomograph (OPG). Orthopantomography is a dedicated and technically sophisticated tomographic technique in which tube and film cassette rotate around the head of the patient. Greg reviews the film (Fig. 13.30) and asks our students to have a good look themselves. This patient, he says, has a whole number of diagnoses. Apart from a maxillary fracture about 20 years ago and the loss of several teeth in the course of time he also has:

- A granuloma of the dental radix
- One impacted and another normal “wisdom tooth”

- One intact and one amputated dental bridge and
  - The reason for Mr. Colgait’s pain
- Our students grab the form and assign their observations to the respective teeth. Do you want to have a go at it also?

Maxilla	18 17 16 15 14 13 12 11	21 22 23 24 25 26 27 28
Mandible	48 47 46 45 44 43 42 41	31 32 33 34 35 36 37 38
	Right	Left

Have you sorted it out? The correct answers are found on p. 342.



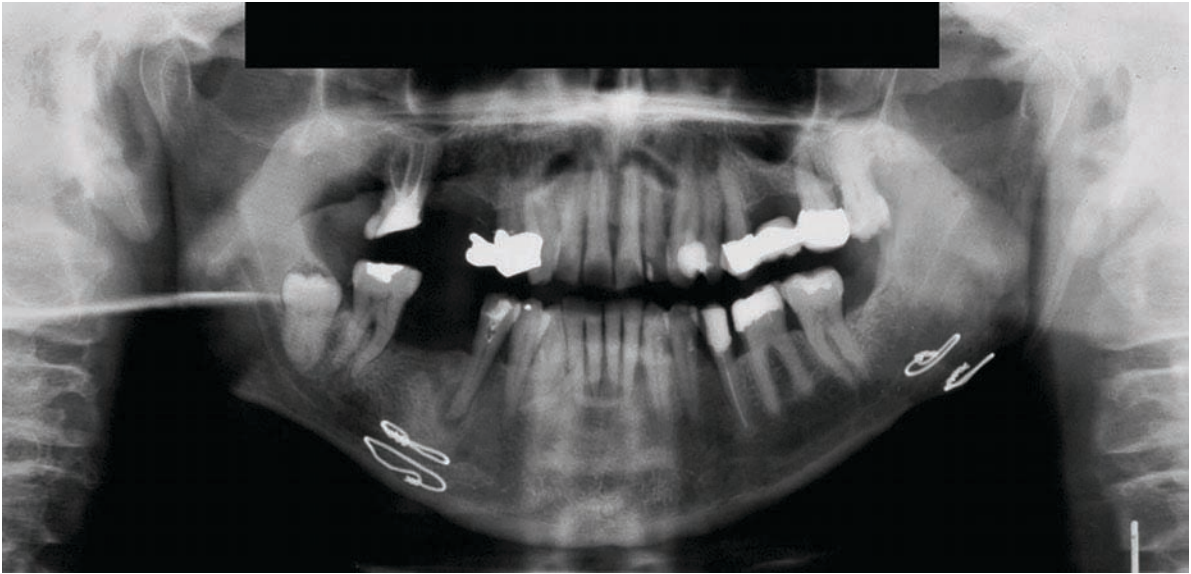
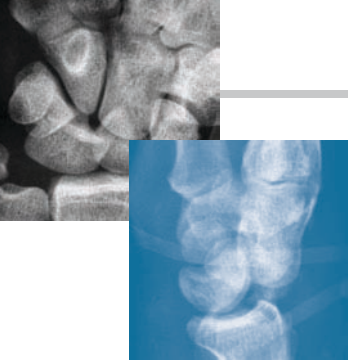**Assign the Findings!**

Fig. 13.30 Orthopantomography is performed with a sophisticated and dedicated tomography unit. The cooperation and positioning of the patient are crucial. Evaluate the whole set of teeth and also the osseous components of the tempo-

mandibular joint. The cervical spine is visible laterally on both sides. Now assign the findings to the individual teeth using the scheme (see the text). Just one hint at the beginning: tooth 47 and tooth 32 are reasonably normal candidates of their kind.



# 14 Trauma

In no other field of medicine can we help so much and so rapidly as in trauma medicine. If you have ever seen the metamorphosis of a beaten-up, lifeless, pale human body back into pink pulsating life—all this under the experienced hands of a crowd of swiftly working, focused, and coordinated specialists—you know why the medical profession is a worthwhile one. And if you hear the same patients tell you half a year later that they have been able to resume their private life and pick up their professional activities again, you get an impression how important the flawless functioning of emergency medicine and trauma care is for the society as a whole. Imaging plays a central role in this scenario, which is also called the “Golden Hour.” It can contribute to efficient management of the acutely injured patient more than anywhere else.

## 14.1 Polytrauma

Hannah, Giufeng, Paul, Ajay, and Joey are quite satisfied with their stint in radiology. As has become the custom, they have invited the department in which they have learned and done so much for a “wine and cheese” event. It is 3 p.m. on Friday, the last working day before a much-needed long summer vacation starts in the schools. The usual hustle and bustle in the department has died down a little earlier than on other days. Who wants to get sick on a day like that anyhow? The mood is cheerful. Paul jokes around with Greg, for the very first time. The chairman also doesn’t want to miss this event and is keen to have one of those fresh kangaroburgers Paul has organized from the delicatessen shop down the

street. He is about ready to address our students in a little thank-you speech as an x-ray technician from emergency radiology rushes into the room. The emergency room just got a distress call from an ambulance driver over the radio: there has been a mass collision on the north-bound highway 30 miles out of town; several trucks and early vacationers are involved. The first ambulance helicopter teams on the site estimate that there are more than a dozen severely injured people. All available city ambulances are on their way to the highway collision. The necessary measures within the department are rapidly initiated. All workers of the early shift will stay in-house until the dust has settled. Hannah, Paul, and Ajay are assigned to one CT each; Joey and Giufeng are sent to the emergency radiology unit and the resuscitation room. There an expectant silence has taken hold of the teams. Everyone waits. The air above the hospital starts to whirr from the incoming helicopters.

### Patient A

Five minutes later, the first severely traumatized patient (A, name unknown, male, approx. 50 years old) is rushed from the helicopter pad into the resuscitation room. He is intubated, several peripheral large bore i.v. cannulas have been placed and he has already been defibrillated once. He wears a protective neck collar and has received quite a lot of i.v. fluid. Many things happen in parallel now (Table 14.1). While radiographs of the chest, the lateral cervical spine, and the pelvis are performed, Giufeng—wrapped in a lead apron—performs an ultrasound of the abdomen.

Table 14.1 Suggestions for diagnostic modalities in trauma imaging<sup>1</sup>

Clinical problem	Investigation	Comment
<b>Major trauma</b>		Perform only the minimum XRs necessary at initial assessment.
General screen in the unconscious or confused patient	CXR	To rule out pneumothorax, pleural fluid, widened mediastinum, and to check tube position during the stabilization of the patient’s condition, which is the priority.
	Pelvis XR	During the stabilization of the patient’s condition, which is the priority. Pelvic fractures are often associated with major blood loss.
	US abdomen	During the stabilization of the patient’s condition, which is the priority. To exclude free fluid in the abdomen and pericardial fluid.

Table 14.1 Suggestions for diagnostic modalities in trauma imaging<sup>1</sup> (Continued)

Clinical problem	Investigation	Comment
	CT head	After initial resuscitation.
	XR cervical spine	Cervical spine XR can wait so long as spine and cord are suitably protected until the patient's circulation, etc., is stabilized.
<b>Abdomen/pelvis</b>		
Blunt trauma	US abdomen	During the stabilization of the patient's condition, which is the priority. To exclude free fluid and look for solid-organ injury in the abdomen.
	CXR, XR pelvis	Pneumothorax must be excluded. Pelvic fractures that increase pelvic volume are often associated with major blood loss.
	XR abdomen erect	Patient erect or positioned on the left side; horizontal beam to exclude free air.
	CT	To further evaluate abdominal XR and US findings. Sensitive and specific, but time-consuming and may delay surgery in some settings.
? Renal trauma	US abdomen	For initial evaluation; negative US does not exclude renal or other retroperitoneal injury.
	CT	In suspected major injury ± hypotension ± macroscopic hematuria. Arterial/venous contrast phase in suspected perfusion problem. Excretory phase to assess collecting system.
<b>Chest</b>		
Minor chest trauma	CXR	Not indicated routinely. The demonstration of a rib fracture does not alter management. Beware of left lower rib cage bruises, indicating splenic injury.
Moderate to severe trauma	CXR	For pneumothorax, fluid, or lung contusion, tube position, mediastinal width.
	CT/CTA with 3D reconstructions of aorta or angiography	If mediastinum is widened, to exclude mediastinal hemorrhage and aortic injury; if CTA not available—low threshold for angiography.
Stab injury	CXR, US	To show pneumothorax, lung damage, or fluid. US for pleural and pericardial fluid.
? Sternal fracture	CXR, XR lateral sternum	Sternal fracture indicates severe mediastinal trauma.
	CT	To exclude suspected thoracic spinal and aortic injuries.
<b>Cervical spine</b>		
		Challenging interpretation.
Conscious patient with head and/or face injury only	XR cervical spine	Not necessary in those who meet all of the following criteria: 1. No midline cervical tenderness 2. No focal neurological deficit 3. Normal alertness 4. No intoxication 5. No painful, distracting injury
Unconscious with head injury. Neck injury with pain	XR cervical spine	Must be of good quality and show cervical spine down to T1/2 to allow accurate evaluation. Should show dens centered between lateral masses of C1 (not always possible at time of initial study). XR may be very difficult in the severely traumatized patient and overzealous manipulation must be avoided.

CSF, cerebrospinal fluid; CT, computed tomography; CTA, CT angiography; CXR, chest radiograph(y); FB, foreign body; MRI, magnetic resonance imaging; MVA, motor vehicle accident; NM, nuclear medicine; US, ultrasound; XR, radiography

All rights reserved. Usage subject to terms and conditions of license.



Table 14.1 Suggestions for diagnostic modalities in trauma imaging<sup>1</sup> (Continued)

Clinical problem	Investigation	Comment
	CT	If difficulties in evaluation arise or if fracture is seen on XR, CT with multiplanar and 3D reconstructions is obligatory. MRI may be considered.
Neck injury with pain but XR initially normal; suspected ligamentous injury, spasm	XR cervical spine; flexion and extension	Views taken in flexion and extension (consider fluoroscopy) as achieved by the patient with no assistance and under medical supervision. Passively guided motion (surgeon only) may give additional information.
	MRI	Demonstrates ligamentous/diskal injury.
Neck injury with neurological deficit	XR cervical spine	For initial assessment. Must be of good quality to allow accurate interpretation.
	MRI	Best and safest method of demonstrating intrinsic cord damage, cord compression, ligamentous injuries, and vertebral fractures at multiple levels. Some constraints with life support systems.
	CT	CT myelography may be considered if MRI is not available.
<b>Head</b>		
<i>Low risk of intracranial injury</i> <ul style="list-style-type: none"> <li>■ Fully orientated</li> <li>■ No amnesia</li> <li>■ No loss of consciousness</li> <li>■ No neurological defects</li> <li>■ No serious scalp laceration</li> <li>■ No hematoma</li> </ul>	No imaging	These patients are usually sent home with head injury instructions to the care of a responsible adult. They may be admitted to hospital if no such adult is available.
<i>Medium risk of intracranial injury</i> <ul style="list-style-type: none"> <li>■ Loss of consciousness or amnesia</li> <li>■ Violent mechanisms of injury</li> <li>■ Scalp bruise, swelling, or laceration down to bone or &gt;5 cm</li> <li>■ Neurological symptoms or signs (including headache, vomiting twice or more, return visit)</li> <li>■ Inadequate history or examination (epilepsy, alcohol, child, etc.)</li> <li>■ Child below 5 years: suspected non-accidental injury, ?tense fontanelle, fall &gt;60 cm or onto hard surface.</li> </ul>	CT	<p>CT is the first and <i>only</i> investigation in this group of patients, to confidently exclude cranial injury.</p> <p>If no abnormality is seen, patients will usually be sent home with head injury instructions to the care of a responsible adult. If no responsible adult is available or if a fracture is present, the patient will usually be admitted.</p> <p>MRI of brain is the preferred investigation for intracranial injuries in nonaccidental injury in children.</p>
<i>High risk of intracranial injury</i> <ul style="list-style-type: none"> <li>■ Suspected FB or penetrating injury to skull</li> <li>■ Disorientated or depressed consciousness</li> <li>■ Focal neurological symptoms or signs</li> <li>■ Seizure</li> <li>■ Coagulopathy, including anticoagulant therapy</li> <li>■ Skull fracture or sutural diastasis shown on skull XR</li> <li>■ CSF from nose or CSF/blood from ear (basal skull fracture)</li> <li>■ Hemotympanum, “racoon eyes”</li> <li>■ Unstable systemic state precluding transfer to neurological unit</li> <li>■ Diagnosis uncertain</li> </ul>	CT (immediately!)	<p>These patients will usually have been admitted for observation. If there is any delay in getting CT on an urgent basis, seek neurosurgical consultation.</p> <p>Later deterioration in Glasgow Coma Scale (GCS) by 1 point (especially motor score) warrants follow-up CT.</p> <p>Failure to reach GCS of 15 within 24 hours in patients with initially normal CT warrants follow-up CT.</p>

CSF, cerebrospinal fluid; CT, computed tomography; CTA, CT angiography; CXR, chest radiograph(y); FB, foreign body; MRI, magnetic resonance imaging; MVA, motor vehicle accident; NM, nuclear medicine; US, ultrasound; XR, radiography

Table 14.1 Suggestions for diagnostic modalities in trauma imaging<sup>1</sup> (Continued)

Clinical problem	Investigation	Comment
<b>Very high risk of intracranial injury</b> <ul style="list-style-type: none"> <li>■ Deteriorating consciousness or neurological signs (e.g., pupil changes)</li> <li>■ Confusion or coma persistent despite resuscitation</li> <li>■ Tense fontanelle or sutural diastasis</li> <li>■ Open or penetrating injury</li> <li>■ Depressed or compound fracture</li> <li>■ Fracture of skull base</li> </ul>	CT (immediately!)	<b>Urgent neurosurgical and anesthetic referral indicated,</b> which must be sought in parallel with imaging.
<b>Thoracic and lumbar spine</b>		
No pain, no neurological deficit	No imaging	Physical examination is reliable in this region. When the patient is awake, alert, and asymptomatic, the probability of injury is low.
Pain, no neurological deficit or patient not able to be evaluated	XR painful area	A low threshold for XR when there is pain/tenderness, a significant fall, a high impact MVA, other spinal fracture present, or if it is not possible to clinically evaluate the patient.
	CT/MRI	CT or MRI if XR suggests instability or posterior element fractures or leaves information to be desired.
Neurological deficit ± pain	XR	For initial assessment.
	MRI	Whole-spine MRI is the best method of demonstrating ligamentous injuries, intrinsic cord damage, cord compression, cauda equina injuries, and vertebral fractures at multiple levels.
	CT	Best for detailed analysis of bone injury. Multiplanar and 3D reconstructions are obligatory. Often used in the context of dedicated “trauma spiral” CT encompassing chest and abdomen.
<b>Pelvis and sacrum</b>		
Fall with inability to bear weight	XR pelvis plus lateral hip	Physical examination may be unreliable. Check for femoral neck fractures, which may not show on initial XR, even with good lateral views.
	CT, MRI, bone scan	Useful in selected cases when XR is normal or equivocal.
Urethral bleeding and pelvic injury	Retrograde urethro-gram	To show urethral integrity, leak, rupture. Consider cystogram or delayed postcontrast CT if urethra is normal and there is suspicion of bladder leak.
Trauma to coccyx or coccydynia	XR coccyx	Not indicated routinely as normal appearances are often misleading and findings do not alter management.
<b>Upper limb</b>		
Shoulder injury	XR shoulder	Some dislocations present subtle findings. As a minimum, orthogonal views are required.
	US, CT, MRI	Have a role in soft tissue injury
Elbow injury	XR elbow	To show an effusion. Routine follow-up XRs not indicated in “effusion, no obvious fracture.”
	CT, MRI	In complex injuries and ambivalent XR.

CSF, cerebrospinal fluid; CT, computed tomography; CTA, CT angiography; CXR, chest radiograph(y); FB, foreign body; MRI, magnetic resonance imaging; MVA, motor vehicle accident; NM, nuclear medicine; US, ultrasound; XR, radiography

Eastman, Getting Started in Clinical Radiology © 2006 Thieme

All rights reserved. Usage subject to terms and conditions of license.

Table 14.1 Suggestions for diagnostic modalities in trauma imaging<sup>1</sup> (Continued)

Clinical problem	Investigation	Comment
Wrist injury	XR	Four-view series is needed where scaphoid fracture is suspected.
	MRI, NM, CT	If clinical doubts persist, MRI, NM, or CT are reliable, MRI being the most specific. There is increasing use of MRI as the only examination in complex injuries.
<b>Lower limb</b>		
Knee injury (fall/blunt trauma)	XR	Not indicated routinely, especially where physical signs of injury are minimal. Inability to bear weight or pronounced bony tenderness, particularly at patella and head of fibula, merit radiography.
Ankle injury	XR	Not indicated routinely. Features that justify XR include: the elderly patient, malleolar tenderness, marked soft tissue swelling, and inability to bear weight.
Foot injury	XR	Not indicated routinely, unless there is true bony tenderness or ongoing inability to bear weight. Even then the demonstration of a fracture rarely influences management. Only rarely are XRs of foot and ankle indicated together; both will not be done without good reason. Clinical abnormalities are usually confined to foot or ankle. If XRs are not taken, advise return in one week if symptoms persist. CT is indicated for complex midfoot or hindfoot injuries.
? Stress fracture	XR	Indicated, although often unrewarding.
	NM or MRI	Provide a means of early detection as well as a visual account of the biomechanical properties of the bone.

<sup>1</sup>Modified after: RCR Working Party. *Making the best use of a Department of Clinical Radiology. Guidelines For Doctors*, 5th ed. London: The Royal College of Radiologists, 2003.

CSF, cerebrospinal fluid; CT, computed tomography; CTA, CT angiography; CXR, chest radiograph(y); FB, foreign body; MRI, magnetic resonance imaging; MVA, motor vehicle accident; NM, nuclear medicine; US, ultrasound; XR, radiography

## → Abdominal Ultrasound

### Checklist: Abdominal Ultrasound in Polytrauma

- Is there any free fluid in the abdomen? Is there any fluid in the pleural spaces, in the pericardium?
- Are any parenchymal organs visibly injured?
- Is there fluid detectable around the aorta?

Giufeng starts to scan sagittally from the right side of the patient and follows the liver edge to the front, thus displaying Morrison's pouch, the recess between the liver and the right kidney (Fig. 14.1a).

! A sign of a significant visceral organ injury, free fluid in the abdomen is best visualized in Morrison's pouch.

Giufeng cannot find any free fluid and reports this to the keeper of the minutes protocolling all events in the resuscitation room, including the exact time of the US examination. A follow-up ultrasound just 30 minutes later—after circulatory stabilization of the patient (see also Fig. 14.31b)—may show an entirely different situation. Rapidly she scans the liver, both kidneys, the spleen, and the aorta for abnormalities and then checks the pleural space on both sides as well as the pericardium (Fig. 14.1b) for fluid. She pushes the ultrasound unit back into the corner.

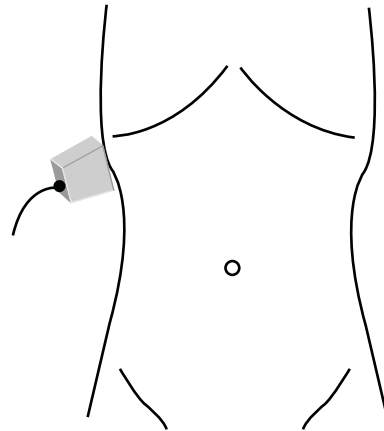
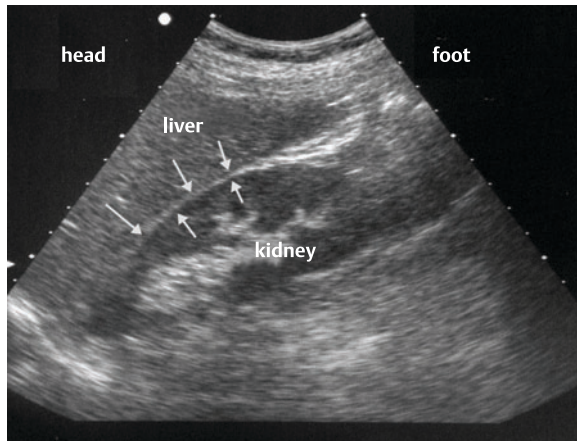
## → Radiograph of the Chest

By now the first radiograph of the chest appears on the viewbox (Fig. 14.2). Giufeng's heart races, her mouth is dry. She takes a deep breath and tries to be systematic in her analysis despite all the adrenaline rush of the situation.



## Patient A: Ultrasound

## a, b Abdomen



## c, d Heart

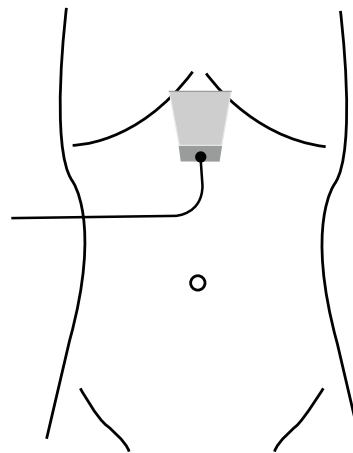
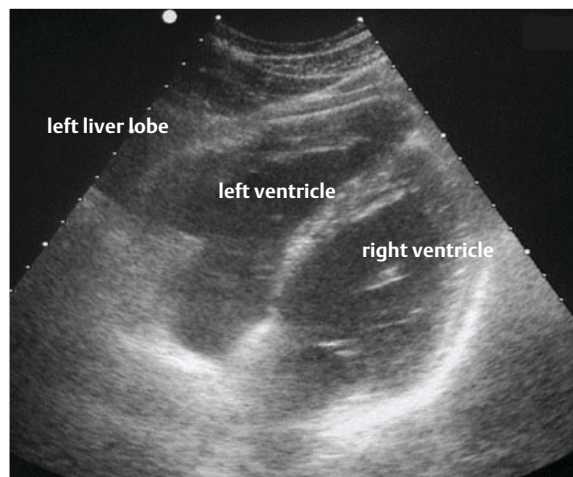


Fig. 14.1 **a** View of the Morrison's pouch. The fine peritoneal recess between liver and right kidney (arrows) is Morrison's pouch. This is where free fluid collects early and where it cannot be mistaken for fluid in any hollow organ. **b** The US probe is located in the superior lateral abdominal wall (sagittal section).

**c** View of the heart. Do you see the interventricular septum and both cardiac ventricles? Fluid in the pericardium would manifest itself as a dark stripe between the liver and the heart. **d** The ultrasound probe is positioned just inferior to the xiphoid process and is tilted cranially.

**Checklist: Radiograph of the Chest in Polytrauma**

- Is the endotracheal tube well positioned?
- Is there a pneumothorax or even a tension pneumothorax?
- Are central venous lines correctly placed?
- Are there rib fractures, particularly in the region overlying the spleen?
- Is there a pulmonary edema, a lung contusion?
- Is the mediastinum widened? Beware: Patient positioning!
- Is the diaphragm intact?

**Is the endotracheal tube correctly positioned?** Your first concern must be the endotracheal (ET) tube. Its tip should

ideally be 1.5 cm above the tracheal bifurcation. If it is placed lower, movements of the patient may lead to selective intubation of a main bronchus with a consecutive reduced aeration or even collapse of the contralateral side. Volume loss ensues and eventually displaces the mediastinum to the contralateral side (Fig. 14.3). In order not to injure the vocal cords, the tube cuff should be located well inferior to them, around the level of the 5th cervical vertebral body. Are you sure the tube is inside the trachea? A lot of air in the stomach may indicate incorrect intubation of the esophagus, either presently or in the immediate past (Fig. 14.3). The anesthesiologist must be alerted to the fact at once and perform clinical examination including auscultation to check ET tube position!

### Patient A: Radiograph of the Chest

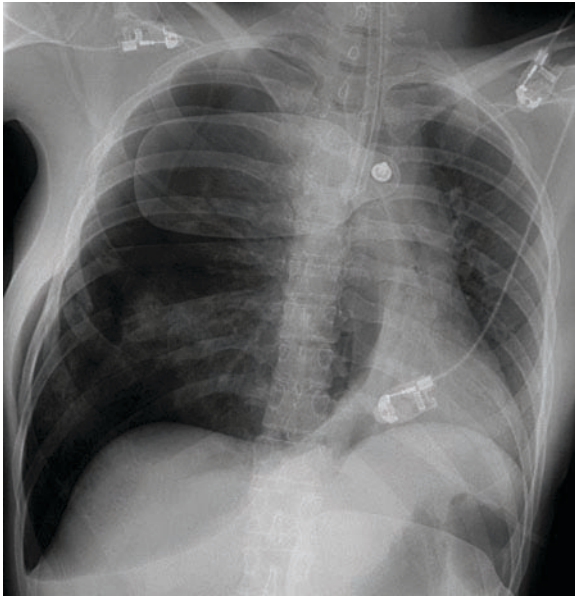


Fig. 14.2 This is the chest radiograph of patient A. Do you see any abnormality? Use the checklist for your image analysis.

**Is there a pneumothorax?** The second major thing to consider is the potential complications of the vascular access. If the large internal jugular or subclavian veins are punctured, the lung apex is particularly at risk, especially if several attempts are necessary before venous access can

be established. Is there evidence for a pneumothorax (Fig. 14.4a, b)? In supine portable CXRs the air in the pleural space moves anteriorly. A fine rim of decreased attenuation along the heart and diaphragm contour may be the only indication of a pneumothorax. There is another sign to look for, however.

! The deep pleural recesses are only reached and unfolded by free air in the pleural space (Fig. 14.4c). This is the rather specific “deep sulcus sign” of a pneumothorax.

If there is a tension pneumothorax (Fig. 14.4d) that causes a mediastinal shift to the contralateral side, the ventilation of the contralateral lung and the venous backflow into the chest are impaired. Rapid relief of the increased pressure in the pleural space is crucial.

Catheters, textile folds, rib margins, the medial contours of the scapulae, and skin folds (Fig. 14.4e) can simulate a pneumothorax because they may look like the outline of the visceral pleura.

! Check for crossing anatomical structures: any “pleural line” that is crossed by pulmonary vessels on their way to the periphery cannot be the pleural outline in pneumothorax.

**Are the central venous lines correctly placed?** Subclavian or jugular venous lines should harmonically follow the course of the vena cava (Fig. 14.5a) and not reach the level of the tricuspid valve (Fig. 14.5b) in order to avoid catheter-induced arrhythmias. A catheter to measure the central pulmonary pressure (Swan–Ganz catheter) is advanced through the right heart into the pulmonary

### Where is the Tube?

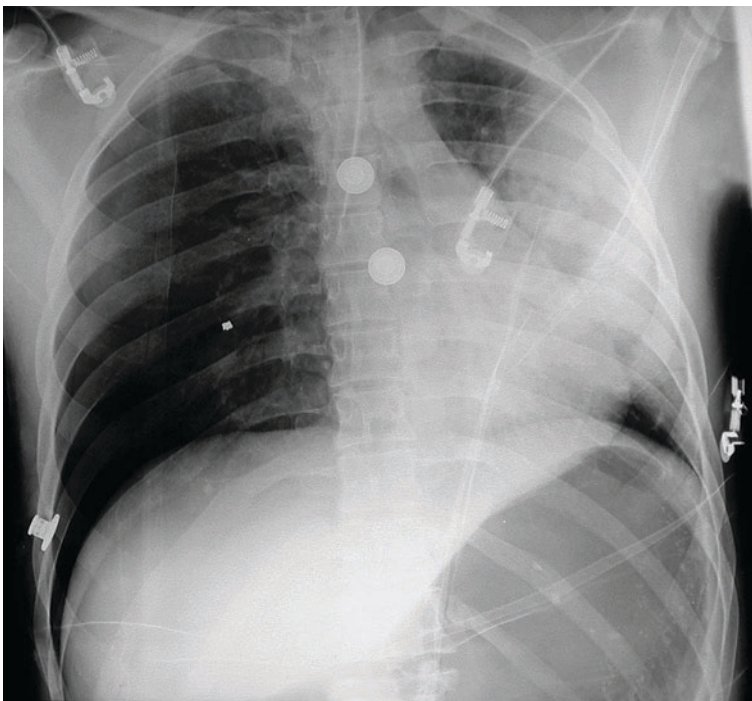
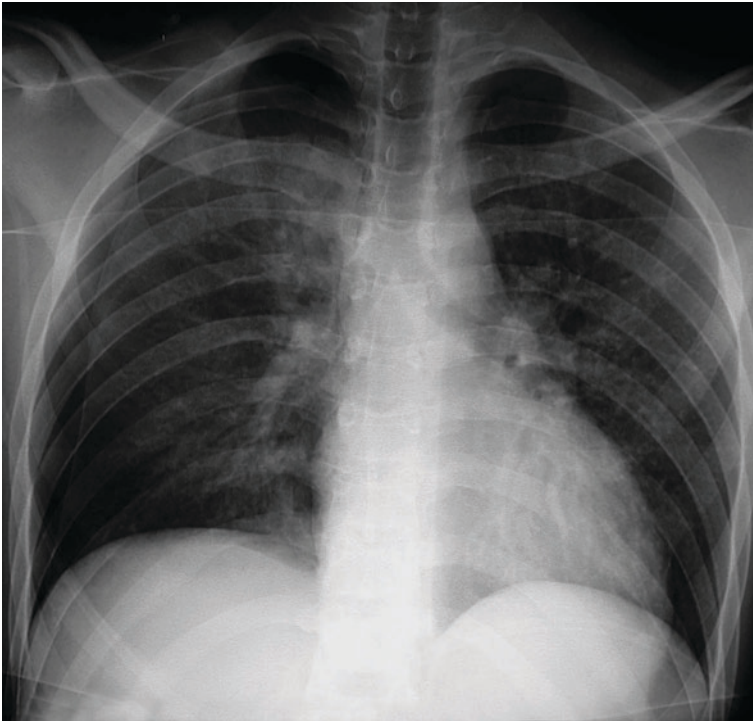


Fig. 14.3 The tip of the tube is located in the right mainstem bronchus! The left lung is increased in density owing to atelectasis and has lost volume; the mediastinum is displaced to the left. The stomach is significantly overdistended as a consequence of a previous esophageal intubation, which has since been corrected. During the accident or during intubation, the patient has aspirated a dental filling. There is another extremely important finding visible on this radiograph. Do you see it?

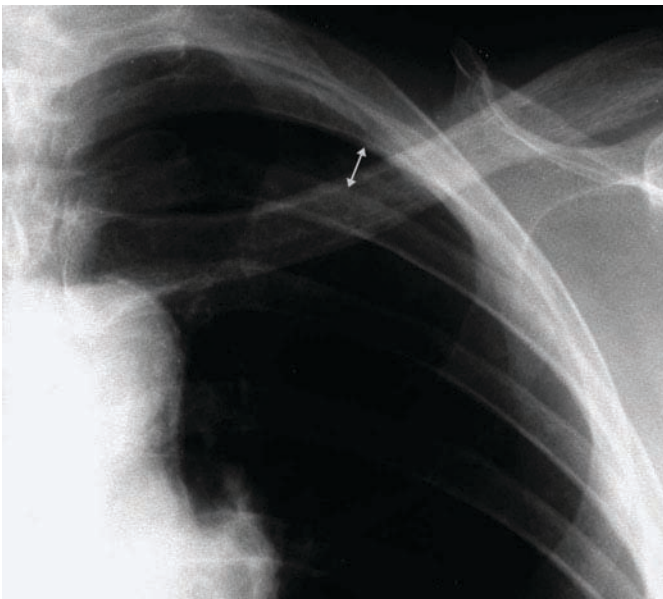
Yes, of course, there is a tension pneumo- folds.  
posed over the upper abdomen are textile  
ECG electrodes. The fine lines superim-  
thorax on the right. The metal gadgets are

## Pneumothorax

### a Pneumothorax



### b Apical pneumothorax



### c "Deep sulcus sign"

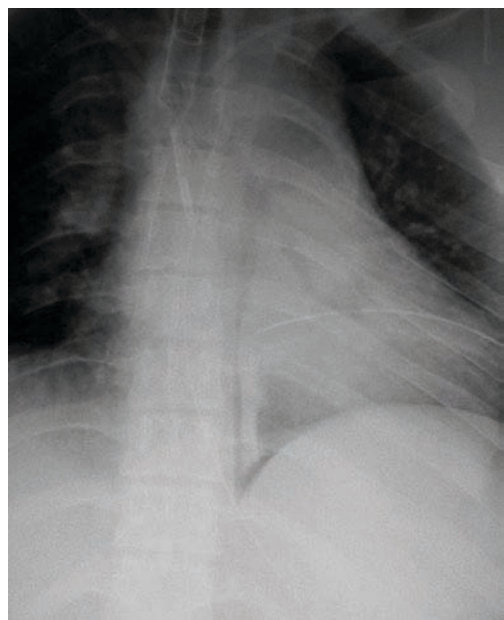


Fig. 14.4 **a** The pleural margin appears as a fine line running along the right thoracic wall that is not traversed by any vessels. A tension pneumothorax is not yet present. To prevent its development, an intrathoracic tube may need to be inserted. **b** In another patient, only a fine line is visible apically between the third and fourth ribs dorsally (arrow). If you are not absolutely sure,

you can have the radiograph repeated in expiration. This technique often makes the air-filled pleural space wider and better visible. **c** Paravertebrally on the left you see the pointed deep pleural recess, also called "deep sulcus sign." The partially airless left lower lobe is seen reaching into it but not filling it. A chest tube has already been inserted in this patient.





## Pneumothorax

d Tension pneumothorax

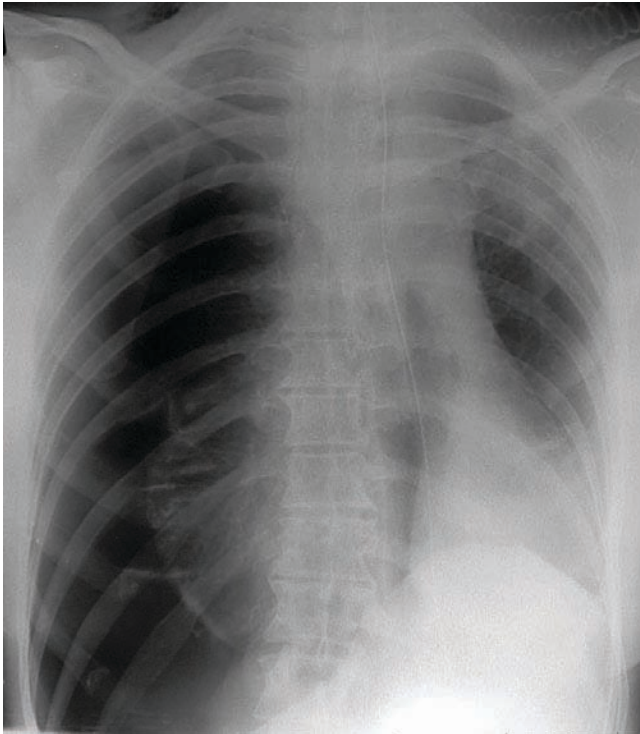
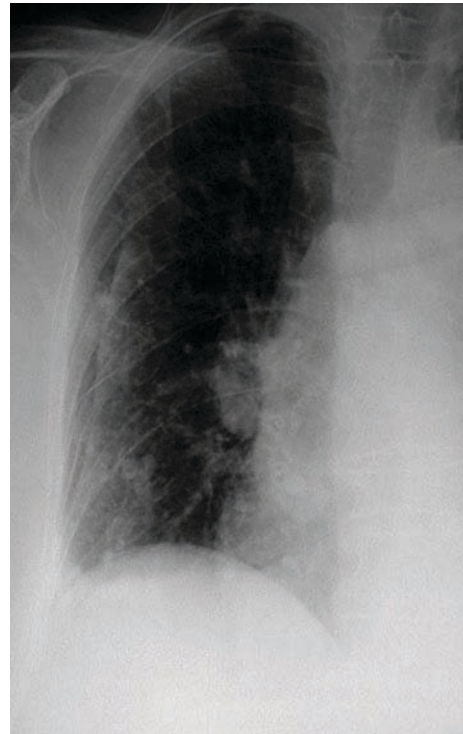


Fig. 14.4d Vascular markings are lacking in the periphery of the right hemithorax (compare to the left hemithorax). The visceral pleura and with it the collapsed lung are appreciated with ease. The right hemidiaphragm is severely depressed, while the mediastinum is displaced to the contralateral side (note the course of the nasogastric tube within the esophagus). Subcutaneous emphysema is present in the right cervical region. The parietal

e Wrong diagnosis



pleura was probably injured during a vascular puncture. Immediate intervention is necessary! e In this radiograph a rather dense line is visible that is traversed by the pulmonary vasculature—it thus cannot be a pneumothorax. The line is paralleled by a dense stripe of attenuation a few centimeters wide: you are looking at a skin fold. Remember: These bedside patients are resting on the film cassette and not everyone is as well built as you are.

artery. For certain measurements the catheter is wedged into a more peripheral pulmonary arterial vessel and temporarily a small balloon is inflated at its tip. The balloon should be deflated at all other times.

#### Are there rib fractures, particularly overlying the spleen?

The presence of a rib fracture or even serial rib fractures (Fig. 14.6) in the left lower hemithorax greatly increases the probability of a coexisting splenic injury. Rib fractures may cause a pneumothorax, even a tension pneumothorax (see above). Is there evidence for a hemothorax? Circumscribed consolidations in the lung at this stage tend to be due to lung contusions (Fig. 14.6).

#### Is there pulmonary edema? Are there lung contusions?

Perihilar symmetric patchy opacities and ill-defined blood vessels indicate *pulmonary edema* if (very important!) the radiograph is performed with sufficient inspiration (Fig. 14.7). Causes may include an overly aggressive fluid resuscitation during the initial emergency care. In elderly patients a cardiac decompensation can also be induced by the trauma itself.

If—particularly in the presence of rib fractures—circumscribed consolidations are detectable in the lung of a freshly traumatized person, *lung contusions* are the most likely cause (Fig. 14.6). They consist of pulmonary hemorrhages that tend to clear within a few days. The injuries to the lung can, however, also lead to tears of the pulmonary parenchyma, so-called lung lacerations (Fig. 14.6). Opacities in dependent lung areas may also be due to atelectasis or aspiration.

**Is the mediastinum widened?** The mediastinum is always wider in the recumbent than in the upright patient. The diaphragm pushes upward, especially in the fatter individual, and compresses the mediastinum. In addition the venous backflow is increased, which also adds to the mediastinal volume. Any rotation of the patient around the longitudinal axis also makes the mediastinum appear wider. For that reason it is crucial that the patient is positioned straight for the radiograph; this is not always trivial in an emergency room or intensive care setting. Assessing the relative position of the spinous processes between the medial edges of the two clavicles (ideally centered)

## Central Venous Catheter

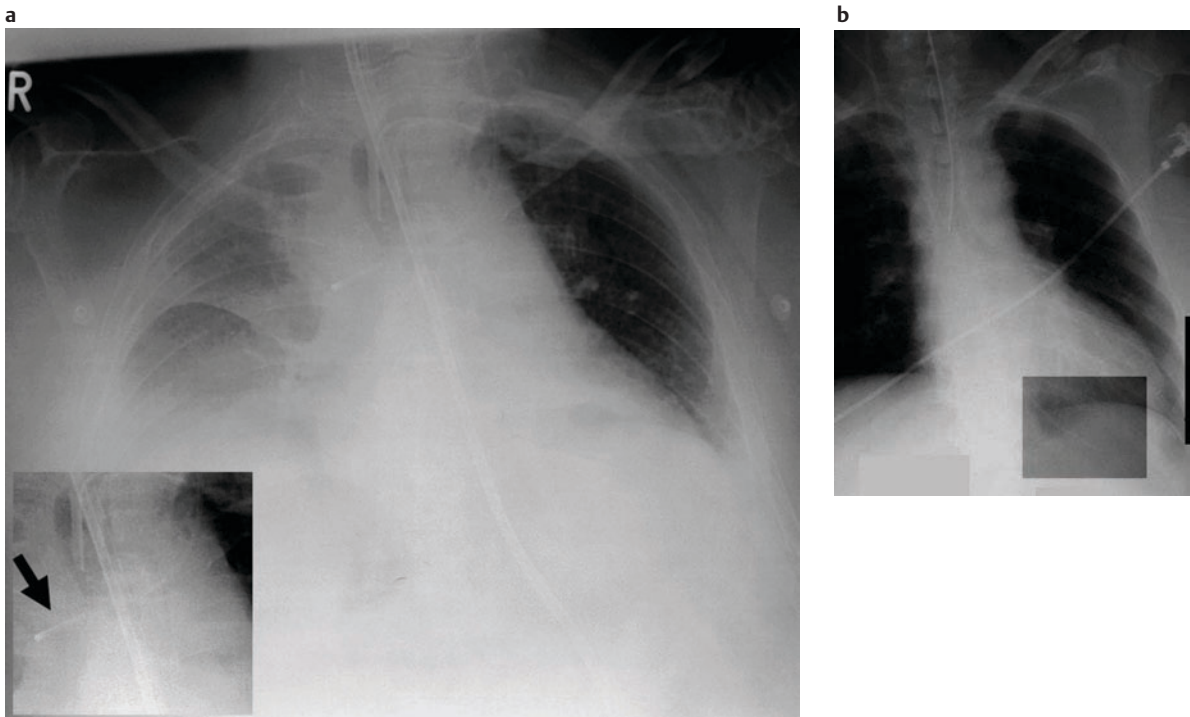


Fig. 14.5 **a** A central venous catheter has been introduced via the left jugular vein and has then deviated into the azygos vein, where its tip appears to have a very high density. It is, however, imaged orthogonally or “down the barrel.”

**b** On this radiograph you can follow the central venous catheter through the right atrium into the apex of the heart (see window). Does anything else strike you?

The tube is positioned too low!

## Serial Rib Fractures

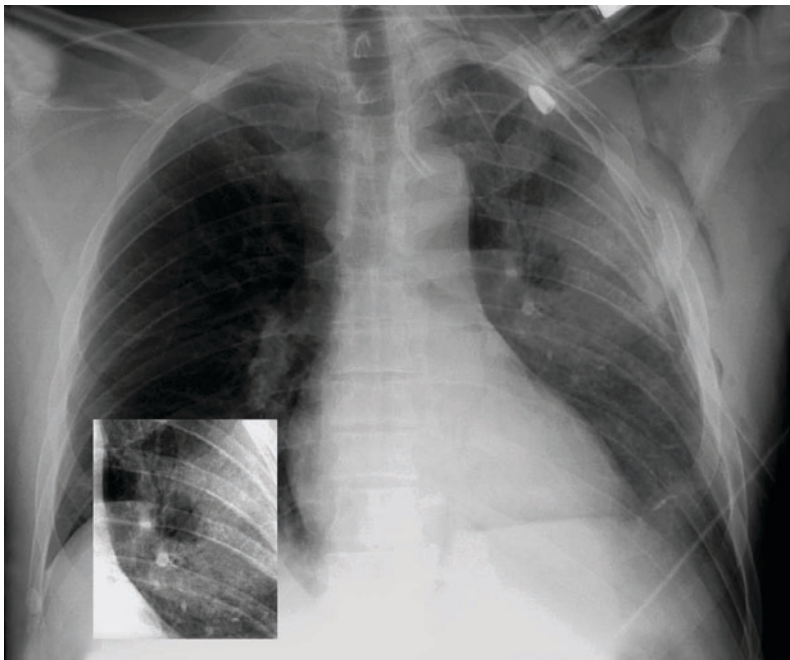

Fig. 14.6 This patient suffered from serial rib fractures (ribs 3–6 on the left). A pneumothorax has already been taken care of with an intrathoracic chest tube in drainage. The lung in the vicinity of the fracture is considerably increased in density: The alveoli are filled with blood, which is why the bronchi are beautifully visible as black stripes, so-called “positive air bronchograms” in a patient with a lung contusion. Within this zone there is a circumscribed area of increased lucency (see also the inset)—this is a pulmonary tear. The pulmonary hemorrhage clears within a few days. The pulmonary tear may take months to heal.

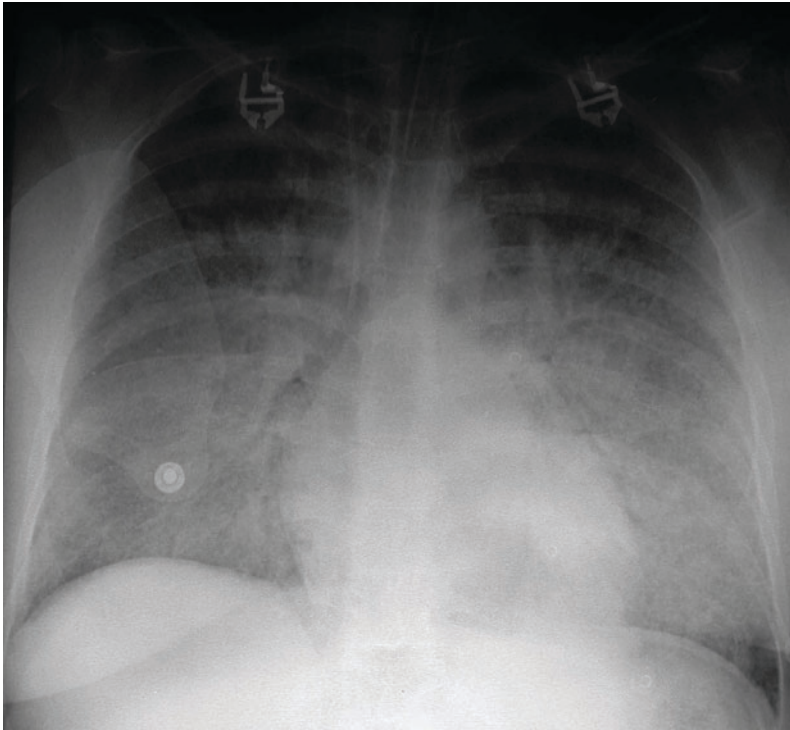
**Pulmonary Edema**

Fig. 14.7 Severe alveolar edema is characterized by positive air bronchograms and perihilar symmetrical opacities. The distribution of the consolidations resembles the outline of a butterfly in flight (or even a less popular creature), which is why perihilar alveolar lung edema is often labeled as “butterfly edema” or “batwing edema.” This patient underwent vigorous fluid resuscitation and defibrillation (you can see the large transparent electrode of the defibrillator superimposed on the right chest) and developed pulmonary edema in this context.

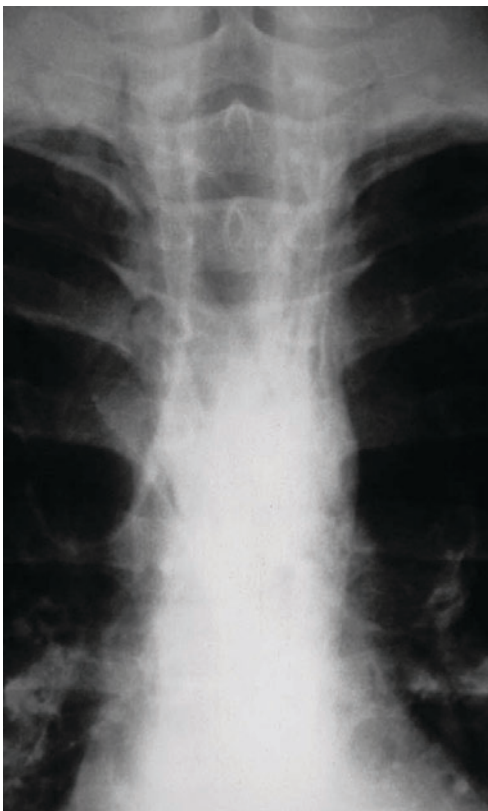
**Pneumomediastinum**

Fig. 14.8 This view of the upper mediastinum shows some fine, dark stripes parallel to the trachea and the large mediastinal vessels, for example, the brachiocephalic trunk. There must be air in the mediastinum. Have a close look!



## Rupture of the Diaphragm

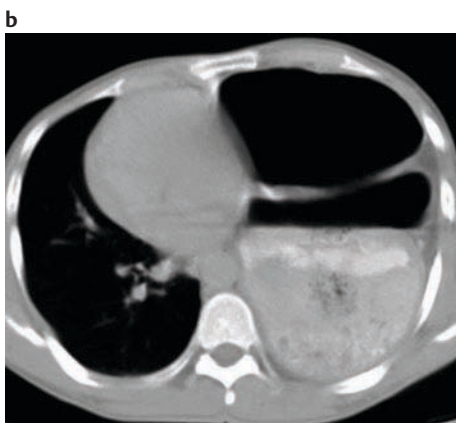
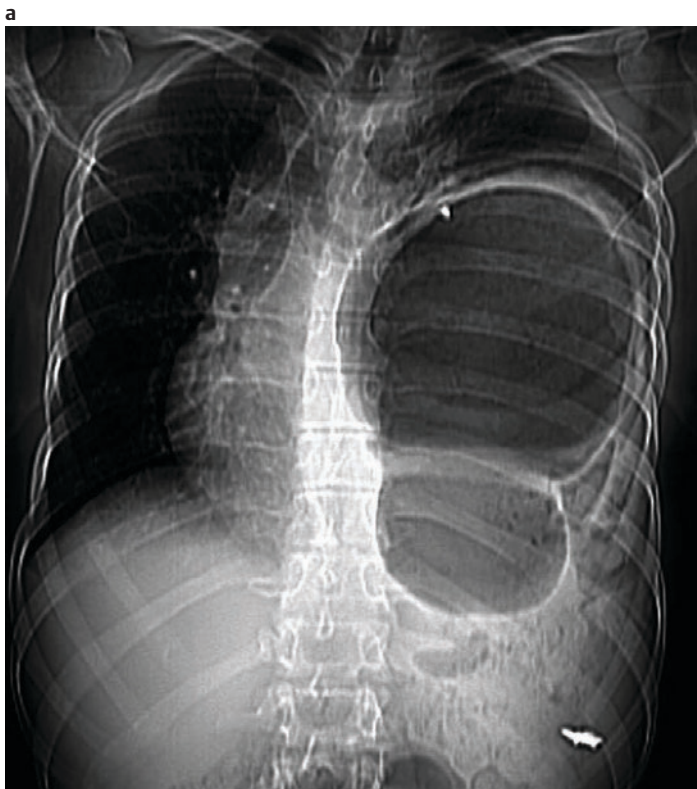


Fig. 14.9 **a** The hemidiaphragm on the left is obliterated. Parts of the colon and the stomach have prolapsed into the chest. **b** CT confirms the finding. The stomach is located high in the left hemithorax.

helps to determine the degree of rotation of the patient around the body axis. If the rotation is taken into consideration and the mediastinum still appears to be abnormally wide, a contrast-enhanced CT of the chest should be done—particularly in those patients with high-speed motor vehicle accident (MVA) trauma or some other deceleration trauma. This is to exclude any treatable injuries to the large vessels, especially traumatic aortic dissection or aneurysm formation. Blood in the mediastinum seen on CT can be an indirect hint. If there is a pneumomediastinum (Fig. 14.8), a tracheal or bronchial tear should be considered.

**Is the diaphragm intact?** If the outline of the diaphragm is invisible or if there are bowel loops seen inside the thorax (Fig. 14.9a), a CT (Fig. 14.9b) should be done to assess the presence of a rupture and look for associated injuries. Most diaphragmatic ruptures occur on the left side because on the right the diaphragm is protected by the sturdy liver.

Giufeng calls the diagnoses out loud for the taker of the minutes to jot down: “Tube malpositioned in the right main bronchus, severe tension pneumothorax on the right, serial rib fractures on the right (4th–8th ribs); volume loss of the left lung; mediastinal shift to the left.” The defibrillation electrode is still fixed to the chest.

### What Pathology Do You Find Here?

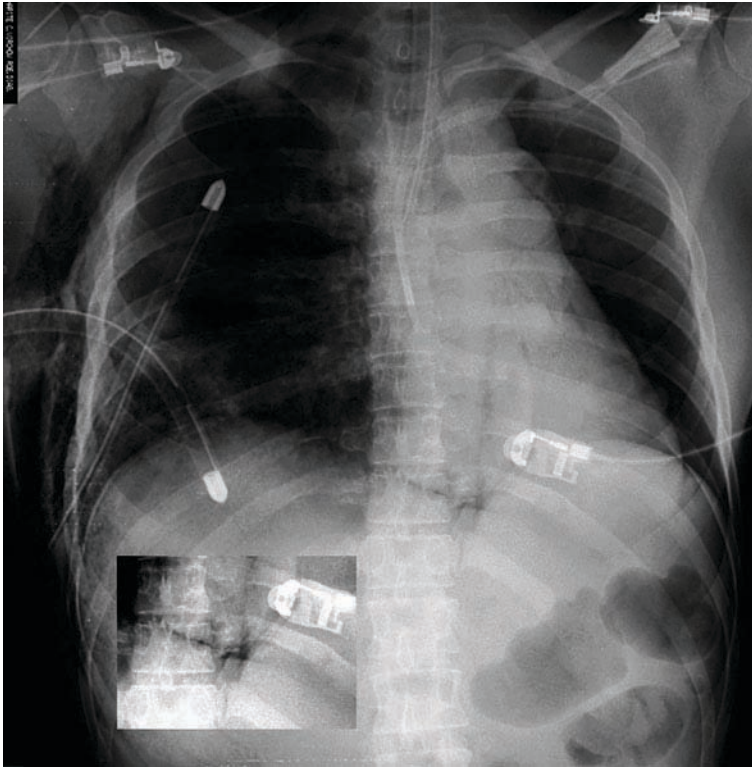


Fig. 14.10

There is a "deep sulcus" (see inset) next to the spine on the left. If you look closer, you will find a fine line along the accentuated heart contour. This patient also has a pneumothorax on the left! The tube position must be corrected and another chest drain inserted on the left.

The reasons for the prior cardiac arrest are evident now: only the side with the tension pneumothorax was being ventilated.

The trauma surgeons had already suspected the tension pneumothorax on clinical grounds and had inserted two chest drains on the right after a first quick glance at the CXR. They had also ordered a follow-up radiograph immediately

after first CXR was out and before Giufeng was finished with her analysis. Giufeng realizes at once that the drains have not had quite the intended effect: the mediastinum is still displaced to the left because it was apparently mainly the right main bronchus intubation that had caused the decreased aeration and the ensuing atelectasis of the left lung. Fortunately, the anesthesiologist listened to Giufeng and corrected the tube position right after Giufeng had called the incorrect tube position. But Giufeng now recognizes another important finding (Fig. 14.10). Any idea what it might be?

### Patient A: The First Radiograph of the Cervical Spine

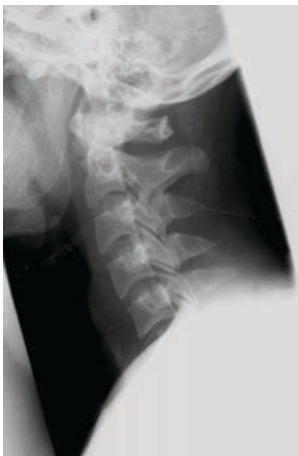

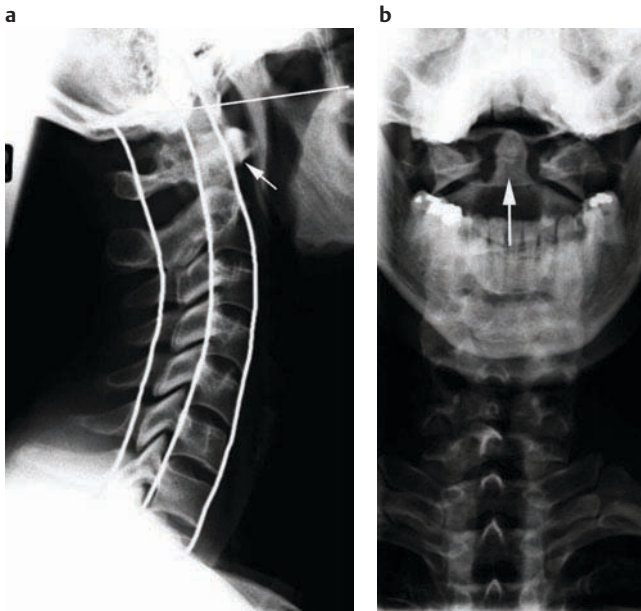
Fig. 14.11 What is your first thought when you see this image? What are the consequences?

#### → Lateral Radiograph of the Cervical Spine

By now the lateral radiograph of the cervical spine is ready for inspection. The trauma surgeons and the anesthesiologist want to know how careful they have to be during repositioning of the patient and whether the stiff collar can be taken off. The radiograph of the cervical spine is always difficult to evaluate and any mistakes can be fatal.

! Twenty percent of all polytraumatized patients have an injury of the cervical spine, a dislocation injury (particularly in deceleration trauma), or a compression injury due to extreme axial loading forces impacting vertebral bodies in the longitudinal direction. It is therefore crucial to check the cervical spine with great care. Definition, outline of all vertebral bodies, and posterior elements and their alignment must be smooth and harmonic!

### Auxiliary Lines for the Evaluation of the Cervical Spine



**Fig. 14.12 a** The auxiliary lines for the evaluation of the configuration of the lateral cervical spine run (from anterior to posterior) along the anterior edges of the vertebral bodies, along the posterior edges of the vertebral bodies, and along the anterior contour of the posterior vertebral arches. Another auxiliary line—the Chamberlain auxiliary line—courses from the hard palate to the occiput. The apex of the dens should not traverse it. Another important point is the atlanto-dental distance (arrow)—it may not exceed 4 mm. Finally, the prevertebral soft tissue rim above the level of the esophageal inlet (about C4/5) may not exceed 7 mm in adults. **b** In the anterior–posterior projection, imagine lines along the spinous processes (do not get thrown off by bifid processes!) and the intervertebral joints. The well-centered position of the dens axis (arrow) relative to the atlanto-occipital joints and to the C1–C2 intervertebral joints is checked with care. (But beware: Is the patient positioned straight?)

#### Checklist: Radiograph of the Cervical Spine in Polytrauma

- Are all cervical vertebral bodies visualized? (Find a strong person to pull down the shoulders or have oblique views performed!)
- Are all auxiliary contour lines well seen and normal in appearance?
- Is the dens axis centered?
- Do the prevertebral soft tissues appear normal?
- Any residual doubts? Get a CT!

Giufeng is quite relieved that Gregory has come to her help. Both delve into the radiograph (Fig. 14.11). First they make sure the whole cervical spine is documented; then they look at the configuration of the spine (normal lordosis?) and the harmonic course of the auxiliary lines along the anterior and posterior edges of the cervical bodies, the posterior margin of the spinal canal (on the lateral projection), and the spinous processes (on the lateral and anterior–posterior projection) (Fig. 14.12). They study the intervertebral joints, the intervertebral disk spaces, the vertebral body configurations, and the prevertebral soft tissue stripe. Is the dens axis well centered on the A–P projection?

Giufeng and Gregory know that the occipitocervical junction zone down to C2/C3 shows some peculiarities in trauma (Fig. 14.13).

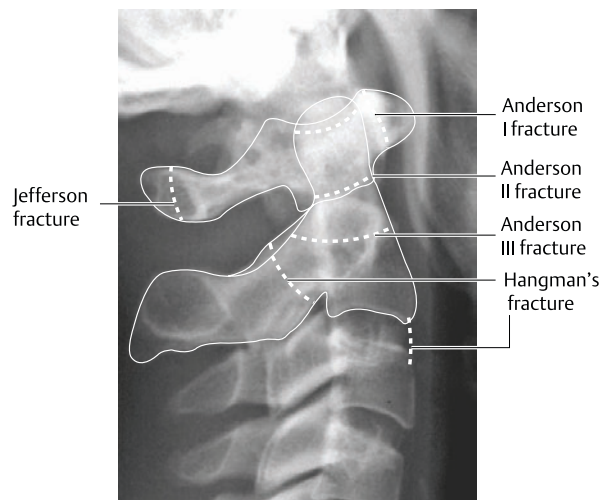
#### Occipitocervical junction injuries down to C2/C3:

**Jefferson fracture:** The Jefferson fracture is a typical compression fracture due to axial loading (for example, a head-first dive into shallow waters). The anterior and posterior arch of C1 is split (Fig. 14.14a), which causes a

dangerous instability. On the dedicated view of the dens or in a coronal CT reconstruction (Fig. 14.14b), the C1 joint facets of the C1/C2 segment are displaced laterally.

**Dens fracture:** The dens fracture is the most frequent traumatic lesion of the upper cervical spine. It is classified according to Anderson into fractures of the top of the dens (Anderson I, probably stable), the base of the dens (Anderson II, probably unstable, Fig. 14.15a, b), and the body of the axis vertebra (Anderson III, mostly stable, Fig. 14.15c).

#### Fractures of the Upper Cervical Spine



**Fig. 14.13** Illustrated are the most important fractures of the upper cervical spine.



## Jefferson Fracture

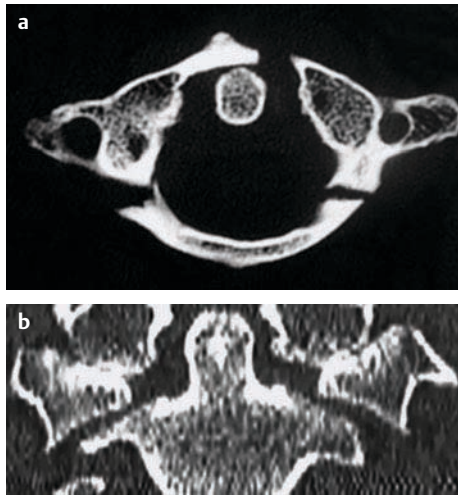


Fig. 14.14 **a** This CT image shows a fracture of the anterior and posterior arches of the atlas ring. It is quite obvious that this fracture is frequently unstable. The dens axis has completely lost its osseous fixation. **b** The lateral migration of the joint facets is best documented by this CT image, which was reconstructed in a plane that shows the abnormality to better advantage. The transverse ligament that normally holds the dens in place must also be torn.

*Traumatic spondylolisthesis:* The second most frequent fracture is the traumatic spondylolisthesis of C2, also called “hangman’s fracture” because it is caused by a sudden hyperextension such as occurs during hanging (Fig. 14.16). Depending on the force of the hyperextension,

## Traumatic Spondylolisthesis

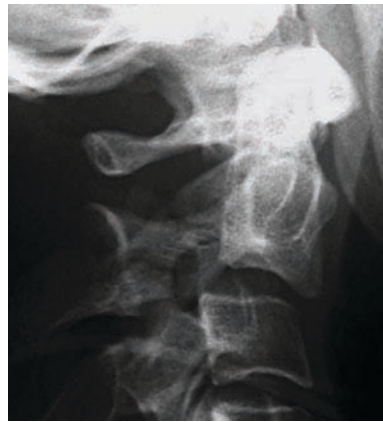

Fig. 14.16 This patient hit the dashboard of his car in a motor vehicle accident. He did not have his seatbelt fastened nor was an airbag installed in his car. The resulting hyperextension has broken his C2 vertebral arch and torn the ligamentary apparatus between C2 and C3. This fracture is evidently unstable.

the arch of C2 breaks bilaterally (type 1, potentially unstable). If the ligaments and the disk of the articular segment C2/C3 rupture partially (type 2) or completely (type 3), a higher degree of instability results.

! The dens fracture is the most common, the traumatic spondylolisthesis is the second most common, and the atlas fracture is the third most common fracture of the upper cervical spine.

## Dens Fracture

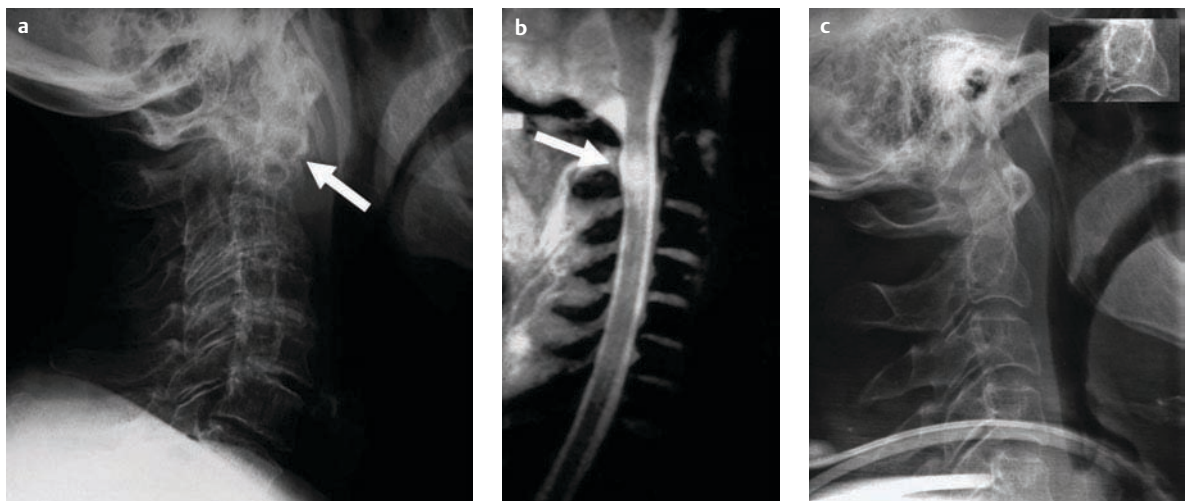


Fig. 14.15 **a** This elderly patient—note the degeneration of the intervertebral spaces—has a fracture of the base of the dens (arrow) classified as Anderson II. **b** An MRI examination of a similar fracture in a different patient illustrates the potential consequence of the resulting osseous instability.

The T2-weighted, sagittal section documents a signal increase (arrow) along the course of the spinal cord. This signal indicates a contusion of the spinal cord. **c** This patient has an Anderson III fracture (see inset).

## Ligamentary Injury of the Cervical Spine

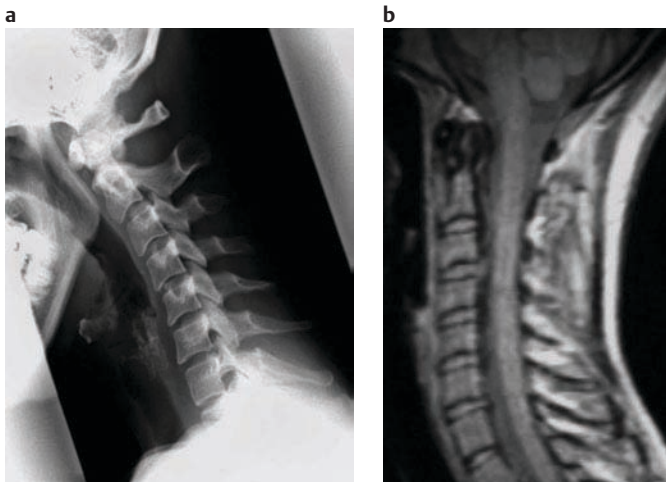


Fig. 14.17 **a** This patient suffered a whiplash trauma during a motor vehicle collision. The radiograph in flexion shows a subtle kink at the level C3/C4. **b** The MR image confirms the disk prolapse at this level.

**Ligamentous injuries:** Primary ligamentous injuries are of great relevance for any future rehabilitation. They are diagnosed after primary emergency care has been concluded using function studies (Fig. 14.17a) and MRI (Fig. 14.17b).

**Spinal column injuries caudal to C3:** Giufeng realizes that the so-called “normal spine” begins at C3. Starting at that level the spinal injuries are categorized as:

- Compression fractures (type A)
- Flexion–distraction fractures (type B)
- Torsion injuries (type C)

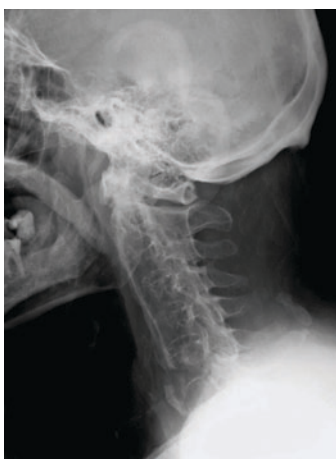The involvement of the posterior edge of the vertebral body is, of course, essential because it indicates a potential hazard to the spinal canal. Fractures of the lower cervical spine mostly evolve in flexion–distraction movement

patterns (type B). Any restriction of the spinal column flexibility, such as seen in ankylosing spondylitis (Fig. 14.18a) or Forrester disease (Fig. 14.18b), increases the risk of unstable fractures even after minor trauma.

While Giufeng is still busy studying the radiograph, Greg has already ordered a repeat study: C6 and C7 are not depicted at all. The new radiograph is performed as an oblique view because, even with two strong trauma surgeons pulling the patient’s shoulders forward, the cervicothoracic transition zone could not be adequately imaged on the lateral projection. The new finding scares the living daylight out of Giufeng (Fig. 14.19). There is a considerable misalignment between C6 and C7: the ligaments of this section must be torn completely. This is a typical torsion injury (C-class spinal injury). The instability can cause a paraplegia. Extreme caution and the stabilization of the cervical spine are warranted.

## Preexisting Spinal Problems That Increase Trauma Risk

**a** Ankylosing spondylitis



**b** Forestier disease

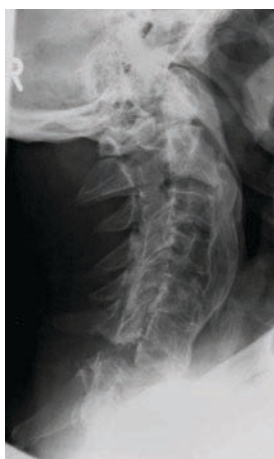

Fig. 14.18 **a** In ankylosing spondylitis, also called Bechterew disease, slowly progressive ossification of the complete ligamentous apparatus of the spinal column occurs. You have already seen the prototypical appearance of the “bamboo spine” in Fig. 8.44b, p. 146. Note the fracture at the C6/7 level after a minor trauma in this patient. **b** In Forestier disease only the anterior longitudinal ligament of the spinal column ossifies, but the effect is the same: the spine loses all its elasticity. Every motion that results in any significant axial loading force on the spine constitutes a considerable fracture risk for these patients. Minor trauma has led to a fracture of the C7 in this case.

### Patient A: The Additional Projections of the Cervical Spine

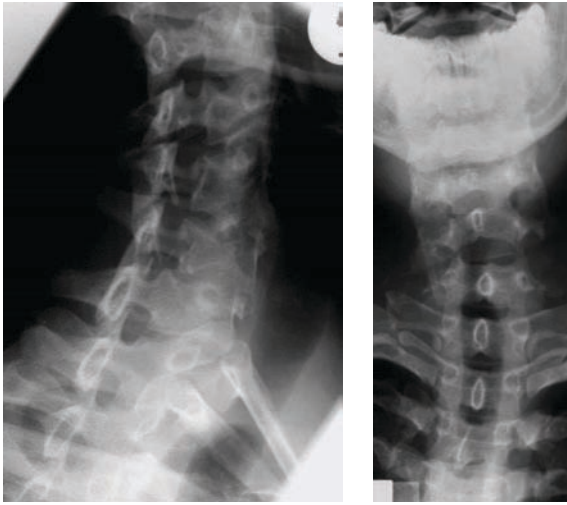


Fig. 14.19 Here you see important additional views of the cervical spine in an oblique (a) and a posterior–anterior (b) projection. Now the pathology should be clear!

### Patient A: Cranial CT

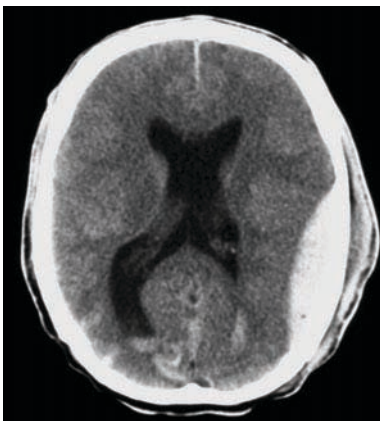


Fig. 14.20 Analyze the cranial CT of patient A. Can you already call the diagnoses? All of them?

### → Cranial CT

After successful circulatory stabilization by the anesthesiologists, patient A is brought to the CT suite. Paul has been waiting for him. The severity of the trauma and the unclear neurological status of the respiration and deeply sedated patient necessitate a head CT. The risk of an intracranial injury is quite high. Cautiously, the patient is moved over onto the CT table. While the anesthesiologists monitor the patient, Paul sits down in front of the CT workstation and analyzes the study as the images appear on the screen one by one (Fig. 14.20). Can you help him? What is the right diagnosis? Before you start, have a look at representative sections of a normal head CT (Fig. 14.21).

**Generalized cerebral edema:** A generalized lethal edema (Fig. 14.22) can develop as a consequence of a severe head trauma. The resulting impaction of the brainstem against edges of the foramen magnum or clivus may compromise the vascular supply of the brain. Secondary infarction can

### Normal Findings in a Cranial CT

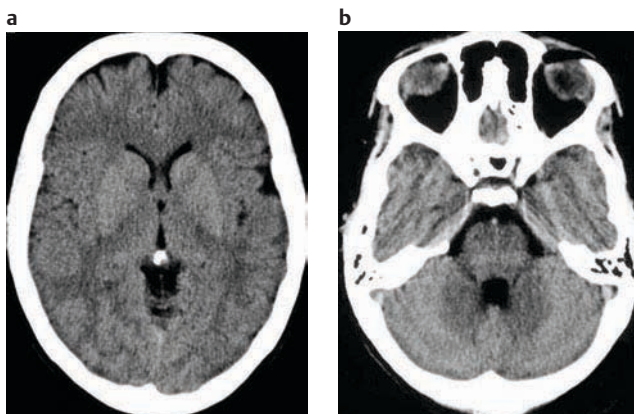


Fig. 14.21 a This is a normal CT of a 50-year-old. The inner and outer CSF spaces are well appreciated. Gray and white matter are easily differentiated from each other and are of normal density. b The basal and posterior fossa cisterns are also well seen.



## Generalized Brain Edema Due to Head Trauma

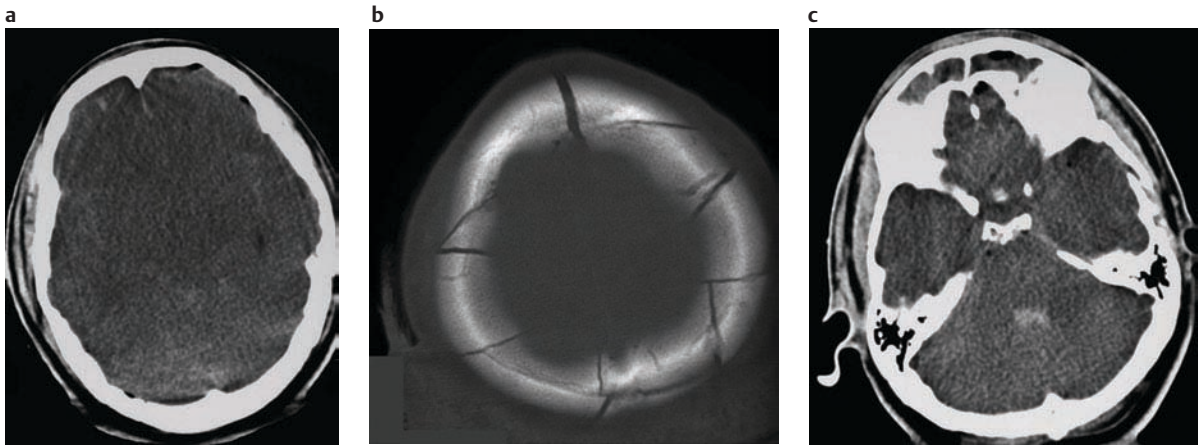


Fig. 14.22 This 40-year-old patient was hit by a wooden plank falling from a building. The pupils had already become unreactive to light in the ambulance helicopter. **a** In comparison to the normal CT (see Fig. 14.21a), the inner and outer CSF spaces are completely obliterated and differentiation between the gray and white matter is impossible. The sylvian fissure and the frontal sulci are outlined with dense material (blood). The midline is not displaced, however. These findings are compatible with severe generalized brain edema and subarachnoid hemorrhages. **b** A more cranial CT section in a bone window shows the reason for the extensive changes: a burst fracture of the skull. As the cranial

vault does not permit sufficient expansion of an edematous brain, the intracranial pressure consequently increases. In less severe states of edema, a conservative antiedematous therapy or a wide surgical fenestration of the skull may be successful—in this patient any help comes too late. **c** A CT image at the level of the posterior fossa demonstrates a complete lack of external CSF space. The fourth ventricle is filled with blood (compare Fig. 14.21b). This patient was later transferred to the intensive care ward for the determination of brain death (24-hour flatline EEG, neurological examination). Hopefully, organ donation is an option in this case to help someone else in need.

develop, resulting in death or permanent brain damage. A similar diffuse edema may be the sequel of a longer-lasting brain hypoxia, for example, in prolonged shock, drowning, suffocation, or strangulation (Fig. 14.23). The consequences are identical.

**Epidural hematoma:** An epidural hematoma (Fig. 14.24) carries a high risk for the patient. It is often an arterial, fracture-induced bleed. It fills the space between the skull bone and its periosteum, the dura mater. This space is, of course, limited by the cranial sutures where the periosteum is tightly fixed. Any blood in this space will elevate the dura, assuming the shape of an expanding cushion. Relatively little blood can thus result in quite a pulsating space-occupying lesion affecting the adjacent brain like a “steam hammer.” This development can be very swift and is naturally accelerated by a successful circulatory stabilization. Immediate neurosurgical intervention is life-saving!

**Subdural hematoma:** A subdural hematoma (Fig. 14.25a), induced by tearing of bridging veins, can spread relatively freely underneath the dura mater (from the viewpoint of the neurosurgeon opening the skull)—subdurally. The bony sutures do not hinder the spread. Frequently, however, an *acute subdural hematoma* goes along with brain contusions that significantly worsen the prognosis. Considerably better are the chances of patients in whom a *subacute subdural hemorrhage* manifests itself only after an interval free of neurological symptoms. The longer

## Generalized Brain Edema Due to Strangulation

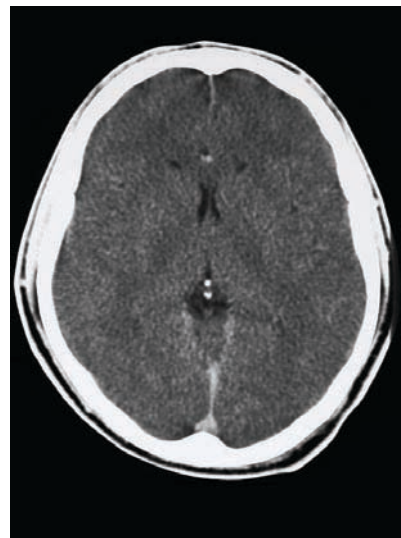
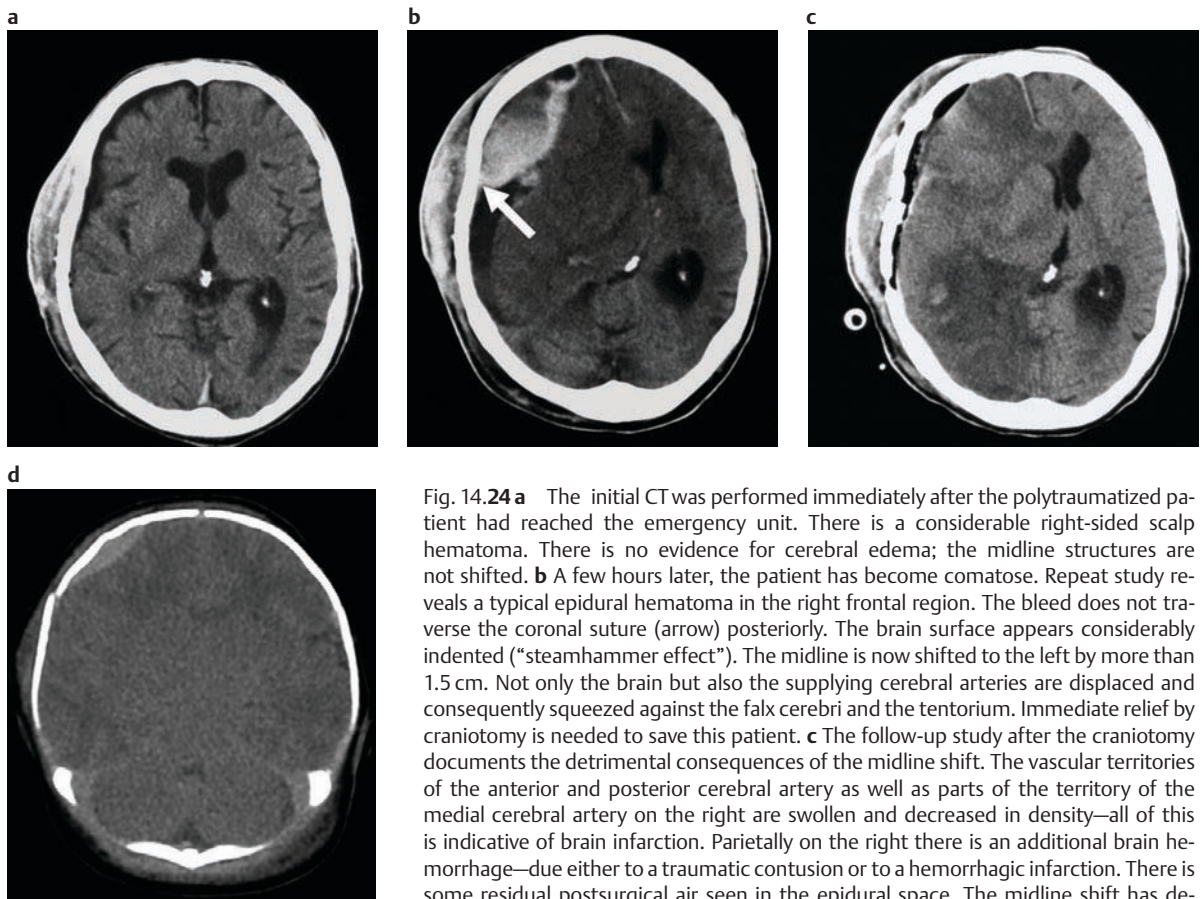


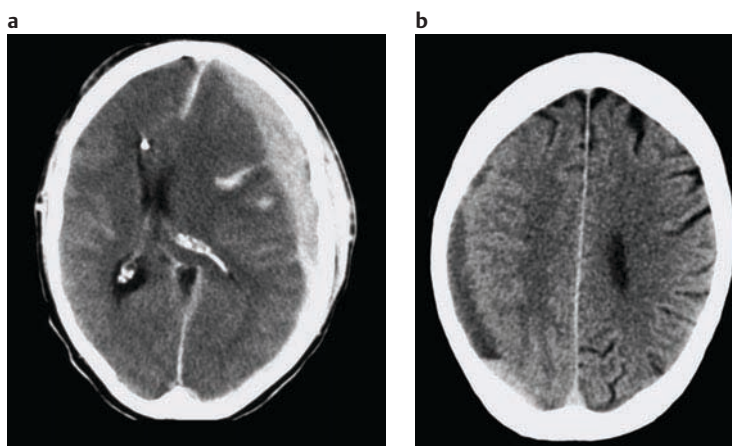
Fig. 14.23 This unhappy young man strangled himself in an effort to commit suicide. The hypoxia has led to a generalized edema. There are no hemorrhages to note on the precontrast image (not shown). The normal bright structure in the midline is the falx cerebri. The contrast-enhanced CT shows the superior sagittal venous sinus dorsally. The bright spots ventrally in the midline are the anterior cerebral arteries; the very dense midline spots a little dorsal to the center are typical calcifications in the pineal gland.

## Epidural Hematoma



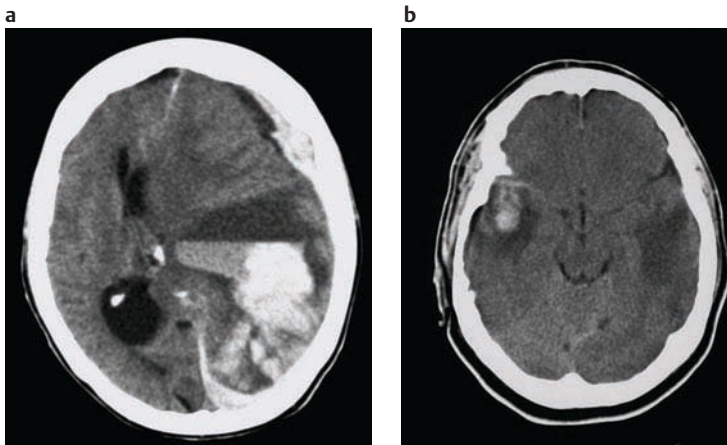
**Fig. 14.24 a** The initial CT was performed immediately after the polytraumatized patient had reached the emergency unit. There is a considerable right-sided scalp hematoma. There is no evidence for cerebral edema; the midline structures are not shifted. **b** A few hours later, the patient has become comatose. Repeat study reveals a typical epidural hematoma in the right frontal region. The bleed does not traverse the coronal suture (arrow) posteriorly. The brain surface appears considerably indented (“steamhammer effect”). The midline is now shifted to the left by more than 1.5 cm. Not only the brain but also the supplying cerebral arteries are displaced and consequently squeezed against the falx cerebri and the tentorium. Immediate relief by craniotomy is needed to save this patient. **c** The follow-up study after the craniotomy documents the detrimental consequences of the midline shift. The vascular territories of the anterior and posterior cerebral artery as well as parts of the territory of the medial cerebral artery on the right are swollen and decreased in density—all of this is indicative of brain infarction. Parietally on the right there is an additional brain hemorrhage—due either to a traumatic contusion or to a hemorrhagic infarction. There is some residual postsurgical air seen in the epidural space. The midline shift has decreased only minimally—by now it is caused by the pronounced edema of the right hemisphere. **d** In this neonate who fell off the table during a diaper change, a right frontal epidural hematoma is accompanied by severe global edema.

## Subdural Hematoma



**Fig. 14.25 a** This patient was involved in a high-speed motor vehicle accident and suffered a head trauma. As a consequence, a large subdural hematoma developed on the left that spread over the surface of the brain and led to a substantial midline shift. The brain contusion has resulted in an intraparenchymal hemorrhage, which is seen frontally on the left. Faint subarachnoid blood is seen bilaterally (see Fig. 14.27 for comparison). Immediate neurosurgical intervention is also necessary in this patient. **b** This woman complained about a continuing headache since she hit her head against a low ceiling in her basement. The cranial CT shows a right-sided chronic subdural hematoma that has a fluid–fluid level (serum above and the erythrocytes in the dependent part of the hematoma) and very little resulting mass effect.

## Intracranial Hematoma



**Fig. 14.26 a** There is a small left-sided subdural hematoma and severe hemorrhage into the brain parenchyma in the occipitoparietal region in this patient. The hemorrhage shows layering. The additive mass effect of both disease processes increases the intracranial pressure and causes severe midline shift, which is probably also the reason for the obstructive hydrocephalus of the right lateral ventricle. The right posterior horn of the lateral ventricle is grossly dilated. The ongoing CSF production further contributes to the intracranial pressure increase. Surgical decompression of the ventricular system is crucial to give the patient a chance of survival. **b** In another patient, a deceleration trauma has led to a brain contusion temporally on the right (and a fracture, not visible in this window setting) with an associated contrecoup contusion temporally on the left.

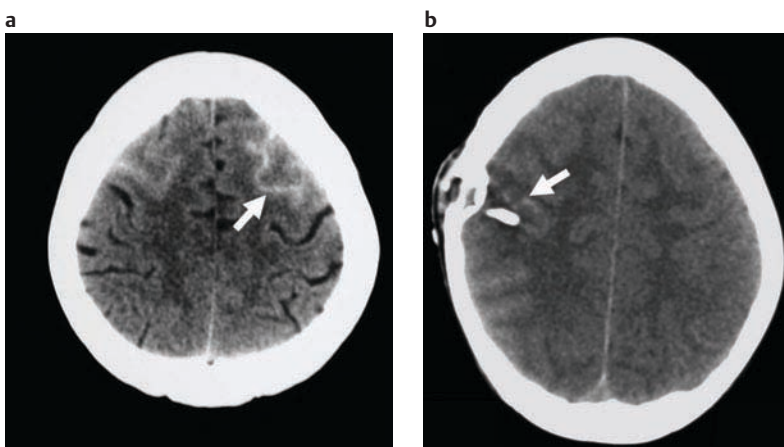
this interval, the better the chances of survival. Both the acute and the subacute subdural hematoma may be treated by neurosurgical drainage through one or several burr holes in the skull or openly with craniotomy and evacuation. The *chronic subdural hematoma* (Fig. 14.25b) may not become symptomatic until weeks after the underlying marginal trauma. If necessary, it is also flushed and drained via a burr hole.

**Intracranial hematoma:** An intracranial hematoma (Fig. 14.26a) can also occur as a sequel of a severe brain contusion. It may be relieved surgically. In deceleration trauma, “coup” and “contrecoup” lesions may be seen (for the few non-francophiles: punch and counter-punch). These consist of hemorrhages in opposing regions of the brain (Fig. 14.26b). In addition, smaller *subarachnoid he-*

*morrhages*—detectable as fine bright lines or dots within the sulci—can occur as a collateral injury (Fig. 14.27). Subarachnoid hemorrhages (SAH) in the absence of significant trauma are most often caused by rupture of a pre-existing aneurysm and resulting hemorrhage (see p. 235, Chapter 11).

Paul’s head is spinning, but finally he makes up his mind: there is a classic epidural hematoma along the left superior convexity of the brain. The scalp in this area is swollen as consequence of a direct trauma. The sulci are swollen and the white-matter/gray-matter distinction is decreased, both findings indicating locoregional cerebral edema. Occipitally on the right the sulci are filled with blood. This is a subarachnoid hemorrhage as part of a “contrecoup” phenomenon. The ventricular system is

## Intracranial Hematoma with Subarachnoid Hemorrhage



**Fig. 14.27 a** Here you see a small subarachnoid hemorrhage (SAH, arrow) that was associated with an occipital brain contusion a few centimeters lower. Note the filling of the sulcus with dense blood. **b** A punch with an iron rod caused this depressed fracture of the skull on the right side. Amazingly, a subtle SAH (arrow) is the only resulting intracranial abnormality.



dilated considerably, which must be due to an obstruction of the CSF drainage. The reason for this remains obscure for Paul, but Gregory comes in time and solves the puzzle: he points out the blood in the right posterior horn of the lateral ventricle, where a small fluid–fluid interface with the CSF is present. Somewhere there must be a parenchymal bleed that has ruptured into the ventricular system. The tiniest blood clot from this source can obstruct the aqueduct connecting the third and fourth ventricles and thus lead to hydrocephalus requiring surgical ventriculostomy. Patient A is transferred immediately to the neurosurgical OR.

### Patient B

Meanwhile, another heavily traumatized patient (B, name unknown, male, about 45 years old) is rushed into the CT scanner.



### What Must Paul Consider in Deceleration Trauma?

Paul knows that aortic injuries are one major problem after high-speed motor vehicle accidents and other deceleration traumas. A rupture of the aortic wall is only survived if the adventitia, the outer wall of the aorta, remains intact. The aortic arch is held in place by the outflows of the cervical vessels and the ligamentum arteriosum (the remnant of the fetal ductus arteriosus of Botalli, which runs between the superior surface of the origin of the left pulmonary artery and the inferior surface of the arch of the aorta; It passes superolaterally from inferior to superior attachments, the latter is about the level of the origin of the left subclavian artery from the aorta). Ninety percent of all aortic ruptures originate directly distal to the ligamentum arteriosum. They may be associated with a dissection.

**Radiograph and CT of the chest:** A CXR that was performed in another primary care hospital shows a mediastinal widening (Fig. 14.28a). As a consequence, the otherwise stable patient was transferred immediately. Paul initiates a dissection protocol type chest CT pre and post contrast administration (Fig. 14.28b).

### Checklist: Chest CT in Polytrauma

- Is there hemorrhage in the mediastinum?
- Are all large vessels normal?
- Is there air present in the mediastinum?
- Is there fluid in the pericardium?

**Aortic injury:** An *incomplete aortic rupture* (Fig. 14.29a)—the complete rupture is not survived—fortunately causes a detectable mediastinal widening in about 80% of cases. In up to 50% of cases a simultaneous hemothorax is seen. The aortic rupture is best appreciated by rapid spiral CT, where the aorta can be reconstructed in three dimensions or in fine two-dimensional slices. If this technology is not available, catheter-based transfemoral aortography needs to be performed. A pseudoaneurysm (Fig. 14.29b–d) is the natural sequel of an untreated incomplete aortic rupture. *Aortic dissection* (Fig. 14.29e, see also p. 79) is frequently associated.

**Cardiac injury:** A cardiac injury is also possible in deceleration trauma. Hemorrhage into the pericardium, leading to tamponade, is the most frequent injury requiring surgical intervention. Penetrating trauma, for example, a stab wound (Fig. 14.29f) or a gunshot injury, may also result in pericardial tamponade. The fluid in the pericardium restricts the cardiac movement and thereby diminishes the cardiac throughput—fast diagnosis is thus essential.

! Patients with preexisting aortic aneurysms (see p. 85) or lipomatosis of the mediastinum (Fig. 14.29g) or infants with a well-developed thymus also demonstrate a wide mediastinum on the CXR.

Paul scrutinizes the CT with great care image by image. He diagnoses a pseudoaneurysm of the aortic arch. Later the finding is confirmed during aortography (Fig. 14.30).

### Patient C

By now the third heavily traumatized patient (C, name unknown, female, about 45 years of age) is wheeled into the resuscitation room. She is conscious and is breathing spontaneously; several peripheral venous cannulas have been inserted and she wears a cervical collar. Joey is now in charge of the ultrasound machine.

**Radiography of the chest and rib series:** The CXR is felt to be within normal limits. A skin bruise on the left lateral thorax and pain in this area prompt a rib series (Fig. 14.31a). This shows a fracture of the 8th rib.

! A fracture of the lower bony thorax should alert you to potential severe trauma of underlying abdominal organs and must be correlated with an ultrasound or CT examination of the abdomen.

## Patient B

## a Radiograph of the chest

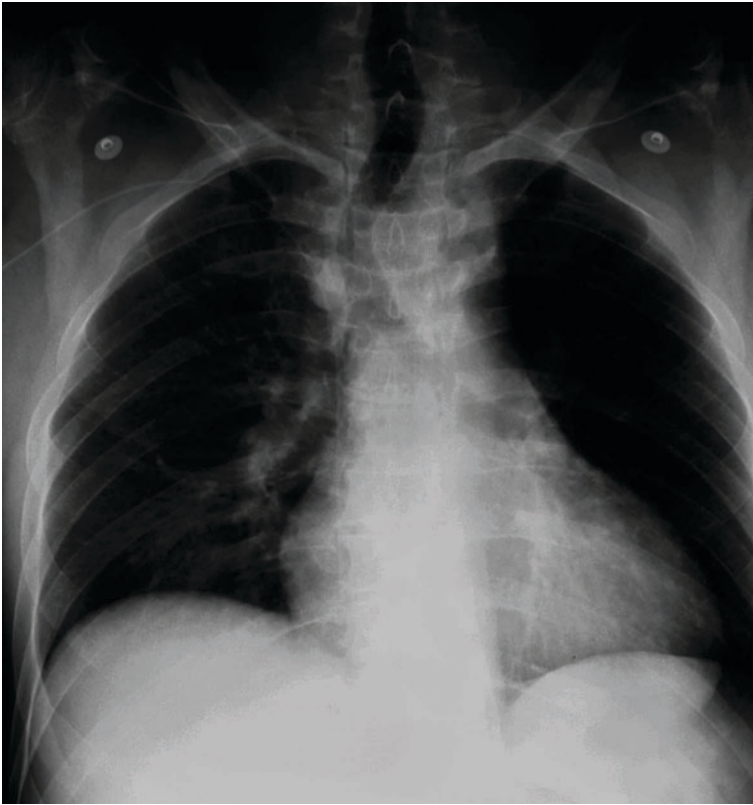
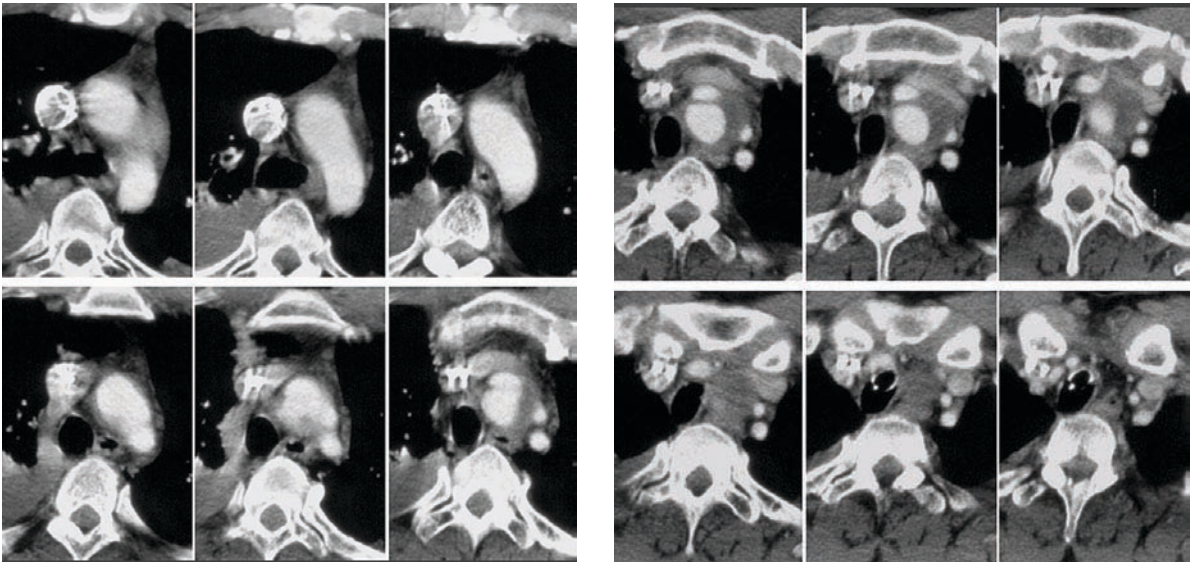


Fig. 14.28 a This is the chest radiograph that led to the immediate transfer of the patient to the trauma center. The upper mediastinum appears widened. Are you sure the patient is well positioned?

**b** Go ahead and trace the aortic arch and its branches on the consecutive slices. Try to form a three-dimensional model of the arch in the back of your mind. Now try to rotate it.

## b Chest CT



### Causes of Mediastinal Widening

#### a Incomplete aortic rupture

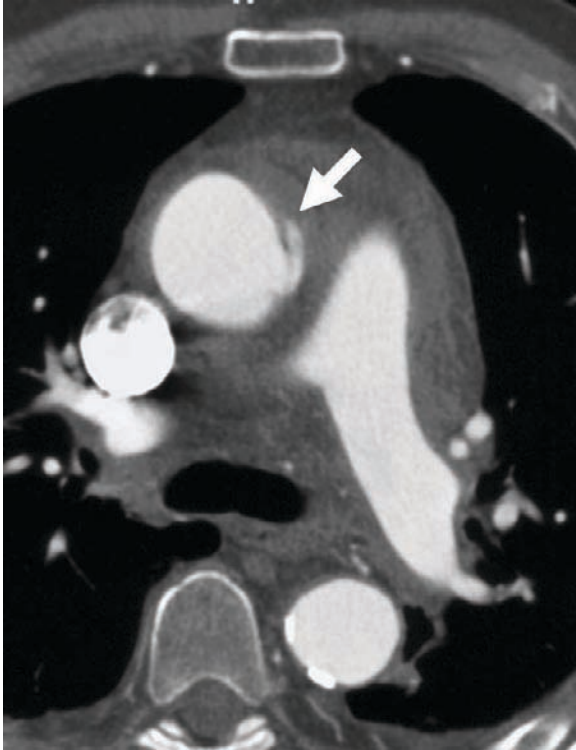
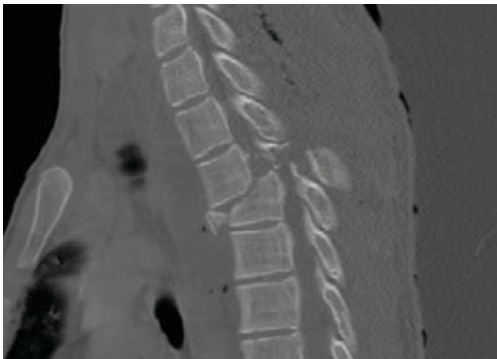
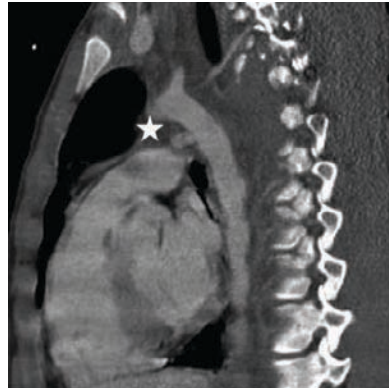
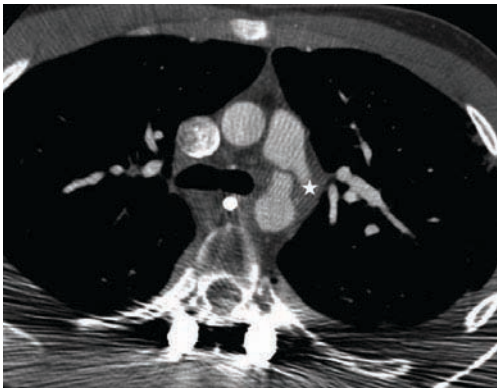

Fig. 14.29 **a** This CT shows an incomplete rupture of the ascending aorta. The leakage of contrast into the defect of the intima and media is seen well (arrow). **b** In this patient a pseudoaneurysm has formed in the typical location close to the ligament of Bothalli (star). **c** The sagittal reconstruction of the aortic arch shows the aneurysm (star) in its relation to the spine to better advantage. **d** The sagittal reconstruction of the thoracic spine depicts the fracture of the adjoining vertebral body emphasizing the brutal force of the trauma.

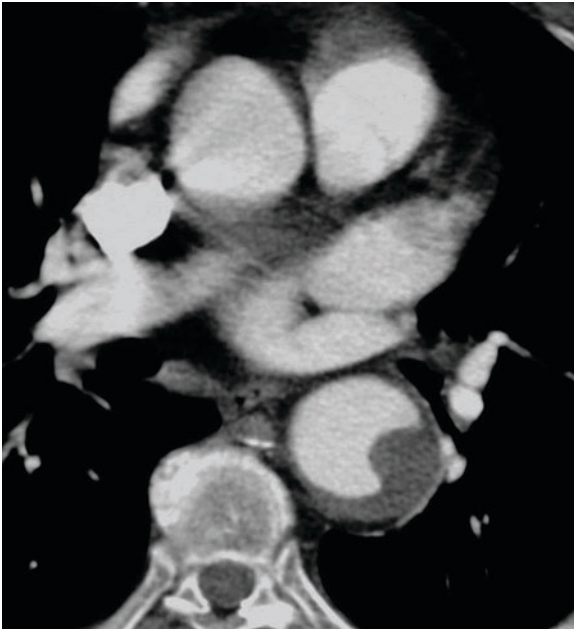
#### b-d Traumatic pseudoaneurysm



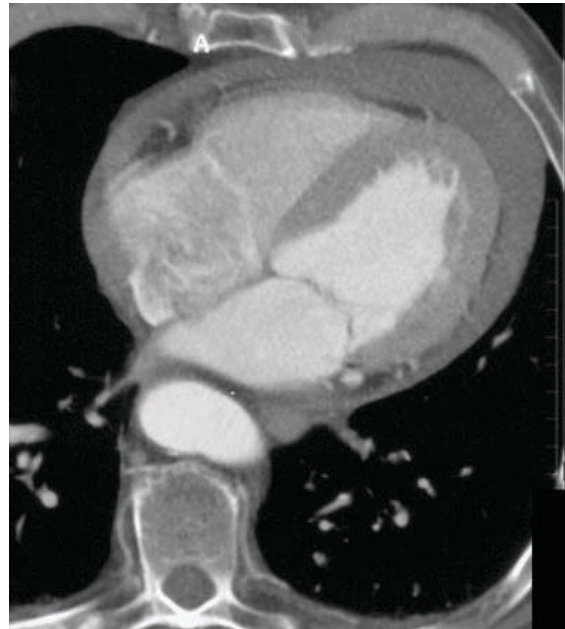


## Causes of Mediastinal Widening

e Aortic dissection



f Hematopericardium



g Mediastinal lipomatosis

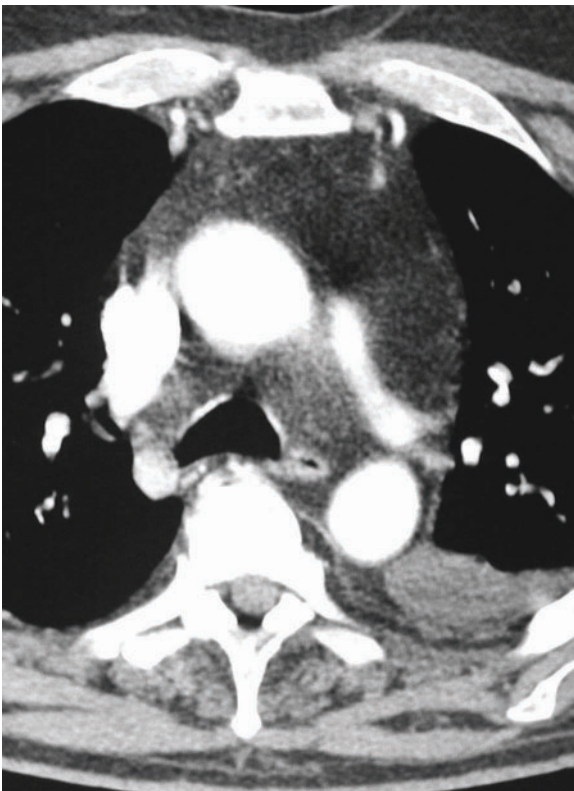


Fig. 14.29 **e** A hematoma of the wall of the descending aorta has been the sequel of a severe chest trauma in this patient. This is a precursor of a full-blown aortic dissection. **f** A heated exchange of arguments among friends climaxed in a knife stab directly into the heart. The pericardium is filled with blood—rapid surgical intervention is imperative. **g** The large vessels are surrounded by a wide fatty tissue cuff. Compare the density of the subcutaneous fat. Only CT can diagnose mediastinal lipomatosis with certainty in an emergency setting.

### Patient B: Aortography

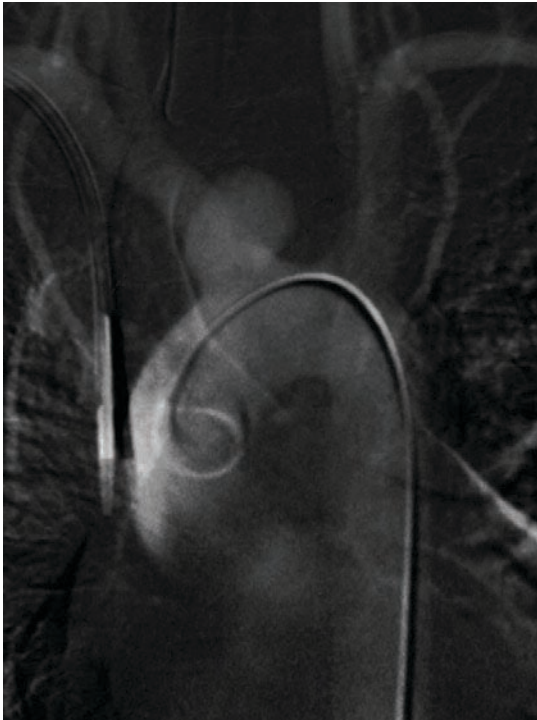


Fig.14.30 A catheter that has the shape of a pigtail is located in the aortic arch. This digital subtraction angiography image (the images acquired before and after contrast administration are subtracted from each other) shows the cranial bulge of the aortic lumen close to the origin of the brachiocephalic trunk. This is a false aneurysm. The diagnosis fits very well with the conventional chest radiograph findings (see Fig. 14.28a): The trachea has been displaced to the right by the aneurysm.

**Ultrasound and CT of the abdomen:** During the ultrasound examination, Joey takes a particularly good look at Morrison's pouch (Fig. 14.31b), where free fluid in the abdomen tends to accumulate first. Owing to its location and consistency, the spleen is the abdominal organ most at risk for blunt injury. Contusions, lacerations, and ruptures of spleen (Fig. 14.32a, b) and liver (Fig. 14.32c) as well as bleeds from larger vessels into the open abdomen (Fig. 14.32b) are readily appreciated on CT images.

! Remember that the amount of hemorrhage may be decreased in severe shock. After circulatory stabilization, bleeds may intensify and manifest with some delay.

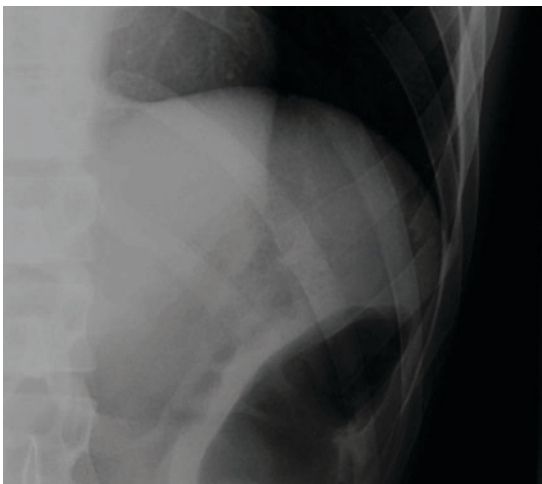
Free fluid in the abdomen in a trauma patient can also have other causes. Trauma may rupture the bowel or induce bursting of a full urinary bladder. Bleeds may also arise in the retroperitoneum, particularly in renal injuries, which often become symptomatic with hematuria (Fig. 14.33).

! In a patient with polytrauma, the parenchymal organs of the upper abdomen and especially the retroperitoneum are not sufficiently examined by ultrasound. An abdominal CT is indicated in all cases of doubt and severe trauma. Ultrasound may be useful as a rapid screening tool to detect conditions that require immediate surgical attention even prior to a trip to the CT scanner, such as pericardial hematoma/tamponade, hemothorax, and large amounts of free fluid in the abdomen requiring immediate emergency laparotomy.

Joey immediately worries about splenic rupture, having seen the obvious fracture of the 8th rib on the left side. The ultrasound aspect of the space of Morrison reinforces

### Patient C

#### a Radiograph of left hemithorax



#### b Abdominal ultrasound

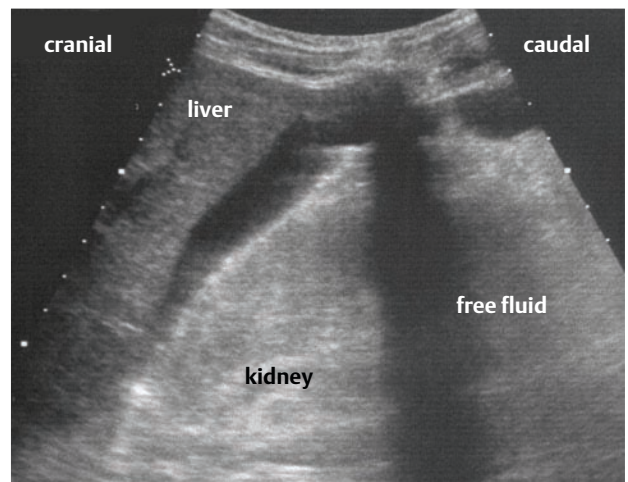
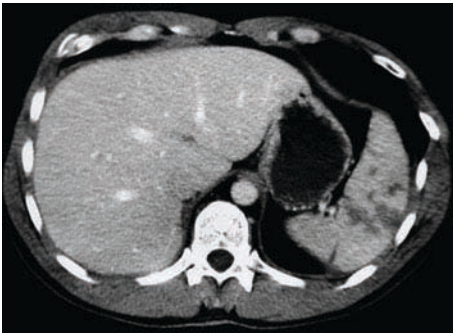

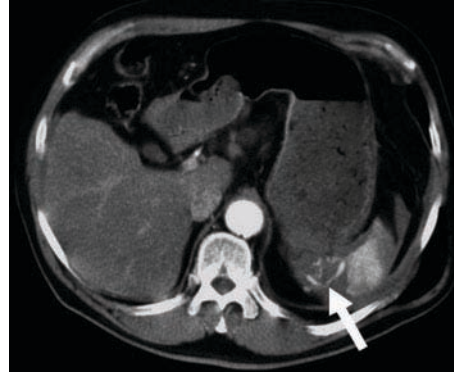
Fig. 14.31 Here you see the radiograph of the left lower hemithorax of patient C (a) as well as a parasagittal ultrasound section through the liver and the right kidney (b).

### Causes of Free Fluid in the Abdomen

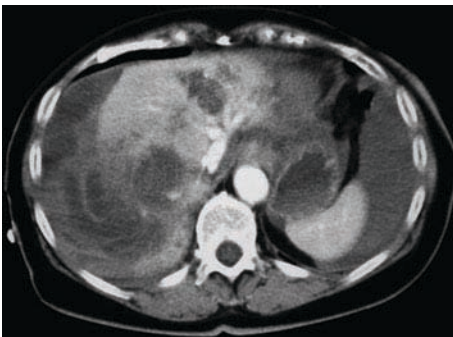
**a** Contained splenic rupture



**b** Splenic rupture with active extravasation of blood

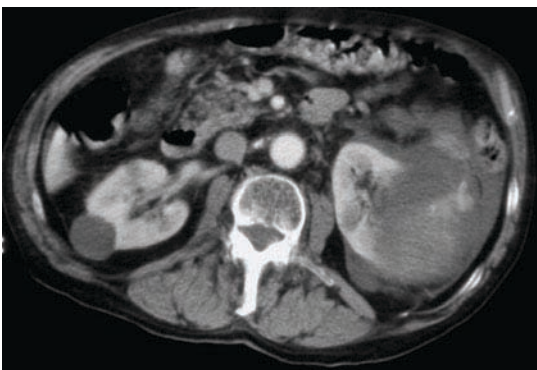

**c** Liver rupture



**Fig. 14.32 a** In this patient a splenic tear has occurred, which luckily has not led to a full-blown bleed into the into the peritoneum. This is an incomplete splenic rupture or splenic laceration. **b** This splenic rupture in another patient exhibits active extravasation of blood into the peritoneum. You recognize the active bleed by appreciating the contrast media-enhanced blood within the intra-abdominal hemorrhage (arrow). This young man was not the victim of an motor vehicle accident but—chained to his own bed—of rather unorthodox sexual habits of his latest boyfriend. In a sexual frenzy the friend attacked and stabbed him with a knife—26 times. Luckily the patient recovered to full health, but he became a little more fussy picking his sexual partners. In any case, the injuries kept the trauma surgeons entertained for quite a while. **c** This is a liver rupture (compare the normal liver in **a** and **b**) due to a blunt abdominal trauma. This lady was treated with thrombocyte aggregation inhibitors because of advanced coronary arteriosclerosis. She called the ambulance during a heart attack. When the ambulance team arrived, she could still open the door but then collapsed. The team resuscitated her successfully on the spot but noted signs of shock a little later. The liver rupture caused by the resuscitation was diagnosed rapidly with an abdominal CT and was later addressed surgically. The patient was lucky: the surgery was successful and she returned home a few weeks later. Hepatic and splenic ruptures and pericardiac injuries occur rarely during resuscitations—rib fractures are common.

### Retroperitoneal Hemorrhage



**Fig. 14.33** On this image you see documented a rupture of the left kidney associated with a retroperitoneal bleed. Fractures of the transverse spinous processes were also seen on that side. The patient had severe hematuria after a motor vehicle accident.

his suspicion: There is a considerable amount of fluid between the liver and the right kidney, indicative of visceral organ rupture—most likely of the spleen. The spleen itself is difficult to image in its entirety as it is partially obscured by the overlying lung. Abdominal CT is performed immediately and confirms the diagnosis (**Fig. 14.34a**).

**Radiographs of the spine:** Meanwhile, the radiographs of the spine are ready for Joey's analysis (**Fig. 14.34b**). He studies them with great care and quietly, despite the trauma surgeons' breathing down his neck.

First of all Joey looks at the configuration of the spinal column. Do all the auxiliary lines along the anterior and posterior edge of the vertebral bodies and along the spinous processes appear smooth and well defined? Are the individual vertebral bodies configured normally? Joey looks at every single body, trying to imagine a three-dimensional and complete model of it in the back of his mind.



## Patient C

## a Abdominal CT

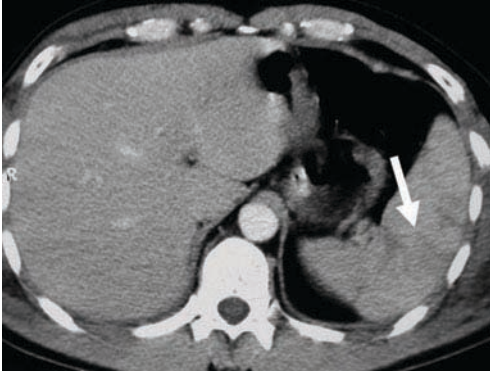
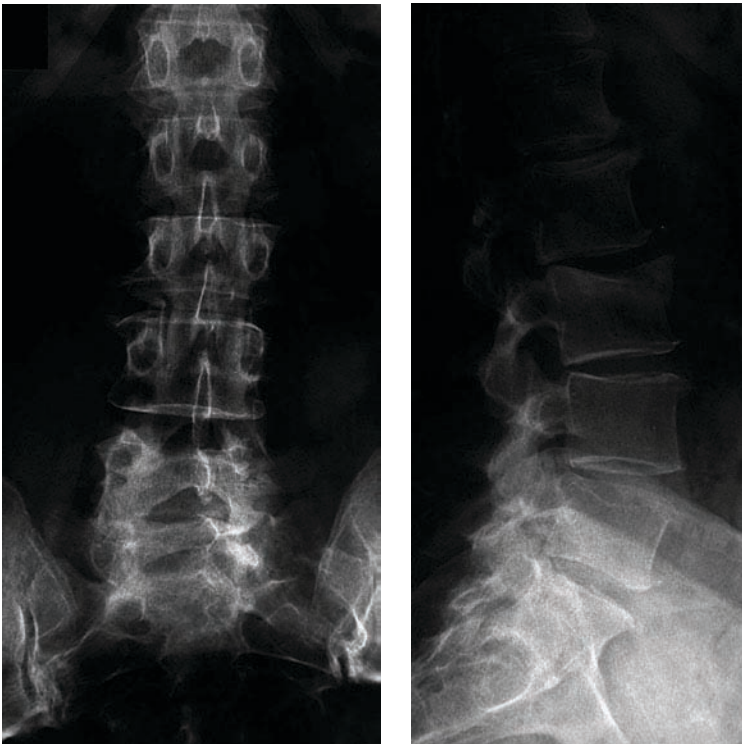
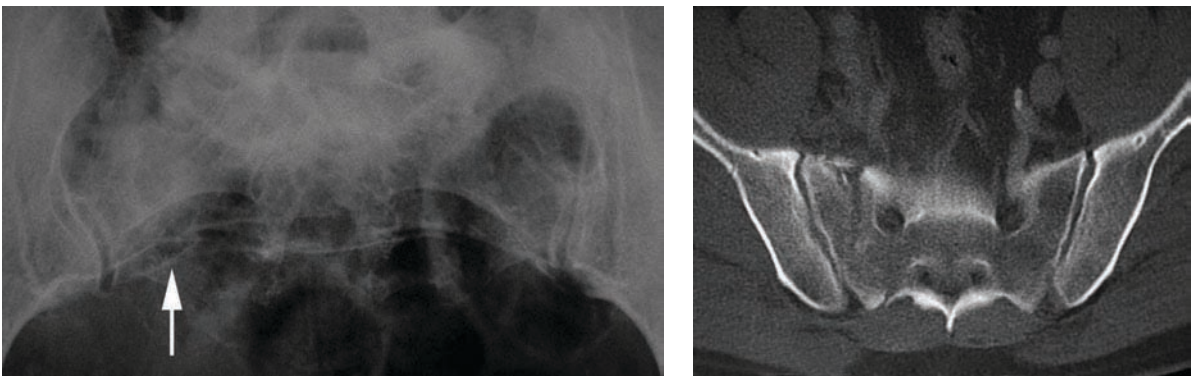


Fig. 14.34 **a** The spleen is ruptured (arrow). **b** Note the radiograph of the patient's lumbar spine. Does anything strike you as abnormal? **c** The second and third right foraminal arches of the sacral bone are interrupted (arrow), which means that the right sacral ala is fractured.

## b Radiographs of the spine



## c Radiograph and CT of the pelvis



**!** One predominant question in the evaluation of a spinal column fracture is whether the spinal canal and/or the neural foramina are involved and how.

Does a fracture affect the posterior column of the vertebral body? This is always the case if the vertebral body is diminished in height dorsally. To determine this, measure the height of the vertebral body immediately underneath and immediately above—vertebral body height normally increases incrementally in the caudal direction. Does the spinal canal appear narrowed? This is of particular importance above the level of L3 because the spinal cord reaches down to that level. Is the dorsal vertebral arch involved? If that is the case, instability looms, which can seriously damage the spinal nerves along their course through the potentially narrowed neuroforamina. Joey makes up his mind and calls a fracture of the anterior vertebral edge of L3. The keeper of the notes hardly suppresses a yawn because the staff surgeon had called this diagnosis minutes before when Joey was still busy doing the ultrasound.

**Radiograph and CT of the pelvis:** In the meantime, the radiograph of the pelvis has also been put up on the view-box (Fig. 14.34c). The evaluation of the pelvis, particularly of the sacral bone, is frequently compromised by the superimposition of bowel content. Helpful structures are the sacral neuroforamina: analyze their outline carefully and in comparison to the contralateral side. Are they completely visible and smooth or are there defects, a step-off, or irregularities? Frequently a fracture of the sacral bone continues on cranially into the lumbar transversal processes. Are these truly intact? In the region of the iliac bone and the anterior pelvic ring, superimposition is less of a problem. But remember that posterior pelvic fractures often go along with another fracture of the anterior pelvic ring and vice versa. If no fractures are found, the width of the pubic symphysis and the iliosacral joints should be scrutinized. Somewhere the pelvic ring must have given way. By the way, the pubic symphysis is wider in women who have given birth than in those who have not.

Joey has not detected any fractures in a first quick glance over the pelvic radiograph. Gregory, who seems to be everywhere at the same time today, puts his finger on the film. The foraminal arch of S2 on the right is interrupted. CT confirms a sacral fracture (Fig. 14.34c).

## 14.2 Luxations and Fractures

The severe, acute, and life-threatening injuries of the polytraumatized patients from the highway collision have been taken care of radiologically by now. Our students return to the routine radiological examinations and procedures occurring in the Emergency Room of our vibrant city in this world. What is better to describe

the numerous dislocations and “small” fractures than a good old fashioned movie style row? By the way: all fractures can be classified. Check your favorite trauma surgery book for the latest fashion in nomenclature.

### Checklist: Luxations and Fractures

- Is the relevant region documented in two projections?
- Are the projections truly perpendicular to each other?

### Eastside Story

There has been a brawl between two rival youth gangs on the outside staircase of the beer garden quite close to the hospital. One of the participants is well known to the emergency team head, Mr. Webber, and is welcomed with a warm handshake. Members of both groups are now sitting in the waiting zone, groaning with pain but still irreconcilable, and kept at a distance only by one robust policewoman. She knows just about enough about what has gone on during the confrontation: a certain “Ayeesha” and a lot of alcohol. The x-ray techs cross the injured off their worklist one by one. Fortunately, the hotheads become a little calmer in the x-ray room once their peers disappear from

### Fractures of the Metacarpal Bones 4 and 5

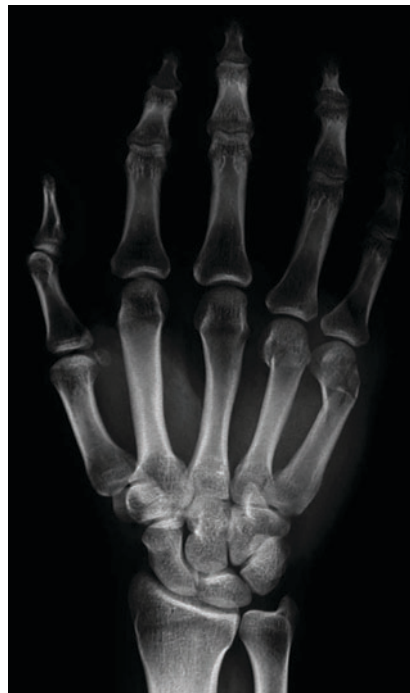

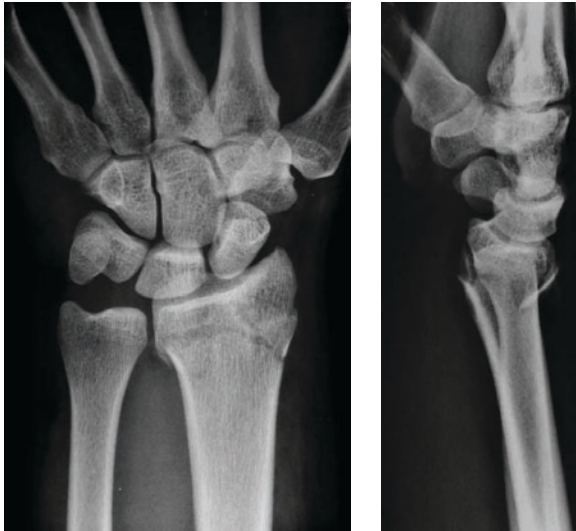
Fig. 14.35 If Dung does not get his temper under control he will get this typical fistfighter injury more often. His 4th and 5th metacarpal bones are fractured and deviated to the palmar side. The respective radiograph of Sylvester Stallone or Bud Spencer would certainly be of interest for comparison.

sight. Joey calls Ajay and Paul as a reinforcement. Each grabs a couple of report forms and jots down the consequences of the brawl.

Dung apparently punched Ayeesha's brother Fuad with his fist when Fuad screamed at his sister and wanted to slap her in the face. Since then his hand hurts badly (Fig. 14.35). Fuad's jaw withstood the punch but while

### Distal Radius Fracture

#### a Extension fracture (Colles type)



#### b Radius edge fracture (Smith type)

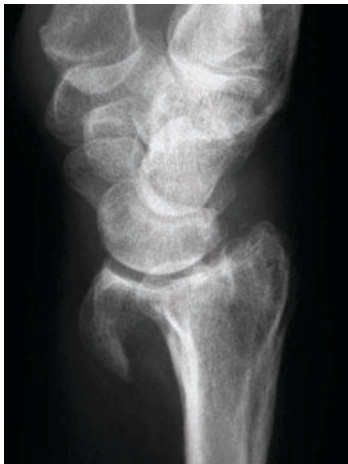

Fig. 14.36 **a** Fuad has suffered the most frequent fracture of the distal radius, the extension fracture of the Colles type. In this type of injury the distal fragment of the radius is displaced and angled dorsally, giving it the appearance of a fork (fourchette or bayonet configuration). Fuad is lucky—the articular surface is not involved and the ulna is positioned correctly. An ulnar protrusion would point to an injury of the triangular fibrocartilage and would have to be corrected in due time. **b** Eyad has landed on the back of his hand: he has a Smith-type flexion fracture in which the distal fragment is deviated to the palmar side. Unfortunately, Eyad's fracture involves the articular surface.

evading the attack he lost balance and fell a few steps down the stairs and on his hand (Fig. 14.36a). He dragged his drunk friend Eyad with him, who tried clumsily to stop his own fall with his left hand (Fig. 14.36b). The colossal Eyad got so mad he tore a wooden picket off the fence and assaulted Dung with it. Dung's friend Nam intervened and fended off the move forward (Fig. 14.37). Hoang jumped on Eyad's back, only to be shaken off and get his hand stuck between the pickets of the fence (Fig. 14.38). Faris, Fuad's first-degree cousin, lost his balance on the staircase while trying to draw himself up to full size and fell off the side of the stairs onto the concrete. Now his lower arm is swollen and hurts considerably (Fig. 14.39). Thanh had just a little hand in Faris's fall, which is why Faris's buddy Ghazi pushed him to the ground. His elbow joint is now immobile and painful (Fig. 14.40).

Oh yes, and Ayeesha took the opportunity to have a nice cappuccino with Dung's sister Hue in a close-by street café. From there the two girls called a bunch of ambulances to the site by mobile phone. They figure the boys are off their backs for the next few hours.

Meanwhile Joey, Ajay, and Paul are sick and tired of looking at radiographs of people who smash themselves up and they all leave for a cup of coffee. Hannah has dropped in a little too late to get the eastside action but she is definitely ready for some more.

### Ulnar Fracture

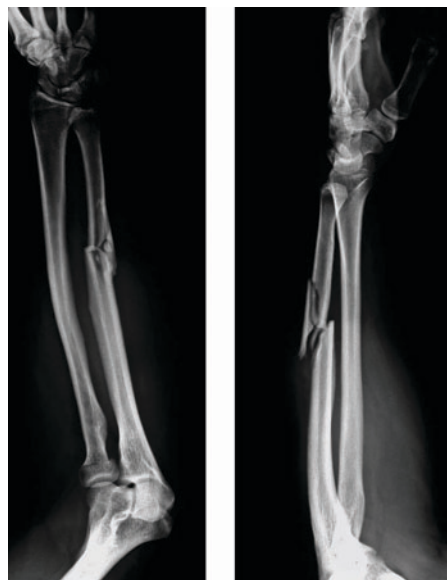

Fig. 14.37 Nam has warded off the blow with his forearm, or parried it. An isolated wedge fracture of the ulna has resulted—also called the “parry fracture.” The little notch at the radial head is a sequel of a previous injury.



## Fracture of the Scaphoid Bone

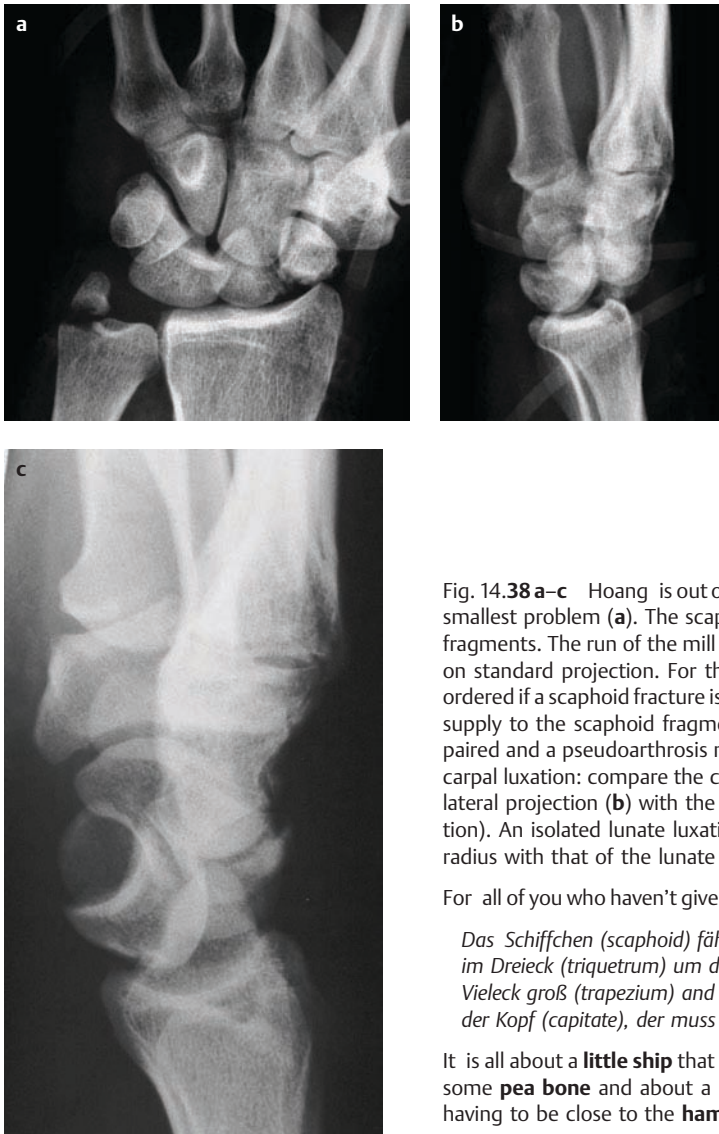

Fig. 14.38 a–c Hoang is out of luck. The bony avulsion of his ulnar epicondyle is his smallest problem (a). The scaphoid is fractured, with a couple of rather displaced fragments. The run of the mill scaphoid fracture is often so subtle it can be missed on standard projection. For that reason additional angled special projections are ordered if a scaphoid fracture is anticipated. Fractures may easily interrupt the blood supply to the scaphoid fragments, which is why the healing process may be impaired and a pseudoarthrosis may eventually develop. Hoang also has a perilunate carpal luxation: compare the configuration of the lunate and capitate bone on the lateral projection (b) with the correct situation seen in Fig. 14.36a (lateral projection). An isolated lunate luxation can also occur (c): compare the position of the radius with that of the lunate to determine whether they are aligned or not.

For all of you who haven't given up on German classes here is an anatomical helper:

*Das Schiffchen (scaphoid) fährt im Mondenschein (lunate)  
im Dreieck (triquetrum) um das Erbsenbein (pisiform),  
Vieleck groß (trapezium) and Vieleck klein (trapezoid),  
der Kopf (capitate), der muss beim Hammer (hamate) sein.*

It is all about a **little ship** that sails in the **moonlight** in a **triangular** course around some **pea bone** and about a **large polygon** and a **small polygon** and the **head** having to be close to the **hammer** (the last of which we should all subscribe to).

## Galeazzi Fracture

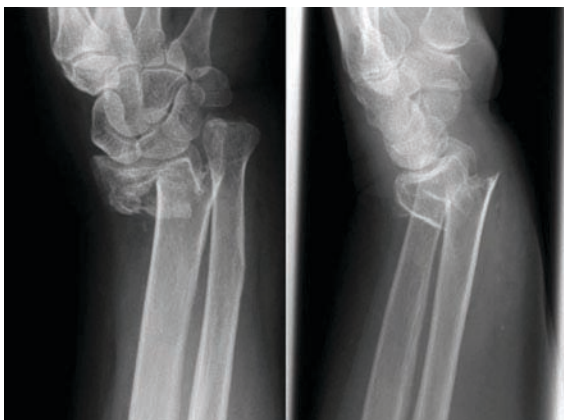

Fig. 14.39 Faris has sustained a severe distal radial fracture and a dislocation of the distal ulna. This is a common fracture named after Galeazzi. If the ulna is fractured proximally and the capitulum of the radius is luxated, this is called a Monteggia fracture. The difference between the two can be remembered using the following if rather homespun and complicated memory hook:

Bella ragazza (Italian for “beautiful girl”) – radius fracture (Ra) = Galeazzi (gazza).

## Fracture of the Radial Head

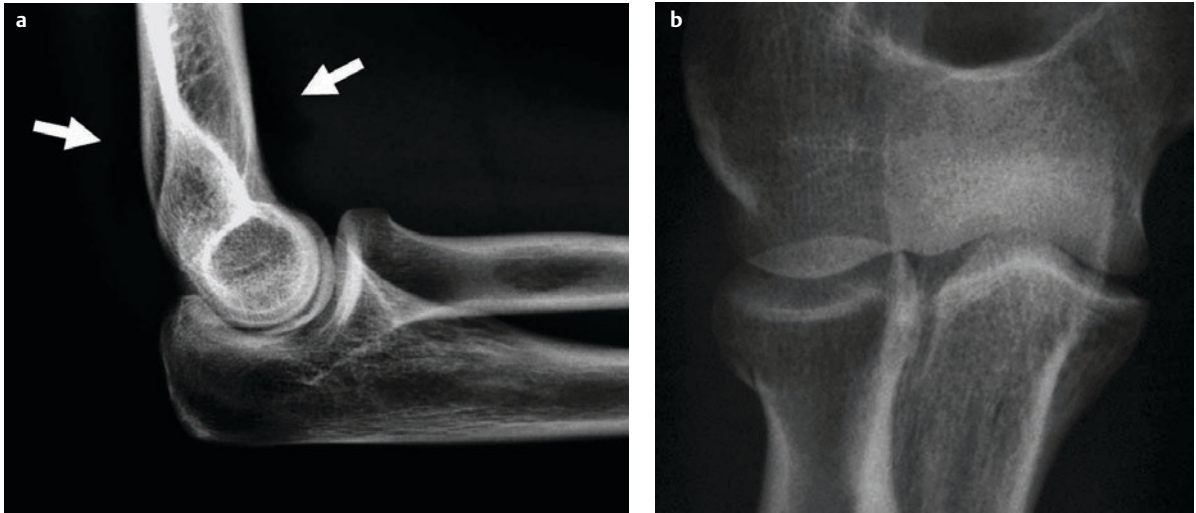


Fig. 14.40 **a** Thanh has an effusion in his elbow joint. The effusion lifts the fat pads normally located in the coronoid and olecranon fossa and adherent to the articular capsule out of hiding (arrows). When you see this positive fat-pad sign, the patient has

an elbow fracture until proven otherwise, most likely of the radial head. **b** The anterior-posterior projection confirms the suspicion: There is a subtle step in the contour of the head on the ulnar side.

## Shoulder Luxation

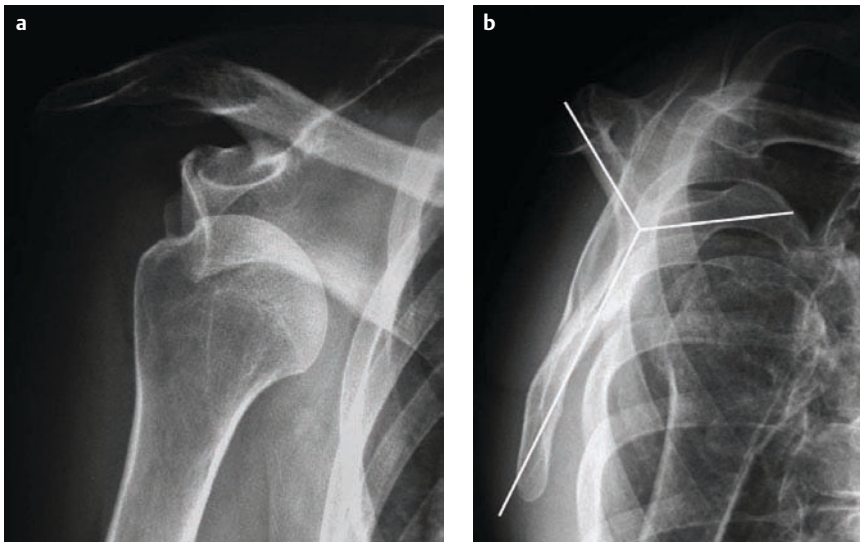


Fig. 14.41 **a** Mr. McClellan has an anterior shoulder dislocation, the most common type. **b** The tangential view of the scapula (also called Y- or “Mercedes star” view owing to the form of the scapula in this projection) shows the humeral head ventral and caudal to the glenoid, which is situated in the center of the Y. If the anterior instability is severe and re-

current, it often results in varying degrees of impression fracture of the dorsolateral circumference of the humeral head (“Hill-Sachs lesion,” but subtle in Mr. McClellan’s case). In addition, during dislocation, impact of the humerus on the bony anterior glenoid process of the scapula may occur (“Bankart lesion”).

### Medial Femoral Neck Fracture

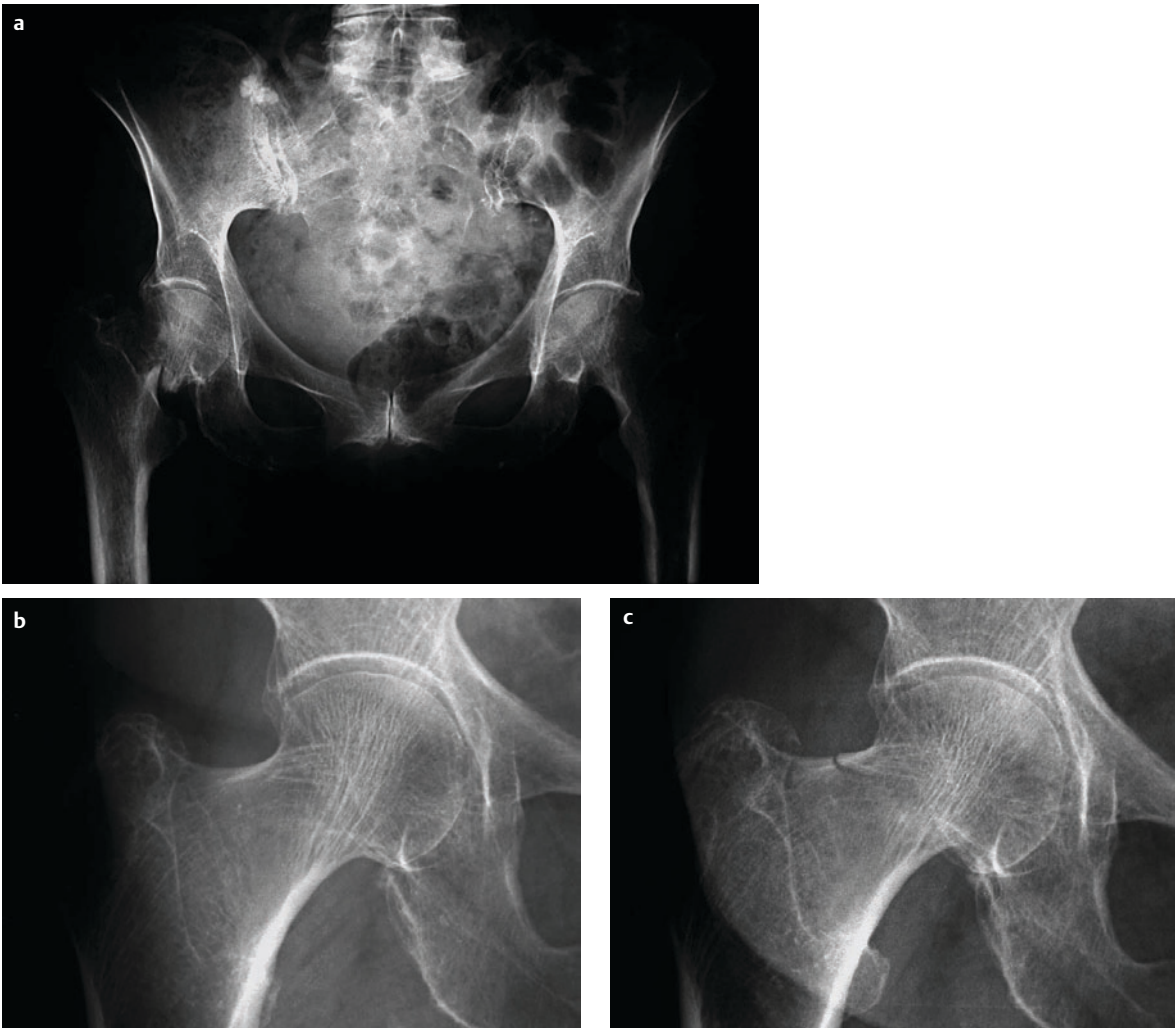


Fig. 14.42 **a** Nadine Rothman has suffered an injury quite typical for her age: a medial femoral neck fracture, which she is at risk for because of her osteoporosis. The fracture is classified according to its angle as Pauwels I–III (approx. 30°, 50°, and 70°). The more acute the angle of the fracture, the higher the degree of instability and the risk of avascular necrosis of the femoral head or pseudoarthrosis formation. What do you think of a Pauwels III in this case? A femoral neck fracture is

not always so obvious. **b** In Mrs. Rothman's girlfriend, Anastasia, no fracture was found on the initial radiograph taken right after a fall and consecutive pain in the right hip. **c** A week later (the pain did not recede) the radiological diagnosis was clear. In such cases bone scintigraphy may also be helpful because it shows the increased bone turnover at a fracture site at an early stage when it might otherwise be invisible. MRI is more costly but would also show the bone bruise.

#### Unlucky Fellows

While on his daily walk through the Royal Botanic Garden this morning, retired stockbroker Rob McClellan lost his balance on slippery ground and fell on his shoulder. He has not been able to move his shoulder since (Fig. 14.41). His girlfriend Nadine Rothman tried to help him up but also fell on the slippery concrete. Now her right hip is painful and she cannot move her leg anymore (Fig. 14.42a). McClellan's grandson

Philipp who had joined them for the walk, tried to come to their help on his inline-skaters at full speed and fell on his arm in the process of braking (Fig. 14.43). Hannah has a look at the radiographs of the pitiful bunch.



## Greenstick Fracture

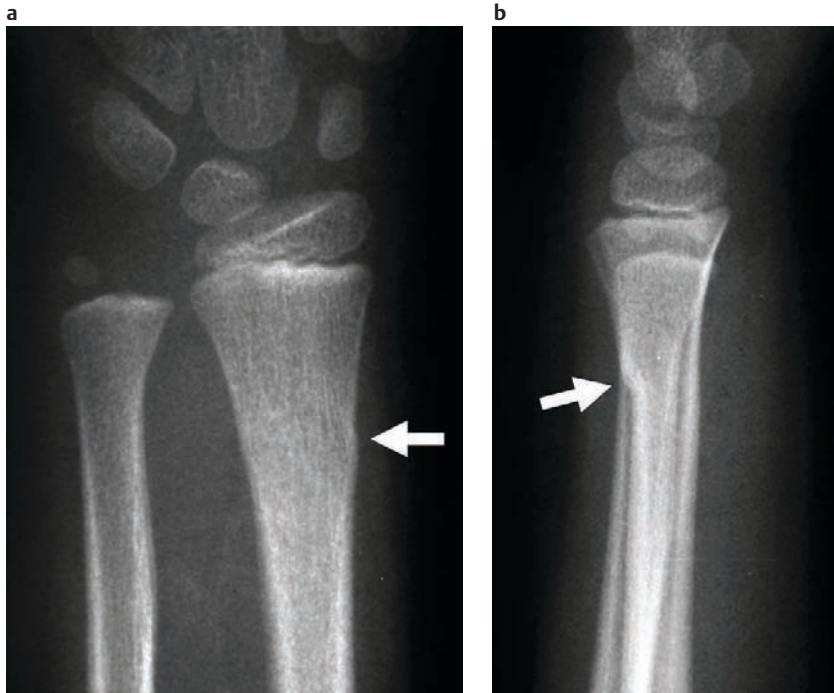


Fig. 14.43 In children the bone can break without seriously injuring the periosteal cuff around it. This is called a greenstick fracture. Frequently the only sign is a little bulge of the cortex

(arrow in **a** and **b**). Philipp has a greenstick fracture of the distal forearm, which will heal rapidly when sufficiently immobilized with a cast.

## Femoral Shaft Fracture

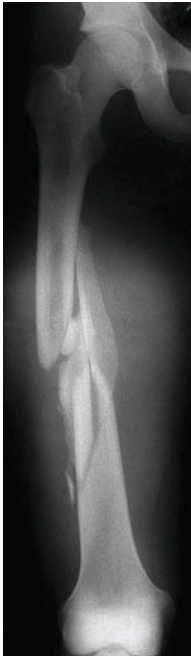
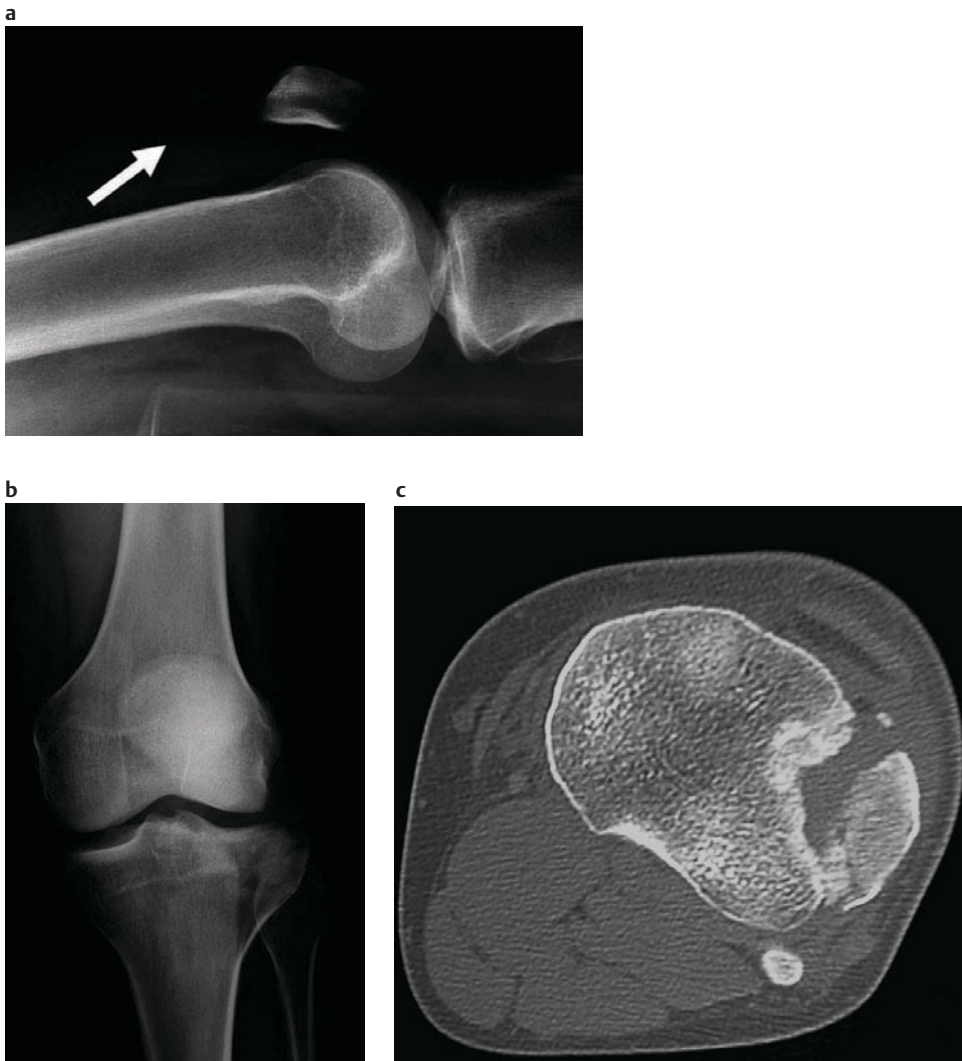
Fig. 14.44 Hank has suffered a comminuted fracture of the femoral shaft. The soft tissue shadow indicates a severe hematoma and soft tissue injury.

## Surfing

The opportunities for avid surfers within the city are limited—but there are ways for the desperate and the airheaded. Hank and his friend Dude are a little bit of both, and to a dangerous degree. After participating in the annual Mardi Gras parade, drunk as skunks, they surfed on the train coupling of the last suburban line to Bondi Junction and fell off at full speed. Fortunately, they were found quite quickly by some other nighthawks. Hank is lying apathetically on a vacuum mattress with his right thigh severely swollen (Fig. 14.44), Dude complains about pain in his right knee (Fig. 14.45) and left foot (Fig. 14.46). Hannah reviews the films toward the end of her shift.

## Tibial Head Fracture



**Fig. 14.45 a** The lateral radiograph already points to a fracture of the tibial head. The pronounced knee joint effusion in the suprapatellar bursa shows a fluid–fluid interface (arrow) indicating a suspended layer of fat, which proves the communication of the joint to the fatty bone marrow. (By the way, this image also helps to understand why life-threatening fat embolism can occur after fractures of large tubular bones.) Only CT could

theoretically exclude a fracture in this setting with sufficient certainty. **b** The anterior–posterior radiograph clearly demonstrates the tibial fracture. **c** Before approaching this articular fracture, the surgeons often ask for a CT with 3D reconstructions to find out preoperatively which type of screws should be put in and where. The reconstruction of the articular surface is crucial for the treatment result.

## Ankle Joint Fracture

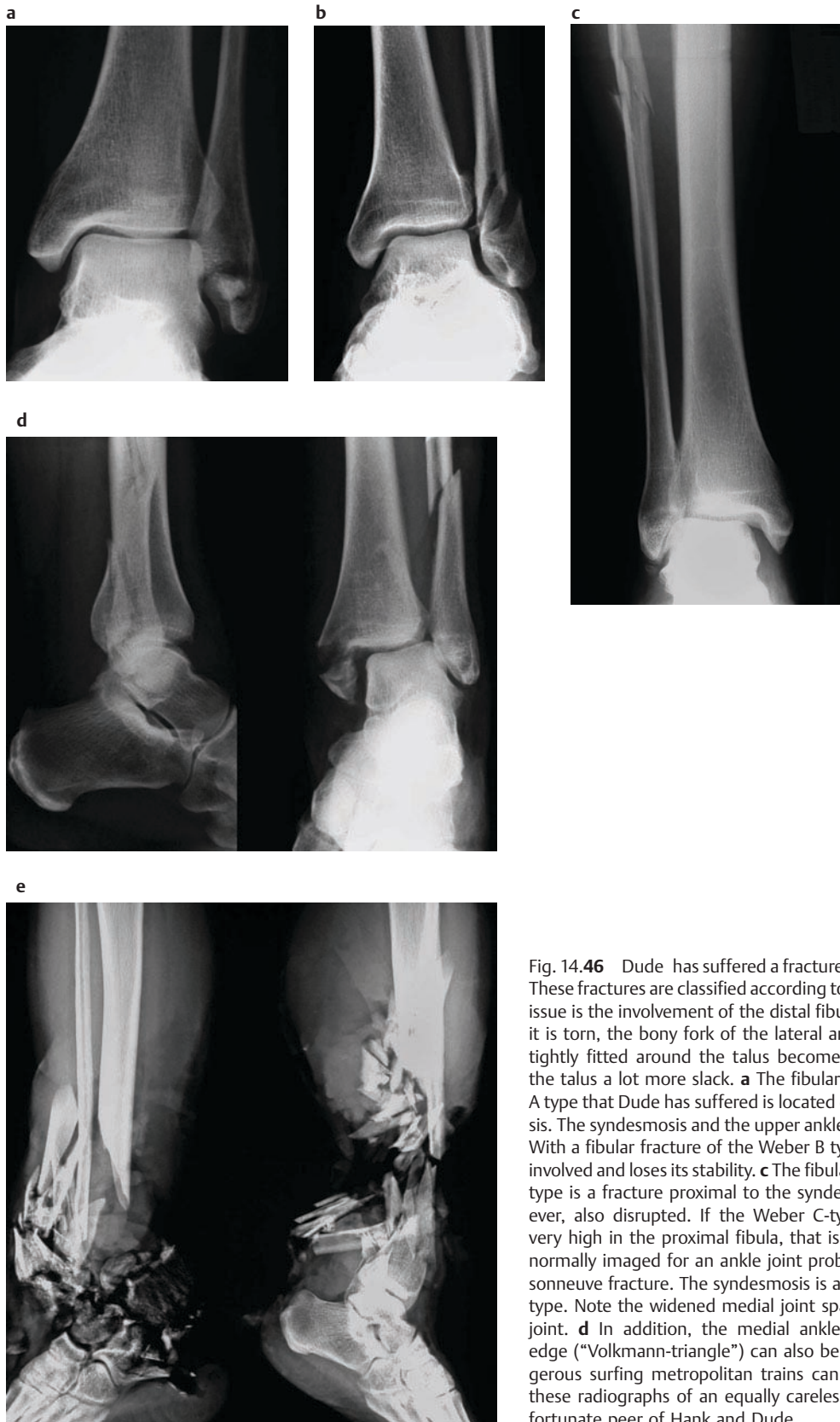

Fig. 14.46 Dude has suffered a fracture of his left lateral ankle. These fractures are classified according to Weber. The important issue is the involvement of the distal fibulotibial syndesmosis: If it is torn, the bony fork of the lateral and medial ankle that is tightly fitted around the talus becomes dysfunctional, giving the talus a lot more slack. **a** The fibular fracture of the Weber A type that Dude has suffered is located distal to the syndesmosis. The syndesmosis and the upper ankle joint are thus intact. **b** With a fibular fracture of the Weber B type, the syndesmosis is involved and loses its stability. **c** The fibular injury of the Weber C type is a fracture proximal to the syndesmosis, which is, however, also disrupted. If the Weber C-type fracture is located very high in the proximal fibula, that is, outside of the region normally imaged for an ankle joint problem, it is called a Maisonneuve fracture. The syndesmosis is also torn in this fracture type. Note the widened medial joint space of the upper ankle joint. **d** In addition, the medial ankle and the dorsal tibial edge ("Volkman-triangle") can also be fractured. **e** How dangerous surfing metropolitan trains can be is documented by these radiographs of an equally careless but considerably less fortunate peer of Hank and Dude.



## 14.3 Hannah's Test

Hannah is just about to leave the trauma imaging unit as Greg turns the corner. "Where is everybody?" he asks Hannah in despair. "Giufeng, Joey, Ajay, Paul—they all seem to have left. Probably hitting the student pubs and gargling ale by now. Typical!" Greg complains. "No-one to play with, is that it, Gregory?" grins Hannah. "Actually I'm really on my way myself but you could do me a favor and run through these cases with me (Fig. 14.47), before I go to Giufeng's party." Gregory pales. "Now don't tell me you don't know of the party, Greg!" Gregory gives a deep sigh and collapses into the seat in front of the view-box. "Good lord, Greg, this seems to be really serious. Have you been misbehaving?" Gregory waves his hand weakly. "Come on, Greg. Be tough. This is an academic department, remember? Let's do these cases and then you can simply come along with me." Hannah taps his shoulder. Go ahead and help Gregory! He and Hannah really want to get going to this private beach party.



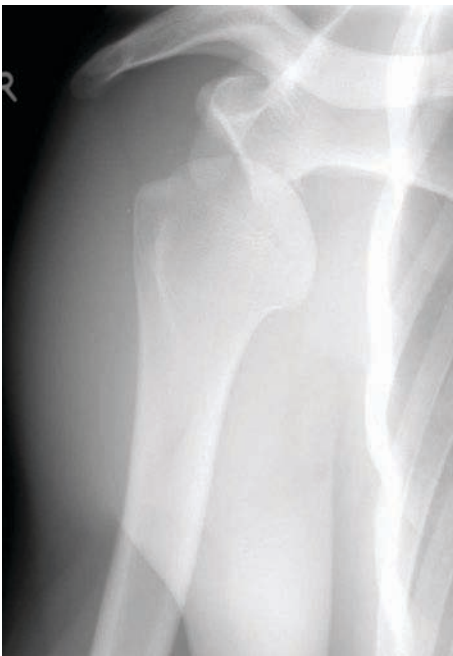### One Truly International Colleague Who Made a Dent in Trauma Survival

Geoffrey Jefferson was a Manchester-born neurosurgeon who worked in St. Petersburg during World War I, where he served in the Anglo-Russian Hospital, a gift of the British Empire to the Russian ally. Obviously he gained a lot of experience with severe trauma during that time. He became a skeptic witness of the 1917 communist October revolution. He earlier practiced in Canada where his wife came from; later in the war he worked in France. He described the typical fracture of the atlas in 1920. One of his wise sayings comes in handy to end this book:

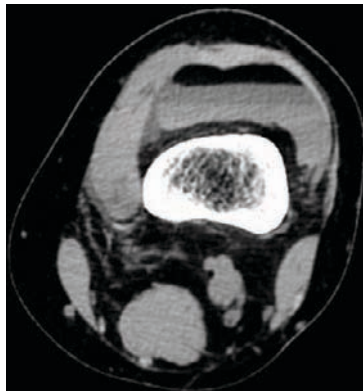
**"Material gains play a small role in life's equation. The great advantage is to be allowed to work with things you enjoy."**

### Test Cases

a This patient cannot move his arm after a fall.



b This history is withheld, but we still want the complete diagnosis.



c This patient came straight off the highway and is in shock.

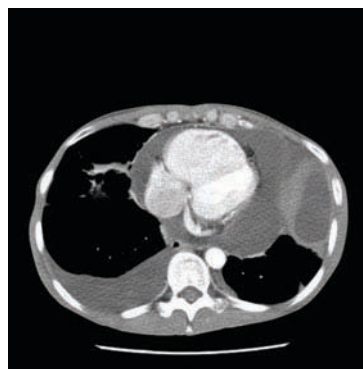
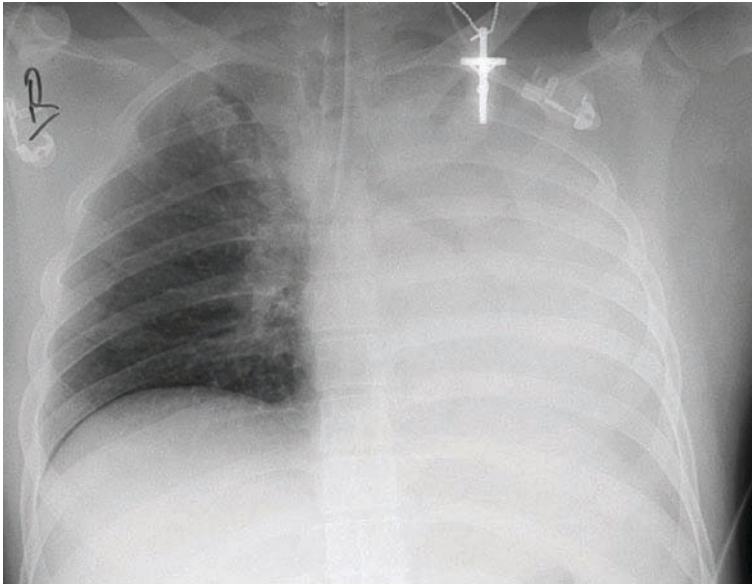


Fig. 14.47

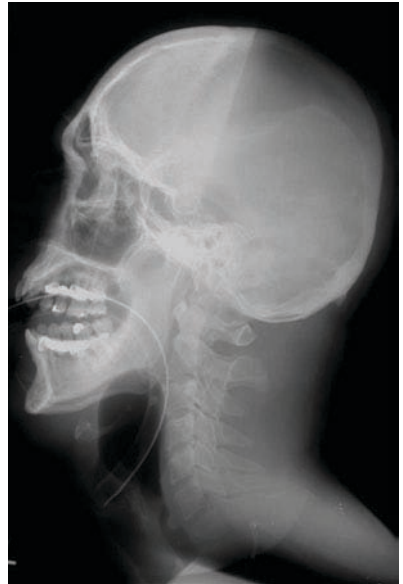

**Test Cases**

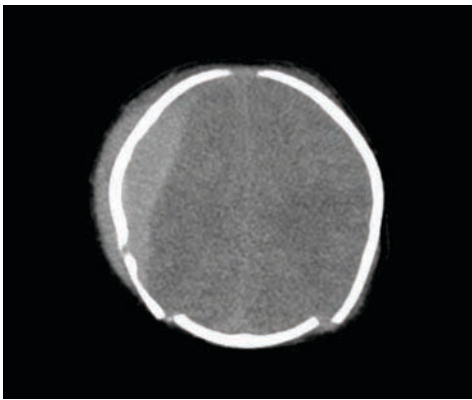
d This patient has just been brought in by helicopter.



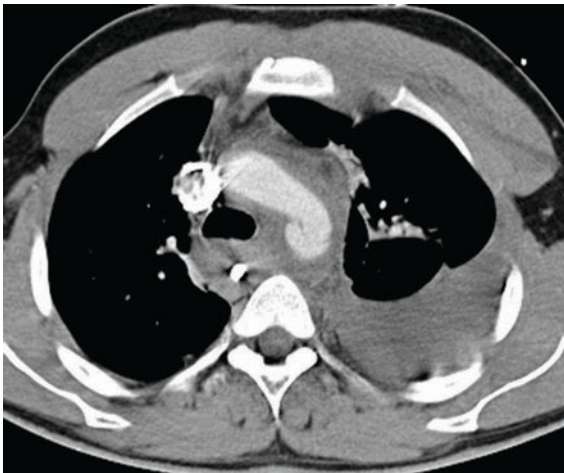
e Question: Cervical fracture?



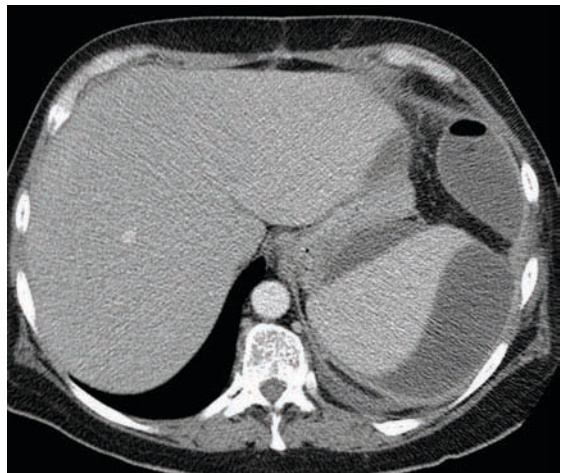
f This child was brought in comatose by the parents.



g This patient had a high-speed motor vehicle accident and the chest radiograph was abnormal.



h Unspecific abdominal pain of two weeks' duration.



**Test Cases**

i-| This is the great wrapper-upper case of this book. Observe, analyze, reason, remember, discuss, and reach a comprehensive diagnosis! All images belong to one patient. Go one by one. Take your time. Write us an email ([george.w.eastman@thieme.com](mailto:george.w.eastman@thieme.com)) if you made it. Good luck!

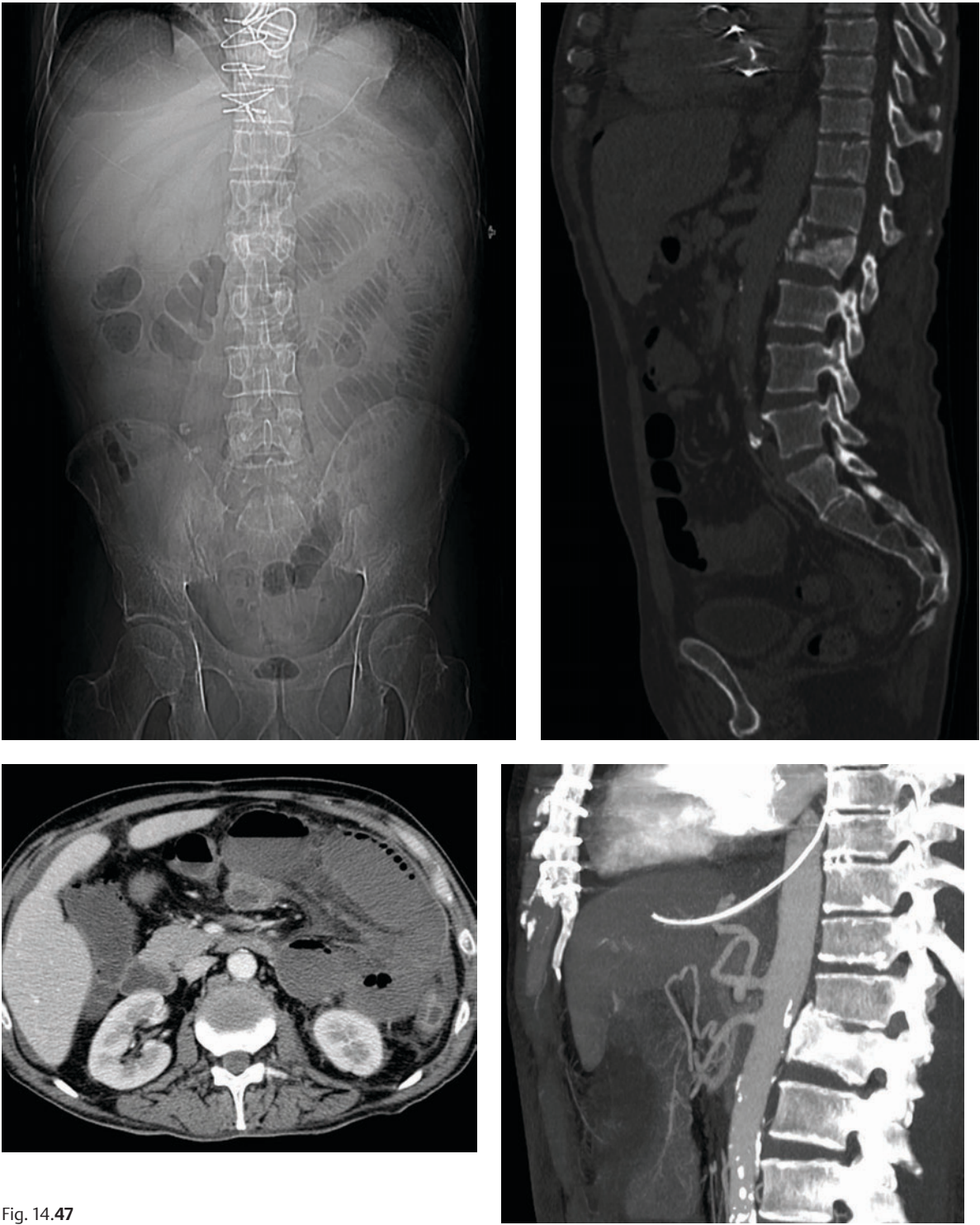


Fig. 14.47



# Solutions to the Test Cases

## Chapter 6

Fig. 6.76 **a** This is a type B aortic dissection—the dissection is limited to the descending aorta. The false lumen can be distinguished from the true lumen by residual fiber strands connecting the intimal flap to the media. The true lumen is the smaller lumen—which shows more contrast enhancement in this case. **b** There is a large tumor in the anterior mediastinum. The trachea is narrowed down to a “saber sheath” configuration. In an acute setting, such as in this case with upper venous congestion, a lymphoma is the most likely cause. A large retrosternal goiter could produce a similar appearance. **c** This CT image shows massively dilated bronchi over all lung fields. This is severe bronchiectasis in cystic fibrosis. **d** The redistribution, the Kerley lines, an accentuated horizontal fissure, unsharp vascular markings, “bronchial cuffing,” and an enlarged heart prove a cardiogenic pulmonary edema. **e** The thick-walled cavern in the right lung apex occurred in an HIV-positive patient—this is tuberculosis until proven otherwise. Tuberculosis it turned out to be. What would you do next if you saw this patient? Of course, for starters you would make sure the patient had a face mask. **f** The radiograph depicts a pneumonia of the right upper lobe and some of the middle lobe. The bronchi are well seen against the background of the pus-filled alveoli. **g** The severely increased interstitial markings in the periphery (Kerley lines) and centrally (reticular or netlike pattern) suggest an interstitial process. The HRCT (**right**) confirms the thickened interlobular septa in a patient with carcinomatosis of the pulmonary interstitium. **h** The left lung is overly transparent, hypovascular, and volume-reduced in this patient. He suffered from recurring pulmonary infections in early childhood until the age of 12. Right—this is Swyer–James syndrome.

## Chapter 7

Where and when should the informed consent of the patient be achieved? This should best be done the day before the study, either in the office or on the ward but never where and when the study is performed. Which parameters should be watched? Prothrombin time should be >50%, partial thromboplastin time <35 seconds, and thrombocyte count >50 000/ $\mu$ l. Acetylsalicylic acid (ASA/aspirin) should be discontinued a week before deep-body interventions are performed.

Here is the great case: Figure 7.18a shows a close up view of the ribs. The infracostal margins are very irregular—they are being remodeled by the enlarged and varicose intercostal arteries in aortic coarctation. Compare this to the normal ribs of Fig. 6.5a. As the aorta is stenosed in this entity (see the sagittal T1-weighted MR; **b**), the descending aorta is filled via intercostal collaterals and via arteries in the abdominal wall (see the MR angiography; **c**). After the insertion of a stent (see the conventional angiography; **d**), the stenosis is reduced to a moderate level without the risks of open chest surgery (see the sagittally reconstructed CT; **e**).

## Chapter 8

Fig. 8.83 **a** There is malalignment at the C4/C5 level much like the degenerative spondylolisthesis seen in the lumbar spine. Ventral osteophytes and disk space narrowing in the lower cervical spine support the notion of a degenerative cause. **b** The C2 vertebral body in this man has turned sclerotic: this is an osteoblastic metastasis of a prostate carcinoma. **c** The hand appears demineralized in comparison to the radial metaphysis. The soft tissues appear to be swollen. This was Sudeck disease. Remember: The clinical symptoms must fit! **d** The width of the radiocarpal joint space is diminished radially. The bordering bone is sclerosed. The scaphoid shows a little osteophyte, the lunate seems a little out of line. This is a posttraumatic osteoarthritis and lunate malalignment. **e** This is a patient with ankylosing spondylitis: both iliosacral joints appear to be fused, more so on the right. **f** They do not come more pathognomonic than this: a gigantic chondrosarcoma engulfs the right half of the pelvis. **g** This is a typical nonossifying fibroma—no further measures are needed. **h** Right. This is an osteoid osteoma of the talus. **i** It is a severe inherited osteosclerosis of the Camurati–Engelmann type. **j** The patient suffers from multiple myeloma. **k** The os lunatum shows a dense inhomogeneous structure. You are looking at an osteonecrosis of the lunatum, also termed Kienboeck disease. It is a little sister of the femoral head necrosis. If you diagnosed this by yourself, either you are a genius or you have leafed through one of those fat books on skeletal radiology. In either case—congratulations! **l** This patient suffers from low back pain. Paget’s disease of the sacral bone is the diagnosis.

## Chapter 9

Fig. 9.70 **a** This is a carcinoma of the hypopharynx that originates from the piriform recess. **b** Sentinel loops in the small intestine with air–fluid levels at different heights point to a mechanical (obstructive) ileus. **c** This is a diverticulosis of the descending colon. **d** A scrotal hernia is present bilaterally. **e** Did you diagnose the splenic cyst alright? **f** This is the radiograph of a neonate without any air in the stomach and small intestine. This is a definite sign of esophageal atresia. **g** This is what a tapeworm looks like in a barium study. **h** This patient suffers from chronic pancreatitis. **i** Have you recognized the liver metastases and the ascites? **j** Did you notice that most air is in the small bowel but none in the distant colon and rectum? Did you also see the dilated air-filled loops of the proximal colon? This is a cecal volvulus! Some contrast media rests in the bowel are also appreciated. **k** This is a cecal volvulus. **l** This patient was referred from a mental institution because he had ingested something. What material might it be? (It was mercury taken from an old thermometer.) **m** No excuses if you did not get this one: It is a severe gangrene of small and large bowel due to mesenteric infarction. **n** Now this one was for the real egg-heads: Contrast is in the vena cava and the liver veins, but not in the aorta. Two theoretical possibilities that one can think of: (a) This is remote: the contrast is given via a vein of the lower extremities—that would never give you that solid filling of the ves-

sels because the venous return of the kidneys would mix in. (b) This is the solution: The patient has severe right heart insufficiency so the contrast flows through the superior vena cava past the heart right into the inferior cava and the liver veins. Of course, the contrast is given via the veins of the arm, as almost always. And, by the way, some people call this the “playboy bunny” sign. **o** This patient felt uneasy after a long flight as a “body packer.” The sealed drug packages were swallowed before the flight. A leakage of the containers, of course, means serious health trouble for the poor fellow.

#### Chapter 10

Fig. 10.21 **a** This is a pelvic kidney with a renal cell carcinoma. **b** Here you see a posttraumatic priapism. The pubic symphysis is torn, the left iliosacral joint is opened: The configuration is also called an “open book” injury. The genitals are enlarged owing to hemorrhage, thrombosis, or edema. **c** This is what a calcified transplant kidney looks like. **d** There is a tumor thrombus that has grown through the vena cava into the right atrium. This patient had a renal carcinoma. **e** Did you diagnose the renal hematoma alright? **f** Did you detect the concrement in the left kidney? This is nephrolithiasis. **g** The lesion in the kidney is a manifestation of lymphoma. If you appreciated the tumor in the mesentery ventral to the aorta you probably got it right. If you overlooked that tumor, remember the “satisfaction of search” effect (Chapter 3).

#### Chapter 11

Fig. 11.57 **a** There is a C7 disk prolapse on the left that significantly compresses the spinal nerve. **b** This coronal MR image of the lumbar spine at the level of the kidneys shows an extra-axial, intrathecal tumor—a typical meningioma. The tumor has expanded the spinal canal **c** This spinal canal is extremely narrow owing to a congenital stenosis. **d** A right foraminal prolapse is seen on this CT. **e** If you have not detected it yet, take a step back! The left basal ganglia are hypodense—an early infarction may not become more obvious. CT perfusion would make the diagnosis a lot easier to reach. But there is no hemorrhage: thrombolytic treatment could start. **f** This dense media sign is pretty obvious: this is an early infarction of the right hemisphere. **g** This CT shows a frontal intracranial hemorrhage in combination with extreme edema.

#### Chapter 12

Fig. 12.29 **a** What you are seeing is a typical plasma cell mastitis. **b** The breast carcinoma (left image, large arrows) shows pronounced acoustic shadowing (right image small arrows).

#### Chapter 13

Fig. 13.30 The 48 is an impacted wisdom tooth; the 28 tooth has come through. A granuloma is visible at the root of the 45 tooth. The bridge between 25 and 27 is intact; the bridge anchored on tooth 14 reaches out into nothing. The crown of tooth 16 is broken and ground down. There are root fillings in tooth 16 and 35. Superimposed over 42–44 a sialolith is visualized sitting in the main duct of the submandibular gland.

#### Chapter 14

Fig. 14.47 **a** You are seeing a typical caudal shoulder luxation. You should now worry about impression fractures or avulsions of the glenoid. **b** Now this should have been so easy. If you did not diagnose this tibial head fracture by its indirect signs, go back and check Fig. 4.4b. This is the Dutch flag sign—this time in CT. **c** Extensive pericardial and pleural hemorrhage in a traumatized patient: an immediate chest intervention is necessary. **d** The tip of the tracheal tube sits in the right main bronchus. A complete atelectasis of the left lung has resulted. Thank god you were the one to analyze the image—you did get this one right, didn't you? **e** This is a cephalad malposition of the tube. Severe injury to the glottis will result. **f** A scalp hematoma and a subdural hematoma with severe edema was diagnosed in this young child. In not so clear trauma in children, always exclude battered child. **g** This is a posttraumatic aortic dissection (see the flap?) with left-sided hemothorax. **h** Two weeks after abdominal trauma this patient presented with pain—a delayed spleen rupture is present. **i, j, k, l** This was your chance to prove you've understood it all, you know how to reason, and you are just a little lucky. The scout view of the abdominal CT (**i**) displays an air-filled dilated loop of small bowel in the mid-abdomen. Note: A vertical beam is used in normal scout views, so air–fluid levels would not show. There is a definite problem of bowel peristalsis. The axial CT image (**j**) confirms the dilated small bowel and finds little air bubbles in the intestinal wall—the “string of pearls” sign. A necrosis of the bowel wall is most likely present. The sagittal reconstruction of the trauma spiral CT (**k**) tells you why the patient came to the hospital in the first place. The L2 vertebral body has been crushed in a deceleration trauma. What else might have happened in the process? The last CT reconstruction (**l**) wraps it all up: The trauma impact caused the L2 fracture and a dissection of the superior mesenteric artery, which led to the bowel necrosis, which was at the base of the developing ileus. Now go through the timewarp back to the first image (**i**) and search for the “string of pearls” and the fracture in that image—it was all our forefathers had for diagnosis.

## Post Scriptum

Our group of students has meanwhile left us, of course, and others are now in their shoes. We have, however, not forgotten this bright bunch and have kept an eye on their fate inside the global village with curiosity.

For starters, there is Paul—our born “mother’s-milk” radiologist. He has actually started ENT training in Melbourne. In addition, he runs an internet shop specialized in French lingerie together with his brother. The shop’s illustrated homepage and special sale event e-mails keep the department amused. We are not really worried about his future.

Giufeng has moved to Stockholm, of all places, where she is getting ready to move into neuroradiology at the Karolinska Institute. Her last postcard from the subpolar city of Hammerfest also bore the signature of a certain Ingmar, igniting fantasies in some members of the CT team. People remember her for her pleasant, easygoing personality.

Ajay is still looking around in the United States for a good residency program. He has also toured Canada and Europe and might consider the Charité in Berlin. But then again his wife has not decided yet.

Some knew it all along but chose to keep it to themselves. First a postcard from Joey arrives in the angio section. It is from Boston, where Joey has paused during a sightseeing trip through New England at the end of which he plans to visit his grandparents on Martha’s Vineyard. The French croissants at Harvard Square really are something, he writes. Is that special research slot in angiography is still open? Chief Waginaw promises to check.

A week later another postcard showing a stunning sunset at Niagara Falls reaches the bone section. Hello to everyone and she is feeling terrific, writes Hannah. Both pieces of information find their way to the department’s coffee counter, where little imagination is needed to get the whole picture: Those two who would have thought? Hannah has, of course, already gotten herself a job with the trauma surgeons. How she did it nobody knows, but the surgeons sure got themselves a great young colleague.

OK, what else? Well, let’s not forget about Greg, who also gets what he deserves: The chairman has asked him to apply for an assistant professorship. Life is tough on some, Gregory!



# Index

Note: page numbers in *italics* refer to figures and tables

## A

- abdomen
  - acute 177–181
    - diagnostic imaging modalities 169
  - biopsy 105, 106
  - CT 328, 330
  - free fluid 328
  - metastases 214, 215
  - pain and chest radiograph 176
  - plain radiograph
    - analysis 174–177
    - calcification 176
  - polytrauma 305, 308, 309, 328–329, 330, 331
  - ultrasonography 308, 309
- abdominal aorta calcifications 21
- abscess
  - brain 245
  - Brodie 127
  - epidural 141, 144, 261, 290, 293
  - intracerebral 293
  - large bowel 194
  - liver 202–203
  - middle ear infection 293
  - mycotic
    - cerebral 245
    - liver 202, 203
  - pancreatic 107, 108
  - perivertebral 141, 144
  - renal 222, 223
- absorption 6
  - ultrasonography 10
- accommodation 15
- acetabular angle 155, 156
- achalasia, esophageal 85, 86, 184, 185
- acoustic schwannoma 254
- acoustic shadow 10, 11
- acromioclavicular joint osteoarthritis 147, 148
- acute respiratory distress syndrome (ARDS) 71–72
- adenoma sebaceum 260
- adrenal glands
  - cysts 229
  - metastases 228, 229
  - radiographic work-up 220
  - tumors 228–229
    - adenoma 228
    - diagnosis 219
    - myelolipoma 228, 229
- adverse reactions, contrast media risks 30
- air bronchograms 49, 50, 66
  - positive 314
- air insufflation, fluoroscopy 191, 192
- air trapping 61, 62
- alcohol
  - abuse 212
  - brain atrophy 257–258
  - image-guided instillation 205
- allergens, hypersensitivity pneumonitis 69
- allergic reactions, contrast media risks 29–30
- alveolar disease 66
  - miscellaneous severe reaction 72
- Alzheimer, Alois 257
- amylase, serum level 212
- amyloid 162
- amyloidosis 162
- anal fistula 194, 196
- anatomical noise 17, 21
- anatomy, normal/variants 21
- Anderson fractures 317, 318
- angiofibroma, juvenile 290, 291
- angiography
  - aortic 82
  - arterial puncture and sheath insertion 99–100
  - arteriovenous malformation 249, 250
  - cerebral 236–237, 238
  - conventional 97
  - cranial aneurysms 236
  - CT 79, 80
  - digital subtraction 328
  - femoral artery 111, 112
  - glomus jugulare tumor 255
  - large bowel bleeds 197, 198
  - meningioma 254
  - modalities 98
  - risks 36–37
  - shunt placement 97
  - subtraction 297
  - vena cava filter placement 97
  - vertebral artery 302
- angioma
  - arteriovenous 249, 259, 260
  - venous 259, 260
- ankle joint
  - fracture 338
  - osteoarthritis 159
  - pain 158–159
- ankylosing spondylitis 144, 146
  - trauma risk 319
- anoxia, brain edema 258
- anterior spinal artery syndrome 261, 263
- aorta
  - aneurysms 85, 326
  - angiography 82
  - dissection 79, 81–82, 83, 326, 327
    - diagnosis 82
  - magnetic resonance angiography 97
  - pseudoaneurysm 326, 328
  - rupture 324
    - incomplete 326, 327
- aortic arch
  - contour 46
  - pseudoaneurysm 326, 328
- aortic valve stenosis 88, 89
- aortography 326, 328
- arachnoid cyst 248
- Arnold, Julius 260
- Arnold–Chiari malformations 258, 259
- arteria lusoria 188
- arterial occlusion 99–102
- arterial puncture and sheath insertion 99–100
- arteriography of mesenteric vessels 197
- arteriovascular disease 113
- arteriovenous angioma 249, 259, 260
- arteriovenous fistula 301, 302
- arteriovenous malformation 249, 250
  - bleeding 236
  - embolization 111, 112, 249, 250
  - invasive occlusion 249, 250
- arteriovenous shunt volume 301
- arthritis
  - gouty 160, 161
  - psoriatic 147, 150
  - see also osteoarthritis; rheumatoid arthritis
- arthropathy, inflammatory 120
- articular pain 146
- asbestosis 74, 75
- ascites 209, 213, 214–215
  - renal volume increase 226, 227
- Aspergillus* 58
- aspirin regimen 102
- astrocytoma 241–243, 261
  - anaplastic 242
  - pilocytic 241, 247
- atelectasis 48, 54, 61
  - compression 49
  - obstructive in children 55
  - polytrauma 310, 312, 316
  - postobstructive 47, 50
  - rounded 74
- atlas, fracture 318
- attention span 18
- attenuation, body components 9, 10
- avascular necrosis, femoral head 151–152, 335
- azygos lobe, pulmonary 21
- azygos vein 302

**B**

- B0 magnetic field 13
- back pain, diffuse 139
- Baker cyst 158
- balloon dilatation 100
- bamboo spine 144, 146, 319
- Bankart lesion 147, 148, 334
- barium contrast medium 10, 31
  - bowel preparation 193
  - contraindications 31
- barium examination
  - enteroclysis 189
  - heart contour 46
  - large bowel enema 192–194
- barium swallow, esophageal disease 183, 185
- Barrett esophagus 185, 186
- batwing edema 66, 314
- Bechterew, Wladimir von 146
- Bechterew disease 144, 146
  - trauma risk 319
- bile duct
  - carcinoma 203
  - congenital cavernous ectasia 211
- biliary system
  - cavernous ectasia 203, 211
  - cystic dilatation 203
  - diagnostic imaging modalities 171–172
  - extrahepatic 210–211
  - intrahepatic 200–209
    - segmental cavernous ectasia 203
  - obstruction 202
  - stones 203
- Binswanger, Otto 257
- Binswanger disease 256
- biopsy *see* tissue biopsy
- body components 18, 20
  - attenuation 9, 10
- bone 18
  - biopsy 105, 107
  - cancellous 120
  - cortical 120
  - cysts 124, 125
  - demineralization 139
  - density 120
  - diseases 121–139
    - congenital 135, 137
    - generalized 132–139
  - disuse atrophy 138, 139
  - focal lesions 121–132
  - heterotopic formation 163
  - image analysis 120–121
  - infarct 126
  - island 122
  - Lodwick classification of lesions 121, 126
  - metastases 128, 129, 130, 131, 134
  - scintigraphy 335
  - tumors 122–124
    - malignant 128
- Boston, been in (B.i.B.) 254
- botulinum toxin 183
- Bouchard type joint degeneration 150
- bowel
  - gas distribution 176
  - mucosal cobblestone appearance 190, 196
  - obstruction 177, 179, 180
    - mechanical 181
  - rupture 328
  - see also* intestine; large bowel/large bowel disease; small bowel/small bowel disease
- bowel wall
  - air 176, 177, 179
  - thickness 176
- brachiocephalic artery 302
- brachiocephalic trunk 314
- brain
  - abscess 245
  - angioma 259, 260
  - atrophy 234, 257–258
  - colloid cyst 248, 249
  - congenital disorders 258, 259, 260
  - contre-coup lesions 323, 324
  - contusion 323, 324, 324
  - coup lesions 324
  - degenerative disease 255–258
  - edema 257, 258
    - trauma 320, 321–322, 323, 324
  - focal lesions 234
  - gross morphology 233, 234
  - hemorrhage 235–237, 239
  - hypoxia 322, 323
  - infarction 257, 322
  - lymphoma 245, 246
  - metastases 234, 243, 244, 246
  - parenchyma 233
    - diffuse disease 234
    - subarachnoid hemorrhage 236
  - perfusion disturbance 235–240
  - small end-artery embolic occlusion 257
  - steamhammer effect 322, 323
  - subacute infarction 237, 239
  - tumors 240–243, 244, 245–254, 255
    - cerebellopontine 253–254, 255
    - perisellar 250–253
    - preoperative imaging 243
    - volume changes 234, 257–258
      - increase 257, 258
      - loss 234, 257–258
    - see also* cerebral infarction
- brain death 321
- brainstem herniation 234
- branchial cleft cysts 300, 301
- breaking bad news 131, 132
- breast
  - circumscribed soft tissue mass 271
  - cyst 273, 274, 277
  - fat implants 282
  - fat necrosis 276–277
  - fibroadenoma 272, 273
  - glandular parenchyma 270, 271
  - hematoma 274, 275, 279
  - implants 280–282
  - intramammary lymph nodes 275, 276
  - lump 272, 273, 274, 276
    - male 282–283
  - MRI 280–281
  - oil cyst 273, 274, 279
  - papilloma 279, 280
  - radiology 268–284
  - scar 274, 275
  - sclerosing adenosis 277, 278
  - skin alterations after surgery 279
  - stellate lesions 270–271
  - tumors/tumorlike lesions 272–280
    - see also* mammography
- breast carcinoma 268
  - abnormal mammogram post-treatment 278–279
  - brain metastases 243, 244
  - calcification 275, 276
  - carcinomatosis 64, 65
  - ductal carcinoma *in situ* 277, 278
  - foci at mastectomy 276
  - invasive 275
  - liver metastases 227, 280
  - lymphatic spread 64, 65
  - male 282, 283
  - recurrence 279
    - breast implant 281
- breast screening outcome 270
- breath, shortness 60–61, 62, 73
- Brodie abscess 127
- bronchial carcinoma 52, 53, 54, 55
  - adrenal metastases 228, 229
  - brain metastases 243, 244
  - hilum enlargement 91, 92
- bronchial cuffing 66
- bronchial wall 64, 66
- bronchoscopy 54, 59
- bronchus tears 315
- brown tumor 131, 132
- Bucky, Gustav 6
- union 160–161
- bursa calcification 147, 148
- butterfly edema 66, 314

**C**

- calcifications 15, 18
  - abdominal aorta 21
  - abdominal radiograph 175–176, 176
  - bursa 147, 148
  - cardiac 45
  - craniopharyngioma 251
  - dog's paw 277, 278
  - eggshell 73, 74, 91
  - enchondroma 123
  - ependymoma 247
  - heart valve 89
  - mammograms 31–32, 271, 272
    - breast carcinoma 275, 276
    - breast circumscribed soft tissue mass 271
    - breast cysts 273, 274
    - fat necrosis 276–277
    - plasma cell mastitis 277
    - sclerosing adenosis 277, 278
    - vascular 276, 277
  - medulloblastoma 247
  - meningioma 298
  - oligodendroglioma 241, 242
  - pancreatic adenoma 213

- pancreatitis 175, 212, 213  
 pericardial 88, 89  
 pineal gland 234, 322  
 polycystic kidney disease 222  
 renal mass 221  
 Sturge–Weber syndrome 260  
 synovial chondromatosis 153  
 teratoma 215  
 tuberous sclerosis 260
- Calvé, Jaques 155
- Camurati–Engelmann disease 135, 137, 298
- Candida albicans* 58
- candidiasis, hepatosplenic 202
- carcinomatosis  
 lymphangitic 64, 65, 74  
 peritoneal 214, 215
- cardiomyopathy 86, 87
- Caroli syndrome 203, 211
- carotid artery, embolization of external 301
- carotid bulb paraganglioma 301
- carotidocavernous fistula 297–298
- carpal luxation, perilunate 333
- caval filters, risks 37
- celiac disease 192
- celiac plexus  
 block 113  
 denervation 98
- central nervous system (CNS) 230, 233  
 diagnostic modalities 230–233
- central venous lines 310, 312, 313
- cerebellar hemisphere  
 hemangioblastoma 243  
 infarction 25
- cerebellopontine tumors 253–254, 255
- cerebral angiography 236–237, 238
- cerebral artery, medial 238  
 aneurysm 253  
 trauma 322
- cerebral edema 257, 258  
 trauma 320, 321–322, 323, 324
- cerebral hemorrhage, thrombolysis-induced 237, 239
- cerebral infarction 237, 238, 239–240  
 acute ischemic 237, 238–239  
 chronic ischemic 237, 239, 240  
 subacute 237, 239
- cerebrospinal fluid (CSF) space 233, 234
- cervical cysts 300, 301, 301
- cervical paraganglioma 301
- cervical spine  
 C2 injuries 317–319  
 C3 injuries 317–319  
 C6 dislocation 19  
 degenerative change 263  
 injuries caudal to C3 319, 320  
 ligamentous injuries 319  
 osteochondrosis 188  
 polytrauma 316–319, 320  
 radiographs 316–319, 320  
 trauma 305–306
- cesium iodide crystals 7–8
- Charcot joint 161
- chemoembolization 205
- chemotherapy, vascular access 110–111
- chest  
 anatomy 40  
 CT 326  
 diagnostic imaging modalities 41–42  
 funnel 90, 91  
 polytrauma 308–328  
 soft tissues 45  
 trauma 305–306
- chest drains 315, 316
- chest radiographs 308–316, 324, 325  
 abdominal pain 176  
 analysis 40, 43–46  
 image quality 40, 43  
 lateral 46
- chest wall hematoma 61
- Chiari, Hans 260
- Chilaiditi syndrome 174, 175
- cholangiocarcinoma 210, 211
- cholangiocellular carcinoma 205, 207
- cholangitis  
 ascending 202  
 recurrent 203
- cholecystitis, acute 210
- cholecystolithiasis 210
- cholestasis 210
- chondromatosis, synovial 153
- chondrosarcoma 123, 124
- circle of Willis, giant aneurysm 252, 253
- clivus, chordoma 251–252
- Codman triangle 126
- coffee-bean sign 180
- colitis  
 radiation 197  
 ulcerative 196, 197
- collateral ligament, sprain/tear 157
- colloid cyst 248, 249
- colon  
 Crohn disease 196  
 parasitosis 197, 198
- colorectal carcinoma 177
- Comberg radiographs 295, 296
- computed tomography (CT) 9–10, 20  
 abdominal 328, 330  
 angiography 79, 80  
 chest 326  
 contrast media 10  
 studies 29–31  
 cranial 320, 321–322, 323–324  
 head injury 28  
 high-resolution in chronic lung disease 72  
 interactive review of thin images 21  
 risks 32–35  
 spiral 97  
 spiral volume scans 9–10  
 three-phase renal scan 221  
 venography 79, 80  
 working principle 9–10
- consent 27
- contrast media  
 contraindications 30–31  
 CT 10  
 Doppler ultrasound 10  
 examination 8
- extravascular use 31
- gastrointestinal tract 8, 31
- head sectional study 233
- iodinated 10, 29–31
- MR tomography 15, 31
- risks of studies 29–31
- ultrasonography 31  
 see also barium
- conventional tomography 8
- cor pulmonale 89
- core needle biopsy  
 breast 275–276  
 lung 54, 55
- coronary artery disease 86, 87
- corpus callosum  
 agenesis 259, 260  
 anomalies 260
- cortical blindness 239
- cortical gyri thickening 259, 260
- corticosteroids  
 bone density decrease 120  
 infiltration 113
- craniopharyngioma 251, 252
- cranium/cranial vault  
 aneurysms 236  
 CT 320, 321–322, 323–324  
 perforation by middle ear infection 293  
 sinus infection 289, 290  
 venous hemorrhage 236  
 see also skull
- cricopharyngeal muscle 183
- Crohn disease 190, 191, 192, 194, 196
- cruciate ligament sprain/tear 157
- current induction 36
- cystic fibrosis 76, 78
- cytomegalovirus (CMV) pneumonia 67

## D

- DaNang lung 71, 72
- dancing needle 99, 100
- Dandy, Walter E 260
- Dandy–Walker complex 258, 259
- decision-making capacity 27
- deep sulcus sign 310, 311
- deep vein thrombosis 102–103, 109–110
- defecation problems 198–199
- defecography 198–199
- dementia 255–258  
 of Alzheimer type 256
- dens fracture 317, 318, 318
- dense media sign 238
- dermoid, nasal 287
- developmental deficit 258
- diabetes mellitus, neuropathic  
 arthropathy 161
- diagnosis 15, 16–17, 17
- double reading 17, 32
- histological 26
- patient history 26
- survival by a day 146
- diagnostic images 15
- diagnostic radiologists 15
- diaphragm  
 contour 43, 44  
 space under 45



rupture 315  
 differential diagnosis 26  
 digital detectors 6–8  
 digital projection radiography unit 7  
 disuse atrophy 138, 139  
 diverticulitis 179, 194, 195  
 diverticulosis 194  
 diverticulum  
 fistula 194, 195  
 pseudotumors 194  
 stenosis 194  
 dizziness 253  
 dog's paw calcifications 277, 278  
 Doppler ultrasound  
 color-coded 10  
 deep vein thrombosis 103  
 double reading 17, 32  
 double-barrel sign 185  
 double-doughnut sign 191  
 drain insertion 107, 108  
 drainage procedures, risks 37  
 drug abuse 257–258  
 dual energy X-ray absorptiometry (DXA),  
 134 133  
 ductal carcinoma *in situ* 277, 278  
 duodenal diverticulum 189, 190  
 Dupuytren disease 164  
 Dutch flag sign 20  
 dysphagia aortica 188  
 dysphagia lusoria 188  
 dyspnea 60–61, 62, 73

## E

ear disease 292–293  
 hearing loss 254  
 ear protection 36  
*Echinococcus granulosus* 201, 202  
 elbow joint fracture 334  
 embolism  
 fat 337  
 septic in lung 58, 59  
 embolization 111, 112  
 angiography 97  
 arteriovenous fistula 301, 302  
 arteriovenous malformation 111, 112,  
 249, 250  
 chemoembolization 205  
 external carotid artery 301  
 glomus jugulare tumor 255  
 risks 37  
 emphysema, pulmonary 60, 92  
 empty delta sign 240  
 empty sella 252, 253  
 encephalocele, nasofrontal 287  
 encephalopathy  
 hepatic 109  
 HIV 257–258  
 subcortical arteriosclerotic 256  
 enchondroma 122–123  
 multiple 162  
 enchondromatosis 123  
 endobronchial obstruction 47, 50  
 endocrine ophthalmopathy 296, 299  
 endoscopic retrograde cholangio-  
 pancreatography (ERCP) 203

endoscopy  
 capsule 168  
 fiberoptic 168  
 lower urinary tract 219  
 endotracheal tube 309, 310  
 incorrect position 315, 316  
 energy dose 32  
 enostosis 122  
*Entamoeba histolytica* 202  
 enterocele 199  
 enteroclysis 188, 189  
 ependymoma 247, 248, 261  
 epidermoids, perisellar 252  
 epidural abscess 141, 144, 261, 290  
 middle ear infection 293  
 epidural hematoma 322, 323, 324  
 epiphysiolysis 155  
 equivalence dose 32  
 esophagitis 187  
 reflux 185, 186  
 esophagus/esophageal disease 182–188  
 achalasia 85, 86, 184, 185  
 adenocarcinoma 185, 186  
 carcinoma 185, 188  
 compression 188  
 corkscrew configuration 185  
 diagnostic imaging modalities  
 169–170  
 diffuse spasm 185  
 diverticula 183–184  
 foreign bodies 187  
 hemorrhage 108–109  
 intubation 309, 310  
 peristalsis disturbances 184, 185  
 squamous cell carcinoma 185, 186  
 tumors 185, 186, 188  
 varices 108–109, 185, 187  
 Ewing sarcoma 127, 128  
 exophthalmos 296–299  
 carotidocavernous fistula 297–298  
 osteopetrosis 298  
 tumors 298  
 exposure geometry 23  
 exposure techniques 8  
 extracorporeal shock wave lithotripsy  
 (ESWL) 224  
 eye  
 diagnostic modalities 286  
 see also orbit; vision

## F

face  
 diagnostic modalities 285–286  
 imaging 285–303  
 facet joints, osteoarthritis 264, 265  
 fallen-fragment sign 124, 125  
 false-negative findings 31  
 false-positive findings 31–32  
 fat 18  
 embolisms 337  
 necrosis of breast 276–277  
 Felson, Benjamin 91  
 femoral artery angiography 111, 112  
 femoral epiphysis, slipped capital 155  
 femoral head

avascular necrosis 151–152, 335  
 idiopathic necrosis 154–155  
 necrosis 155  
 recurrent dislocation 155, 156  
 femoral neck fractures 120, 335  
 femur  
 comminuted fracture 336  
 pathological fracture 111, 112  
 ferrite compounds 31  
 ferromagnetic materials 36  
 fibroma, nonossifying 124, 126  
 fibromatosis, palmar/plantar 164  
 fibrosarcoma 163  
 fibrous dysplasia 124, 125  
 fibula fracture 19, 338  
 fibulotibial syndesmosis 338  
 film–screen combinations 7  
 fine needle aspiration, breast cyst 274  
 finger joints, osteoarthritis 150  
 fish vertebra 133  
 fistula  
 anal 194, 196  
 diverticular 194, 195  
 fluid–fluid/fluid–gas interfaces 26  
 fluoroscopy 8  
 air insufflation 191, 192  
 swallowing problems 183  
 thoracic abnormalities 46  
 foot neuropathy 161  
 footdrop 263  
 forearm, greenstick fractures 336  
 foreign bodies  
 esophageal 187  
 orbital 295, 296  
 Forrester disease 319  
 Forssmann, Werner 98  
 fox hole 191  
 fractures  
 Anderson 317, 318  
 ankle joint 338  
 atlas 318  
 dens 317, 318, 318  
 elbow joint 334  
 femoral neck 120, 335  
 femur 111, 112  
 comminuted 336  
 fibula 19, 338  
 forearm 336  
 Galeazzi 333  
 greenstick 336  
 hangman's 317, 318  
 humerus 23  
 Jefferson 317, 318  
 knee 20  
 Maisonneuve 338  
 metacarpal bones 337  
 Monteggia 333  
 parry 332  
 pathological 111, 112  
 pelvis 331  
 radius 333  
 extension (Colles type) 332  
 ribs 312, 313, 315, 327, 328  
 sacrum 330, 331  
 scaphoid 333

- skull 321, 323, 324  
 Smith-type flexion of hand 332  
 stress 126  
 tibial head 20, 337  
 transverse spinous processes 329  
 trauma 331–338  
 vertebral body 120  
 vertebral end plate 133  
 wedge of ulna 332
- G**
- gadolinium chelate 31  
 gadolinium contrast medium 10  
 galactography 279–280  
 Galeazzi fracture 333  
 gallbladder  
   adenocarcinoma 210  
   carcinoma 210, 211, 211  
 gallstones 210  
   bowel obstruction 177, 180  
   impaction 210  
   migration 210  
   pancreatic duct blockage 212  
 ganglion cyst, intraosseous 151, 152  
 Gardner syndrome 122  
 gastric bubble 43  
 gastrinoma 214  
 gastrointestinal tract  
   contrast media 8, 31  
   diagnostic imaging modalities 169–173  
   radiological imaging 168  
   *see also named regions*  
 genitourinary tract 219–230  
 "gestalt" 25  
 giant cell tumor 124  
 glioblastoma  
   malignant 234, 246  
   multiforme 242–243  
 glioma 241–243  
   high-grade 234  
   nasal 287, 288  
   pontine 247  
 glomerulonephritis 225  
 glomus jugulare tumor 254, 255  
 glomus tumor 300–301  
 glucagon 193  
 glue, tissue 98, 111, 112, 133  
 goiter 84  
 gonadal protection, radiation dose 33  
 Goodpasture syndrome 69  
 gout 160, 161  
 gradient switching, noise generation 36  
 Graves disease 296–297  
 Gregory's test 114  
 Grüntzig, Andreas 100–101  
 gummy bears 24  
 gynecomastia 282
- H**
- hallux base joint osteoarthritis 160  
 hallux valgus 160–161  
 hand  
   osteoarthritis 150  
   Smith-type flexion fractures 332  
   hangman's fracture 317, 318  
   haustral folds 176  
 head  
   injury 27–28  
   sectional study analysis 233–234  
   shaking in the negative 19  
   trauma 306–307, 320, 321–322, 323–324  
 headache  
   chronic 240  
   chronic subdural hematoma 323  
   cluster 235  
   pediatric 247  
   severe 235  
     colloid cyst 248, 249  
 hearing loss 254  
 heart/heart disease  
   cardiomyopathy 86, 87  
   contours 45, 46  
   contrast media risks 29  
   failure 301  
   injury 326, 327  
   left  
     chronic insufficiency 73  
     enlargement 88, 89  
     right heart enlargement 89, 92  
     shadow 45  
 Heberden nodes 150  
 hemangioblastoma 243  
 hematological disease, contrast media risks 29  
 hematuria 328, 329  
 hemianopia, bitemporal 252–253  
 hemidiaphragm 43, 44, 46  
   rupture 315  
 hemiparesis 237  
 hemochromatosis 209  
 hemothorax 61, 62, 312  
 hepatic artery 202  
 hepatic duct, bifurcation of common 210, 211  
 hepatic encephalopathy 109  
   *see also liver/liver disease*  
 hepatic steatosis 208–209  
 hepatocellular carcinoma 205, 207, 209  
 hiatal hernia 90  
 hila 45, 46  
   enlargement 91, 92  
 Hill–Sachs defect 147, 148, 334  
 hip joint 151, 152  
   dysplasia 155, 156  
   osteoarthritis 151, 152  
 histiocytoma, malignant fibrous 163  
 histoplasmosis 74  
 HIV encephalopathy 257–258  
 HIV infection  
   brain abscess 245  
   *Pneumocystis carinii* pneumonia 69, 70  
 Hoffmann, Felix 102  
 Hounsfield units 10  
 humerus, fracture 23  
 hydatid cyst of liver 201, 202  
 hydrocephalus  
   colloid cyst 248  
   Dandy–Walker complex 258, 259  
   intracranial hemorrhage 236  
   normal-pressure 235, 236, 256, 257  
   obstructive 323, 324  
 hydronephrosis 221, 227  
 hyperparathyroidism 132  
   osteomalacia 135, 136  
 hypopharynx, squamous cell carcinoma 185, 186
- I**
- ileitis, terminal 190  
 ileus 176  
   adynamic 177  
   diagnosis 181  
   mechanical 177, 179, 180, 181  
   dynamic 181  
   paralytic 179, 181, 214, 215  
 iliopsoas muscle  
   contours 175  
   contrast resolution 22–23  
 image analysis 18, 19, 20–23, 24, 25–26  
 unsharpness 23  
 image intensifier systems 8  
 image processing 8–9  
 imaging modality 15, 17  
 immunosuppression  
   brain abscess 245  
   lung septic emboli 58  
   mycotic liver abscess 203  
 implants, metallic 36  
 incidentaloma 228  
 incontinence, fecal 198–199  
 inflammatory bowel disease *see Crohn disease; ulcerative colitis*  
 informed consent 27  
   angiography 98  
 insulinoma 214  
 intensifying screens 6–7  
 interventions, risks 36–37  
 intervertebral disk  
   degeneration 141, 142  
   herniation 21, 146, 263  
   prolapse 141, 142, 263–264  
   massive 261  
   whiplash injuries 319  
 sequesters 264  
 intestine  
   air distribution 176  
   infarction 176  
   sentinel loops 174, 175, 176–177, 181  
   *see also bowel; large bowel/large bowel disease; small bowel/small bowel disease*  
 intracerebral abscess 293  
 intracranial hematoma 323, 324  
 intracranial hemorrhage 27–28, 236  
 intracranial injury 306–307  
 intracranial pressure, raised 321, 323  
 intraperitoneal air, free 176, 177, 178, 181  
 intravenous pyelography 219  
 intravenous urography 219  
 intussusception 197, 192  
 iodine contrast medium 10, 29–31  
 islet cell tumor 214

**J**

jaundice, obstructive 210  
 Jefferson, Geoffrey 339  
 Jefferson fracture 317, 318  
 jejunal diverticulum 190  
 joints 120  
   disease 146–161  
   effusions 120  
   inflammation 120  
   lower extremity 151–161  
   upper extremity 147–150  
 jugular venous line 310, 313

**K**

Kerckring folds 176  
 Kerley, Peter James 67  
 Kerley lines 64, 67  
 kidney/kidney disease  
   abscess 222, 223  
   contours 175  
   contrast media risks 29  
   contrast resolution 22–23  
   cysts 201, 202, 222  
   horseshoe 222, 223  
   polycystic disease 202, 222  
   radiographic work-up of disorders 219–220  
   rupture 329  
   size 220  
   three-phase CT scan 221  
   tumors 222–225  
     adenoma 224  
     angiomyolipoma 222, 223  
     carcinoid 222  
     diagnosis 219  
     hypervascular 221  
     lymphoma 222, 223, 227  
     pelvic 224  
     renal cell carcinoma 223, 224, 225  
     transitional cell carcinoma 222  
     urinoma 224  
   volume  
     increase 226–227  
     loss 225–226  
   *see also renal entries*  
 Klatskin tumor 210, 211  
 knee joint  
   fracture 20  
   osteoarthritis 157  
   synovial hemangioma 164

**L**

large bowel/large bowel disease  
   abscess 194  
   barium enema 192–194  
   bleed 197, 198  
   carcinoma 194, 195  
   diagnostic imaging modalities 170–171  
   diseases 192–198  
   haustral folds 176  
   obstruction 177, 194, 195  
   polyps 194, 195  
   stenosis 197  
 Larmor, Joseph 13

Larmor frequency 12, 13, 14  
 laser-induced thermotherapy (LITT) 205  
 lead-point 191, 192  
 Ledderhose disease 164  
 Legg, Arthur Thornton 155  
 Legg–Calvé–Perthes disease 154–155, 156  
 leukemia  
   acute myelogenous 202  
   acute myeloid 245  
 lidocaine infiltration 113  
 ligamentum arteriosum 324  
 ligamentum flavum hypertrophy 264, 265  
 light box 15, 16–17  
 lipase, serum level 212  
 lipoma 162–163, 164  
 liposarcoma 162–163  
 liver/liver disease 200–209  
   abdominal radiography 174, 174–175  
   abscess 202–203  
   adenoma 203, 204, 205–206  
   amebic abscess 202  
   bacterial abscess 202–203  
   cirrhosis 185, 209  
   congenital cysts 200, 201, 202  
   Couinaud classification of lobes 200  
   cysts 206  
   diagnostic imaging modalities 171–172  
   diffuse 208–209  
   fatty 208–209  
   fibrolamellar carcinoma 205  
   focal lesions 200–207, 209  
   focal nodular hyperplasia 204, 205, 205–206  
   hemangioma 203, 204, 206  
   hydatid cyst 201, 202  
   metastases 202, 204–205, 206, 209, 211  
     breast cancer 227, 280  
     pancreatic carcinoma 213, 214  
   mycotic abscess 202, 203  
   polycystic 201, 202  
   pyogenic abscess 202–203  
   trauma 327, 329  
   tumors  
     benign 203–204, 205  
     malignant 204–206, 207  
   *see also hepatic entries*  
 Lodwick, Gwilym 121  
 loose bodies 120  
 Looser zones 135  
 lower extremity joints 151–161  
 lower limb trauma 308  
 lumbar spine 263  
   trauma 307, 330, 331  
 lumbar sympathetic nerve block 113  
 lunate luxation 333  
 lung/lung disease 127  
   acute changes 63–64, 65, 66–67, 68  
   acute diffuse pattern  
     alveolar 69, 70, 71–72  
     interstitial 63–64, 65, 66–67, 68  
   air–soft tissue interface obliteration 52, 54  
 apex 310  
 biopsy 104, 105  
 chronic 72–74, 75, 76–77, 78  
 contusion 49, 312, 313  
 core needle biopsy 54, 55  
 edema 49, 51  
   cardiogenic interstitial 67, 68, 69  
   polytrauma 312, 314  
   toxic 72  
 fibrosis 74, 76, 77  
 fluid exudation into interstitium 64  
 hemorrhage 69, 70  
 interlobar fissures 64, 65  
 interlobular septae 64  
 laceration 312, 313  
 lesions  
   border 52, 53  
   contour 52, 53  
   with homogeneous internal structure 47, 48, 49, 50  
   with inhomogenous internal structure 49–50, 51, 52  
   volume effect 54  
 lipoma 52, 53  
 lymphangitic carcinomatosis 64, 65, 74  
 metastases 53, 56, 57  
   osteosarcoma 127  
 multiple lesions 56, 57, 58–59, 60  
 necrotic lesions 50, 51  
 occupational exposures 73–74, 77  
 opacities 47–63  
   diffuse homogenous 60–61, 62, 63  
   osteosarcoma 56, 57  
   parenchyma 44–45  
     abnormalities 46  
   scarring 47  
   septic emboli 58, 59  
 shock 71–72  
 space-occupying lesions 50, 51, 52  
 trauma 61, 62  
 tumors 53, 54, 82  
   brain metastases from carcinoma 243, 244  
   malignant 50, 52  
 vascular tree 21  
 vessel walls 66  
 volume loss 54, 310, 315  
 Wegener disease lesions 59  
*see also atelectasis; bronchial carcinoma; pulmonary entries*  
 lymph nodes  
   head and neck cancer 300  
   intramammary 275, 276  
   metastases 223  
 lymphadenopathy 300  
 lymphangioliomyomatosis 76  
 lymphoma 84, 91  
   exophthalmos 298  
   extradural spinal 261  
   intracranial 245, 246  
   neck lymph node enlargement 300  
   renal 222, 223, 227  
   retroperitoneal 215, 216



**M**

McCune–Albright syndrome 124, 125  
 Mafucci syndrome 123, 162  
 magnetic fields 12  
   B0 13, 14  
   external 13, 14  
   inhomogeneities 15  
   internal 13, 14  
 magnetic resonance angiography (MRA) 97  
 magnetic resonance cholangiopancreatography (MRCP) 203  
 magnetic resonance signal  
   analysis 14–15  
   generation 10–11, 12, 13–14  
   spatial allocation 14  
 magnetic resonance (MR) tomography  
   10–11, 12, 13–15, 20  
   breast  
     contrast-enhanced 276  
     implants 280–281  
   children 250  
   contrast media 15, 31  
   emergency 261, 263  
   pregnancy 36  
   risks 35–36  
   sinus malignant tumor 290, 292  
   uncooperative patients 250  
 Maisonneuve fracture 338  
 mammography 15, 268  
   abnormal post-carcinoma treatment 278–279  
   analysis 270–272  
   asymptomatic patients 268–269  
   breast cyst 273, 274  
   calcifications 271, 272  
   fat necrosis 276–277  
   malignant 277–278  
   plasma cell mastitis 277  
   sclerosing adenosis 277, 278  
   vascular 276, 277  
   digital 16–17  
   double reading 32  
   false-positive findings 31–32  
   fibroadenoma 272, 273  
   image quality 270  
   recurrent carcinoma 279  
   symptomatic patients 269–270  
 mandibular angle pain 302, 303  
 mandibular condyle 293, 294, 295  
 marble bone disease 135, 137, 298  
 Marfan syndrome 79  
 mastectomy, cancer foci 276  
 mastitis, plasma cell 277  
 mastoid, pneumatized 294  
 mastoid air cells 292, 293  
 mastoiditis 293  
 maxillary sinus cyst 293  
 Meckel diverticulum 190  
 mediastinum  
   abnormalities 46  
   biopsy 104, 106  
   compression 44  
   displaced 310, 315, 316  
   inferior 45

lesions 83–91  
 lipomatosis 326, 327  
 lower 86, 87  
   superior 45  
 tumor 82  
 widening 312, 314, 315, 324, 325, 326  
   upper 83–86  
   see also pneumomediastinum  
 medulloblastoma 247, 248  
 megacolon, toxic 177  
 meninges, changes 234  
 meningioma 234, 241, 242, 263  
   cerebellopontine angle 254  
   exophthalmos 298  
   spinal 261, 262  
 meningitis  
   epidural abscess 290  
   normal-pressure hydrocephalus 257  
 meningocele 258, 259, 287  
 meniscal tear 158  
 menisci, kissing 158  
 mesenteric vessels, arteriography 197  
 metabolic disease, contrast media risks 29  
 metacarpal bone fracture 331  
 metal components 15  
 metallic implants 36  
 metallic objects, movement 36  
 metastases  
   abdominal 214, 215  
   adrenal 228, 229  
   bone 128, 129, 130, 131, 134  
     destruction 111, 112  
   brain 234, 243, 244, 246  
   exophthalmos 298  
   extradural spinal 261, 262  
   intramedullary spinal 261, 262  
   liver 202, 209, 211  
     breast cancer 227, 280  
     pancreatic carcinoma 213, 214  
   lung 53, 56, 57  
     osteosarcoma 127  
   lymph nodes 223  
   multiple myeloma 133, 134  
   osteoblastic 131, 134  
   retroperitoneal 216  
   skull base 251, 252  
 methylmethacrylate, percutaneous injection 133  
 microcalcifications 15, 31–32  
 middle ear infection 292–293  
 migraine 235  
 Mirizzi syndrome 210  
 mitral valve 44, 46  
 Monteggia fracture 333  
 Morrison's pouch 308, 309, 327, 328  
 mouse 159  
 multiple myeloma 130, 261, 262  
   metastases 133, 134  
 multiple sclerosis 246  
 musculoskeletal imaging 115–119  
 mycotic abscess  
   cerebral 245  
   liver 202, 203  
 myelomeningocele 258

myocardial infarction 79  
 left ventricular aneurysm 89  
 myositis ossificans 163

**N**

nasofrontal encephalocele 287  
 neck  
   diagnostic modalities 285  
   diseases 299–301, 302  
   imaging 285–303  
   malignant tumor 299–300  
   swelling 299–301, 302  
 needle biopsy  
   stereotactic 278  
   see also core needle biopsy  
 nerve compression syndromes 140  
 neural blockades 113  
 neural foramina 329, 330  
   sacral 331  
 neurofibroma, plexiform 299  
 neurofibromatosis 59, 60  
   type 1 162, 163  
   type 2 254  
 neurofibrosarcoma, malignant 162  
 neuroforaminal stenosis, degenerative 264, 265  
 neuropathic arthropathy 161  
 neuropathy, foot 161  
 nipples 59  
   secretions 279–280  
 noise, gradient switching 36  
 nonstochastic effect 32  
 nose/nasal diseases 286–290, 291–292  
   dermoid 287  
   glioma 287, 288  
   nasofrontal encephalocele 287  
   tumor 286, 287, 288  
**O**  
 observation time 18  
 occipitocervical junction injuries 317–319  
 oligodendroglioma 241, 242  
 Ollier disease 123  
 omental caking 214, 215  
 oncological disease, contrast media risks 29  
 oneupmanship see Boston, been in (B.i.B.)  
 ophthalmopathy, endocrine 296, 299  
 optic nerve osteopetrosis 298  
 optical density 15  
 oral contraceptives 203, 205, 206  
 orbit  
   diseases 294–299  
   foreign body 295, 296  
   injuries 294–299  
   sinus infection 289  
 orbitopathy, endocrine 296  
 organ donation 321  
 Ormond disease 216  
 orthopantomography 302, 303  
 osseous protruberances 151  
 osteoarthritis 120  
   acromioclavicular joint 147, 148

- ankle joint 159  
 facet joints 264, 265  
 finger joints 150  
 hallux base joint 160  
 hand 150  
 hip 151, 152  
 intervertebral joint 140, 141  
 knee joint 157  
 shoulder joint 147, 148  
 synovial chondromatosis 153  
 uncovertebral joints 264, 265  
 osteoarthropathy, hypertrophic 135, 138  
 osteochondritis dissecans 159  
 osteochondroma 123, 124  
 osteochondromatosis, synovial 153  
 osteochondrosis 139–140  
 cervical spine 188  
 osteoclastoma 131, 132  
 osteogenesis imperfecta 137  
 osteoma 122  
 frontal sinus 290, 291  
 osteoid 122, 123  
 osteomalacia 135  
 hyperparathyroidism 135, 136  
 osteomyelitis 127, 128  
 osteopetrosis 135, 137  
 exophthalmos 298  
 osteophytes 151, 153  
 osteopoikilosis 130  
 osteoporosis 133, 335  
 transient 153  
 osteosarcoma 126, 127  
 lung 56, 57  
 pulmonary metastases 127  
 transformation from Paget disease 131  
 osteosclerosis, congenital 135, 137  
 osteosynthetic material 36  
 overexposure 7
- P**
- pachygyria 259, 260  
 Paget, Sir James 131  
 Paget disease 130–131, 156  
 pancreas/pancreatic disease 211–214  
 abdominal radiograph 175  
 abscess drainage 107, 108  
 adenoma 213–214  
 biopsy 214  
 carcinoma 211, 213, 214  
 metastases 215  
 diagnostic imaging modalities 172–173  
 islet cell tumor 214  
 necrosis 213  
 pseudocysts 213, 214  
 tumors 213–214  
 pancreatic duct blockage 212  
 pancreatic head carcinoma 211  
 pancreatitis  
 acute 175, 179, 212–213, 214  
 calcification 175  
 chronic 212, 213  
 paraganglioma 300–301  
 paramagnetic materials 36  
 paranasal sinuses 286–290, 291–292  
 Caldwell view 288  
 Waters view 288, 290  
 paraplegia, acute 261, 263  
 parasitosis of colon 197, 198  
 parotid tumors 300  
 pathological findings, typical 26  
 patients  
 history 26  
 informed consent 27, 98  
 preparation 28  
 protection from radiation dose 33  
 refusal 27  
 pectus excavatum 90, 91  
 pelvis  
 fractures 331  
 trauma 307, 330, 331  
 perception 15, 16, 17, 25–26  
 “gestalt” 25  
 gummy bears 24  
 pericardial effusion 86  
 pericardial hemorrhage 326, 327  
 pericardial tamponade 326, 327  
 pericarditis, constrictive 88, 89  
 perirenal hematoma 223, 224  
 perisinusoidal bone sclerosis 289, 290  
 peristalsis disturbances 184, 185  
 peritoneal disease 214–216  
 carcinomatosis 214, 215  
 perivertebral abscess 141, 144  
 Perthes, Georg Clemens 155  
 phase shift 14  
 phlebography 97  
 photographic film 6  
 physician protection from radiation dose 34, 35  
 Pick, Arnold 257  
 Pick disease 256  
 Pierre–Marie–Bamberger disease 135, 138  
 piezoelectric crystals 10, 11  
 pineal gland calcification 234, 322  
 pituitary 251  
 pituitary tumors, adenoma 250–251  
 plasma cell mastitis 277  
 plasmacytoma 262  
 pleura  
 asbestosis 74  
 border 44  
 effusions 47, 49, 52, 61, 74  
 plaques 74  
 pleural recess, deep 310, 311  
 pneumatosis intestinalis 176  
 pneumoconiosis 73, 74  
*Pneumocystis carinii* pneumonia (PCP) 69, 70  
 pneumomediastinum 314, 315  
 pneumonia 82  
 viral 67  
 pneumonitis  
 hypersensitivity 69  
 interstitial 74, 76, 77  
 pneumothorax  
 apical 310, 311  
 lung biopsy 104, 105  
 rib fractures 312, 313  
 tension 310, 311, 312, 315  
 wrong diagnosis 310, 312  
 polymethylmethacrylate (PMMA), transpedicular injection 98  
 polyps, small bowel 191, 192  
 polytrauma 304, 308–331  
 abdomen 308, 309, 328–329, 330, 331  
 cardiac injury 326, 327  
 chest 308–328  
 port implantation 110–111  
 port needle 111  
 port wine stain 260  
 portal circulation 202  
 portal hypertension 185, 187  
 liver cirrhosis 209  
 portal vein occlusion 185  
 positive end-expiratory pressure (PEEP) simulation 67  
 pregnancy, MR tomography 36  
 projection radiography 6–9, 8  
 contrast resolution 22  
 projections 21–22, 23  
 risks 32–35  
 prostate, radiographic work-up 220  
 protons 11, 13  
 pseudarthrosis  
 femoral neck fracture 335  
 scaphoid fractures 333  
 pseudocysts, pancreatic 213, 214  
 pseudolesion simulation 25  
 pseudospondylolisthesis 140, 141, 144, 266  
 psoriatic arthritis 147, 150  
 psychiatric patients, esophageal foreign bodies 187  
 pubic symphysis 331  
 pulmonary embolism 78–79, 80, 97, 109–110  
 see also lung/lung disease  
 pulmonary fibrosis, idiopathic 74, 76, 77  
 pulmonary hypertension 92  
 pulmonary nodules, ossifying 56, 57  
 pulmonary pressure, central 310, 312  
 pulmonary tear 312, 313  
 pulmonary venous redistribution 63–64  
 pulsion diverticula 183–184  
 pyelography, intravenous 219  
 pyelonephritis 226, 227
- R**
- radiation attenuation 21  
 radiation colitis 197  
 radiation dose 27, 32–33, 34  
 effective total body 34  
 effects 32  
 personal 32–33  
 physician protection 34, 35  
 radiofrequency ablation 205  
 radiofrequency pulse 12, 13–14  
 B1 14  
 radiography  
 contrast media studies 29–31  
 findings 26

- plain of abdomen 174  
analysis 174–177  
tissue characteristics of images 18, 20–21  
see also projection radiography  
radius fracture 333  
extension (Colles type) 332  
rectal invagination/prolapse 199  
rectocele, anterior 199  
reflection, sound 10  
refusal by patient 27  
relaxation  
longitudinal 14, 15  
transversal 14  
renal arteries  
arteriosclerosis 225  
stenosis 226  
see also kidney/kidney disease  
renal atrophy 225–226  
renal calculi 227–228  
ESWL 224  
imaging 219  
renal calices, dilatation 221  
renal colic 227  
renal cysts 221, 222  
renal hypertrophy, compensatory 226  
renal infarction 225, 226  
renal mass 220–225  
renal obstruction, chronic 225  
renal parenchyma 221  
renal pelvis  
dilatation 221  
tumors 224  
renal ultrasonography 219  
assessment 220–221  
renal vein  
circumaortic 21  
thrombosis 227  
respiration, mechanical 72  
resuscitation, contrast media adverse reaction 30  
retroperitoneum/retroperitoneal disease 214–216  
air 176, 177, 178  
cancer spread 181  
fibrosis 216  
hemorrhage 328, 329  
lymph node enlargement 215, 216  
lymphoma 215, 216  
metastases 216  
retrosternal space 46  
rheumatoid arthritis 147, 149  
toe joint 160  
ribs 45  
fractures 312, 313, 315, 327, 328  
radiography 326, 327  
risks 27  
contrast media studies 29–31  
CT 32–35  
interventions 36–37  
MR tomography 35–36  
projection radiography 32–35  
radiological procedures 32–36  
ultrasonography 35  
Roentgen, Wilhelm Conrad 7, 32  
rotator cuff rupture 147, 148  
rugger-jersey spine 135, 136
- S**  
sacroiliac joint  
ankylosing spondylitis 144, 146  
trauma 331  
sacroiliitis 144, 146  
sacrum  
fracture 330, 331  
neural foramina 331  
trauma 307, 330, 331  
saline tunnel technique 104, 106  
sarcoidosis 74, 75–76, 91  
satisfaction of search effect 17, 25, 26, 209, 277  
sausage digit 147, 150  
scaphoid fracture 333  
scatter 6, 7  
Schüller projection 292  
schwannoma  
acoustic 254  
peripheral 264, 266  
scleroderma 185  
scoliosis 141, 142  
scopolamine derivatives 193  
Scottie dog sign 144, 145  
seizures, tonic 240  
sheath insertion 99–100  
shock, severe 328  
shock lung 71–72  
short bowel syndrome 192  
shoulder joint  
degeneration 147, 148  
dislocation 147, 148  
luxation 334  
osteoarthritis 147, 148  
pain 147  
shunt placement  
angiography 97  
see also transjugular intrahepatic portosystemic shunt (TIPPS)  
signal intensity 21  
silhouette sign 43, 44, 45, 52, 54  
funnel chest 90  
silicosis 73–74, 91  
sinus thrombosis 239, 240  
sinusitis, acute/chronic 289, 290  
sinus/sinus diseases 286–290, 291–292  
benign tumor 290  
Caldwell view 288  
juvenile angiofibroma 290, 291  
malignant tumor 290, 292  
osteoma 290, 291  
radiography 288  
retention cyst 290, 291  
Waters view 288, 290  
skeleton, thoracic 45  
skin tumors 59, 60  
skip lesions 192, 194  
skull  
fracture 321, 323, 324  
see also cranium/cranial vault  
skull base metastases 251, 252  
small bowel/small bowel disease 188–192  
diagnostic imaging modalities 170  
diverticulum 190, 191  
double contrast examination 188, 189  
fistula 191, 192  
intussusception 191, 192  
leiomyoma 192  
lipoma 192  
mucosal hyperplasia 192  
obstruction 176, 181  
polyp 191, 192  
tumors 192  
valvulae conniventes 176  
soft tissue 18  
evaluation 120  
hemangioma 123  
tumors 162–164  
sound reflection 10  
spatial resolution in ultrasonography 10  
spinal artery, compression of anterior 261, 263  
spinal canal stenosis 141, 261, 263, 329  
congenital 266  
spinal cord tumors 261, 262, 263–264, 265, 266  
spinal dysraphism 258  
spinal nerve root compression 263, 264, 265  
spine 45  
bamboo 144, 146, 319  
diseases 139–146  
extra-/intra-dural tumors 261, 262  
intradural tumors 261, 262  
radiographs 328–329, 330, 331  
rugger-jersey 135, 136  
thoracic 307  
torsion injury 319  
trauma 261, 263  
tumors 261, 262  
see also cervical spine; lumbar spine  
spinous processes, fracture of transverse 329  
spleen  
blunt injury 327, 329  
rupture 327, 328, 329, 330  
spondylodiskitis 141, 143, 144, 261  
spondylolisthesis 263  
classification 144  
degenerative 140, 141, 266  
traumatic 317, 318  
with/without spondylolysis 144, 145, 146  
spondylolysis 144, 145, 146, 266  
stents  
aortic dissection 79, 82  
coronary artery 87  
esophageal hemorrhage 108–109  
fabric-coated 101, 102  
implantation 100, 101–102  
risks 37  
placement 97  
during endoscopy 168  
see also transjugular intrahepatic portosystemic shunt (TIPPS)  
stereotactic biopsy 278  
steroids, brain volume 257, 258



- stochastic effect 32  
 stomach disease, diagnostic imaging modalities 169–170  
 stool  
 amount 176  
 defecation problems 198–199  
 distribution 176  
 retained particles 193  
 storage phosphors 7  
 strangulation 322, 323  
 stroke 237, 238, 239–240  
 management 240  
 subacute 239  
 study  
 cancellation risks 27  
 contrast media 29–31  
 ill-prepared 28–29  
 nonindicated 27–28  
 quality 18, 19  
 Sturge–Weber syndrome 260  
 subarachnoid hemorrhage 235–236, 237  
 normal-pressure hydrocephalus 257  
 trauma 324  
 subchondral cysts 151  
 subclavian line 310  
 subdural hematoma 323–324  
 infected 245  
 subependymal hamartomas 260  
 Sudeck disease 139  
 summation effect 25  
 swallowing problems 182–183  
 Swan–Ganz catheter 310, 312  
 Swyer–James disease 61, 62  
 synovial cyst 264, 265  
 synovial hemangioma 164  
 synovial osteochondromatosis 153  
 synovitis, transient 154
- T**  
 T1 value 14–15  
 T1-weighted image 15  
 T2 value 14–15  
 T2-weighted image 15  
 talus, osteonecrosis 159  
 tapeworm  
 colon parasitosis 197, 198  
 dog 202  
 tea-cup phenomenon 273, 274  
 teeth 302, 303  
 temporomandibular joint (TMJ)  
 disease 293–294  
 dislocation 295  
 function 294  
 luxation 294, 295  
 tension pneumothorax 310, 311, 312, 315  
 teratoma 84, 215  
 thoracic spine trauma 307  
 thoracic wall 45  
 abnormalities 46  
 thorax analysis 40, 43–45  
 three-dimensional view 21, 22  
 thrombolysis 102  
 cerebral infarction 237, 238–239, 240  
 risks 239  
 thymoma 85  
 thymus 85  
 thyroid disease, contrast media risks 29  
 tibial head fracture 20, 337  
 tinnitus 254  
 tissue biopsy 104–105, 106–107  
 core needle biopsy  
 breast 275–276  
 lung 54, 55  
 lung 54, 55, 104, 105  
 mediastinum 104, 106  
 pancreas 214  
 risks of image-guided 37  
 stereotactic needle 278  
 toe joint, rheumatoid arthritis 160  
 toe pain 160–161  
 toxic megacolon 177  
 toxoplasmosis, cerebral 245  
 trachea  
 stenosis 83  
 tears 315  
 traction diverticula 183–184  
 transient ischemic attacks (TIAs) 237  
 transjugular intrahepatic portosystemic shunt (TIPPS) 97  
 implantation 108–109, 209  
 trauma 304  
 abdomen 305, 308, 309, 328–329, 330, 331  
 cervical spine 305–306  
 chest 305–306  
 deceleration 315, 324  
 diagnostic modalities 304–308  
 fractures 331–338  
 head 306–307, 320, 321–322, 323–324  
 intracranial injury 306–307  
 liver abscess 203  
 lower limb 308  
 lumbar spine 307  
 lung radiolucency loss 61, 62  
 luxations 331–338  
 major 304–305  
 medial cerebral artery 322  
 motor vehicle accident 315  
 pelvis 307  
 penetrating 326, 327  
 perirenal hematoma 223, 224  
 renal 223, 224  
 sacrum 307  
 spinal 261, 263  
 thoracic spine 307  
 upper limb 307–308  
 ureters 224  
 see also polytrauma  
 tuberculosis 51, 91  
 miliary 67, 68, 74  
 tuberous sclerosis 259, 260  
 renal angiomyolipoma 222
- U**  
 ulcerative colitis 196, 197  
 ulna  
 dislocation of distal 333  
 epicondyle bony avulsion 333  
 wedge fracture 332  
 ultrasonography 10, 11  
 abdominal 308  
 contrast media 31  
 renal 219, 220–221  
 risks 35  
 uncovertebral joint osteoarthritis 264, 265  
 underexposure 7  
 upper extremity joints 147–150  
 upper limb trauma 307–308  
 ureters  
 calculi 219  
 obstruction 224  
 trauma 224  
 urinary bladder  
 abdominal radiograph 175  
 rupture 328  
 urinary obstruction 221, 227  
 urinoma 224  
 urography, intravenous 219
- V**  
 vacuum phenomenon 139, 140, 265  
 valvulae conniventes 176  
 vascular access 110–111  
 vascular occlusive disease interventions 99–103  
 vascular system, contrast media examination 8  
 vena cava, MR angiography 97  
 vena cava filter placement 109–110  
 angiography 97  
 venography 97, 102–103  
 CT 79, 80  
 venous angioma 259, 260  
 venous hemorrhage, cranial 236  
 venous obstruction 102–103  
 venous sinus thrombosis 239, 240  
 venous thrombosis 79, 80  
 ventilation–perfusion mismatch 79, 81  
 ventricle, left (cardiac)  
 aneurysm 89  
 failure 63–64, 65, 66  
 ventricle drain, dislocated 25  
 ventriculostomy, neurosurgical 236  
 vertebral arch closure defect 21  
 vertebral artery 302  
 vertebral body 328–329  
 fractures 120  
 vertebral end plate fracture 133  
 vertebroplasty 133  
 vessel dilatation 97  
 vestibuloacoustic nerve 254  
 videofluoroscopy, swallowing act 182–183  
 viewing monitors 15, 16  
 vision  
 double 296  
 visual acuity decrease 296  
 visual field defect 250, 252–253  
 volume changes 26  
 volvulus 177, 179, 181  
 von Hippel–Lindau disease 213–214  
 hemangioblastoma 243

**W**

Walker, Arthur E 260  
water 18  
Wegener disease 59, 69  
Westermark sign 78–79  
whiplash injury 319  
Wilms tumor 222, 225

**X**

X-gradient 12, 14  
X-rays  
  attenuation 6, 7  
  detection 6–8  
  generation 6, 7

**Y**

Y-gradient 12, 14

**Z**

Zenker diverticulum 183, 184  
Z-gradient 12, 14