Radioimagistic Diagnosis used in Ophthalmology

USMF “Nicolae Testemițanu”

HOMEWORK

1. Radiography of the head – technique of investigation, projections, indications and contraindications

2. CT of the head - indications and contraindications

3. IRM of the head - indications and contraindications

4. Focht method – technique of investigation, indications

5. Komberg –Baltin method - technique of investigation, indications

6. Method with metallicaly sonde - technique of investigation, indications

- Any anatomical structure of the human body is not comparable to face, which is important for an external evaluation and self-esteem as aesthetically as personally.
- The role of imaging in ophthalmology for an early and correct diagnosis is difficult to sub estimate - this medical discipline has the central role in ophthalmic pathology.

RADIOIMAGISTIC METHODS USED IN OPHTHALMOLOGY

1. Radiography conventional (standard) and digital
2. CT scan
3. MRI
4. USG

- Conventional and digital Radiography allows to determine the complications of orbital trauma : orbital wall fracture with or without the involvement of orbital fissure, foreign intraorbital body, hemophthalmus (bleeding) and orbital emphysema.
- CT scan specify the severity of orbital fractures and injuries of juxtaposed soft tissues.
- MRI is useful for determining of the pathologies of soft tissues and detection of radiotransparent foreign bodies.

Basic Principles

- The radiological investigation represent one of the most important investigation in whole medical imaging, especially in cranio-cerebral and face trauma, also in the trauma of orbits. The final succes depend on right investigation, especially in simetric position of patient.
- In case of non-collaborative patient, or in severe cranio-cerebral trauma, the effectiveness of radiological exam will be less.

The radiological investigation

Basic projections: anterior, posterior, lateral, axial.

The investigation usually start with frontal projection (anterio-posterior) and lateral pojection (from trauma side).

During the investigation the radiologist can make other types of projections (it’s depend on the character of craniocerebral trauma).

The anterior projection: visualisation of orbits, nose walls, maxillary sinus, maxilla and mandible.

The possibility to exclude the extraorbitar lesions.

- The radiography of orbits shows a metallic foreign body 1x2mm into the left orbit.

- The radiography of orbits shows a metallic foreign body 3x10 mm into posttraumatic pseudochist in the left orbit.

For the location of the intraorbital foreign body, three radiographic procedures are used:

1. Focht method
2. Komberg- Baltin method
3. The method of locating with metallical sonde.

Focht method

It is an ascheletical X-rays exam that uses 2 films. During the investigation the patient is those who hold the cassette at the internal angle of the eye, near the nose. The x-rays pass trough temporal region perpendicular to the films.

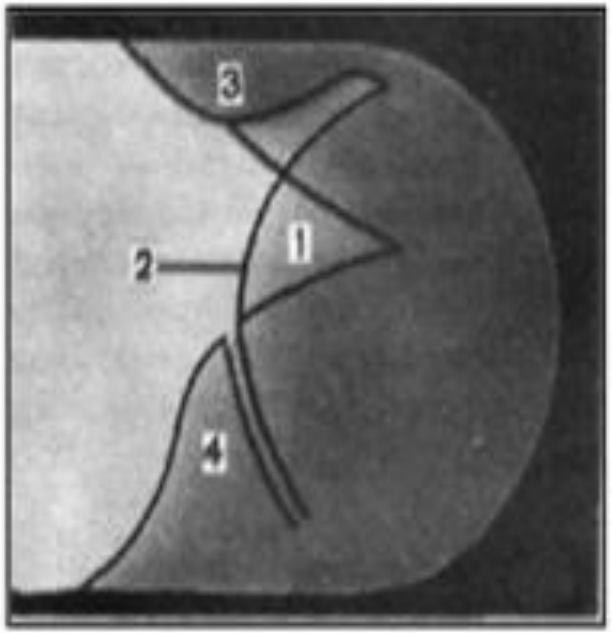

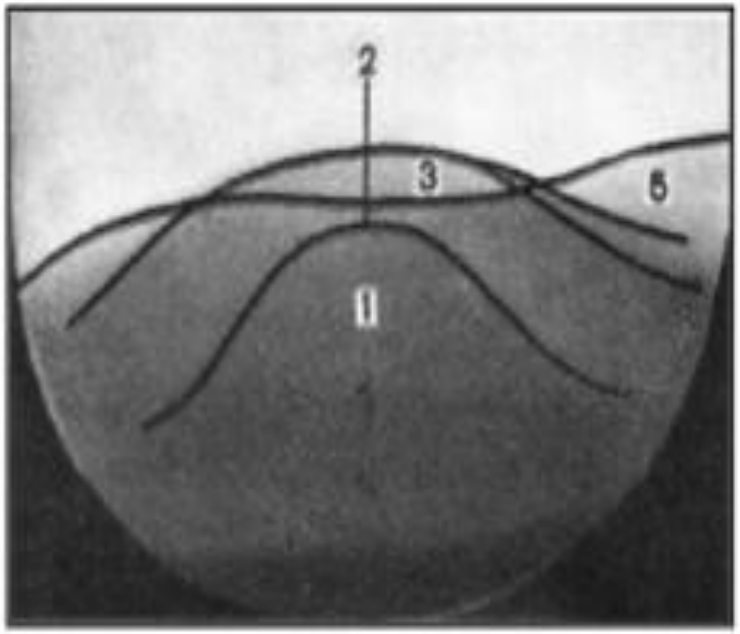

1. eyeball 2. cornea 3. superior eyelid 4. inferior eyelid

- Focht method- allows to see the foreign body into the anterior part of eyeball

- Focht method shows the localization of foreign body into the iris

Komberg- Baltin method

- the localization is done by a plastic prosthesis with metal parts situated at 3, 6, 9, 12 hours.
- The prosthesis is installed at the external surface of the affected eye. Before the investigation the affected eye will be anesthetized with solution of 0.5% lidocaine.
- An antero-posterior radiographic exam.

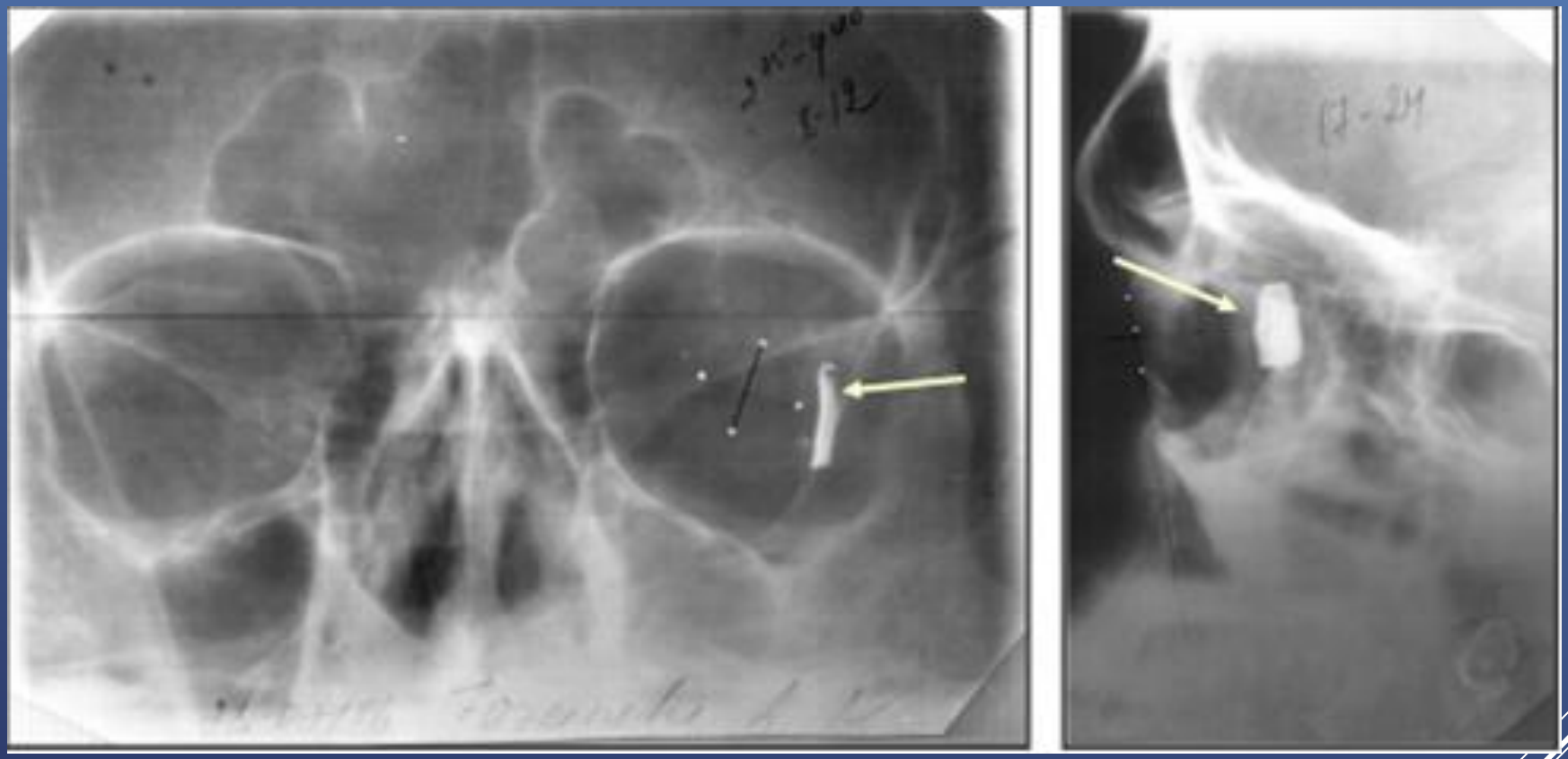

- In projection of left orbit is found a metallic foreign body, placed between 2 and 5 h, into the eyeball.

The method of locating foreign bodies with metallical sonde.

Fixing perpendicular the sonde in the center of the eye cornea (that will be anesthetized with dicaine). An antero-posterior and lateral radiographic exam is maked.

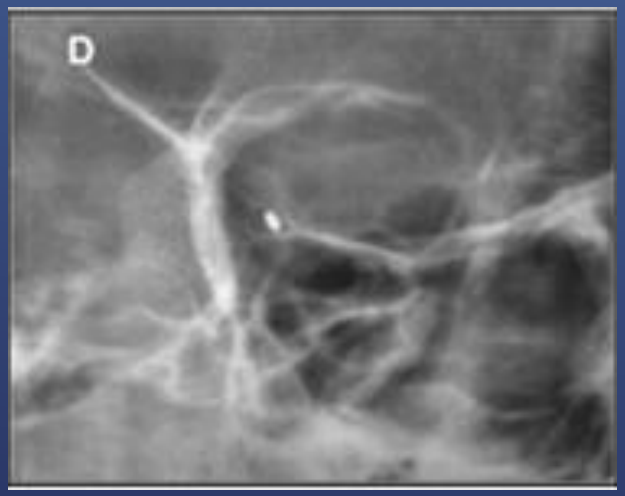

Metallic foreign body 5x7 mm, localized outside of eyeball, into the nervus opticus.

CLINICAL CASE : INTRAORBITAR FOREIGN BODIES

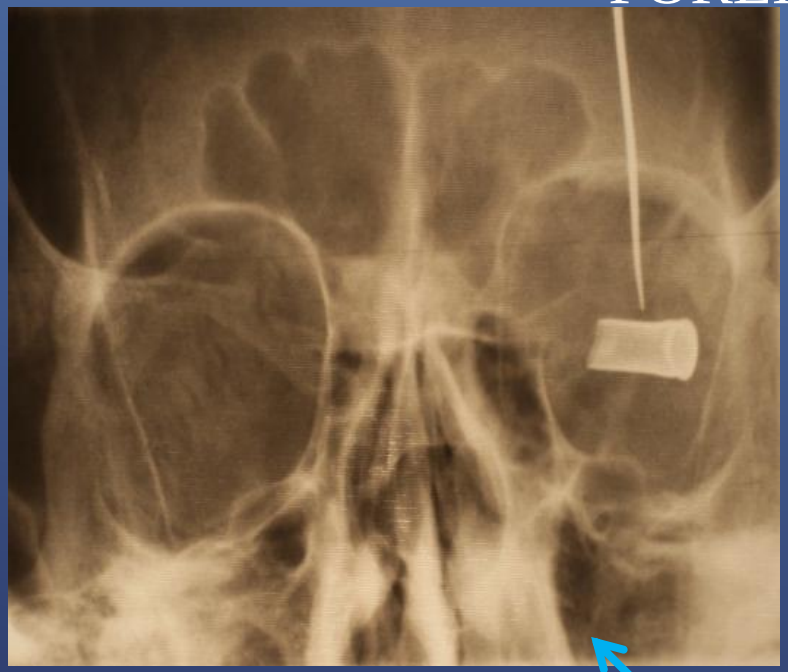

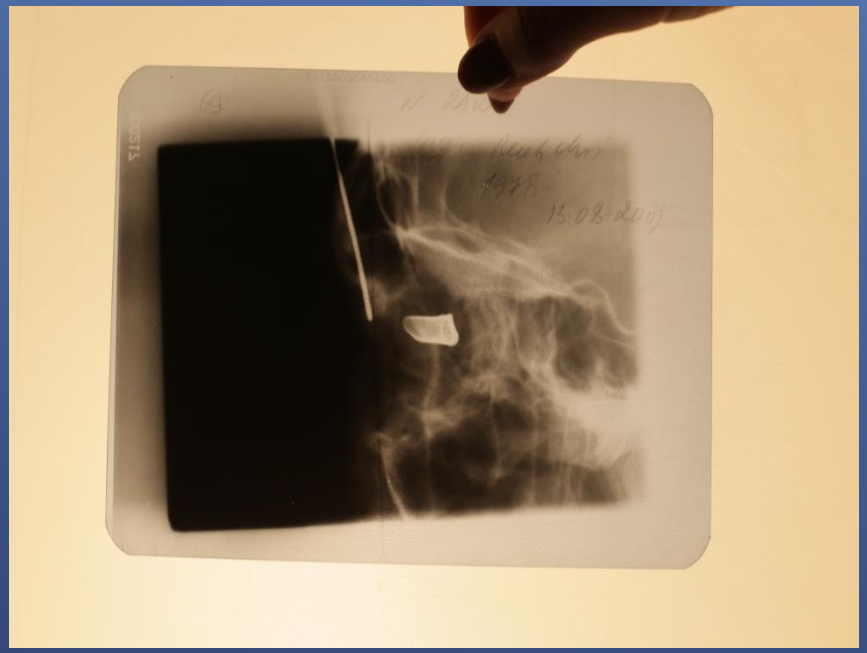

Orbital trauma by firearm. Bullet localized by metallic sonda . Simultaneously reveal an orbital floor fracture in left orbit . The bullet was extracted, eyeball was preserved that organ.

Large penetrating trauma suffered, that did not allow the application of prosthesis to perform radiography by Komberg method. Try to locating with sonda.
1x2 mm metallic foreign body placed into the eyeball.

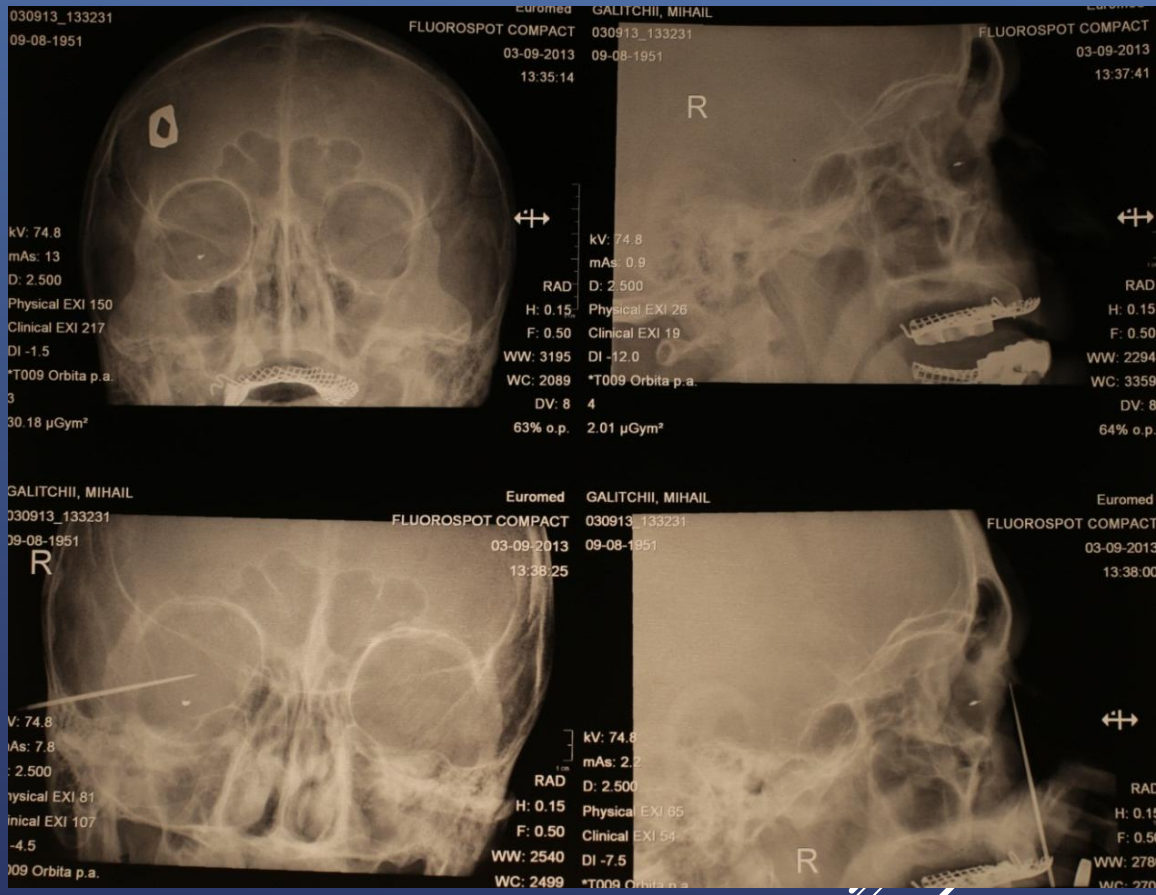

CLINICAL CASE

- Multiple foreign bodies. Corn shrapnel in left orbit, but eyeball was not involved in the process.

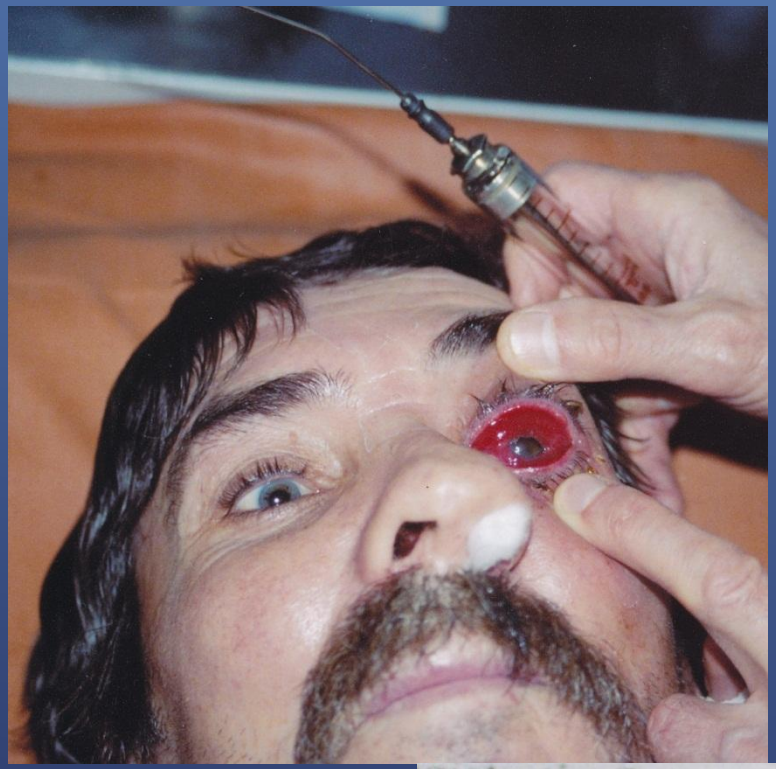


gistrați oficial

Fracture of nasal bones

Lateral projection. Nasal bone fracture with fragments displacement following a sports injury.

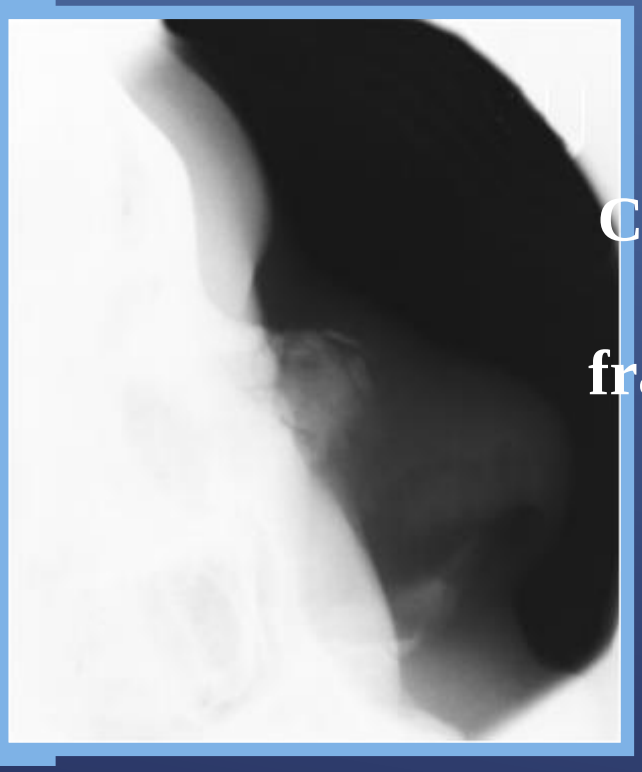

Lateral projection. Comminuted nasal bones fracture after a fall as a result of syncope.

CT - NASAL SEPTUM FRACTURE

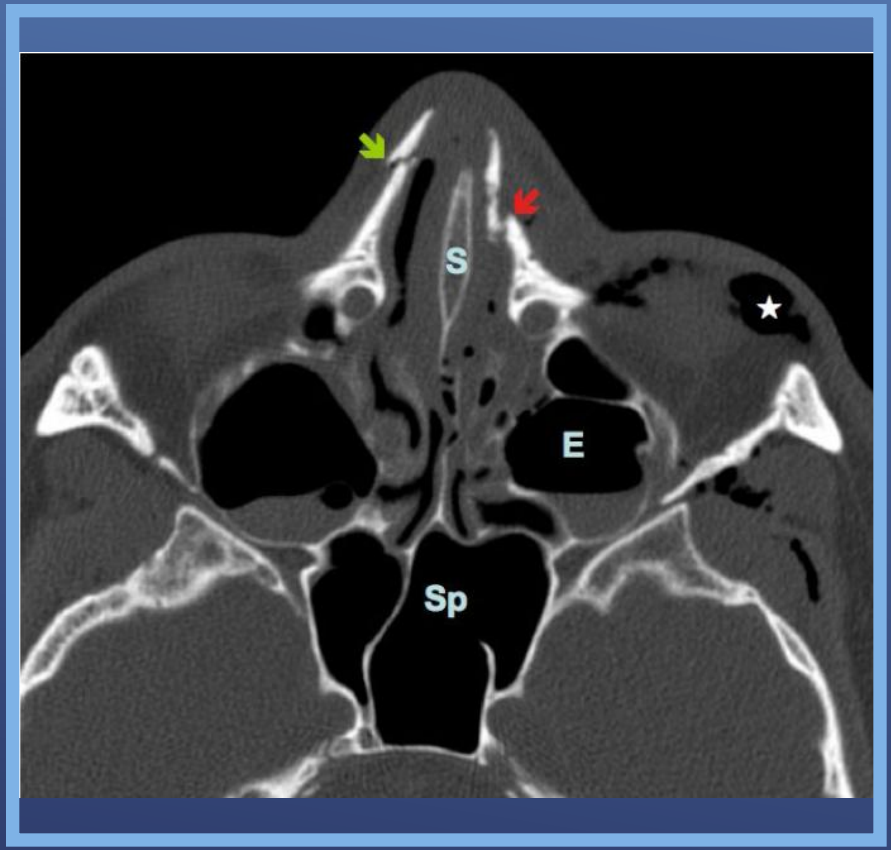

Bilateral nasal bone fracture (arrows). The fragments are moved to the right, indicating trauma from the left. * Indicates orbital emphysema (fracture of maxillary sinus wall).

Posttraumatic nasal deformity. The angulation of cartilaginous portion of the nasal septum. Red arrows - blood in the nasal cavity. * - emphysema in preseptalis region, anterior of eyeball.

ORBITAL FRACTURE

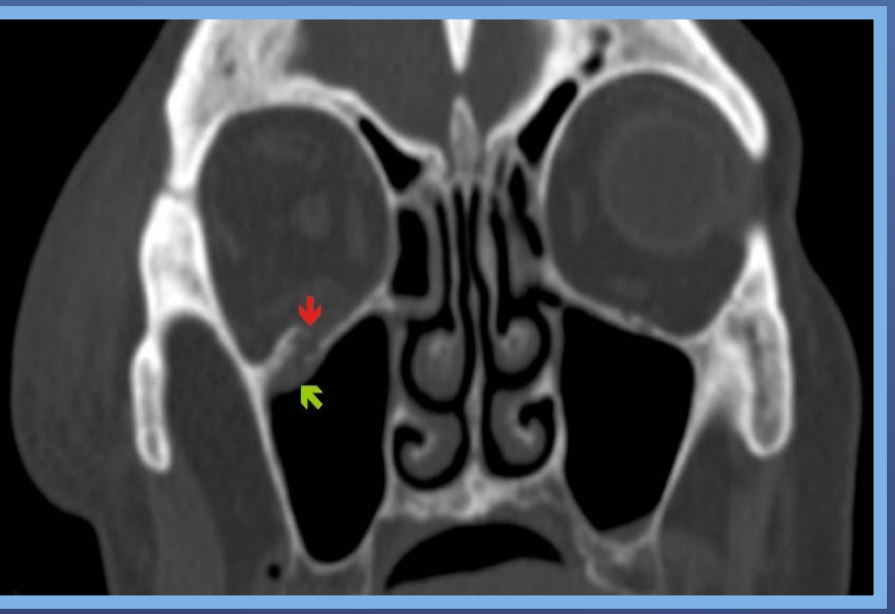

Blow-out fracture

Fractured bone is moved outside the orbit, most commonly affects the lower wall, but can affect any wall. Up to 30% of patients had ocular lesions associated. Clinical: enophtalmia, diplopia, hypoesthesia. Imaging: m. Rectus inferior has a round shape. CT: coronary sections in bone and soft tissue window demonstrates fracture of inferior orbital wall. Inferior rectus muscle is "trapped in hole". The red stars correspond at posttraumatic edema

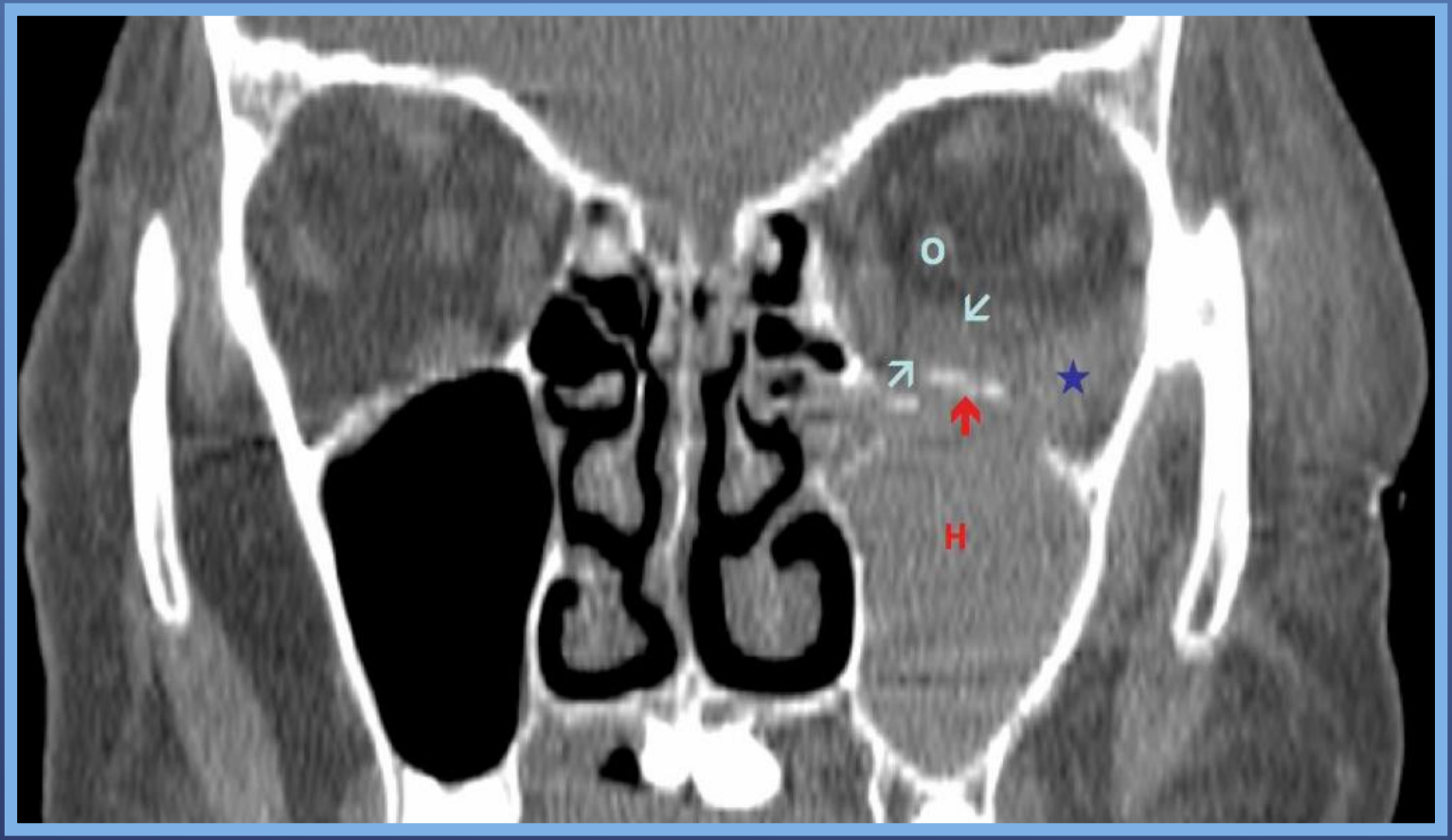

Fracture blow-in. Fractured bone is displaced toward the orbit, may involve any wall. Clinical: exophtalm, reduced visual acuity (trauma to the eyeball, optic neuropathy, optic nerve canal fracture).

In orbital trauma by dropping: the fracture of inferior orbital wall with fragment displacement (red arrow) and medial rectus muscle dislocation (blue arrows), retrobulbar hematoma (blue stars). H – hemosinusitis (blood in sinus). O - optic nerve.

Fractures Le Fort II type - are usually caused by kicks applied to the middle portion of the jaw. The fracture line crosses the nasal bones at or below the nasofrontal suture, the lacrimal bone, and the frontal (ascending) apophysis of the superior jaw, laterally meshing the orbital plane to the sphinomaxillary fissure, then extending obliquely downwards following a descending tract through the zygomatic process of the maxilla and the weak resistance region adjacent to the wall of the maxillary sinus.

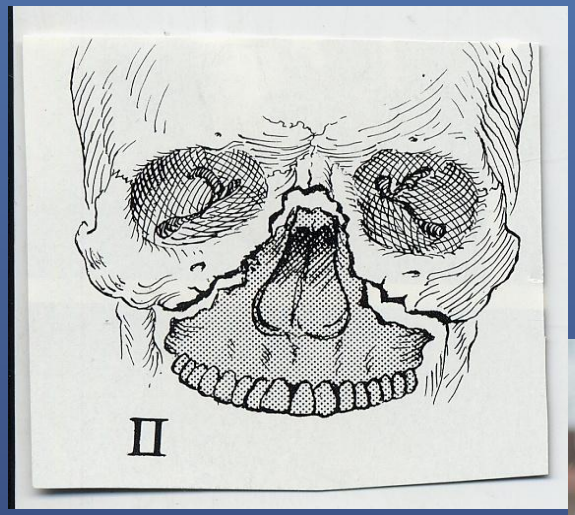
II

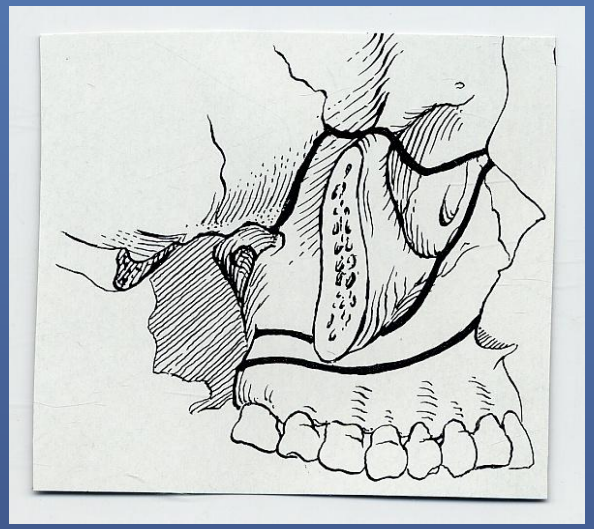

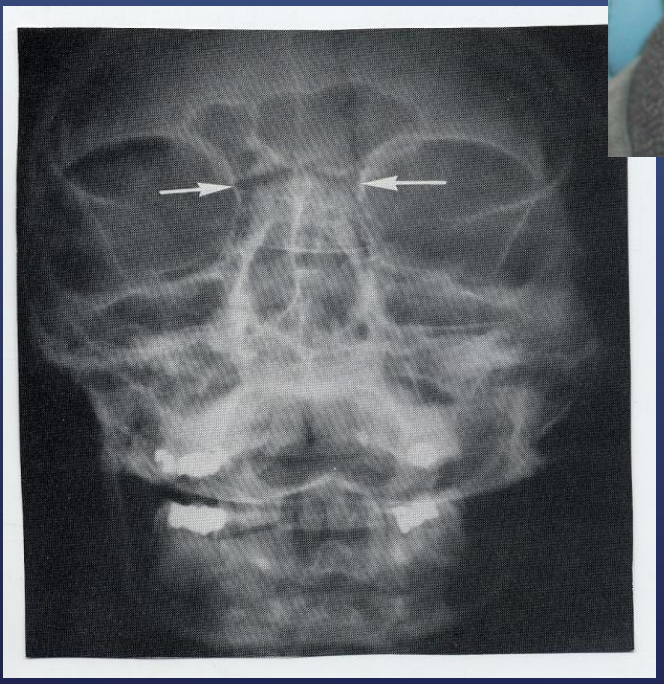


15/10/2007 02:29

Le Fort III fractures (high craniofacial disjunctions) - may be caused by kicks applied to the upper jaw or nose region. The fracture line starts from the nasofrontal or frontomaxillary suture region, then extends posteriorly to the etmoid cells, vomer, tuberosity and pterigoid apophysis, and laterally to the anterior (apical) apophysis of the superior jaw, the orbital plane and the zigomatic arcade. This type of fracture is frequently associated with distortion of dura mater, the occurrence of ocular and infectious complications.

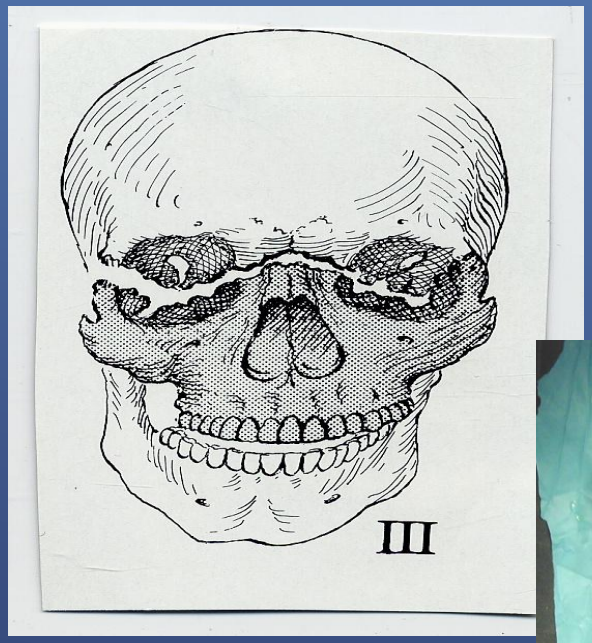
III

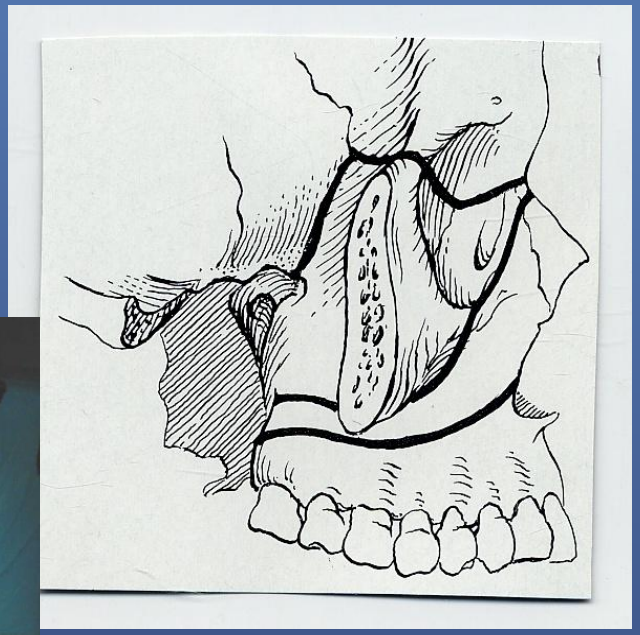

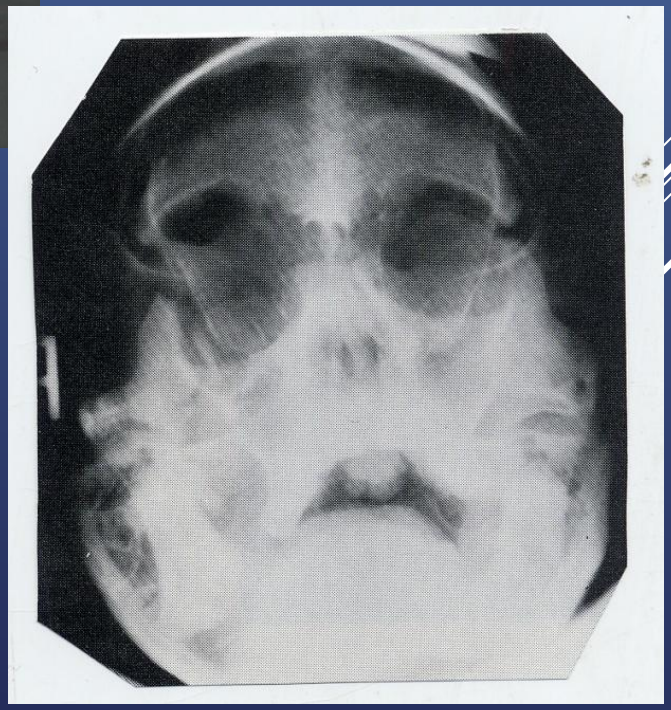

GRAVE'S OPHTHALMOPATHY

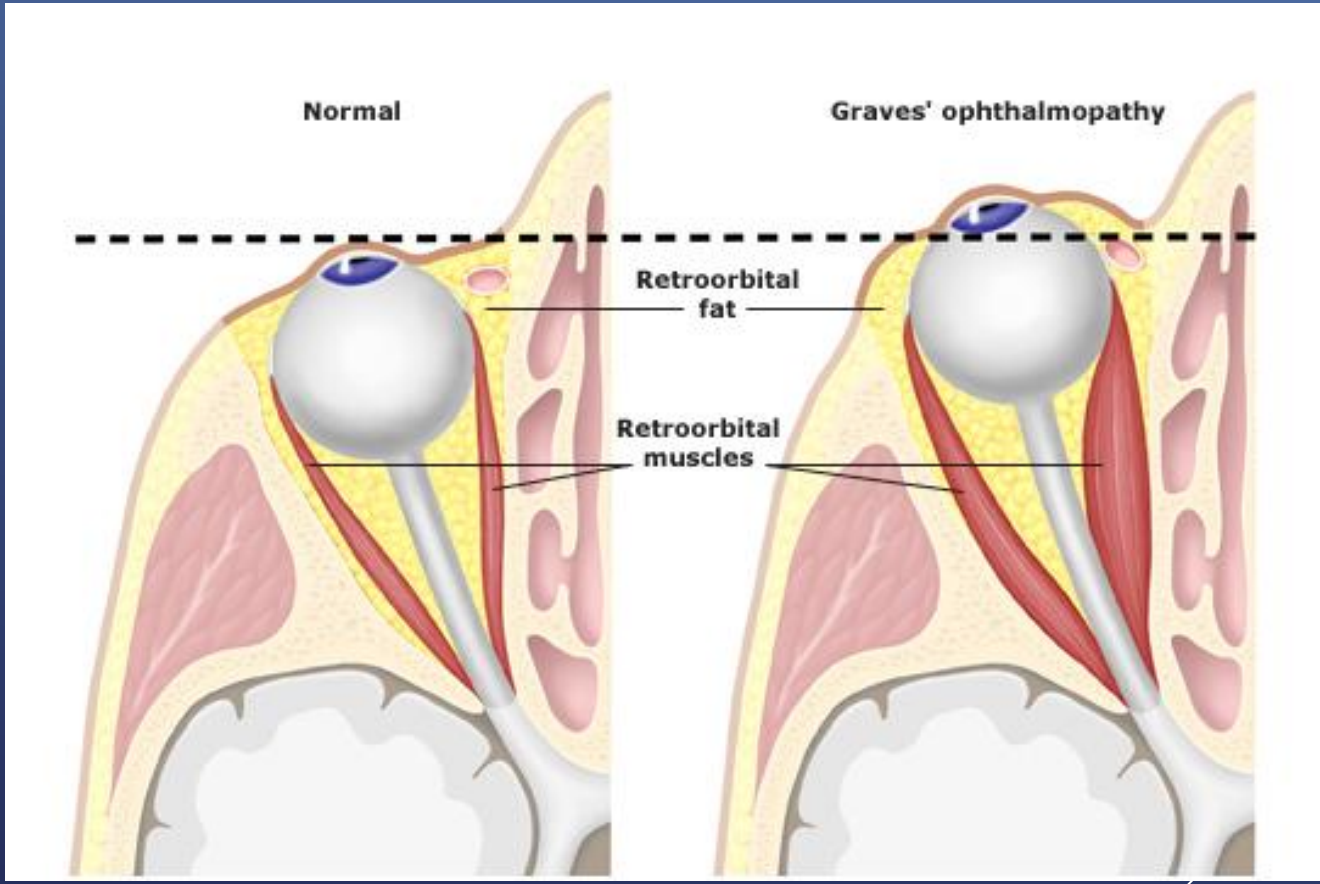

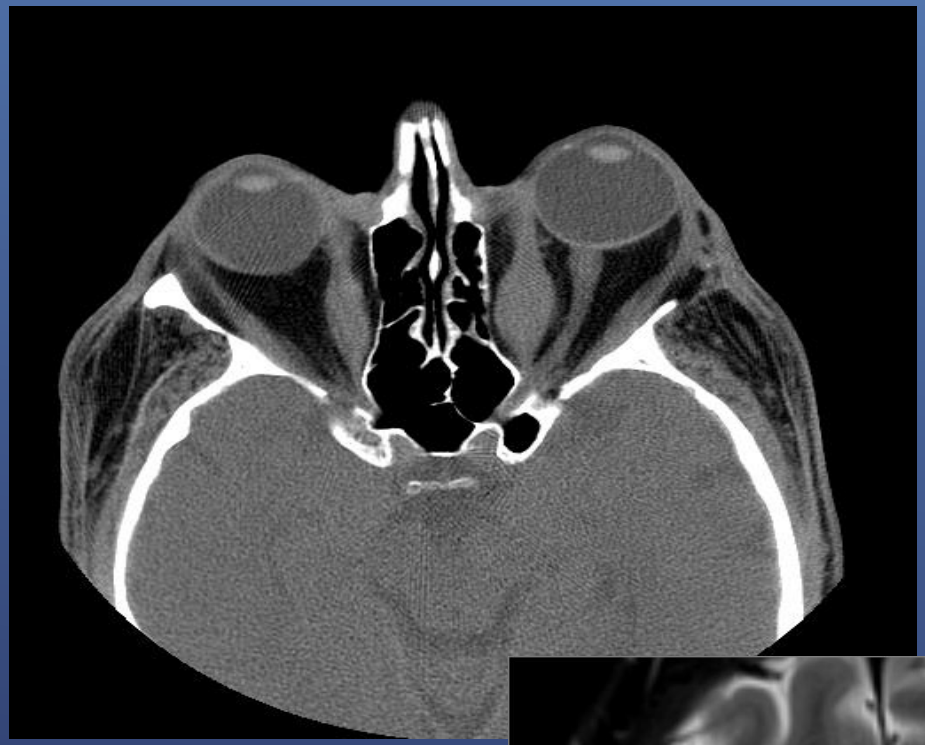


A
W/L [1201,5/781,00010]
AVIP
Толщ. По умолчанию
Промежуток По умолчанию
R
L
12,1mm
I

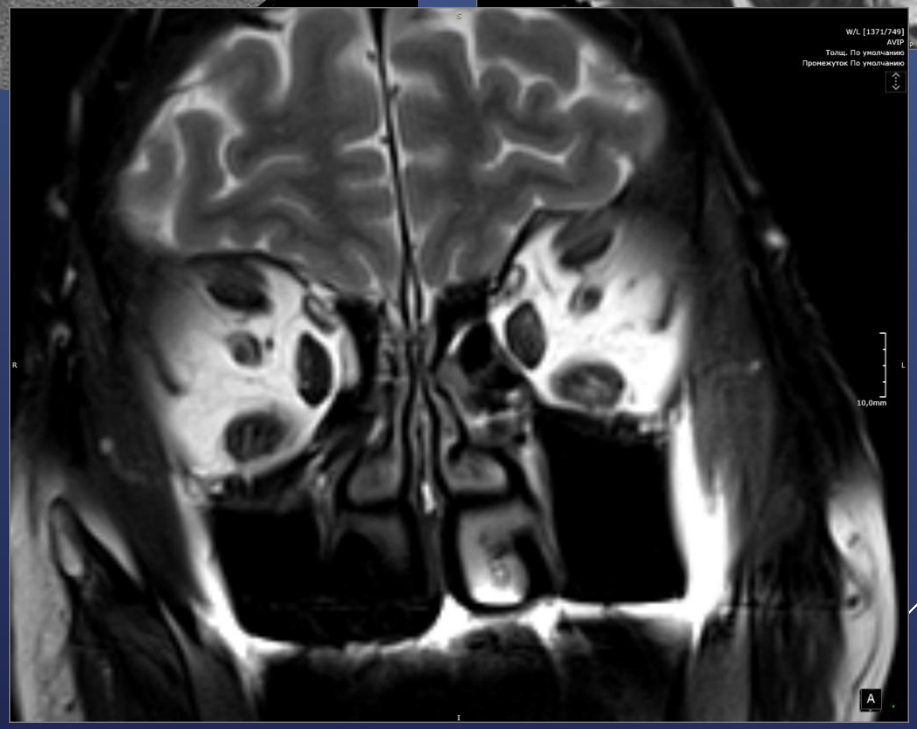
W/L [1371/749]
AVIP
Толщ. По умолчанию
Промежуток По умолчанию
R
L
10,0mm
A

ORBITAL DISORDERS (CT)

Inflammation/Infection

Orbital pseudotumor
Thyroid ophthalmopathy
Orbital cellulitis
Abscess
Neoplastic
Lymphoma
Dermoid
Metastases
Vascular
Hemangioma
Vascular malformations

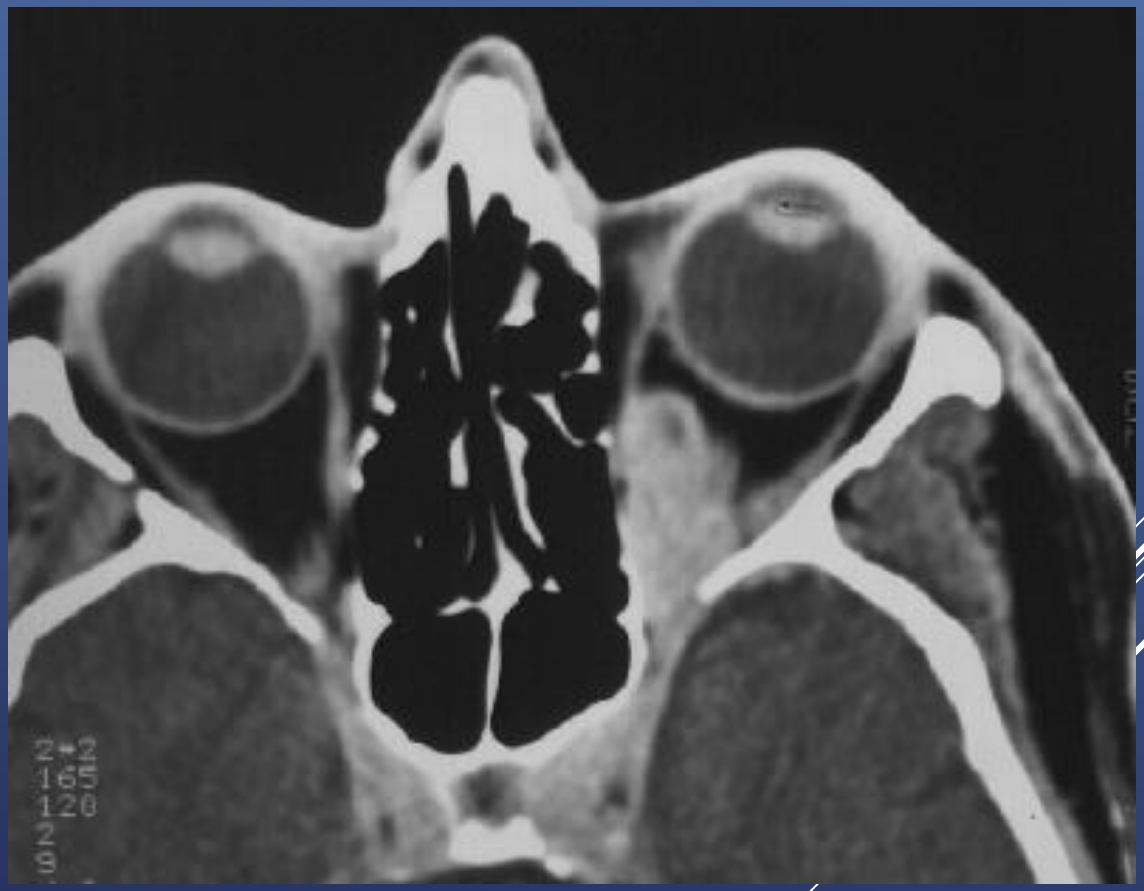

ORBITAL DISORDERS (MRI)

Inflammation/Infection
Orbital pseudotumor
Thyroid ophthalmopathy
Orbital cellulitis
Abscess

Neoplastic
Lymphoma
Dermoid
Metastases

Vascular
Hemangioma
Vascular malformations

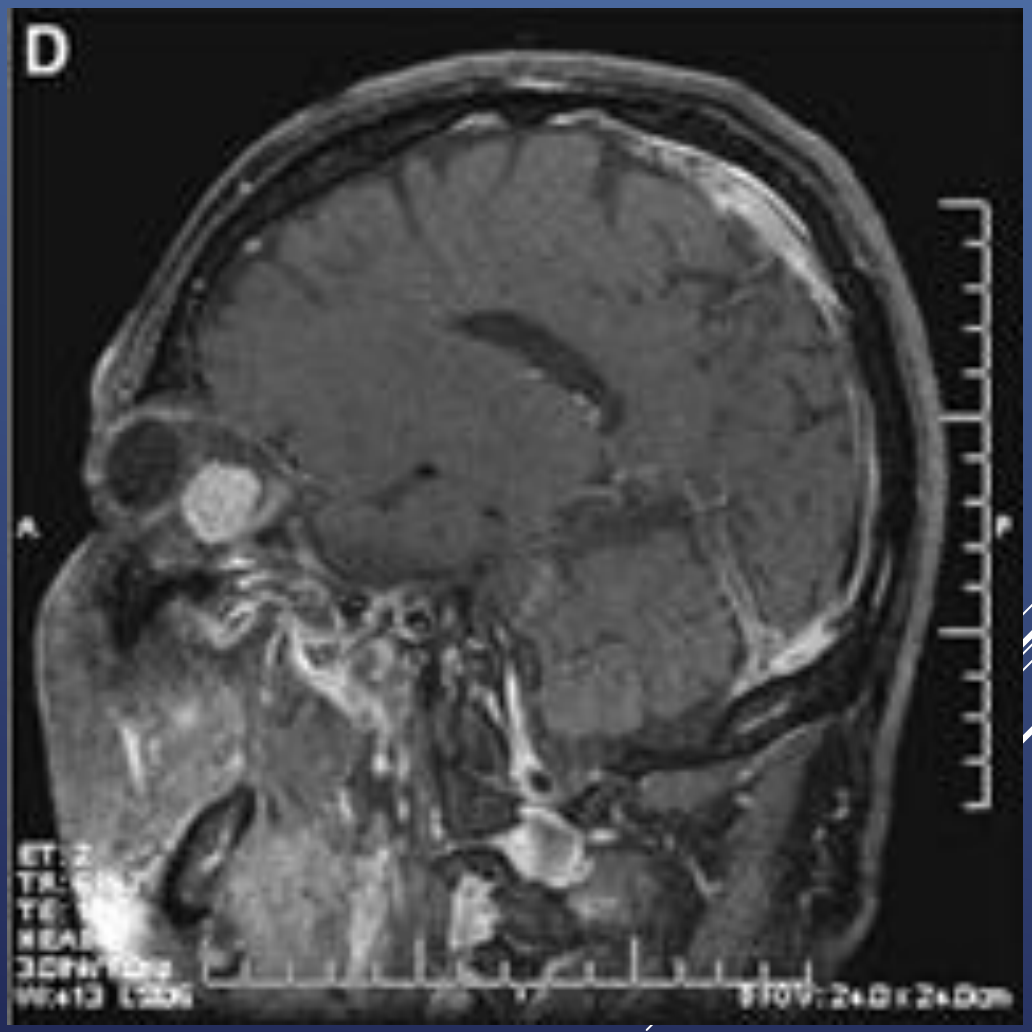

Trauma of left eyeball

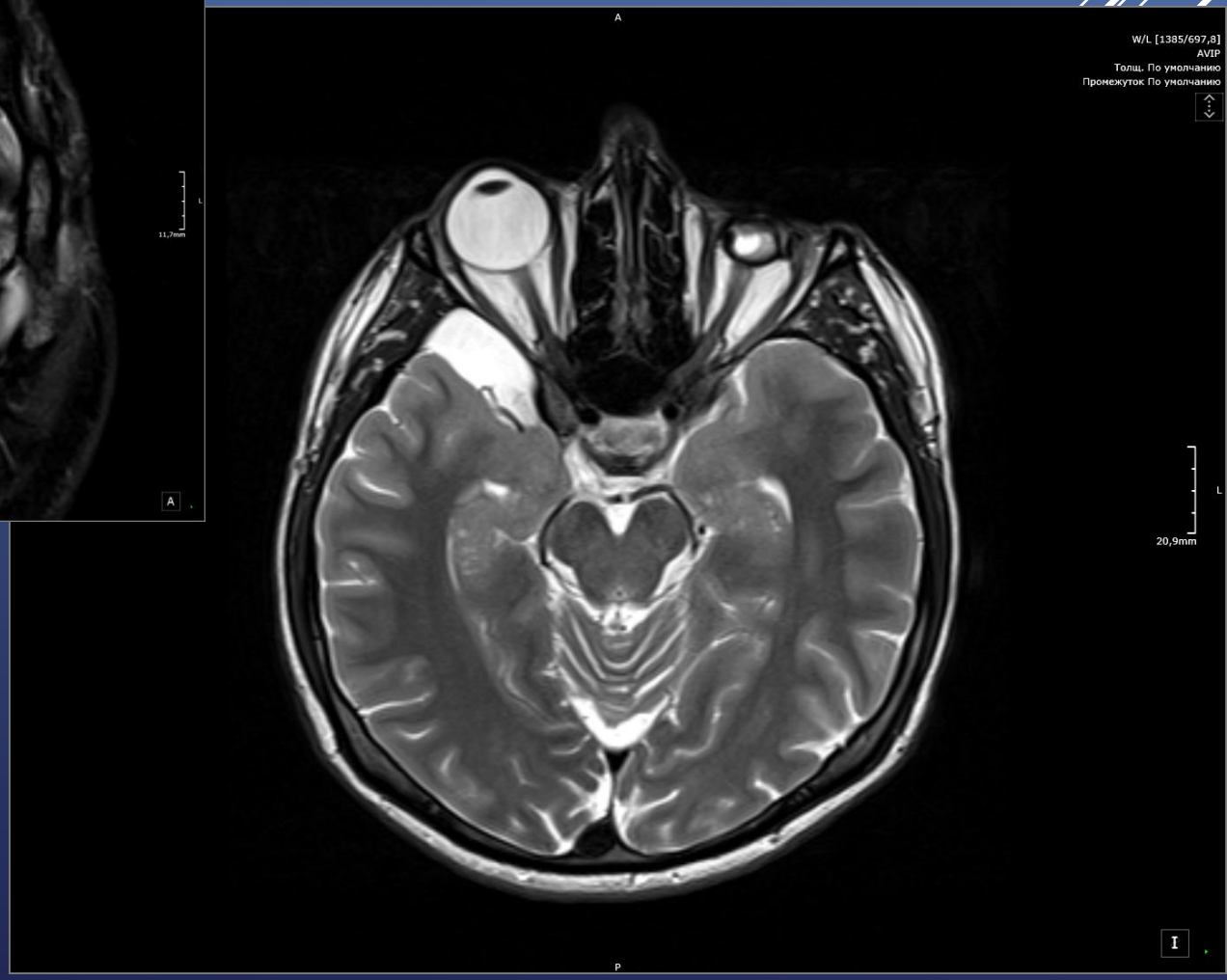

Retrobulbar tumor

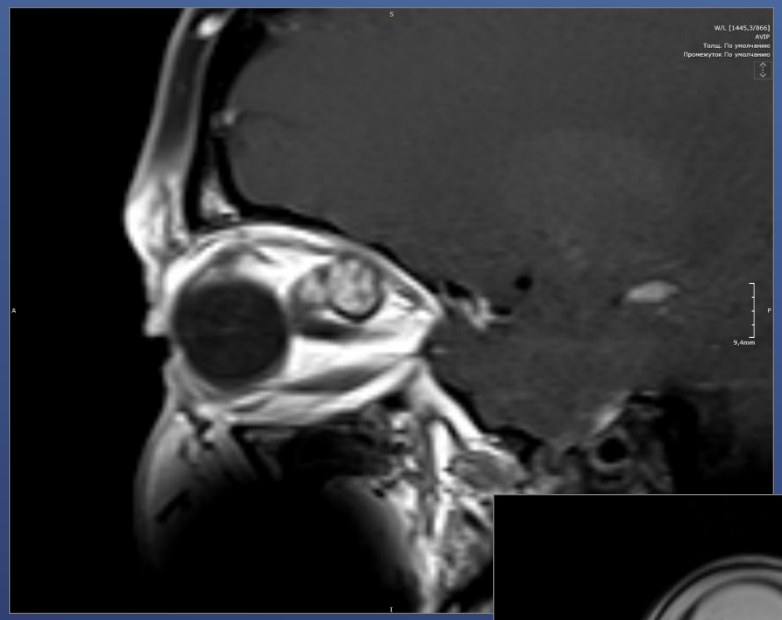

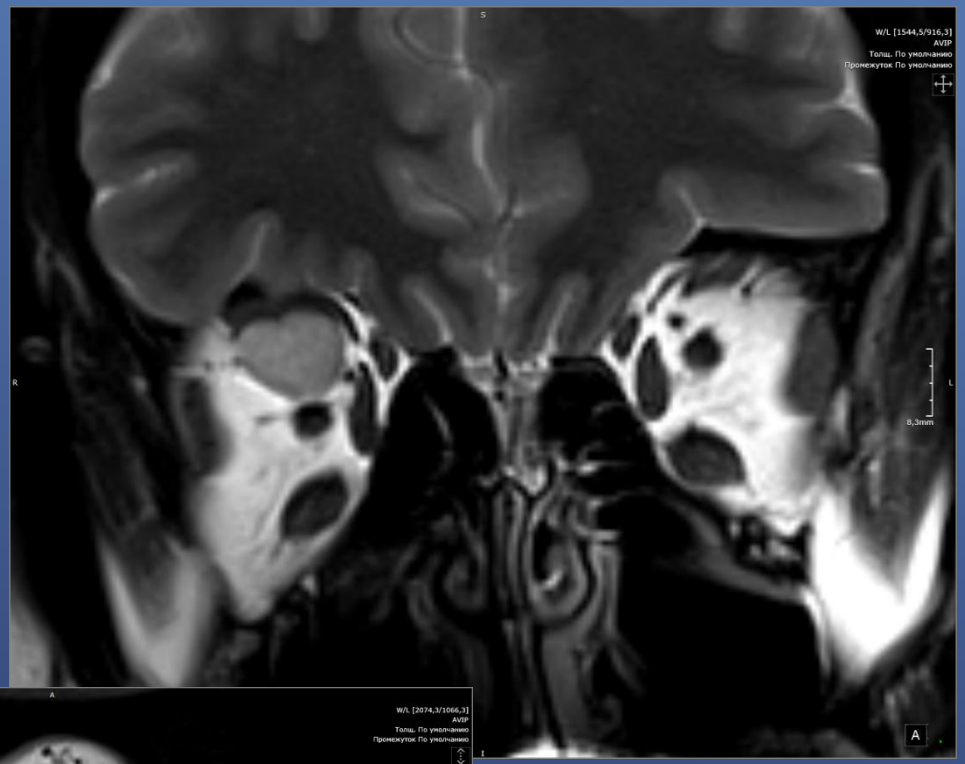

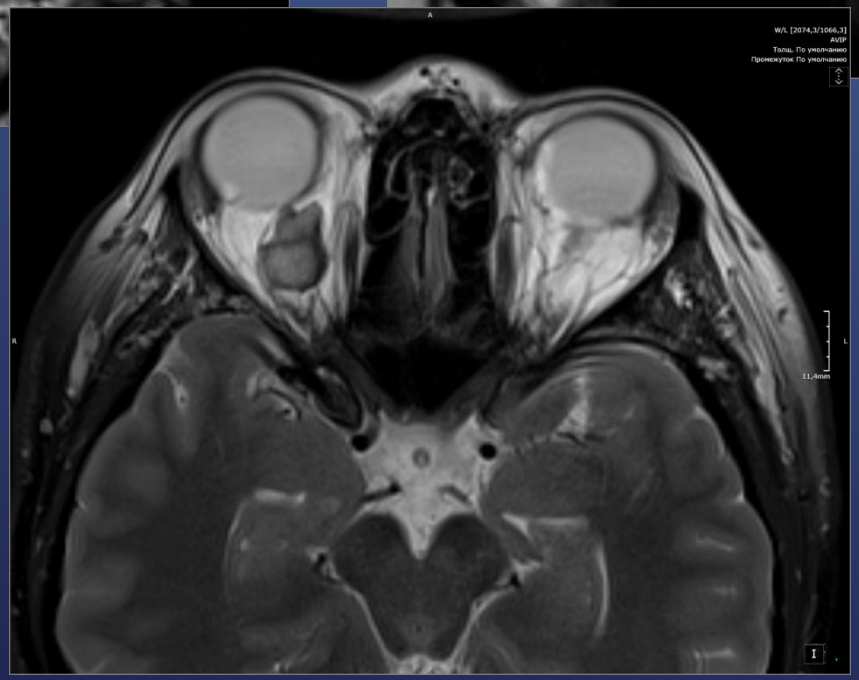

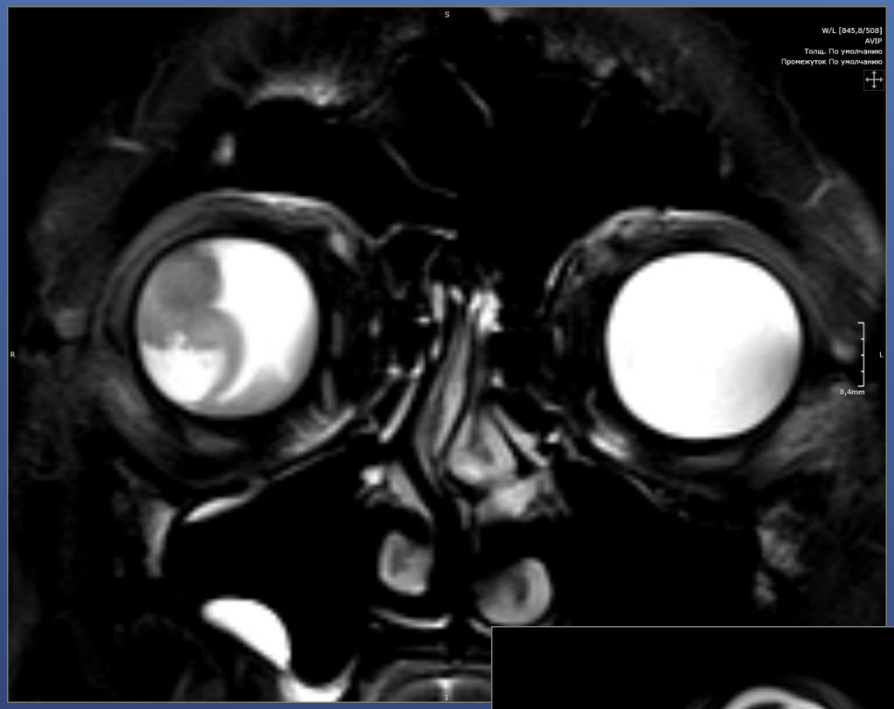
S
W/L [845,8/508]
AVIP
Толщ. По умолчанию
Промежуток По умолчанию
R
L
8,4mm


A
W/L [1095,8/646,00010]
AVIP
Толщ. По умолчанию
Промежуток По умолчанию
R
10,8mm

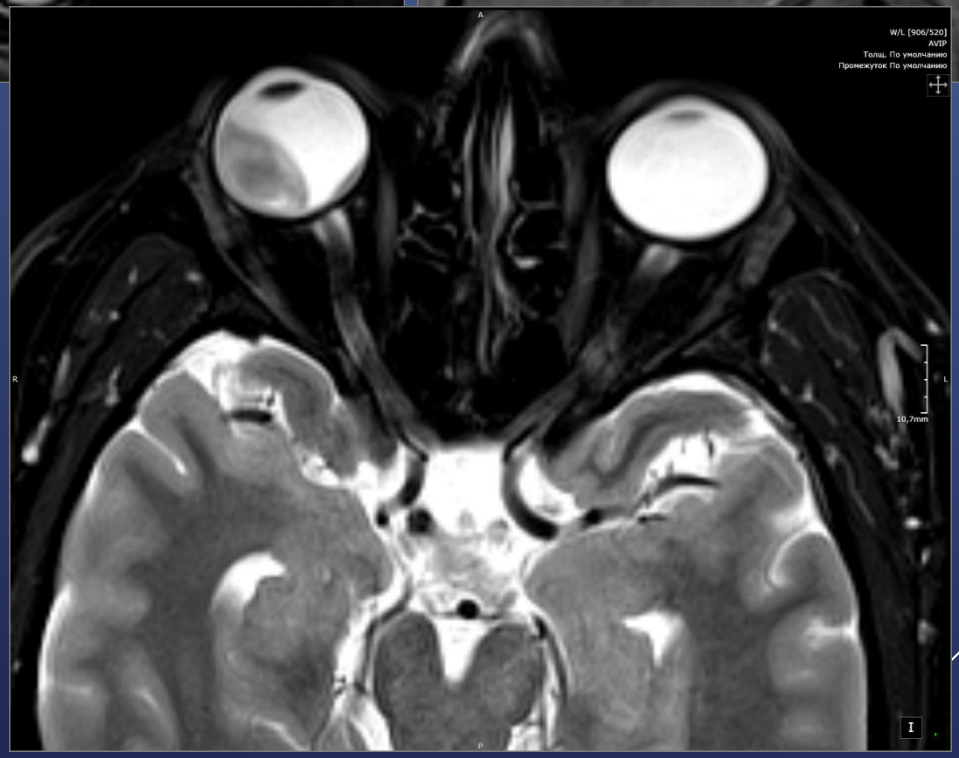
A
W/L [906/520]
AVIP
Толщ. По умолчанию
Промежуток По умолчанию
R
L
10,7mm
P

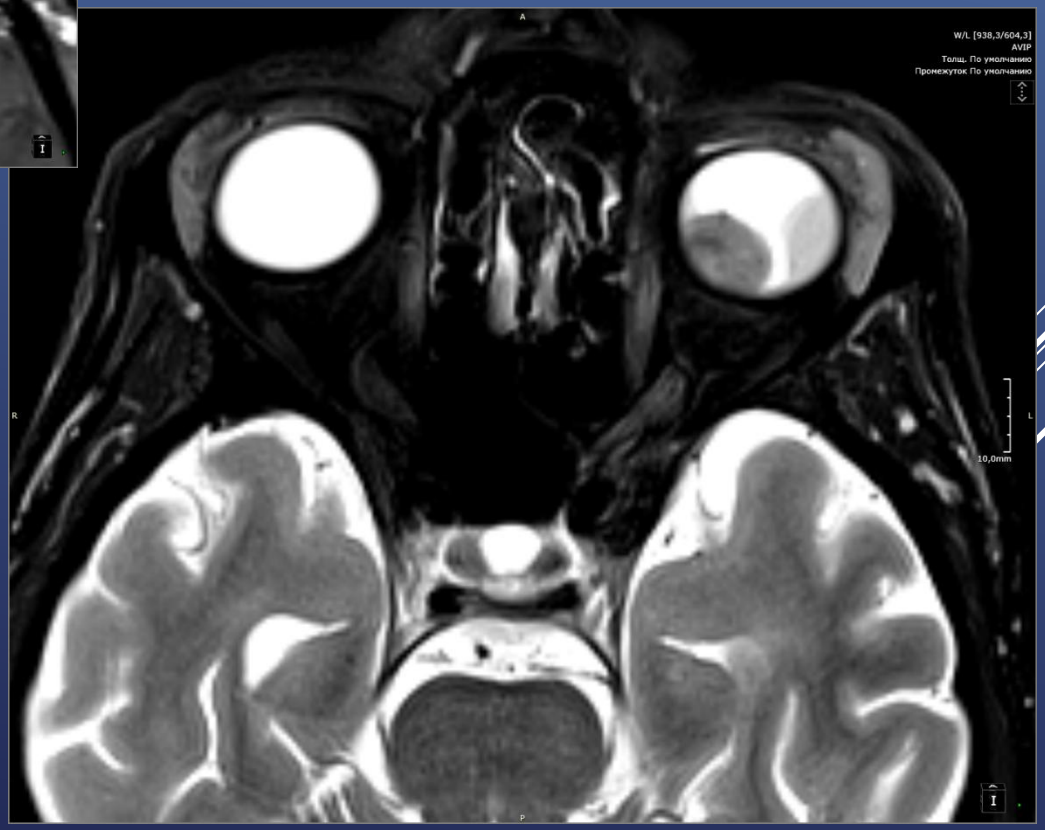

Intraorbitar tumor with retinal detachment

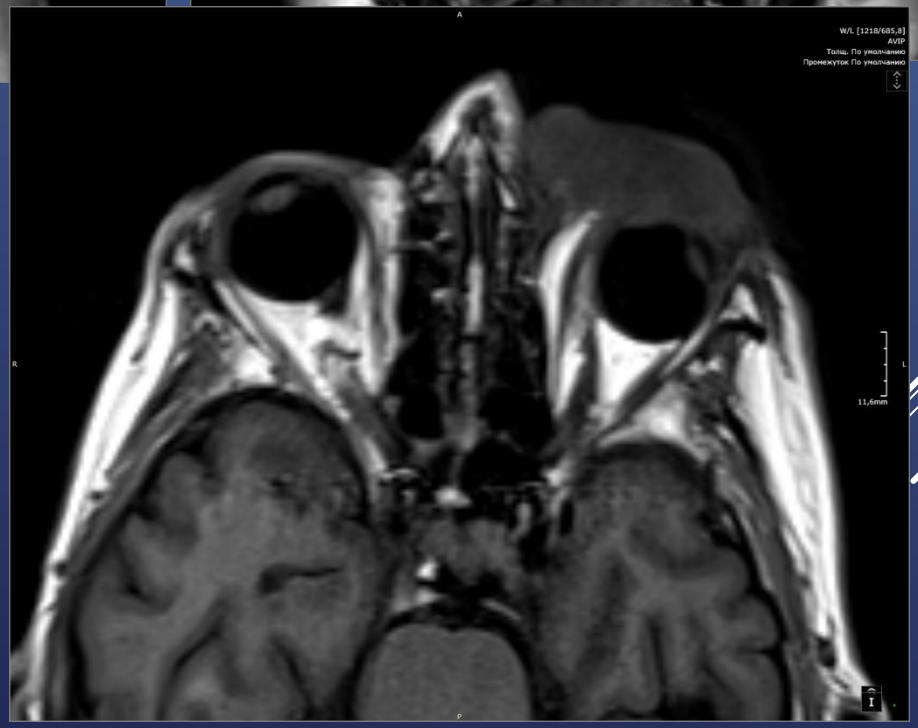

Tumor of orbit

THANK YOU FOR ATENTION